



ਭਾਰਤ ਸਰਕਾਰ
Unique Identification Authority of India
Government of India

ਦਾਖਿਲੇ ਦੇ ਪਛਾਣ / Enrollment No. : 1052/70302/00557

To
Neetu Thapar
 ਸੰਤੋਖ ਥਾਪਰ
 W/O Deepak Thapar
 PUR HIRAN
 Hoshiarpur
 Punjab - 146001

04/09/2011



UF363527264IN
 36352726



ਤੁਹਾਡਾ ਆਧਾਰ ਨੰਬਰ / Your Aadhaar No. :

4729 3706 1042

ਆਧਾਰ - ਆਮ ਆਦਮੀ ਦਾ ਅਧਿਕਾਰ



ਭਾਰਤ ਸਰਕਾਰ

ਨੀਤੂ ਥਾਪਰ
Neetu Thapar

ਜਨਮ ਦਾ ਸਾਲ / Year of Birth: 1964
 ਲਿੰਗ / Gender: Female

4729 3706 1042



ਆਧਾਰ - ਆਮ ਆਦਮੀ ਦਾ ਅਧਿਕਾਰ

Neetu

Kapil Gupta
DR. KAPIL GUPTA
 MD
 MEDICAL SPECIALIST
 KAPIL HOSPITAL
 NEAR NEW COURTS, JALANDHAR CITY
 PMC-35401



KAPIL HOSPITAL



Phone : 0181-2230822, 2235822
 Telefax : 0181-2230822 (R)2456833
 e-mail : guptakapil.12@gmail.com
 Website: www.kapilhospital.com

Multispeciality, Comprehensive & Intensive Care Centre
 A Centre approved for Cashless Hospitalization by all Insurance Companies/TPAs/GIPSA
 Civil Lines, Rajinder Nagar, opp. Commissioner's Office, Jalandhar City.(PB.)-144 001

NABH ACCREDITED HOSPITAL

Page No.1

NAME	NEETU THAPER	DATE	07/02/2022
HUSBAND NAME	DEEPAK THAPER.		
AGE	59/Yrs	HOSPITAL ID	49/22
SEX	Female		
MARITAL STATUS	Married	EXAMINED BY	Dr. KAPIL GUPTA

PERSONAL HISTORY

HISTORY OF PRESENTING ILLNESS :	Nothing Significant
PAST HISTORY	Post hysterectomy case

DIET	Non-Vegetarian	BOWELS	Normal
APPETITE	Good	MICTURITION	Normal
SLEEP	Normal	HABITS	SMOKING: Nil
ALLERGY	Nil		ALCOHOL: Nil

PHYSICAL EXAMINATION

HEIGHT	155 cm	VISION	Use spectacle for near & distance vision B/E
WEIGHT	76 Kg	Chest:100/106cm	
BP	160/90 mmhg	Abdomen:102cm	COULOUR VISION - Normal
PULSE	76/mnt	Dental check up	Normal
RESP. RATE	18/mnt		
TEMP	98.0° F		
SKIN	Normal		

Kapil

Dr. KAPIL GUPTA
 MD
 MEDICAL SPECIALIST
 KAPIL HOSPITAL
 NEAR NEW COURTS, JALANDHAR CITY
 PMC-35401



KAPIL HOSPITAL

Multispeciality, Comprehensive & Intensive Care Centre
A Centre approved for Cashless Hospitalization by all Insurance Companies/TPAs/GIPSA
Civil Lines, Rajinder Nagar, opp. Commissioner's Office, Jalandhar City.(PB.)-144 001



Phone : 0181-2230822, 2235822
Telefax : 0181-2230822 (R)2456833
e-mail : guptakapil.12@gmail.com
Website: www.kapilhospital.com

NABH ACCREDITED HOSPITAL

Page No.2

	JVP	Normal
	APEX BEAT	5 th ICS mid clavicular line
CVS	THRILLS	Absent
	HEART SOUNDS	Normal
	MURMURS	Absent

	TRACHEAL POSITION	Central
	SHAPE OF CHEST	Normal
RS	MOVEMENTS	Equal Bilateral
	BREATH SOUNDS	Vesicular
	ADVENTITIOUS SOUNDS	Absent


	TENDERNESS	Nil
	LIVER	Normal
ABDOMEN	SPLEEN	Not Palpable
	KIDNEY	Normal
	FREE FLUID	Absent
	BOWEL SOUND	Normal
	HERNIAL ORIFICES	Normal

	HIGHER MENTAL FUNCTION	Normal
	CRANIAL NERVES	Normal
CNS	SENSORY SYSTEMS	Normal
	MOTER SYSTEMS	No Abnormality
	REFLEXES	Normal

MUSCULOSKELETAL SYSTEM	Normal
------------------------	--------

IMPRESSION: - CLINICALLY AND INVESTIGATION WISE FIT.

Adv: Control B.P


DOCTOR SIGNATURE & SEAL :

DR KAPIL GUPTA

MD
Dr. KAPIL GUPTA
MD
MEDICAL SPECIALIST
KAPIL HOSPITAL
NEAR NEW COURTS, JALANDHAR CITY
PMC-35401

1
58 Years
Neetu Thaper
Female

07/02/2022 09:51:06
KAPIL HOSPITAL JALANDHAR

Rate 76

PR 132
QRSD 81
QT 363
QTc 409

--AXIS--
P 41
QRS 33
T 29

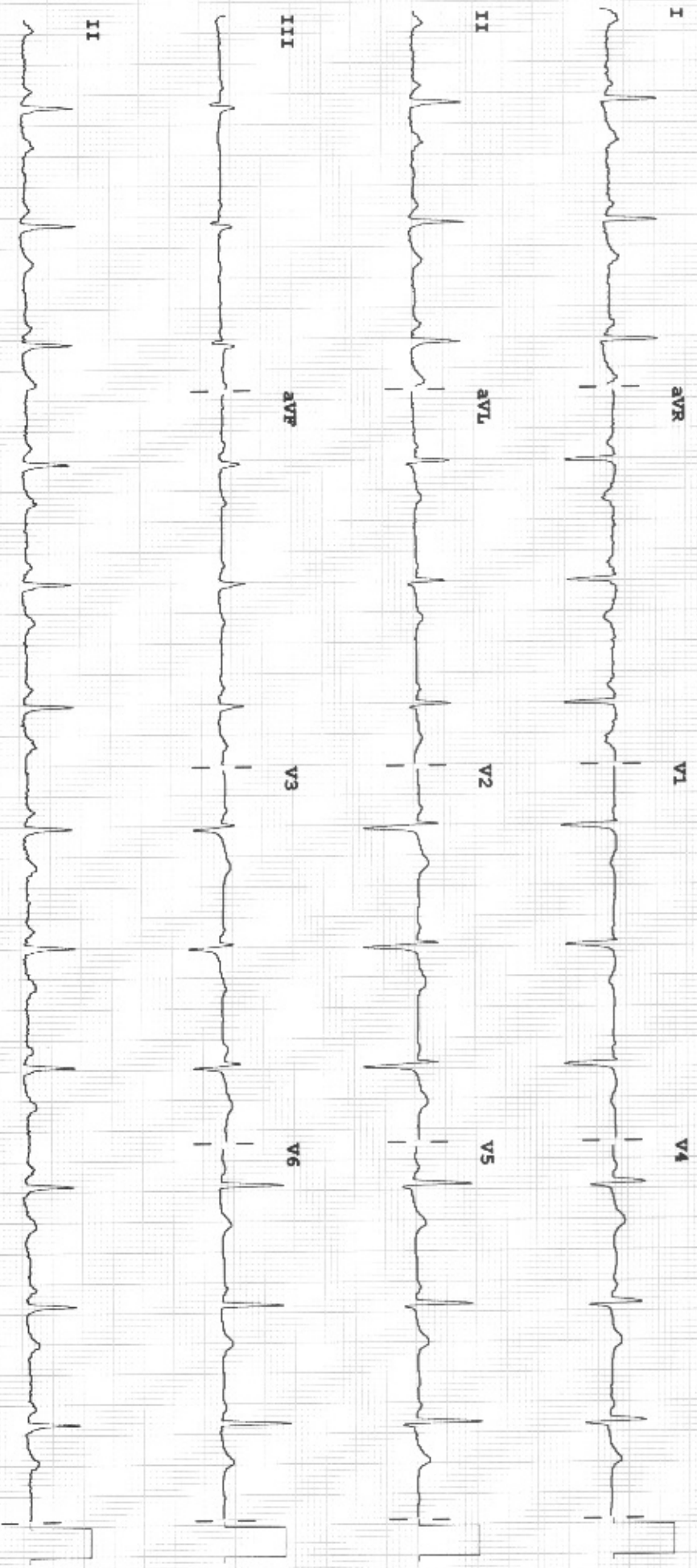
12 Lead; Standard Placement

OPINION

mitral opened level

lyps

DR. KAPIL GUPTA
MD
MEDICAL SPECIALIST
KAPIL HOSPITAL
NEAR NEW COURTS, JALANDHAR CITY
PINC-151401



Device:

Speed: 25 mm/sec

Lead: 10 mm/mV

Chest: 10.0 mm/mV

F 60 - 0.50 - 40 Hz W

PH10

CL

P?

Neetu



KAPIL HOSPITAL

Multispeciality, Comprehensive & Intensive Care Centre
A Centre approved for Cashless Hospitalization by all Insurance Companies/TPAs/GIPSA
Civil Lines, Rajinder Nagar, opp. Commissioner's Office, Jalandhar City.(PB.)-144 001

NABH ACCREDITED HOSPITAL



Phone : 0181-2230822, 2235822
Telefax : 0181-2230822 (R)2456833
e-mail : guptakapil.12@gmail.com
Website: www.kapilhospital.com

ECHOCARDIOGRAPHY

Patient Name: Mrs Neetu Thaper	Age/Sex: 59yrs/Male
UHID: 2204/21-22	Medical
Date: 07/02/2022	Dr. Deebanshu Gupta DM (Cardiologist)

M mode:- (Measure in MM)

LVID (ed)	39 (36-52mm)	EDV	
LVID(ES)	26 (23-39mm)	ESV	
IVS (ed)	09 (06-12mm)	LVEF%	62% (62%-85%)
LV PW (ed)	11 (06-12mm)	FS%	(28%-42%)
RVID (ed)	20 (11-25mm)		
LA	28 (21-37mm)		
Aorta	26(21-37mm)		

2-D Dimensions:

- **Left Ventricle:** Normal in size. The wall dose not show hypertrophy. No RWM abnormality, No LV clot seen
- **Right ventricle:** Normal
- **Left Atrium:** Normal

D1	D2	Area

- **Right Atrium:** Normal in size and function.

D1	D2	Area

Valves:

- **Mitral Valve:** Normal

E	0.8m/s	e' Septal		MAPSE		Mitral Regurgitation
A	0.7m/s	e' lateral		MVA		Nil

Dr. KAPIL GUPTA
MD
MEDICAL SPECIALIST
KAPIL HOSPITAL
NEAR NEW COURTS, JALANDHAR CITY
PMC-35401



KAPIL HOSPITAL

Phone : 0181-2230822, 2235822
 Telefax : 0181-2230822 (R)2456833
 e-mail : guptakapil.12@gmail.com
 Website: www.kapilhospital.com

Multispeciality, Comprehensive & Intensive Care Centre
 A Centre approved for Cashless Hospitalization by all Insurance Companies/TPAs/GIPSA
 Civil Lines, Rajinder Nagar, opp. Commissioner's Office, Jalandhar City.(PB.)-144 001



NABH ACCREDITED HOSPITAL

➤ **Tricuspid Valve: Normal**

<i>E</i>	<i>Max Vel</i>		<i>RVSP</i>	24	
<i>A</i>	<i>Annulus</i>		<i>Tricuspid Regurgitation</i>	Nil	

➤ **Aortic Valve: Normal**

<i>Vp</i>	<i>1.2m/sec</i>	<i>MG</i>		<i>AVA</i>	
<i>PG</i>		<i>Annulus</i>		<i>Aortic Regurgitation</i>	Nil

➤ **Pulmonary Valve: Normal**

<i>Vp</i>	<i>1m/sec</i>	<i>MG</i>	<i>Pulmonary Regurgitation</i>	Nil
<i>PG</i>		<i>Annulus</i>		

- IAS: Intact
- IVS: Intact
- PA: Normal
- Pericardium: No pericardial effusion

Final Impression:

- No structural heart disease
- Normal LV size
- No RWM abnormality
- Normal LV systolic function (LVEF=62%)
- Normal LV Diastolic function
- No Pericardial effusion
- No clots, vegetations seen.

Dr. Deebanshu Gupta
 MD/DM
 (Cardiologist)

DR. KAPIL GUPTA
 MD
 MEDICAL SPECIALIST
 KAPIL HOSPITAL
 NEAR NEW COURTS, JALANDHAR CITY
 PMC-35401



KAPIL HOSPITAL

Multispeciality, Comprehensive & Intensive Care Centre
A Centre approved for Cashless Hospitalization by all Insurance Companies/TPAs/GIPSA
Civil Lines, Rajinder Nagar, opp. Commissioner's Office, Jalandhar City.(PB.)-144 001

NABH ACCREDITED HOSPITAL



Phone : 0181-2230822, 2235822
Telefax : 0181-2230822 (R)2456833
e-mail : guptakapil.12@gmail.com
Website: www.kapilhospital.com

Client Name: Mrs. Neetu Thaper	Age/Sex: 59Yrs/Female
Date: 07/02/2022	Incharge: Dr. Kapil Gupta MD
Package Code: PKG10000247	

X-RAY CHEST REPORT

REPORT:

- Trachea is centrally placed.
- Heart size is normal along with all normal.
- Both costo – phrenic and cardio – phrenic angles are clear.
- Both lungs clear and no parenchymal destruction or lesion seen.
- No any Retro – sternal or mediastinal soft tissue abnormality seen.
- Both domes of diaphragms are normal with well delineated cupulae and margins.
- Normal sub – diaphragmatic stomach shadow noticed.
- Broncho – vascular shadows are normal both side.
- Hilar region both side normal.

OPINION/IMPRESSION:-

No cardiopulmonary lesion seen.


Dr KAPIL GUPTA MD
 Medical & Heart Specialist

Dr. KAPIL GUPTA
 MD
 MEDICAL SPECIALIST
 KAPIL HOSPITAL
 NEAR NEW COURTS, JALANDHAR CITY
 PMC-35403



KAPIL HOSPITAL

Phone : 0181-2230822, 2235822
Telefax : 0181-2230822 (R)2456833
e-mail : guptakapil.12@gmail.com
Website: www.kapilhospital.com

Multispeciality, Comprehensive & Intensive Care Centre
A Centre approved for Cashless Hospitalization by all Insurance Companies/TPAs/GIPSA
Civil Lines, Rajinder Nagar, opp. Commissioner's Office, Jalandhar City.(PB.)-144 001



NABH ACCREDITED HOSPITAL

ULTRA SONOGRAPHY REPORT

Patient Name: Mrs. Neetu Thaper	Age/Sex: 59Yrs/Female
Part Scanned: ABDOMEN	Sonography Window :- Good/Bad/Reasonable
Non-fasting	Date: 07/02/2022

Liver: is normal in size to 11.0.cm, shape, outline and show echogenicity. No sol. is seen. I.H.B.R. are normal. Portal vein is 10.6.No pathology seen in Porta.

Gall Bladder is normal in size. Walls are normal. No calculus/sol. seen.
The cleavage line between the liver and gall bladder is maintained. To be repeated on fasting

Common Bile Duct: is normal in calibre. No obstruction /mass/calculus could be seen up to the length scanned.

Pancreas: is normal in size, shape, outline and echopattern. PD is normal. No sol. seen. Peripancreatic region is normal.

Spleen: is normal in size and echopattern. No sol. seen. Splenic vein is normal in size. No collaterals could be seen.

Kidneys: Both kidneys are normal in size, shape, outline and parenchymal echopattern. Cortico medullary distinction is well maintained bilaterally. Central echoes are compact. No calculi/hydronephrosis seen in both kidneys. Peri renal area is normal Rt kidney 9.7x 3.6cm, Lt kidney 10.8 x 5.0cm.

Ureters: seem to be normal upto the parts scanned. However There is echogenic focus at medial end of vesico uretic junction

Uterus: Post Hysterectomy case

Urinary Bladder: is normal. No calculus/mass is seen. UB wall is normal. vesicles are Psoas muscles seem to be normal.

Bowel loops: Right iliac region seem to be grossly normal. No sol. seen. No free fluid/gross lymphadenopathy noted.

Pleural: spaces are normal.

Impression: Post Hysterectomy case Rest Us Scan Study Normal

Date: 07/02/2022


Dr Kapil Gupta
MD

DR. KAPIL GUPTA
MD
MEDICAL SPECIALIST
KAPIL HOSPITAL
NEAR NEW COURTS, JALANDHAR CITY
PMC-35401



K.S. Clinical Lab.

Inside Kapil Hospital

NABH ACCREDITED HOSPITAL

A CENTRE APPROVED FOR CASHLESS HOSPITALIZATION
NEAR NEW COURTS, JALANDHAR CITY.

(Authorised Collection Centre for Dr. Lal Path Lab., Reliance, Metropolis etc.)



Phone : 0181-2230822, 2235822
Telefax : 0181-2230822 (R) 2456833
e-mail : guptakapil.12@gmail.com
Website : www.kapilhospital.in

Client Name:-Mrs.Neetu Rani Thaper	Age/Sex: 58Yrs/Female
Date: 07/02/2022	Incharge: Dr N K Sardana MD(Path)
Package Code :-PKG10000247	

Liver Function Test	Patients Value	Normal Range
S.Bilirubin (Total)	0.9mg/dl	0.2-1.0 mg/dl
S.Bilirubin (Direct)	0.4 mg/dl	0.2-0.4 mg/dl
S.Bilirubin (Indirect)	0.5 mg/dl	0.2-0.6 mg/dl
S.G.O.T	21.0 Units/ml	5-35 Units/ml
S.G.P.T	30.0 Units/ml	7-40 Units/ml
S.G.G.T.P	38.0 IU/L	17-70 IU/L
S.Alkaline phosphatase	103.0 U/L	43-240 U/L
S.Total Proteins	6.3 gm/dl	6.0-8.0 gm/dl
S.Albumin	3.8gm/dl	3.8-5.0 gm/dl
S.Globulin	2.5gm/dl	2.3-3.5 gm/dl

Urine Analysis	
Color	Pale Yellow
Sugar	Nil
Sugar(PP)	Nil
Albumin	Nil
Ketones	Nil
Bilirubin	Nil
Urobilinogen	Normal
Leucocyte esterase	Negative
Microscopic Examination/HPF	
Leucocytes/Pus Cells	4-6
R.B.Cs.	Nil
Casts	Nil
Epithelial Cells	Nil
Significant Crystals	Nil
Specific Gravity	1.020
PH	5.5

DR. KAPIL GUPTA
MD
MEDICAL SPECIALIST
KAPIL HOSPITAL
NEAR NEW COURTS, JALANDHAR CITY
PMC-35401

Dr. N. K. Sardana

M.D. (Pathology)
Consultant Pathologist (Visiting)

Lab Technician



K.S. Clinical Lab.

Inside Kapil Hospital

NABH ACCREDITED HOSPITAL

A CENTRE APPROVED FOR CASHLESS HOSPITALIZATION
NEAR NEW COURTS, JALANDHAR CITY.

(Authorised Collection Centre for Dr. Lal Path Lab., Reliance, Metropolis etc.)



Phone : 0181-2230822, 2235822
Telefax : 0181-2230822 (R) 2456833
e-mail : guptakapil.12@gmail.com
Website : www.kapilhospital.in

Client Name:-Mrs.Neetu Rani Thaper	Age/Sex: 58Yrs/Female
Date: 07/02/2022	Incharge: Dr N K Sardana MD(Path)
Package Code :-PKG10000247	

INTERPRETATION:-

Fasting Blood Sugar: 94.0mg/dl (Normal value: 70-110.0 mg/dl)

Clients HbA1c: 5.4% (Normal value (4.0% - 6.0 %))

HBA1C	NORMAL RANGE	
	Non Diabetic	4.0% - 6.0%
	Good Control	6.1% - 8.0%
	Poor Control	8.1% - 9.0%
	Unsatisfactory	>9%

Note:-

- 1. A three monthly monitoring is recommended in diabetics.
- 2. Since HbA1c concentration represents the integrated values for blood glucose over the preceding 6-10 weeks and is not affected by daily glucose flocculation, exercise and recent food intake, it is a more useful tool for monitoring diabetics.

Clinical Use:-

- Clinical management of diabetes mellitus through routine monitoring.
- Assess compliance with therapeutic regimen.

Report Completed:-

Test Requested:

GLYCOSYLATED HEMOGLOBIN/HbA1c.


Lab Technician

Dr. N. K. Sardana
M.D. (Pathology)
Consultant Pathologist (Visiting)

*DR. KAPIL GUPTA
MD
MEDICAL SPECIALIST
KAPIL HOSPITAL
NEAR NEW COURTS, JALANDHAR-CITY
PMC-35491*



K.S. Clinical Lab.

Inside Kapil Hospital

NABH ACCREDITED HOSPITAL

A CENTRE APPROVED FOR CASHLESS HOSPITALIZATION
NEAR NEW COURTS, JALANDHAR CITY.

(Authorised Collection Centre for Dr. Lal Path Lab., Reliance, Metropolis etc.)



Phone : 0181-2230822, 2235822
Telefax : 0181-2230822 (R) 2456833
e-mail : guptakapil.12@gmail.com
Website : www.kapilhospital.in

<i>Client Name:-Mrs.Neetu Rani Thaper</i>	<i>Age/Sex: 58Yrs/Female</i>
<i>Date: 07/02/2022</i>	<i>Incharge: Dr N K Sardana MD(Path)</i>
<i>Package Code :-PKG10000247</i>	

Stool Examination	
Gross Examination	
Colour	Brownish
Blood	Absent
Mucous	Absent
Reaction	Acidic
Viscosity	Formed
Microscopic Examination	
Trophozoites	Absent
Ova/Egg	Absent
Pree Cyst	Absent
Cyst	Absent
Entamoeba Histolitica (E H Cyst)	Absent
PH	7.0
Occult Blood	Negative

Lab Technician

Dr. KAPIL GUPTA
MD
MEDICAL SPECIALIST
KAPIL HOSPITAL
NEAR NEW COURTS, JALANDHAR CITY
Dr. N. K. Sardana
M.D. (Pathology)
Consultant Pathologist (Visiting)



K.S. Clinical Lab.

Inside Kapil Hospital

NABH ACCREDITED HOSPITAL

A CENTRE APPROVED FOR CASHLESS HOSPITALIZATION

NEAR NEW COURTS, JALANDHAR CITY.

(Authorised Collection Centre for Dr. Lal Path Lab., Reliance, Metropolis etc.)



Phone : 0181-2230822, 2235822
Telefax : 0181-2230822 (R) 2456833
e-mail : guptakapil.12@gmail.com
Website : www.kapilhospital.in

Client Name:-Mrs.Neetu Rani Thaper	Age/Sex: 58Yrs/Female
Date: 07/02/2022	Incharge: Dr N K Sardana MD(Path)
Package Code :-PKG10000247	

THYROID FUNCTION TEST:

<u>Investigation</u>	<u>Observed Value</u>	<u>Unit</u>	<u>Biological ReferenceInterval</u>
Thyroid Panel-1			
T3 (Total)	84.64	ng/dl	70-204 First Trimester:81-190 Second Trimester:100-260 Third Trimesters:100-260
T4 (Total)	8.2	µg/dl	5.0-12.5
TSH (Ultrasensitive)	3.6	µlu/ML	0.45-4.5 First Trimester : 0.1-2.5 Second Trimester : 0.2-3.0 Third Trimester :0.3-3.0

References:1.Interpretaion of thyroid function tests.Dayan et al.
THELANCET.Vol357.Febuary24,2001.

2.Laboratory Evaluation of Thyroid function,India Thyroid Guidelines,
JAPI, January 2011,Vol.59

---END OF REPORT---

Dr. KAPIL GUPTA
MD
MEDICAL SPECIALIST
KAPIL HOSPITAL
NEAR NEW COURTS, JALANDHAR CITY
PMC 35401

Dr. N. K. Sardana

M.D. (Pathology)
Consultant Pathologist (Visiting)

Lab Technician



K.S. Clinical Lab.

Inside Kapil Hospital



Phone : 0181-2230822, 2235822
Telefax : 0181-2230822 (R) 2456833
e-mail : guptakapil.12@gmail.com
Website : www.kapilhospital.in

NABH ACCREDITED HOSPITAL

A CENTRE APPROVED FOR CASHLESS HOSPITALIZATION
NEAR NEW COURTS, JALANDHAR CITY.

(Authorised Collection Centre for Dr. Lal Path Lab., Reliance, Metropolis etc.)

<i>Client Name:-Mrs.Neetu Rani Thaper</i>	<i>Age/Sex: 58Yrs/Female</i>
<i>Date: 07/02/2022</i>	<i>Incharge: Dr N K Sardana MD(Path)</i>
<i>Package Code :-PKG10000247</i>	

PAP SMEAR{ Bethesda 2001 Guidelines/ scope}

Specimen Adequacy : Adequate
Endocervical Content : Present
Endometrial content: Absent
Relevant Description: Epithelial cells Have
Regular appearing nuclei. There is no Aniso- Nucleosis.
Bacterial Shift: Normal
Trichomonads/ Monilia: Absent

COMMENT: NEGATIVE FOR INTRAEPITHELIAL LESION OR MALIGNANCY.

Lab Technician

DR. KAPIL GUPTA
MD
MEDICAL SPECIALIST
KAPIL HOSPITAL
NEAR NEW COURTS, JALANDHAR CITY
Dr. N. K. Sardana
M.D. (Pathology)
Consultant Pathologist (Visiting)