

**Mumbai, Maharashtra, India**  
 Shop No. - 3, Akhil Bharti Bhavan, Belasis Road, Tardeo, Mumbai - 400034, Marzban Parsi Colony, Dalal Estate, Mumbai Central, Mumbai, Maharashtra 400008, India  
 Lat 18.968775°  
 Long 72.819982°  
 25/09/21 08:39 AM




Mediwhaet.

**3496 9133 3784**

Address: D6/41 OVELL HOUSE, K S H B COLONY, MEDICAL COLLEGE P O, Kozhikode (MCP), Kozhikode, Kerala - 673008

Unique Identification Authority of India



**DR. HARNICHHABLANI'**  
 M.D. (P) (PNEUMONIC) PGDIPHA, PGDMLS  
 FELLOW INTENSIVE CARE  
 MMC REG. NO. - 91702

**'DR. PLUS HEALTHCARE CENTRE'  
 NATHANI HEIGHTS', B-WING,  
 42, MUMBAI CENTRAL (EAST)**

W/E 2

**ഭാരത സർക്കാർ**  
**Government of India**



ക്ലിന്റ് എസ് ജെയിംസ്  
 Clint S James  
 ജനന തീയതി/DOB: 15/01/1994  
 പുരുഷൻ/ MALE



3496 9133 3784

എന്റെ ആധാർ, എന്റെ ഐഡൻറിറ്റി





# Dr-Plus Healthcare Centre

NATHANI HEIGHTS, B-Wing, Shop No. 42, Ground Floor, Opp. Mumbai Central Station (East), Mumbai - 400 008.

Patient's Name : CLINT JAMES

Report Date : 25/09/2021

Referred By Dr. : DR. HARI CHHABLANI

Age : 27 Years

Sex : MALE

## X- RAY CHEST PA

BOTH THE LUNG FIELDS ARE CLEAR .

THE HILAR SHADOWS APPEAR NORMAL.

THE COSTO -PHRENIC ANGLES ARE CLEAR.

THE CARDIAC SHADOWS APPEAR NORMAL.

THE TRACHIA IS CENTRAL IN POSITION.

THE BONY CAGE APPEARS NORMAL.

  
Radiologist

DR. A. J. MAZUMDAR

MD. DMRE, MDRD

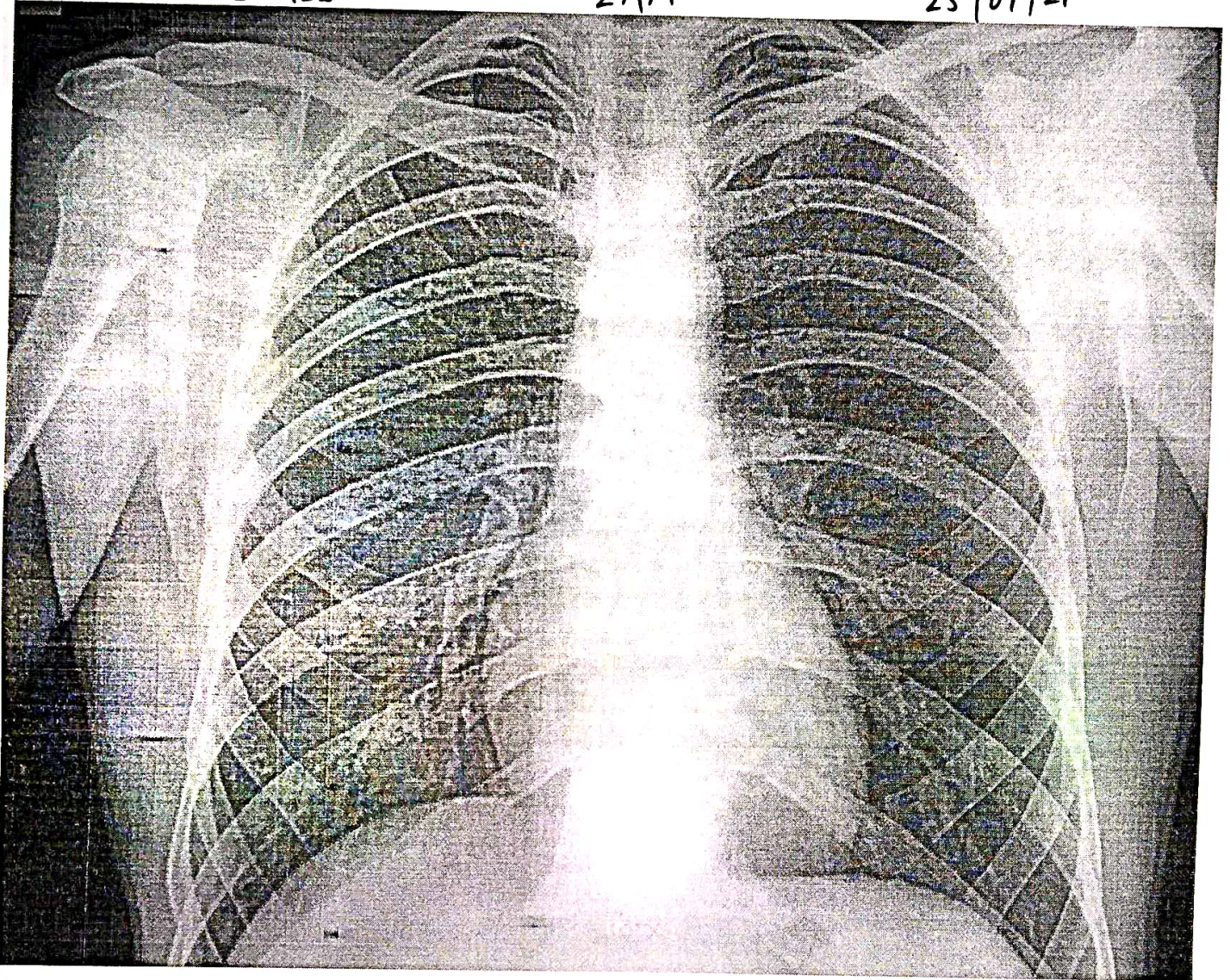
"DR. PLUS HEALTHCARE CENTRE"  
NATHANI HEIGHTS, B-WING,  
42, MUMBAI CENTRAL (EAST)



CLINT S JAMES

27/M

25/07/21



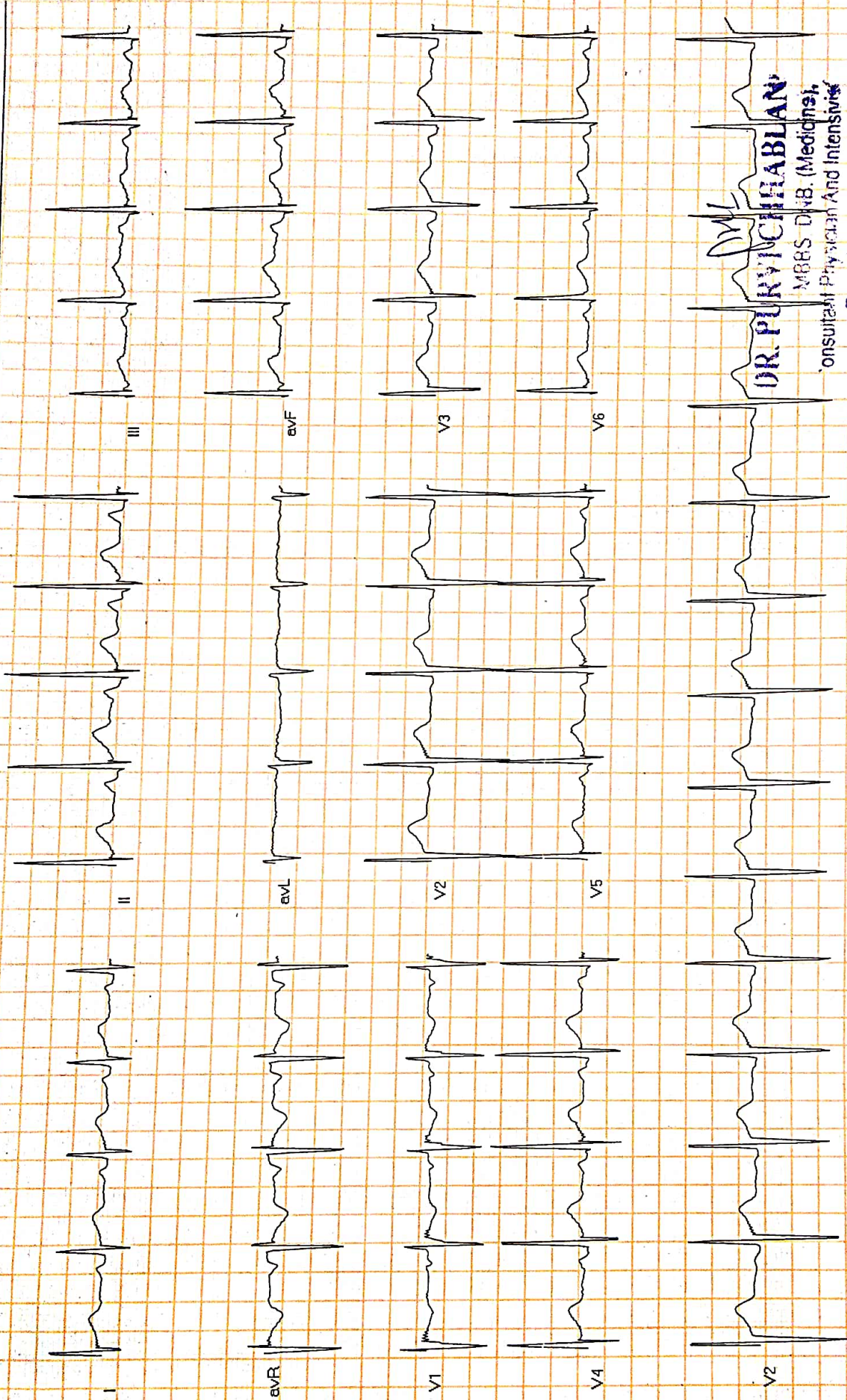


**DR PLUS HEALTHCARE CENTRE- MUMBAI CENTRAL**

1085 / CLINT JAMES / 27 Yrs / M

Heart Rate : 87 bpm / Tested On : 25-Sep-21 08:54:39 / HF 0.05 Hz - LF 1.00 Hz / Notch 50 Hz / Sn 1.00 Cm/mV / Sw 25 mm/s

**ECG**



**DR. PURVI CHHABLANI**

M.B.S. D.M.B. (Medicine),  
Consultant Physician And Intensivist

Reg No 7769F

Reported By: DR. PURVI CHHABLANI

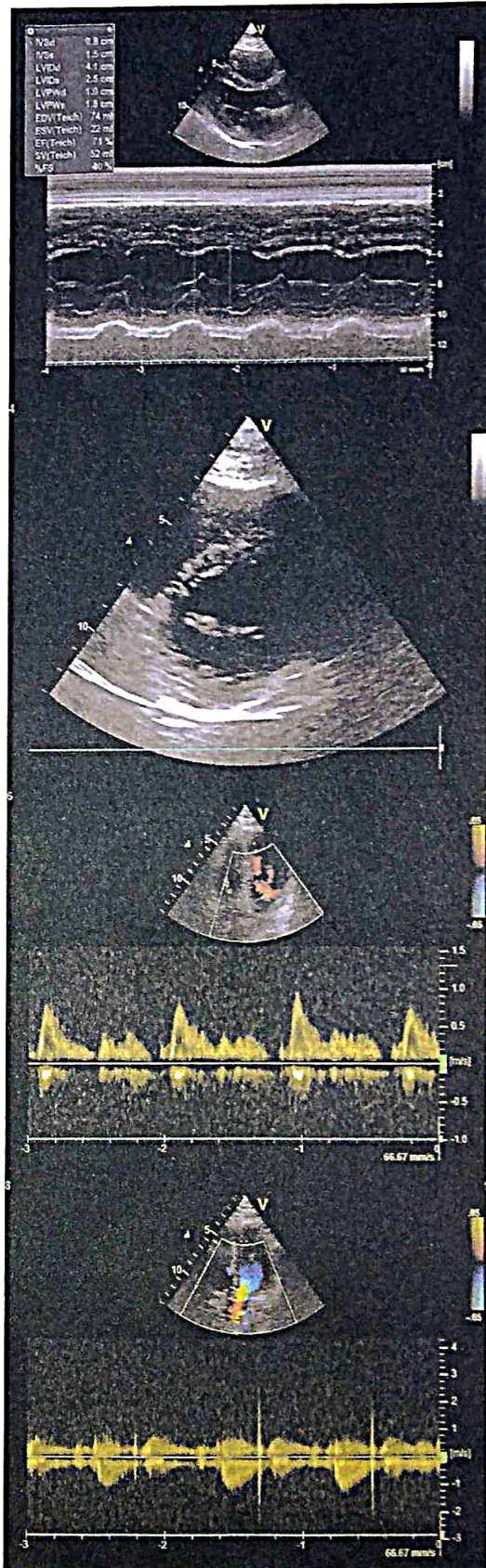
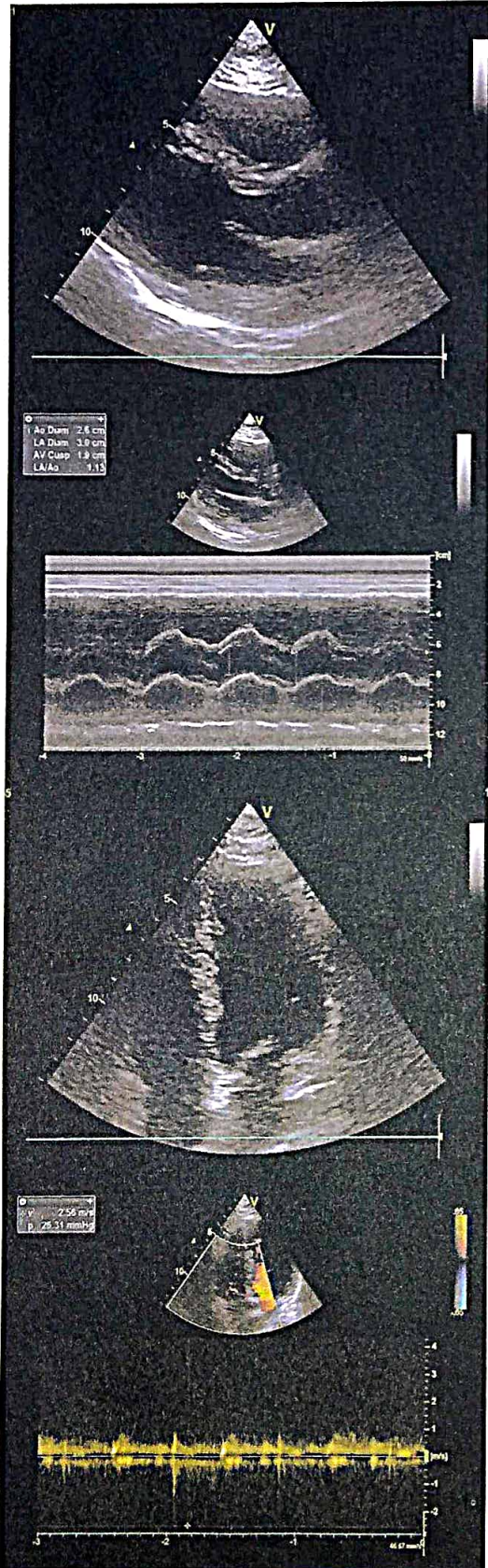


Name **CLINT JAMES**

Sex **Male**

Age **27**

Date **25/09/2021**







NAME : CLINT JAMES

27/M

DATE:25/09/2021

REF BY : DR. PURVI CHHABLANI

## 2D-ECHO.AND COLOR DOPPLER REPORT

- NORMAL CARDIAC VALVES WITH TRIVIAL TR.
- NORMAL CARDIAC CHAMBERS
- NO E/O REGIONAL WALL MOTION ABNORMALITY. WITH NORMAL LVEF OF 65%.
- NO E/O PULMONARY HYPERTENSION. PASP 32 mmHg by TR jet.
- NO E/O LEFT VENTRICULAR HYPERTROPHY.
- NO E/O DIASTOLIC DYSFUNCTION.
- NO E/O PERICARDIAL EFFUSION.
- NO E/O INTRACARDIAC CLOT OR VEGETATIONS.
- INTACT IAS/IVS
- CONVENTIONL DOPPLER :

E TO A RATIO IS MORE THAN ONE IN LV INFLOW.


THERE IS NO GRADIENT ACROSS AV,LVOT OR RVOT

PASP FROM TR JET IS .32 mm OF Hg.

- COLOUR DOPPLER:

TRIVIAL TR

EF Slope	113	mm/sec		
Opening Amplitude	19			
Posterior leaflet				
E.P.S.S	02	mm		
Mitral valve prolapse				
Vegetations				
<b>TRICUSPID VALVE</b>	<b>OBSERVED</b>	<b>NORMAL VALUES</b>		
<b>PULMONARY VALVE</b>	<b>OBSERVED</b>	<b>NORMAL VALUES</b>		
EF Slope				
'A' Wave				
Midsystolic notch				
Flutter				
Other Findings				
<b>AORTIC VALVE</b>	<b>OBSERVED</b>	<b>NORMAL VALUES</b>		
Cuspal opening	16	mm		
Closure line	Central			
Eccentricity index	1			
Other Findings				
<b>DIMENSIONS</b>	<b>OBSERVED</b>	<b>NORMAL VALUES</b>		
1. Lvd (Diastolic)	41	26-52		
2. Lvd (Systolic )	28	24-42mm		
3. RVD (Diastolic)	16	7-23mm		
4. IVST (Diastolic)	08	6-11mm		
5. IVST (Systolic )	15			
6. LVPWT (Diastolic)	09	6-11mm		
7. LVPWT (Systolic )	16			
8. Aortic root	26	22-37mm		
9. left Atrium	30	19-40mm		
	<b>STRUCTURE</b>	<b>REGURG GRADING</b>	<b>VELOCITY</b> m/sec	<b>STENOSIS GRADIENT</b> mm/Hg
			Max mean	Peak mean
<b>MITRAL VALVE</b>	NORMAL	0/3	/	/
<b>TRICUSPID VALVE</b>	NORMAL	TRIVIAL	/	/
<b>PULMONARY VALVE</b>	NORMAL	0/4	/	/
<b>AORTIC VALVE</b>	NORMAL	0/4	/	/

  
**DR. P.H. CHHABLANI**  
 M.B.B.S, DNB. (MEDICINE)  
 CONSULTANT PHYSICIAN AND CARDIOLOGIST.

**DR. PURVI CHHABLANI**  
 MBBS, DNB. (Medicine)  
 Consultant Physician And Intensivist  
 Reg No 77696





# Dr-Plus Healthcare Centre

NATHANI HEIGHTS, B-Wing, Shop No. 42, Ground Floor, Opp. Mumbai Central Station (East), Mumbai - 400 008.

<b>Patient Name</b> :	CLINT JAMES	<b>Sex:</b>	MALE
<b>Doctor's Name</b> :	DR. H. CHHABLANI	<b>Age:</b>	27 YEARS
<b>Date</b> :	25/09/2021		

## ULTRASONOGRAPHY OF THE ABDOMEN AND THE PELVIS:

The relevant sonographic findings include the following:

### HEPATOBIILIARY APPARATUS

The liver is normal in size and echogenicity. No obvious focal parenchymal lesion is seen. Extrahepatic biliary radicals are not dilated. The portal vein and the common bile duct are normal.

### GALL BLADDER

The gall bladder is adequately distended. The wall thickness is normal. No echogenic contents are noted in its lumen. There is no pericholecystic collection noted.

### PANCREAS

The pancreas shows normal echogenicity and size. No focal or diffuse lesions are noted. No evidence of calcification is noted.

### SPLEEN

The spleen appears normal in size and echogenicity. No focal or diffuse lesions are noted. No evidence of calcification is noted.

### KIDNEYS

Right Kidney measure: 10.0 x 4.5 cm, Left kidney measure: 10.1 x 4.3 cm  
Both the kidneys appear normal in size, shape and echogenicity. Both the pelvicalyceal system is normal and both corticomedullary differentiations are well maintained. There is no obvious focal or diffuse lesion noted. No evidence of any calculus seen in either kidney.


### PROSTATE

The Prostate appears normal and shows a normal echogenicity.

### URINARY BLADDER

The urinary bladder shows anechoic contents. Its wall thickness appears normal. No evidence of calcification is seen. There is no obvious evidence of abdominal or pelvic lymphadenopathy or ascites noted.

**IMPRESSION: No significant abnormality is detected.**

  
Dr. Parag Jhaveri  
MBBS (BOM), DMRE (BOM)  
Radio-Sonologist

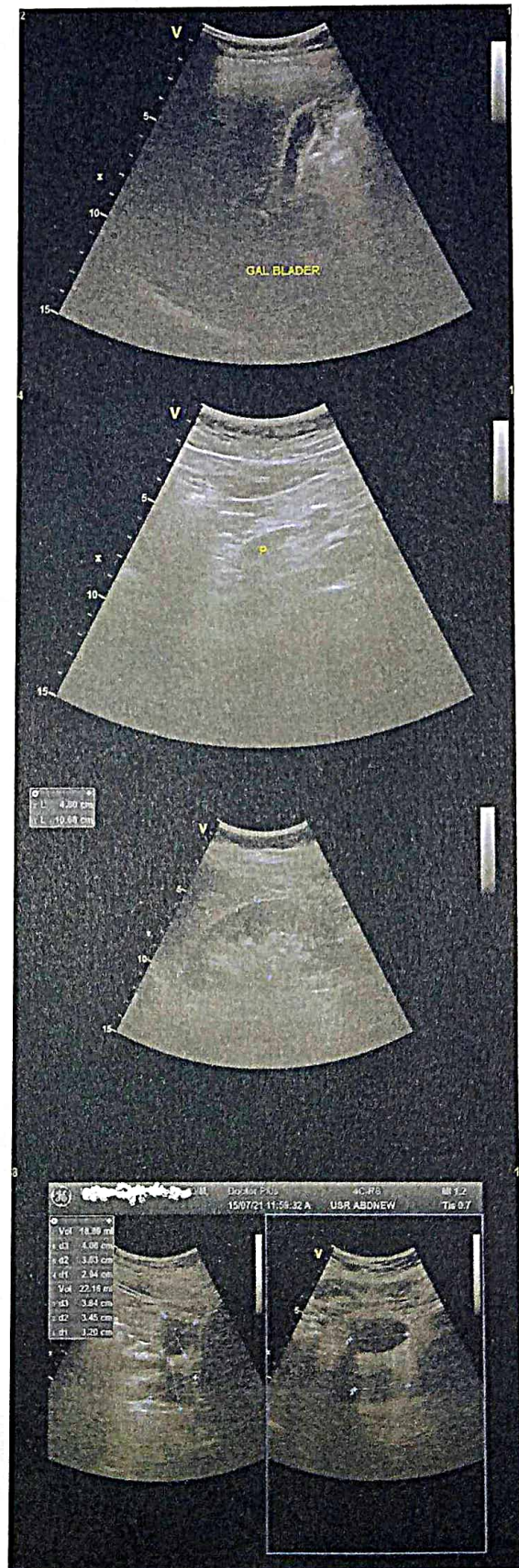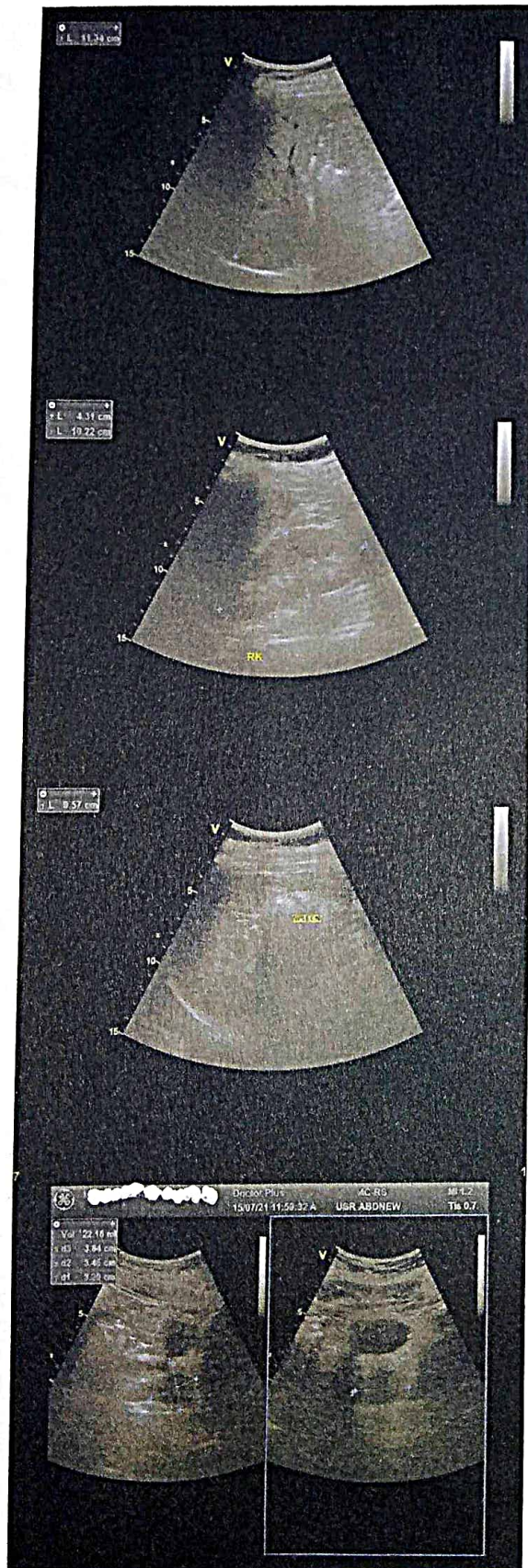DR. PLUS HEALTHCARE CENTRE  
NATHANI HEIGHTS, B-WING,  
42, MUMBAI CENTRAL (EAST)



Name **CLINT JAMES**

Sex **Male**

Age **27**







# Dr-Plus Healthcare Centre

NATHANI HEIGHTS, B-Wing, Shop No. 42, Ground Floor, Opp. Mumbai Central Station (East), Mumbai - 400 008.

Full Name

CLINT JAMESH

27/M

DATE:25/09/202

	Type of Test	Actual Reading	Normal Range
1	Fasting Blood Sugar	89	70-100 mg%
2	PPBS	122	110 TO 140 mg%
3	Total Cholesterol	173	120-200 mg%
4	VERY LOW DENSINTY LEVEL(VLDL)	21	10-30 mg/dl
5	High Density Lipid (HDL)	50	40-60 mg%
6	Low Density Lipid (LDL)	102	Upto 150
7	S. Triglycerides	115	50-150 mg%
8	CHOL/HDL	3.4	Upto 5
9	HDL/LDL	0.4	
10	S. Creatinine	1.1	0.5-1.2 mg%
11	Blood Urea Nitrogen (BUN)	18	7-21 mg%
12	BUN/CREAT RATIO	16.3	
13	S. Proteins	6.8	6.0-7.9 mg%
14	(a) Albumin	3.5	3.5-5.5 mg%
15	(b) Globulin	3.3	2.0-3.5 mg%
16	A/G RATIO	1.06	
17	S. Bilirubin	0.9	0.3-1.3mg%
18	(a) Direct	0.5	0.0-0.8 mg%
19	(b) Indirect	0.4	0.0-0.5 mg%
20	SGOT (AST)	22	05-34 IU
21	SGPT (ALT)	35	05-40 IU
22	GGTP (GGT)	43	05-50 IU
23	SGOT/SGPT	0.6	
24	HBA1C	5.6	UPTO 6.5
25	S. Alkaline Phosphatase	82	30-115 IU
26	T3	135	80-180ng/dl
27	T4	7.2	4.6-12 ug/dl
28	TSH	3.1	0.4-4.0 mIU/L
29	SERUM URIC ACID	5.9	2.5-7.2mg/dl
30	URINE SUGAR PP	ABSENT	
31	URINE SUGAR FASTING	ABSENT	
32	BLOOD GROUP	"AB" POSITIVE"	

DR. JAMESH PATKAR  
M.D., D.N.B. (Pathology)  
Reg. No. 2013/05/1660





# Dr-Plus Healthcare Centre

NATHANI HEIGHTS, B-Wing, Shop No. 42, Ground Floor, Opp. Mumbai Central Station (East), Mumbai - 400 008.

Full Name of life to be assured:

CLINT JAMES

27/M DATE:25/09/2021

## HAEMOGRAM

		Normal Range	
1.	Red Blood Cell Count	4.5	[M : 4.5 - 5.6 / F : 3.5 - 5.5/cu.mm]
2.	Hb%	15.3	[M: 14-18 / F : 11-16%]
3.	Hematocrit	45	[M : 40-53 / F : 30-47 %]
4.	Indices:		
(a)	MCV(Mean Corpuscular Volume)	90	[79-101 cu.mi.]
(b)	MCH(Mean Corpuscular Hb)	31	[27-32 pg]
(c)	MCHC(Mean Corpuscular Hb Concentration)	32	[32-38%]
5.	Morphology	-	
	Macrocytes :	--	Microcytes: -- Hypochromia: --
	Poikilocytosis:	--	Anisocytosis: --
6.	Target cells:	--	
	Spherocytes:	--	Elliptocytes: --
7.	TOTAL W.B.C.Count	7.000	[4000-11000/cu.mm]
Differential Count 0			
a)	Neutrophils :	55	[45 - 70%] c) Eosinophils: 04 [01 - 06%]
b)	Lymphocytes :	32	[20 - 45%] d) Monocytes: 05 [00 - 08%]
e)	Basophils :	01	[00 - 01%]
8.	Platelets : 2.89	1.5-4.5 Lacks/cu.mm	
9.	Erythrocyte Sedimentation Rate:10	20 mm at end of 1 hour	Method : Westergrens

## ROUTINE URINE EXAMINATION (RUA)

### 1. Physical Examination:

(i)	Colour:	PLAN YELLOW	(ii)	Sediment:	CLEAR
(iii)	Transparency:	ABSENT	(iv)	Reaction:	ACIDIC
(v)	Specific gravity	1.005			

### 2. Chemical Examination:

(i)	Protein :	ABSENT	(ii)	Sugar:	ABSENT
(iii)	Bile salt:	ABSENT	(iv)	Bile pigment:	ABSENT

### 3. Microscopic Examination:

(i)	Red Blood Cells:	ABSENT	(ii)	Epithelial Cells:	ABSENT
(iii)	Crystals:	ABSENT	(iv)	Pus Cells:	02 TO 03/HPF
(v)	Casts:	ABSENT	(vi)	Deposits:	ABSENT
(vii)	Bacteria's :	ABSENT			

DR. R. S. PATKAR  
M.D. (Pathology)  
Reg. No. 2013/05/1660





**Dr. Hari Chhablani**

Cardiometabolic Physician & Intensivist  
M.B.B.S., F.C.C.P. (RESP. MED.), PGDHHM,  
PGDMLS, FELLOW INTENSIVE CARE MED.

ATTACHED TO: Wockhardt Hospital • Saifee Hospital • Apollo Spectra Hospital

NATHANI HEIGHTS, B-Wing, Shop No. 42, Ground Floor, Opp. Mumbai Central Station (East),  
Mumbai - 400 008. • Cell : 98206 46163 • E : drharichhablani@gmail.com

## PHYSICIAN REPORT

25/09/2021

NAME : CLINT JAMES\*

AGE/SEX: 27/M

PRESENTING COMPLAINS: NIL

PAST HISTORY: NIL

TREATMENT HISTORY : NIL

FAMILY HISTORY: NOT SIGNIFICANT

ADDICTION: NIL

P: 88/MIN

BP: 120/70

RS: CLEAR

CVS: S1,S2 REGULAR

PA: SOFT

CNS: CLINICALLY NAD

ECG: WNL

CXR: WNL

LABS: ATTACHED

EYE EXAMINATION B/E : NEAR VISION - BL N6 DISTANT VISION - 6/6 COLOUR VISION - NORMAL

IMPRESSION : FIT ON CLINICAL MEDICAL EXAMINATION .

DR. HARI CHHABLANI

**DR. HARI CHHABLANI**  
M.B.B.S., F.C.C.P. (RESP. MED.), PGDHHM, PGDMLS  
FELLOW INTENSIVE CARE  
M.M.C. REG. NO. - 91702