

R

ANKITA GUPTA 33 Y/F PT154607 CHEST.PA 26/Mar/2022 11:10 AM  
RADIX HEALTH CARE, C-218 NIRMAN VIHAR, PH. 22011196



# MALIK RADIX HEALTH CARE

(UNIT OF MALIK RADIX HEALTHCARE PVT. LTD)

C-217, 218, Nirman Vihar, Vikas Marg, New Delhi - 110092

Tel.: 011-22011192, 22011196, 47060150 • Fax.: 22011208

E-mail : radixhealthcare@yahoo.co.in

Website : www.radixhealthcare.org



Safety at WEI now accredited by NABH

UHID	PT154607	LAB No.	XRY2111101
Name	Mrs. ANKITA GUPTA	Regn. No.	GEN2159080
Age / Sex	33 Yrs / F	Receiving Dt/Time	26/Mar/2022 11:10
		Reporting Dt/Time	26/Mar/2022 11:24 AM

## XRAY

CHEST (PA)

Both lung fields are normal.

Cp angles are clear.

Hila are normal...

Heart size appears within normal limits.

Soft tissue shadows and bony thorax are normal.

IMP- NORMAL CHEST X-RAY

Advised....please correlate clinically.

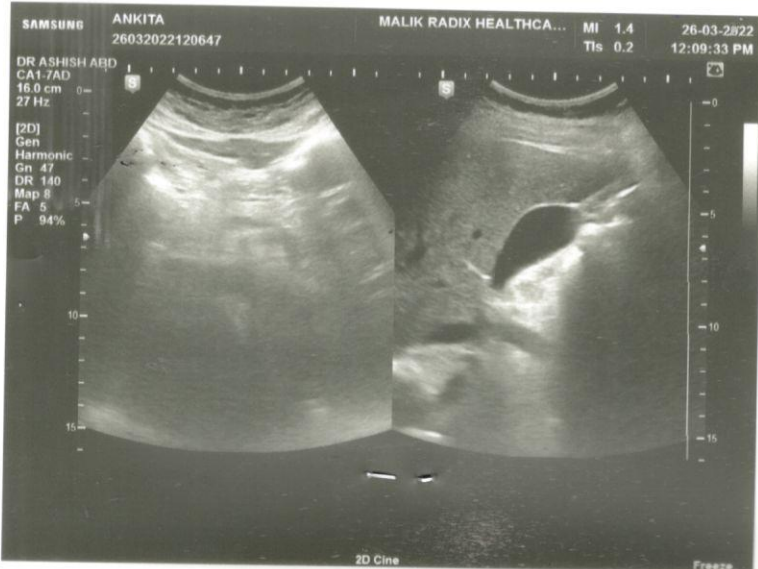
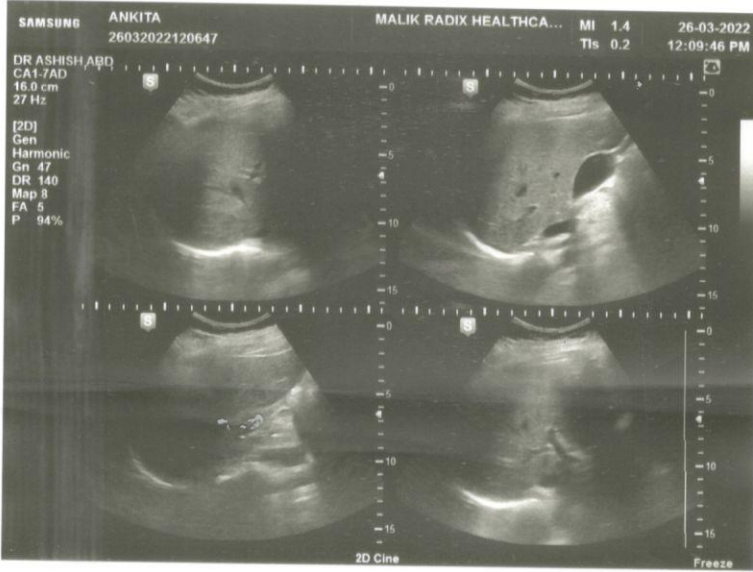
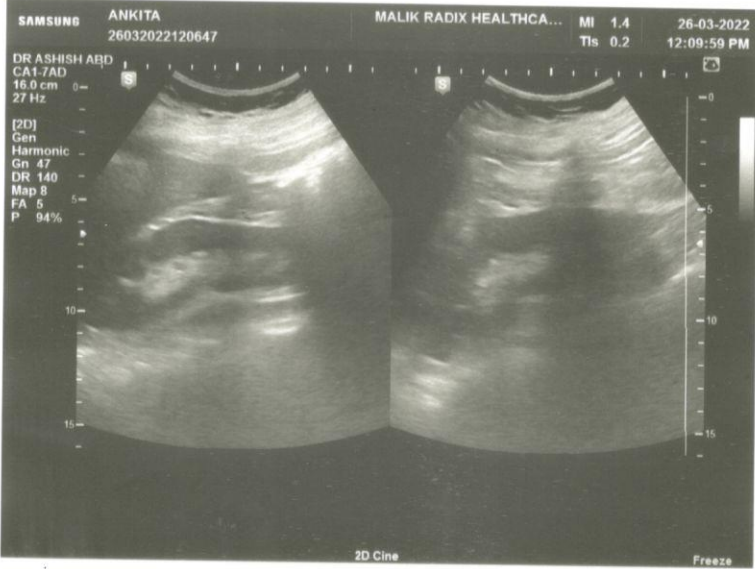
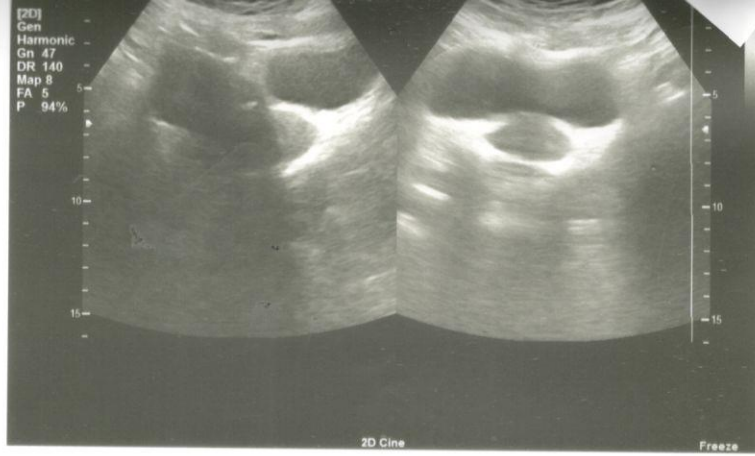\*\*\*\*\* END OF REPORT \*\*\*\*\*

DR. K.K. SINHA  
M.B.B.S., D.M.R.D.  
SENIOR CONSULTANT  
Reg. No. 25437 (DMC)

DR. RAJESH MALHOTRA  
MBBS, MD (RADIOLOGY)  
CONSULTANT RADIOLOGY  
Reg.No.DMC9299

DR. T. K VOHRA  
MD (RADIODIAGNOSIS)  
SENIOR CONSULTANT  
Reg. No. 3272 (DMC)

DR ASHISH KUMAR  
MBBS, MD (RADIOLOGY)  
CONSULTANT RADIOLOGY  
Reg.No.DMC62682





# MALIK RADIX HEALTH CARE

(UNIT OF MALIK RADIX HEALTHCARE PVT. LTD)

C-217, 218, Nirman Vihar, Vikas Marg, New Delhi - 110092

Tel.: 011-22011192, 22011196, 47060150 • Fax.: 22011208

E-mail : radixhealthcare@yahoo.co.in

Website : www.radixhealthcare.org



Safety at WEI now accredited by NABH

UHID	PT154607	LAB No.	ULC2106870
Name	Mrs. ANKITA GUPTA	Regn. No.	GEN2159080
Age / Sex	33 Yrs / F	Receiving Dt/Time	26/Mar/2022 12:10
		Reporting Dt/Time	26/Mar/2022 12:10 PM

## U/S WHOLE ABDOMEN

The liver is normal in size, shape and normal in echogenicity. No focal lesion is seen. No Intra hepatic biliary radicals dilatation seen. Portal vein is normal in course and calibre.

Gall bladder appears normal in size, shape and distention. Lumen is free and gall bladder wall thickness. No evidence of any cholecystitis or pericholecystic fluid seen. **CBD measures - 3.5mm**

Pancreas is normal in size, shape and echogenicity

Spleen is normal size, shape and echogenicity.

Right kidney is normal in size, shape and echogenicity. No calculus seen. Pelvicalyceal system is normal. Corticomedullary differentiation is maintained.

Left kidney is normal in size, shape and echogenicity. No calculus seen. Pelvicalyceal system is normal. Corticomedullary differentiation is maintained.

Urinary bladder is normal in shape, outline and distension. Lumen is anechoic and no wall thickening seen.

Uterus is **anteverted**, and is normal in size. No focal myometrial lesion seen. Endometrium is normal in thickness

Bilateral ovaries are normal in size, shape and echogenicity.

No free fluid is seen in the abdomen/pelvis.

## IMPRESSION: Normal Study

Please correlate clinically.

**Dr. ASHISH KUMAR TOMER**

Consultant in Radiology & maternal-fetal medicine  
MD

Member of fetal medicine Foundation ( UK)

DMC reg no. 62682. FMF, UK : id no. 236814

DR. K.K. SINHA  
M.B.B.S. D.M.R.D.  
SENIOR CONSULTANT  
Reg. No. 25437 (DMC)

DR. RAJESH MALHOTRA  
MBBS, MD (RADIOLOGY)  
CONSULTANT RADIOLOGY  
Reg.No.DMC9299

DR. T. K VOHRA  
MD (RADIODIAGNOSIS)  
SENIOR CONSULTANT  
Reg. No. 3272 (DMC)

DR ASHISH KUMAR  
MBBS, MD (RADIOLOGY)  
CONSULTANT RADIOLOGY  
Reg.No.DMC62682

Page 2 of 2

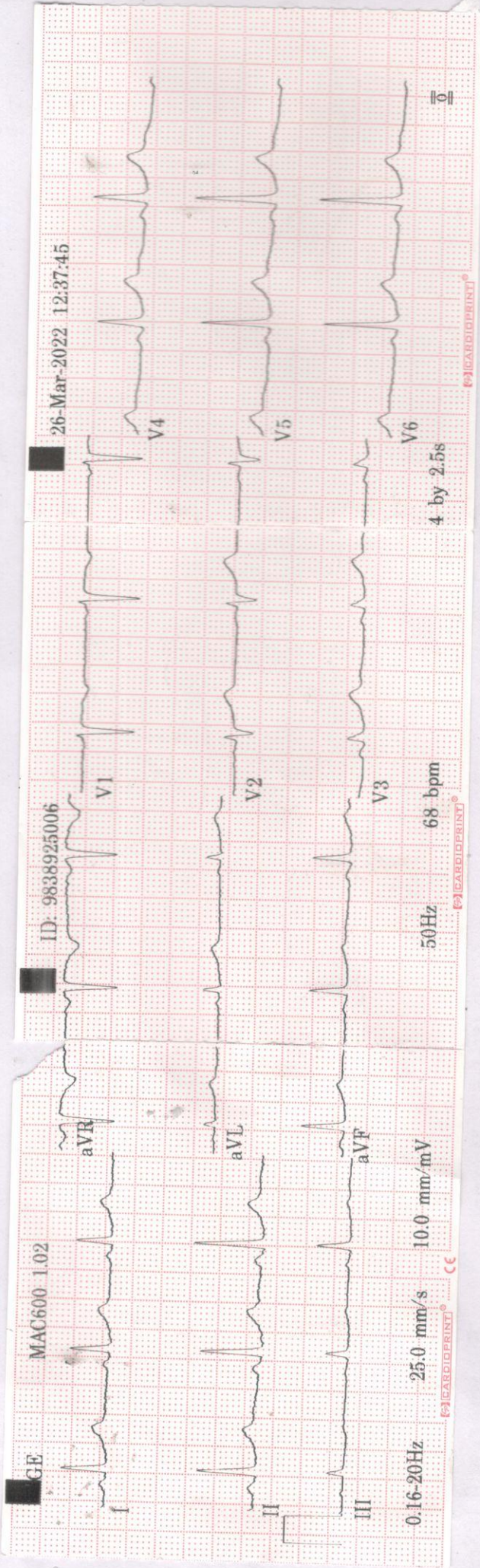
RADIOLOGIST :

## Facilities Available :

MRHC / GEN / FR / 15

- ★ Multispeciality Hospital ★ 24 Hours Emergency ★ X-Ray/ ECG/ Ultrasound ★ Dental
- ★ Fully Equipped Operation Theatre ★ Fully Functional Lab ★ Casualty/ICU ★ Nursery
- ★ Labour Room ★ All Speciality OPD ★ Laparoscopic Surgery ★ ECHO ★ Plastic Surgery

Home Collection Facility Available Contact : 9999254739



MAC600 1.02

ID: 9838925006

33years Female

Vent. rate 68 bpm

QRS duration 80 ms

QT/QTc 420/446 ms

PR interval 102 ms

P duration 86 ms

RR interval 882 ms

P-R-T axes 41 52 37

Ankita Gupta

MAC600 1.02

I2SL™ v239

GE CARDIOPRINT

GE HEALTHCARE  
 GE HEALTHCARE  
 GE HEALTHCARE  
 GE HEALTHCARE

# Malik Radix HealthCare.

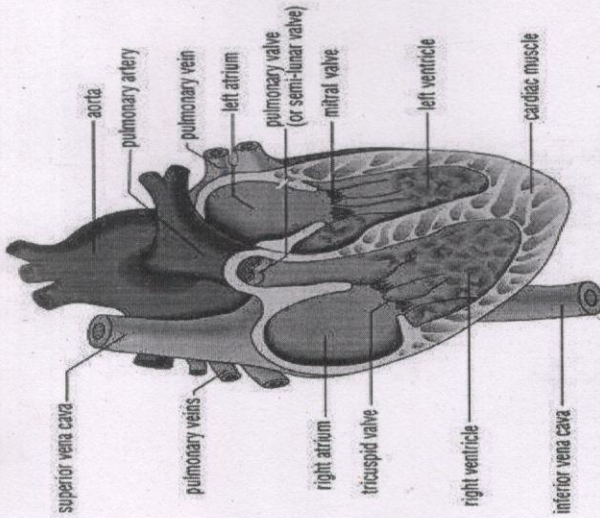
## ELECTROCARDIOGRAM

Name: MRS. ANKITA GUPTA

Age & Sex: 33YR/FEMALE

Ref by: MEDIWHEEL

Date: 26/03/2022



### ECG FINDINGS:

Rate 68bpm      Rhythm Sinus      Mechanism Normal

Axis Normal      P Wave Normal      PR Interval 0.10Sec

QRS Complex Normal      QT Interval Normal      Q Wave Normal

ST Segment Normal      T Wave Normal

Conclusion – Sinus Rhythm, Normal Axis, TWNL.

Doctors Signature

*[Signature]*  
 Dr. SHEIKH AZIZ AHMED  
 M.D. "Physician"  
 PGDCC  
 DMC-46499