

MER- MEDICAL EXAMINATION REPORT

Date of Examination	25/11/23		
NAME	VINAY KUMAR		
AGE	35	Gender	M
HEIGHT(cm)	173	WEIGHT (kg)	75 25.1
B.P.	120/84		
ECG	normal		
X Ray	normal		
Vision Checkup	very poor eyes for reading		
Present Ailments	None		
Details of Past ailments (If Any)	No		
Comments / Advice : She /He is Physically Fit	Inconcomitant Pt		



Dr. Smita Rastogi
 MBBS, DCP
 Reg. No. 7370

Signature with Stamp of Medical Examiner

घरत मरकर

UNIVERSITY OF AM



विनीत कुमार

Vineet Kumar

जन्म तिथि/DOB: 10/07/1988

पुरुष / MALE



9107 1507 6045

आम आदमी का अधिकार



You have been informed that ent dental othal diet consultation facility is not available at our centre. If you are ready then your test can be start.

2D echo test facility is not available at our center, instead we do TMT test.





MODERN PATHOLOGY & DIAGNOSTIC CENTRE

Dr. R. P. Rastogi
M.B.B.S., M.D. (Path & Bact)



CLINIC :
1/4A, Vineet Khand, (Opp Jaipuria Management)
Gomti Nagar, Lucknow - 226 010
Ph.: 0522-4008184, 4308184 • 8112323230
Mob.: 7618884441, 9450389932, 8177063877

Date	: 25-Nov-2023		
Name	: Mr. VINEET KUMAR	Age	: 35 Yrs.
Ref.By	: APOLLO HEALTH	Sex	: Male
Haemoglobin	15.1	gm%	14 - 17
Total Leucocyte Count	5400	Cells/cumm.	4000-11000
Differential Leucocyte Count			
Polymorphs	47	%	45 - 70
Lymphocytes	44	%	20 - 45
Eosinophils	02	%	0 - 6
Monocytes	07	%	0 - 8
Basophils	00	%	0 - 1
Erythrocyte Sedimentation Rate (Wintrobe)			
ESR	06	mm in 1st Hr.	0 - 9
PCV	46.5	cc%	40 - 52
Corrected ESR	02	mm in 1st Hr.	0 - 9
Platelet Count	1.66	lakh/cumm.	1.5 - 4.0
Red Cells Count	5.51	million/cmm	3.90 to 5.80
Absolute values			
MCV	84.4	fL	77 - 97
MCH	27.3	pg	27 - 31
MCHC	32.4	gm /dl	31 - 34

Dr. Sanjay Rastogi
M.B.B.S., D.C.P. (P&B)

Dr. Smriti Rastogi
M.B.B.S., DCP

Results, adhering to W.H.O. and International Federation of Clinical Chemists Quality Control Standards.

SAMPLE COLLECTION FACILITY AVAILABLE

Report needs clinicopathological correlation ♦ Not for Medico Legal Purpose

e-mail : mpdcgn@gmail.com ♦ For online reports - www.modernpath.in

♦ Please ask for your computerized bill ♦ Pay only the printed collection charges



MODERN PATHOLOGY & DIAGNOSTIC CENTRE

Dr. R. P. Rastogi
M.B.B.S., M.D. (Path & Bact)



CLINIC :

1/4A, Vineet Khand, (Opp Jaipuria Management)
Gomti Nagar, Lucknow - 226 010
Ph : 0522-4008184, 4308184 • 8112323230
Mob : 7618884441, 9450389932, 8177063877

Date	: 25-Nov-2023	Age	: 35 Yrs.
Name	: Mr. VINEET KUMAR	Sex	: Male
Ref.By	: APOLLO HEALTH		

-Haemoglobin	15.1	gm%	14 - 17
--------------	------	-----	---------

Total Leucocyte Count	5400	Cells/cumm.	4000-11000
-----------------------	------	-------------	------------

Differential Leucocyte Count			
Polymorphs	47	%	45 - 70
Lymphocytes	44	%	20 - 45
Eosinophils	02	%	0 - 6
Monocytes	07	%	0 - 8
Basophils	00	%	0 - 1

Erythrocyte Sedimentation Rate (Wintrobe)			
ESR	06	mm in 1st Hr.	0 - 9
PCV	46.5	cc%	40 - 52
Corrected ESR	02	mm in 1st Hr.	0 - 9

Platelet Count	1.66	lakh/cumm.	1.5 - 4.0
----------------	------	------------	-----------

Red Cells Count	5.51	million/cmm	3.90 to 5.80
-----------------	------	-------------	--------------

Absolute values			
MCV	84.4	fL	77 - 97
MCH	27.3	pg	27 - 31
MCHC	32.4	gm /dl	31 - 34

Dr. Sanjay Rastogi
M.B.B.S., D.C.P. (CCRC)

Dr. Smriti Rastogi
M.B.B.S., DCP

Results, adhering to W.H.O. and International Federation of Clinical Chemists Quality Control Standards.

SAMPLE COLLECTION FACILITY AVAILABLE

Report needs clinicopathological correlation ♦ Not for Medico Legal Purpose

e-mail : mpdcgn@gmail.com ♦ For online reports - www.modernpath.in

♦ Please ask for your computerized bill ♦ Pay only the printed collection charges



MODERN PATHOLOGY & DIAGNOSTIC CENTRE

Dr. R. P. Rastogi
M.B.B.S., M.D. (Path & Bact)



CLINIC :
1/4A, Vineet Khand, (Opp Jaipuria Management)
Gomti Nagar, Lucknow - 226 010
Ph. : 0522-4008184, 4308184 • 8112323230
Mob. : 7618884441, 9450389932, 8177063877

Date	: 25-Nov-2023	Age	: 35 Yrs.
Name	: Mr. VINEET KUMAR	Sex	: Male
Ref.By	: APOLLO HEALTH		

General Blood Picture

RBCs	RBCs are Normocytic & Normochromic. No Normoblasts are seen.
WBCs	TLC is within normal range. DLC shows normal counts. No immature cells of WBC seen.
PLATELETS	Platelets are adequate in number and morphology.
OTHERS	No haemoparasites are seen.
IMPRESSION	Normal GBP

Dr. Sanjay Rastogi
M.B.B.S., (D.D., CHRP, BARC)

Dr. Smita Rastogi
M.B.B.S., DCP

Results, adhering to W.H.O. and International Federation of Clinical Chemists Quality Control Standards.

SAMPLE COLLECTION FACILITY AVAILABLE

Report needs clinicopathological correlation ♦ Not for Medico Legal Purpose

e-mail : mpdcgn@gmail.com ♦ For online reports - www.modernpath.in

♦ Please ask for your computerized bill ♦ Pay only the printed collection charges

CLINIC :
1/4A, Vineet Khand, (Opp Jaipuria Management)
Gomti Nagar, Lucknow - 226 010
Ph : 0522-4008184, 4308184 • 8112323230
Mob : 7618884441, 9450389932, 8177063877

Date	: 25-Nov-2023	Age	: 35 Yrs.
Name	: Mr. VINEET KUMAR	Sex	: Male
Ref.By	: APOLLO HEALTH		
Plasma Glucose - F GOD-POD Method	97	mg/dl	70 - 110
Plasma Glucose - PP GOD-POD Method	114	mg/dl	110 - 170
Blood Group & Rh	"A" Positive		
LFT T&D			
Total Bilirubin	0.46	mg%	0.2 - 1.0
Direct Bilirubin	0.10	mg%	0.0 to 0.40
Indirect Bilirubin	0.36	mg%	0.10 to 0.90
S.G.P.T	50	IU/L	5 - 40
S.G.O.T	48	IU/L	5 - 50
ALP	95	IU/L	40 to 129
Serum Gamma G.T.	34	IU/L	11 - 50
KFT			
UREA	20.1	mg %	15 - 50
CREATININE	0.59	mg %	0.5 - 1.5
URIC ACID	5.5	mg %	2 - 7
CALCIUM	9.4	mg %	8.8 - 10.0
Urine Sugar (Fasting)	NIL		
Urine Sugar (PP)	NIL		

Dr. Sanjay Rastogi
M.B.B.S., DCP, CRIAT (BARC)

Dr. Smita Rastogi
Contd... M.B.B.S., DCP

Results, adhering to W.H.O. and International Federation of Clinical Chemists Quality Control Standards.

SAMPLE COLLECTION FACILITY AVAILABLE

Report needs clinicopathological correlation ♦ Not for Medico Legal Purpose

e-mail : mpdcgn@gmail.com ♦ For online reports - www.modernpath.in

♦ Please ask for your computerized bill ♦ Pay only the printed collection charges



MODERN PATHOLOGY & DIAGNOSTIC CENTRE

Dr. R. P. Rastogi
M.B.B.S., M.D. (Path & Bact)



CLINIC :
1/4A, Vineet Khand, (Opp Jaipuria Management)
Gombi Nagar, Lucknow - 226 010
Ph. : 0522-4008184, 4308184 • 8112323230
Mob.: 7618884441, 9450389932, 8177063877

Date	: 25-Nov-2023	Age	: 35 Yrs.
Name	: Mr. VINEET KUMAR	Sex	: Male
Ref.By	: APOLLO HEALTH		

LIPID PROFILE

Triglycerids	82	mg%	70 - 190
S. Cholestrol S.	223	mg%	130 - 230
S. HDL Cholestrol	49.2	mg%	35 - 75
S. LDL Cholestrol	157.4	mg%	75 - 150
VLDL	16.4	mg%	0 - 34
Chol / HDL factor	4.53		
LDL / HDL Factor	3.2		

COMMENTS

* Triglycerides (TG) are the main dietary lipids. Cholesterol constitutes a small part of the dietary lipids, it is mostly synthesised in the liver. Both TG and Chol. are transported through the plasma by lipoproteins (Chylomicrons, VLDL, LDL, IDL, HDL).

* LDL is the major cholesterol particle in plasma and high levels are strongly implicated in the formation of atheroma. An increase in the LDL leads to hypercholesterolemia, and therefore a risk factor for IHD. LDL increases with age particularly in females. Oestrogen lower LDL and raise HDL. Raised chol. in females is mostly due to disturbed thyroid function.

* Increase in VLDL leads to hyperglyceridaemia. Raised TGs are associated with increased risk of CHD. Very high TGs increase the risk of Pancreatitis. Cholesterol is often raised due to Diabetes, Renal disease, Diuretic or Betablocker therapy.

TYPES OF HYPERLIPOPROTEINEMIAS

TYPE 1: Normal cholesterol TG greatly raised	TYPE 3: Cholesterol increased TG increased
TYPE 2a: Cholesterol increased LDL increased TG normal	TYPE 4: Cholesterol normal /increased VLDL increased TG increased
TYPE 2b Chol. increased VLDL raised TG increased LDL increased	TYPE 5: Cholesterol increased LDL reduced VLDL increased TG greatly increased

Dr. Sanjay Rastogi
M.B.B.S., DCP, CRIAT (BARC)

Dr. Smita Rastogi
Contd...M.B.B.S., DCP

Results, adhering to W.H.O. and International Federation of Clinical Chemists Quality Control Standards.

SAMPLE COLLECTION FACILITY AVAILABLE

Report needs clinicopathological correlation ♦ Not for Medico Legal Purpose

e-mail : mpdcgn@gmail.com ♦ For online reports - www.modernpath.in

♦ Please ask for your computerized bill ♦ Pay only the printed collection charges



MODERN PATHOLOGY & DIAGNOSTIC CENTRE

CLINIC :
1/4A, Vineet Khand, (Opp Jalpuria Management)
Gomti Nagar, Lucknow - 226 010
Ph. : 0522-4008184, 4308184 ✆ 8112323230
Mob. : 7618884441, 9450389932, 8177063877

Dr. R. P. Rastogi
M.B.B.S., M.D. (Path & Bact)



Date : 25-Nov-2023

Name : **Mr. VINEET KUMAR**

Age : 35 Yrs.

Ref.By : APOLLO HEALTH

Sex : Male

THYROID TEST

Tri-iodothyronine (T3)	1.50	nmol/L	0.50 to 2.50
Thyroxine (T4)	6.76	mcg/dL	5.0 to 12.5
Thyroid Stimulating Hormone (TSH)	2.73	mIU/ ml	0.3 to 6.0

COMMENTS

- 1) Primary hyperthyroidism is accompanied by elevated Serum T3 and T4 values along with depressed TSH levels.
- 2) Primary Hypothyroidism is accompanied by depressed serum T3 and T4 values and elevated serum TSH levels.
- 3) Normal T4 levels accompanied by high T3 levels are seen in patients with T3 thyrotoxicosis.
- 4) Slightly elevated T3 levels may be found in pregnancy and estrogen therapy, while depressed levels maybe encountered in severe illness, malnutrition, renal failure and during therapy with drugs like propranolol and propylthiouracil.
- 5) Elevated TSH levels may also be indicative of TSH secreting Pituitary Tumour.

Dr. Sanjay Rastogi
M.B.B.S., DCP, CRIAT (BARC)

Dr. Smita Rastogi
Contd... M.B.B.S., DCP

Results, adhering to W.H.O. and International Federation of Clinical Chemists Quality Control Standards.

SAMPLE COLLECTION FACILITY AVAILABLE

Report needs clinicopathological correlation ✦ Not for Medico Legal Purpose

e-mail : mpdcgn@gmail.com ✦ For online reports - www.modernpath.in

✦ Please ask for your computerized bill ✦ Pay only the printed collection charges

CLINIC :
1/4A, Vineet Khand, (Opp Jaipuria Management)
Gomti Nagar, Lucknow - 226 010
Ph: 0522-4008184, 4308184 ♦ 8112323230
Mob: 7618884441, 9450389932, 8177063877

Date : 25-Nov-2023	Age : 35 Yrs.
Name : Mr. VINEET KUMAR	Sex : Male
Ref.By : APOLLO HEALTH	

Glycosylated Haemoglobin

Glycosylated Haemoglobin 5.3 % 4.5 TO 6.0

INTERPRETATION AND COMMENTS

NON DIABETIC : 4.5 to 6.0 %
GOOD CONTROL: 6.0 to 7.0
FAIR CONTROLLED 7.0 AND 8.0
UNCONTROLLED 8.0 AND ABOVE

Glycosylated haemoglobin is the adducted glucose in the haemoglobin of the red blood cells, this adduction is stable for the life time of the RBC (i.e 120 days). There fore the measure of glycosylated haemoglobin reflects the average blood glucose concentration over the preseding several weeks. The sudden change in blood glucose level would not effect the glycosylated haemoglobin level ,which serves as a better marker of long term metabolic control and the efficacy of therapy.

Dr. Sanjay Rastogi
M.B.B.S., DCP, CRIAT (BARC)

Dr. Smita Rastogi
Contd... M.B.B.S., DCP

Results, adhering to W.H.O. and International Federation of Clinical Chemists Quality Control Standards.

SAMPLE COLLECTION FACILITY AVAILABLE

Report needs clinicopathological correlation ♦ Not for Medico Legal Purpose

e-mail : mpdcgn@gmail.com ♦ For online reports - www.modernpath.in

♦ Please ask for your computerized bill ♦ Pay only the printed collection charges



MODERN PATHOLOGY & DIAGNOSTIC CENTRE

Dr. R. P. Rastogi
M.B.B.S., M.D. (Path & Bact)



CLINIC :
1/4A, Vineet Khand, (Opp Jaipuria Management)
Gomti Nagar, Lucknow - 226 010
Ph.: 0522-4008184, 4308184 • 8112323230
Mob.: 7618884441, 9450389932, 8177063877

Date : 25-Nov-2023

Name : Mr. VINEET KUMAR

Age : 35 Yrs.

Ref.By : APOLLO HEALTH

Sex : Male

Urine Examination

PHYSICAL

Colour	Straw
Turbidity	Nil
Deposit	Nil
Reaction	Acidic
*Specific Gravity	1.030

CHEMICAL

Protein	Nil
Sugar	Nil
*Bile Salts	Nil
*Bile Pigments	Nil
Phosphate	Nil

MICROSCOPIC

Pus Cells	Nil	/hpf
Epithelial Cells	1-2	/hpf
Red Blood Cells	Nil	/hpf
Casts	Nil	
Crystals	Nil	
Others	Nil	

Dr. Sanjay Rastogi
M.B.B.S., DCP, CRIP (BARC)

Dr. Smita Rastogi
M.B.B.S., DCP

Results, adhering to W.H.O. and International Federation of Clinical Chemists Quality Control Standards.

SAMPLE COLLECTION FACILITY AVAILABLE

Report needs clinicopathological correlation ♦ Not for Medico Legal Purpose

e-mail : mpdcgn@gmail.com ♦ For online reports - www.modernpath.in

♦ Please ask for your computerized bill ♦ Pay only the printed collection charges

CLINIC :
1/4A, Vineet Khand, (Opp Jaipuria Management)
Gomti Nagar, Lucknow - 226 010
Ph.: 0522-4008184, 4308184 • 8112323230
Mob.: 7618884441, 9450389932, 8177063877



TEST REQUEST ID :012311250027	SAMPLE DATE	:25/Nov/2023 09:42AM
NAME :Mr. VINEET KUMAR	SAMPLE REC. DATE	:25/Nov/2023 09:42AM
AGE/SEX :35 YRS/MALE	REPORTED DATE	:25/Nov/2023 02:28PM
REFERRED BY : Apollo Health and Lifestyle Limited,	BARCODE NO	:01250027

XRAY CHEST PA

- Trachea is central in position.
- Bilateral lung fields are normally aerated.
- Both hilar shadows are normal.
- Both C.P. angles are clear.
- Cardiac shadow is within normal limits.
- Bony cage appears normal.

OPINION: NORMAL STUDY.

Please correlate clinically.

*** End Of Report ***

Dr. Sanjay Rastogi
M.B.B.S., DCP, CRIAT (BARC)



DR. PANKAJ UPADHYAYA

Dr. Smita Rastogi
M.B.B.S., DCP

Results, adhering to W.H.O. and International Federation of Clinical Chemists Quality Control Standards.

DMRD
SAMPLE COLLECTION FACILITY AVAILABLE

Report needs clinicopathological correlation ♦ Not for Medico Legal Purpose

e-mail : mpdcgn@gmail.com ♦ For online reports - www.modernpath.in

Print Date/Time: 25/11/2023 2:40 PM ♦ Please ask for your computer check list ♦ Only the printed collection charges



TEST REQUEST ID :012311250027	SAMPLE DATE	:25/Nov/2023 09:42AM
NAME :Mr. VINEET KUMAR	SAMPLE REC. DATE	:25/Nov/2023 09:42AM
AGE/SEX :35 YRS/MALE	REPORTED DATE	:25/Nov/2023 01:16PM
REFERRED BY : Apollo Health and Lifestyle Limited,	BARCODE NO	:01250027

USG WHOLE ABDOMEN-MALE

Liver: is normal in size (139 mm). Parenchymal echogenicity is normal. No focal echovariant lesion is seen. Intrahepatic biliary radicles are not dilated.

Gall Bladder: is well distended. Lumen is anechoic. Wall is of normal thickness.

CBD: is normal in diameter. Portal vein is normal in diameter.

Pancreas: is normal in size, shape and echotexture. No focal echovariant lesion is seen. Pancreatic duct is not dilated.

Spleen: is normal in size (95 mm), shape and echotexture. No focal echovariant lesion is seen. Splenic vein is normal.

Both Kidneys: are normal in size (RK- 99 x 52 mm & LK -99 x 45 mm), shape, position and excursion. Parenchymal echogenicity and echotexture is normal with maintained corticomedullary differentiation. No mass, cyst or calculi is seen. Pelvicalyceal systems are not dilated. Ureters are not dilated.

Urinary bladder: is well distended. Lumen is anechoic. Wall is of normal thickness. No mass or calculus is seen.

Prostate: is normal in size (42 x 34 x 28 mms, wt = 21 gms), shape and echotexture. No focal echovariant lesion is seen. Prostatic capsule appears to be intact. Median lobe is not projecting in UB lumen. Both seminal vesicles appear normal.

Both iliac fossae are clear. No obvious bowel pathology is noted.

There is no free fluid in peritoneal cavity.

OPINION: NORMAL STUDY.

*** End Of Report ***

Dr. Sanjay Rastogi
M.B.B.S., DCP, CRIAT (BARC)



DR. PANKAJ UPADHYAYA

Dr. Smita Rastogi
M.B.B.S., DCP

Consultant Radiologist

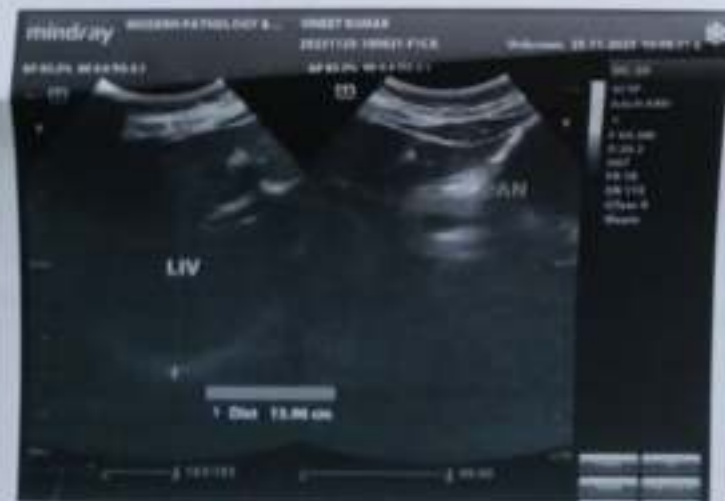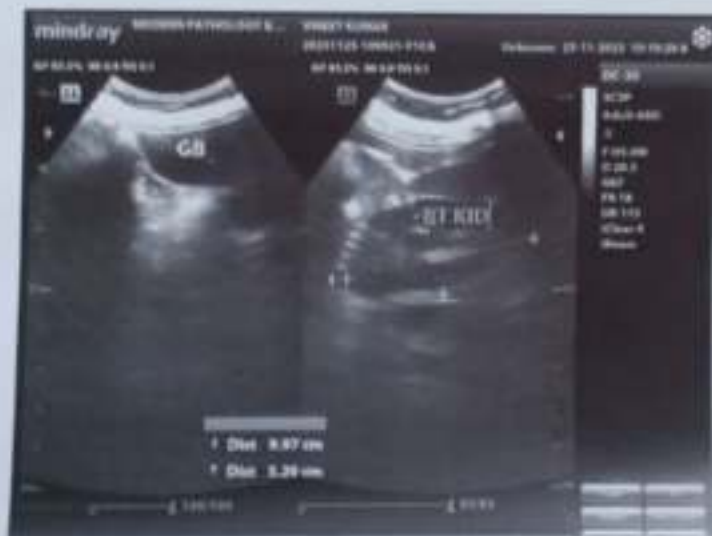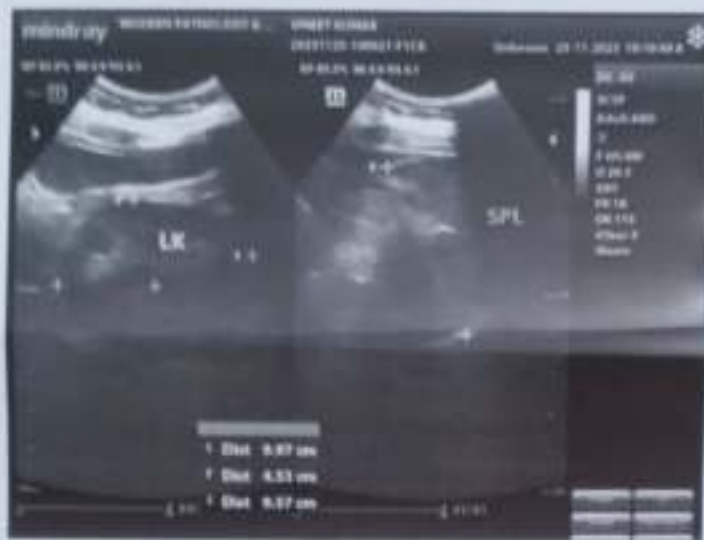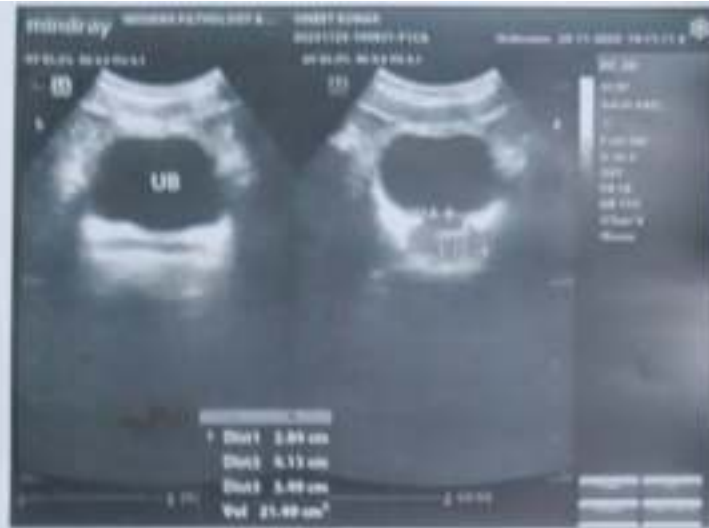Printed Results adhering to W.H.O. and International Federation of Clinical Chemists Quality Control Standards.

SAMPLE COLLECTION FACILITY AVAILABLE

Report needs clinicopathological correlation ♦ Not for Medico Legal Purpose

e-mail : mpdcgn@gmail.com ♦ For online reports - www.modernpath.in

♦ Please ask for your computerized bill ♦ Pay only the printed collection charges





MODERN PATHOLOGY & DIAGNOSTIC CENTRE

Dr. R. P. Rastogi
M.B.B.S., M.D. (Path & Bact)



CLINIC :
1/4A, Vineet Khand, (Opp Jaipuria Management)
Gomti Nagar, Lucknow - 226 010
Ph.: 0522-4008184, 4308184 • 8112323230
Mob.: 7618884441, 9450389932, 8177063877

Registration Date 25/11/2023

Age : 35 Sex: M

Name : Mr Vineet Kumar

Ref By: Apollo Health

Dr. H. S. Kholia
M.B.B.S., D.O.M.S.
Consultant Ophthalmologist
Registration No.: 34062 (M.C.I., U.P.)

EYES EXAMINATION REPORT

EYE SIGHT	DISTANT VISION		NEAR VISION	
	RIGHT	LEFT	RIGHT	LEFT
WITHOUT GLASSES	6/6	6/6	N-9	N-9
WITH GLASSES			N-6	N-6
POWER OF GLASSES IF USED			Power not confirmed	
FUNDUS	NORMAL			
COLOR VISION	Present Normal according to ISHIHARA'S CHART			
PUPILS	Normally reacting to light and accommodation			



Dr. Sanjay Rastogi
M.B.B.S., DCP, CRIAT (BARC)

Dr. Smita Rastogi
M.B.B.S., DCP

Results, adhering to W.H.O. and International Federation of Clinical Chemists Quality Control Standards.

SAMPLE COLLECTION FACILITY AVAILABLE

Report needs clinicopathological correlation ♦ Not for Medico Legal Purpose

e-mail : mpdcgn@gmail.com ♦ For online reports - www.modernpath.in

♦ Please ask for your computerized bill ♦ Pay only the printed collection charges



MODERN PATHOLOGY & DIAGNOSTIC CENTRE

Dr. R. P. Rastogi
M.B.B.S., M.D. (Path & Bact)



CLINIC :
1/4A, Vineet Khand, (Opp Jaipuria Management)
Gomti Nagar, Lucknow - 226 010
Ph. : 0522-4008184, 4308184 • 8112323230
Mob. : 7618884441, 9450389932, 8177063877

Patient name: **Mr Vineet Kumar**
Ref By. **Apollo Health**


Age/Sex **35/M**
25/11/2023

E.C.G. REPORT

1. Rhythm	:	Sinus, Regular
2. Atrial Rate	:	94/mt
3. Ventricular Rate	:	94/mt
4. P – Wave	:	Normal
5. P R Interval	:	Normal
6. Q R S	:	
Axis	:	Normal
R/S Ratio	:	Normal
Configuration	:	Normal
7. Q T c Interval	:	Normal
8. S-T Segment	:	Normal
9. T-Wave	:	Normal

FINAL IMPRESSION

E.C.G. is within normal limits.


Dr. AMIT MOHAN
MD
44559
Signature of Doctor

Dr. Sanjay Rastogi
M.B.B.S., DCP, CRIAT (BARC)

Dr. Smita Rastogi
M.B.B.S., DCP

Results, adhering to W.H.O. and International Federation of Clinical Chemists Quality Control Standards.

SAMPLE COLLECTION FACILITY AVAILABLE

Report needs clinicopathological correlation ♦ Not for Medico Legal Purpose

e-mail : mpdcgn@gmail.com ♦ For online reports - www.modernpath.in

♦ Please ask for your computerized bill ♦ Pay only the printed collection charges

Name **Veenit Kumar**

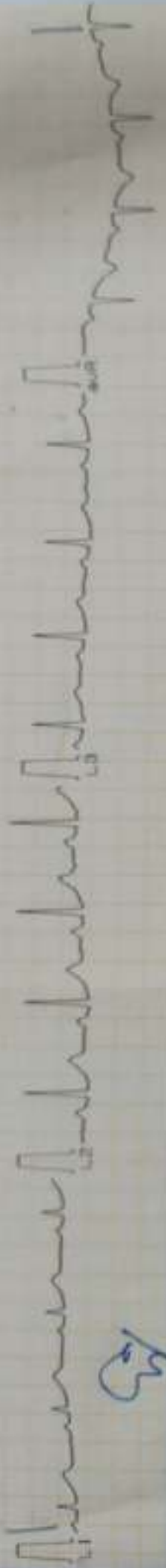
Age **45** Yrs

Sex **M**

ECG

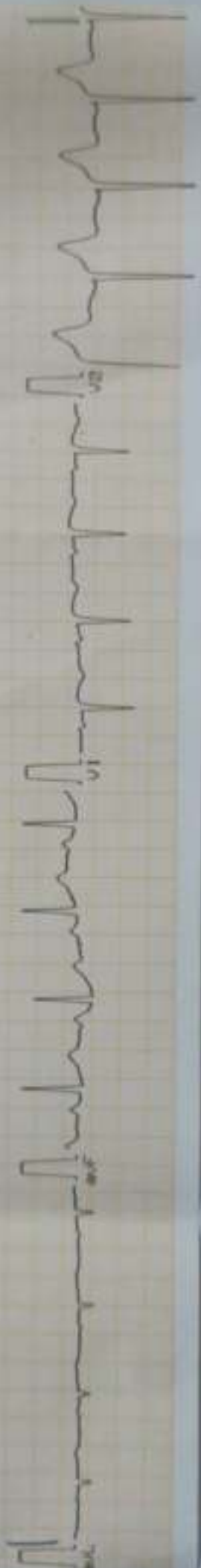
0.1-35 Hz

BLC



Dr. *[Signature]*

Dr. *[Signature]*



Dr. AMIT MOHAR
MC
File No. 24459

MODERN PATHOLOGY AND DIAGNOSTIC CENTER

Gomti Nagar Lucknow

Report

VINEET KUMAR / 35 Yrs / M / 173 Cms / 75 Kg
 Date: 25 - 11 - 2023 Refd By : APOLLO HEALTH Examined By:

Stage	Time	Duration	Speed(Kmph)	Elevation	METs	Rate	% THR	BP	HRP	PVC	Comments
Supine	00:05	0:05	00.0	00.0	01.0	087	47 %	120/84	104	00	
Standing	00:09	0:04	00.0	00.0	01.0	089	48 %	120/84	106	00	
HV	00:13	0:04	00.0	00.0	01.0	090	49 %	120/84	108	00	
ExStart	00:19	0:06	00.0	00.0	01.0	090	49 %	120/84	108	00	
BRUCE Stage 1	03:19	3:00	02.7	10.0	04.7	140	76 %	120/84	168	00	
BRUCE Stage 2	06:19	3:00	04.0	12.0	07.1	163	88 %	132/90	215	00	
PeakEx	06:24	0:05	00.0	00.0	07.2	164	89 %	142/96	232	00	
Recovery	07:24	1:00	00.0	00.0	01.1	129	70 %	140/92	180	00	
Recovery	08:24	2:00	00.0	00.0	01.0	115	62 %	136/90	156	00	
Recovery	09:24	3:00	00.0	00.0	01.0	108	58 %	130/86	140	00	
Recovery	09:32	3:07	00.0	00.0	01.0	106	57 %	130/86	137	00	

FINDINGS :

Exercise Time : 06:05
 Max HR Attained : 164 bpm 89% of Target 185
 Max BP Attained : 142/96 (mm/Hg)
 Max WorkLoad Attained : 7.2 Fair response to induced stress
 Test End Reasons : Test Complete

REPORT :

CONCLUSIONS:

1. STRESS TEST IS NEGATIVE FOR EXERCISE INDUCED ISCHAEMIC HEART DISEASE.


 ANAND MOHAN MD
 Reg. No. 44559



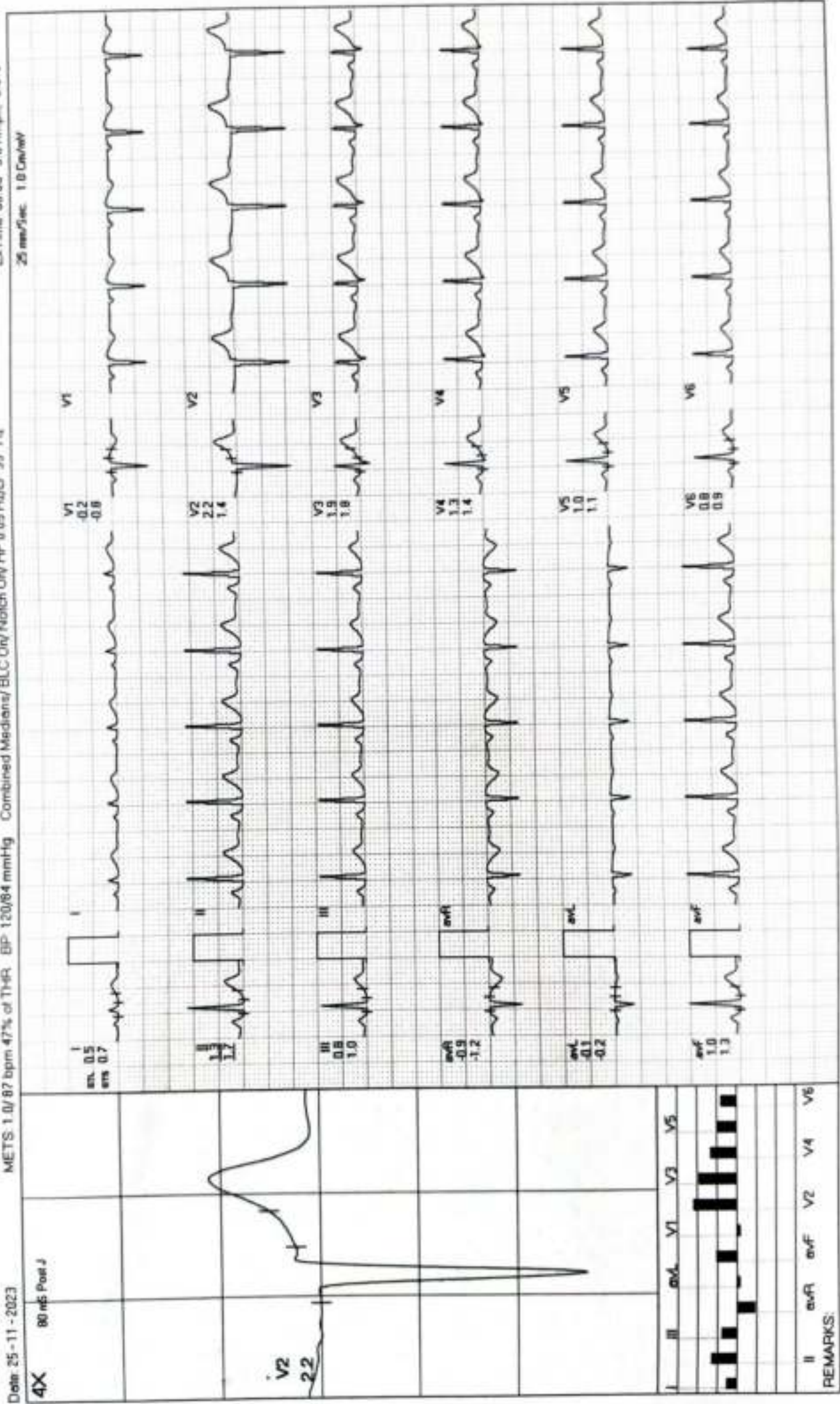
BRUCE:Supine(0:05)

MODERN PATHOLOGY AND DIAGNOSTIC CENTER

VINEET KUMAR / 35 Yrs / M / 173 Cms / 75 Kg / HR : 87

ExTime 00:00 0.0 Kmph 0.0%
25 mm/sec 1.0 Cm/box

METS 1.0/ 87 bpm 47% of THR. BP: 120/84 mmHg Combined Medians/ BLC Or/ Notch Or/ HF 0.05 Hz/ LF 35 Hz



4X 80 mm Post J

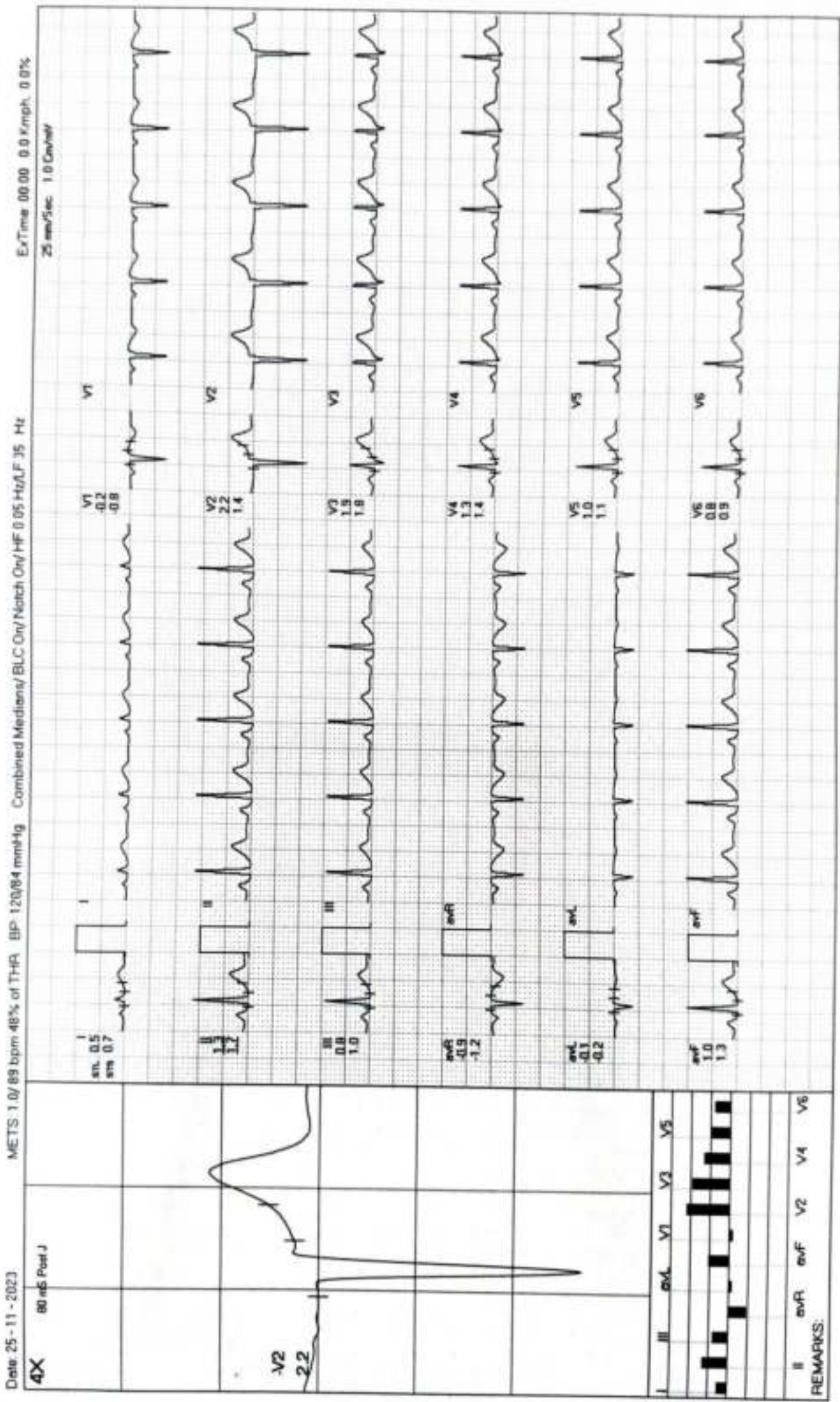
v2 2.2

I	II	III	aVR	aVL	aVF	V1	V2	V3	V4	V5	V6
REMARKS:											

MODERN PATHOLOGY AND DIAGNOSTIC CENTER

VINEET KUMAR / 35 Yrs / M / 173 Cms / 75 Kg / HR : 89

BRUCE: Standing(0:05)



REMARKS:

MODERN PATHOLOGY AND DIAGNOSTIC CENTER

VINEET KUMAR / 35 Yrs / M / 173 Cms / 75 Kg / HR : 90

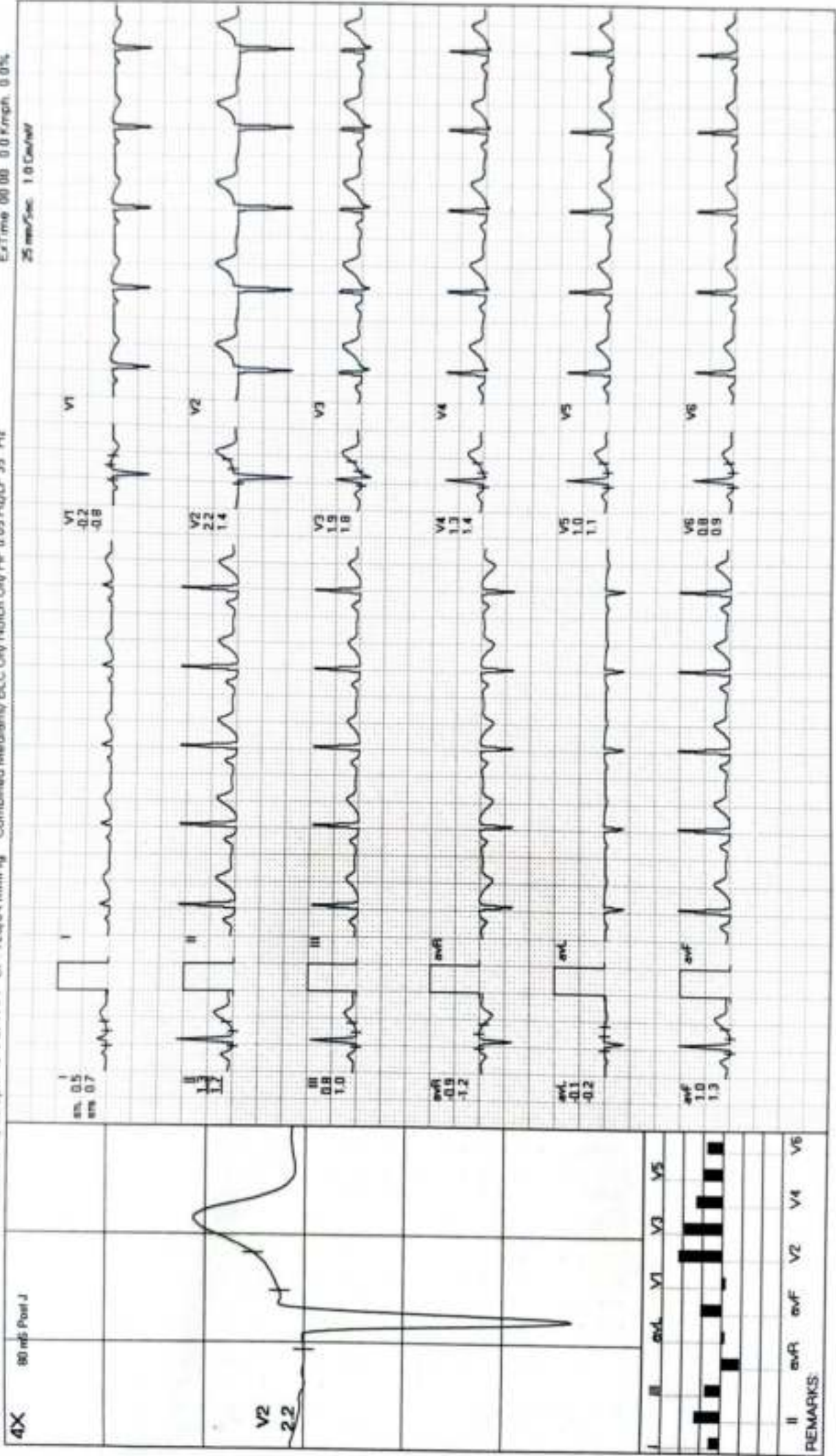
BRUCE:HV(0:07)



Date: 25-11-2023

METS: 1.0/90 bpm 49% of THR BP: 120/84 mmHg Combined Medians/EKG On/Notch On/HF 0.05 Hz/LF 35 Hz

ExTime 00:00 0.0 Kmph 0.0%
25 mm/Sec 1.0 Cm/mV



MODERN PATHOLOGY AND DIAGNOSTIC CENTER

VINEET KUMAR / 35 Yrs / M / 173 Cms / 75 Kg / HR : 90

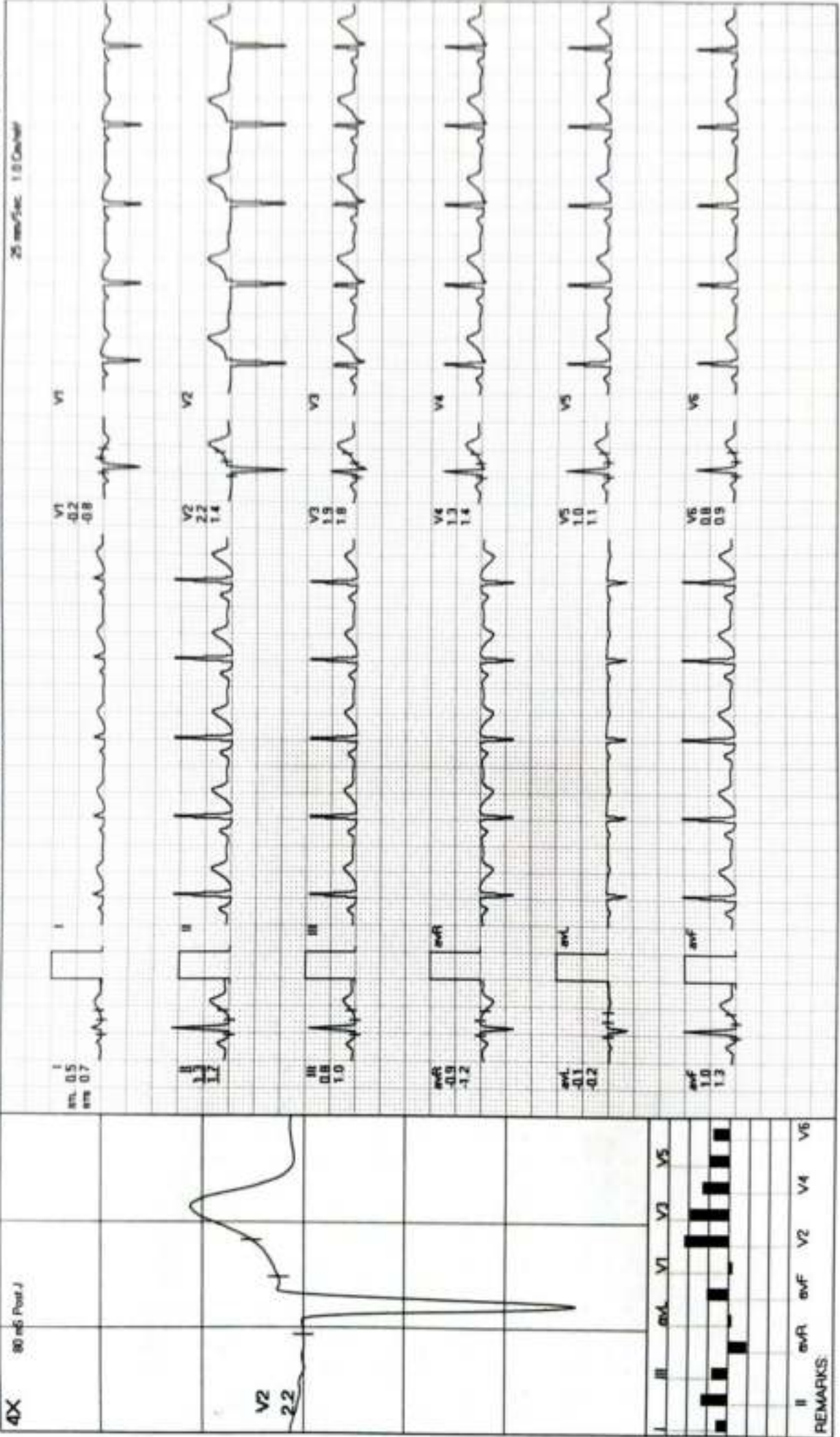
ExStart



Date 25-11-2023

METS 1.0/ 90 bpm 49% of THR BP- 120/84 mmHg Combined Medians/ BLC- On/ HF 0.05 Hz/ LF 35 Hz

ExTime 00:00 8.0 kmph 8.0%





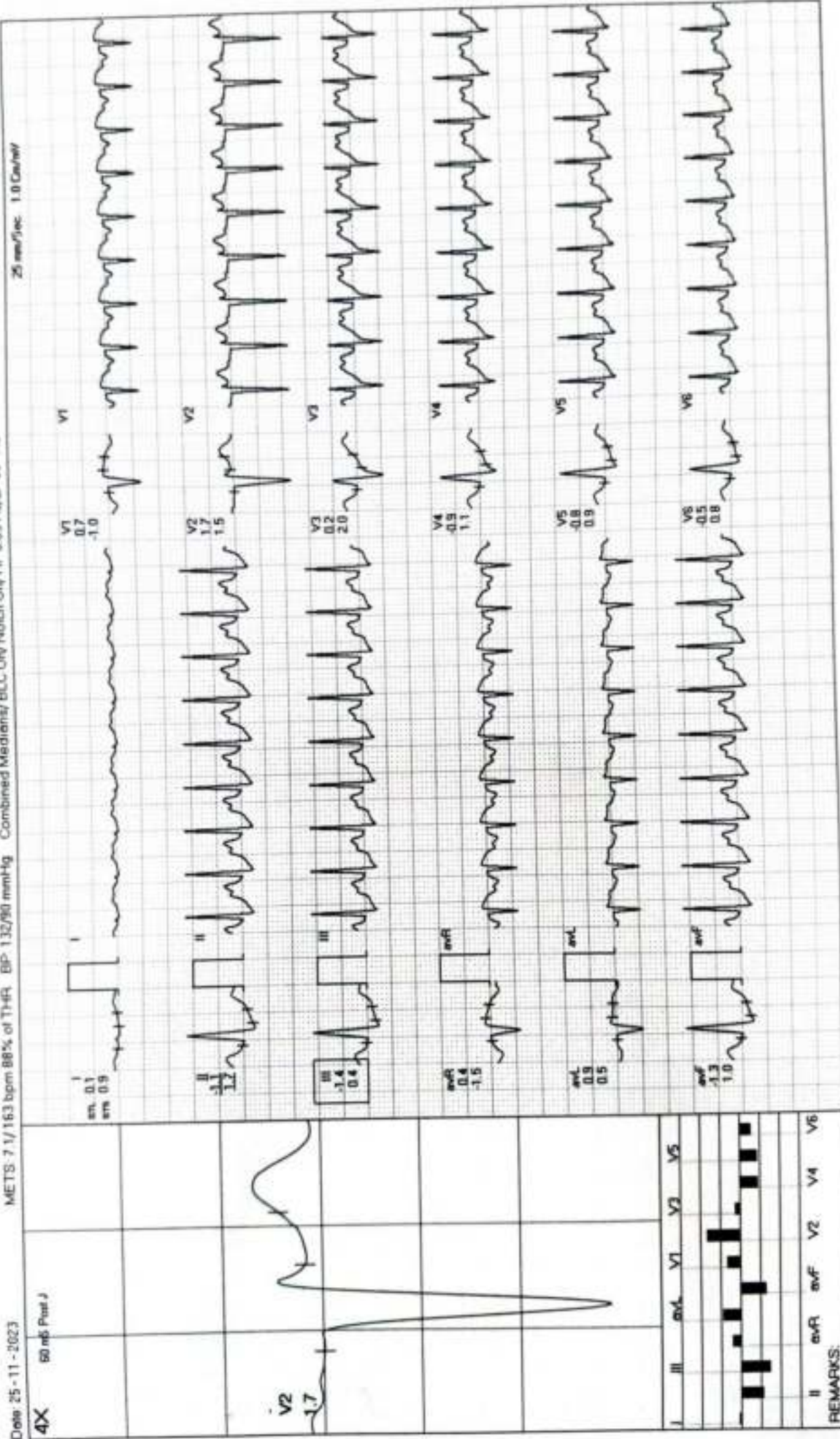
BRUCE: Stage 2(3:00)

MODERN PATHOLOGY AND DIAGNOSTIC CENTER

VINEET KUMAR / 35 Yrs / M / 173 Cms / 75 Kg / HR : 163

Ex Time 05:00 4.0 Kmph. 12.0%

Date: 25-11-2023 METS: 7.1/163 bpm 88% of THR BP: 132/90 mmHg Combined Medians/ BLC On/ HF 0.95 Hz/LF 35 Hz




MODERN PATHOLOGY AND DIAGNOSTIC CENTER

VINEET KUMAR / 35 Yrs / M / 173 Cms / 75 Kg / HR : 164

PeakEx



Date: 25-11-2023 METS: 7.2/164 bpm 89% of THR BP: 142/96 mmHg Combined Medications/ BLC On/ Notch On/ HF 0.05 Hz/LF 35 Hz



REMARKS:

MODERN PATHOLOGY AND DIAGNOSTIC CENTER

VINEET KUMAR / 35 Yrs / M / 173 Cms / 75 Kg / HR : 129

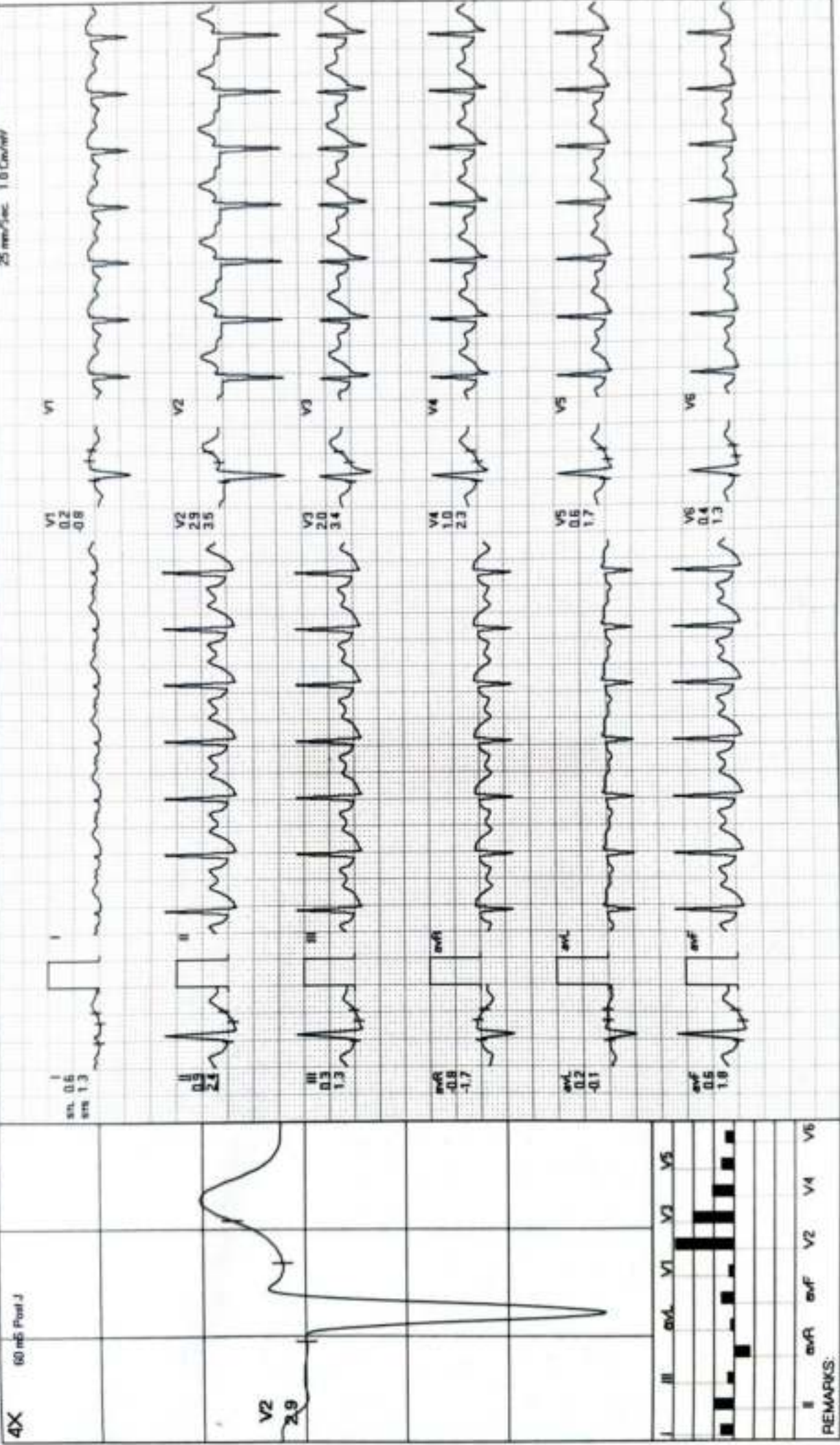
Recovery(1:00)



Date: 25-11-2023 METS: 1.1/129 bpm 70% of THR BP: 140/92 mmHg Combined Mediens/BLC On/ HF 0.05 Hz/LF 35 Hz

ExTime: 06:05 0.0 Kmph 0.0%

25 mm/sec 1.0 Cm/mV



REMARKS:

MODERN PATHOLOGY AND DIAGNOSTIC CENTER

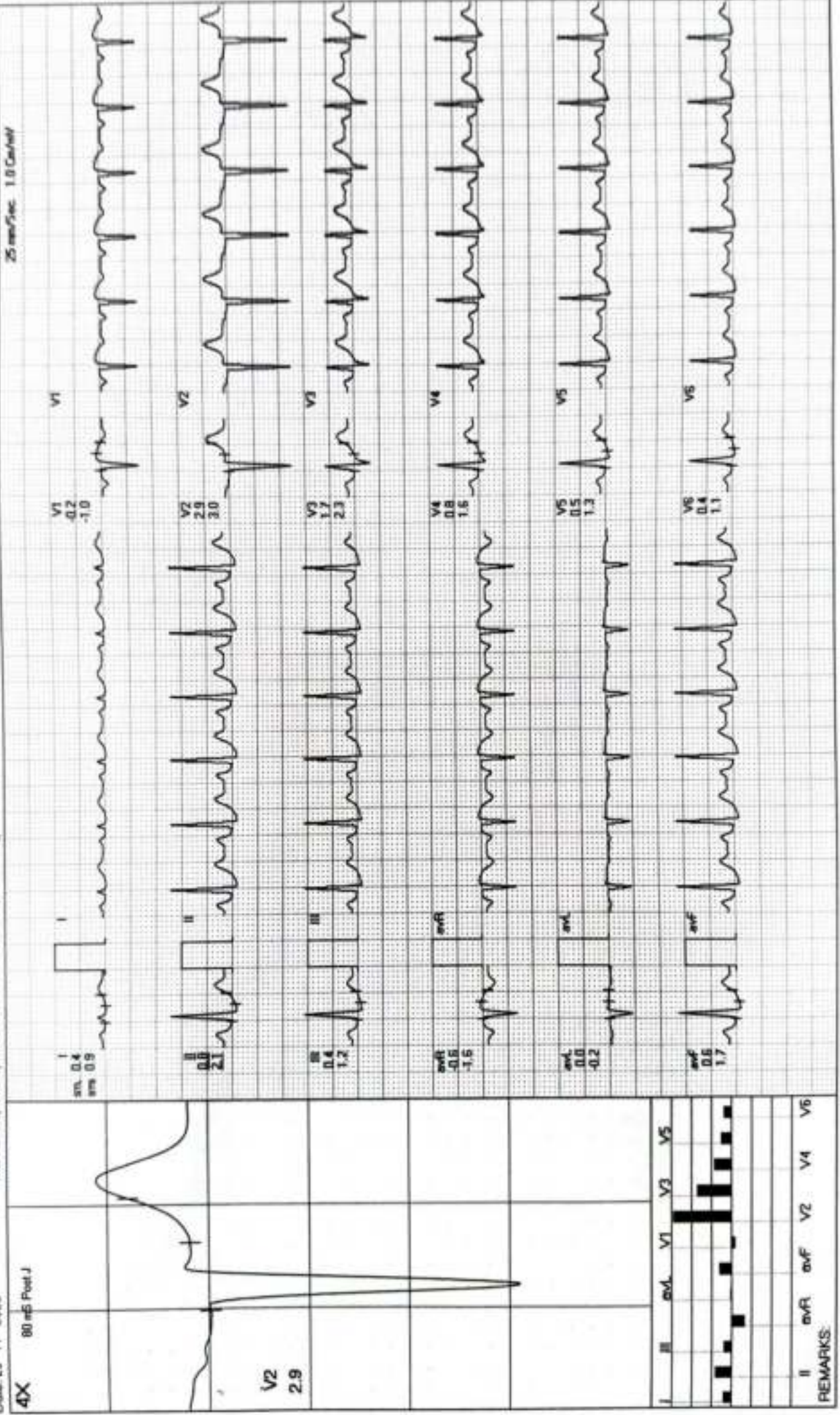
VINEET KUMAR / 35 Yrs / M / 173 Cms / 75 Kg / HR : 115

Recovery(2:00)



ExTime 06:05 0.0 Kmph, 0.0%

METS: 1.0 | 115 bpm 62% of THR BP: 136/90 mmHg Combined Meds: BLOC On/ HF 0.05 Hz/ LF 35 Hz



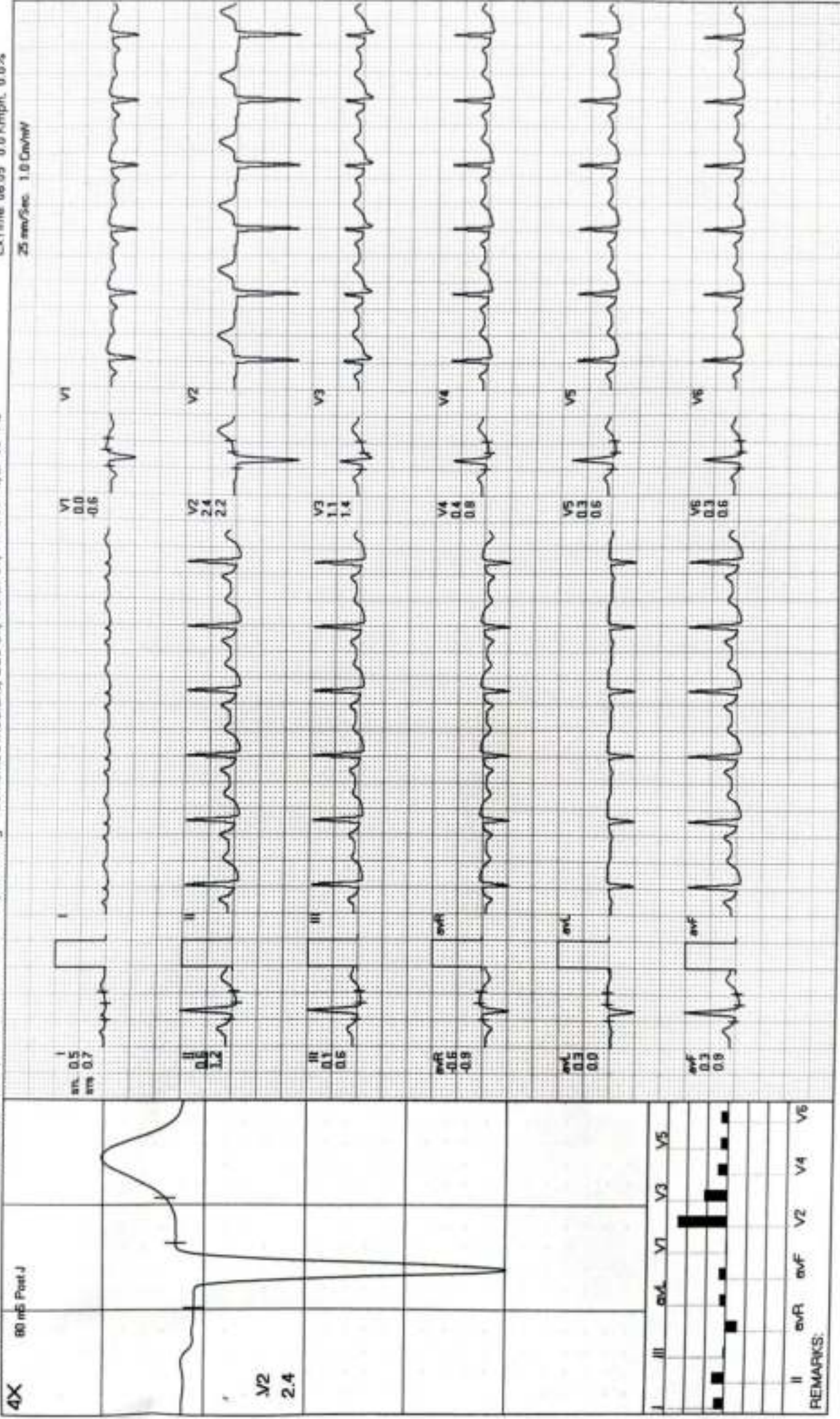
MODERN PATHOLOGY AND DIAGNOSTIC CENTER

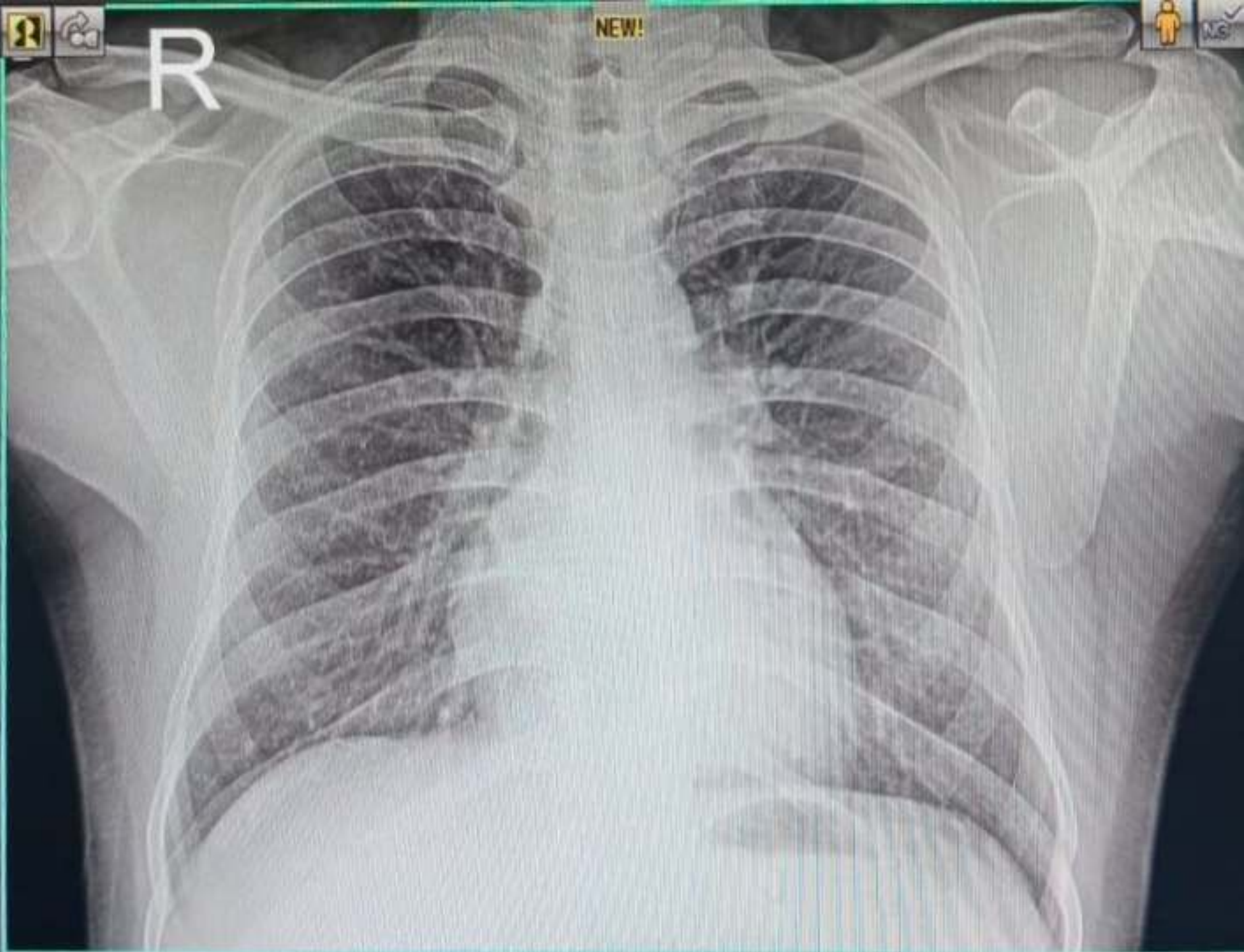
VINEET KUMAR / 35 Yrs / M / 173 Cms / 75 Kg / HR : 108

Recovery(3:00)



Date: 25-11-2023 METS: 1.0/108 bpm 56% of THR BP: 130/86 mmHg Combined Medians/ BLC-On/ Notch-On/ HF 0.05 Hz/ LF 35 Hz ExTime 06:05 0.0 Kmph. 0.0%





23112502651 MR VINEET KUAMR 35 YRS M DR SELF CHEST PA
11/25/2023 MODERN PATHOLOGY & DIAGNOSTIC CENTRE GOMTI NAGAR LUCKNOW