

HOS 260633
RES 261633

GULATI HOSPITAL

169, Sarojini Colony, Near Bus Stand,
YAMUNA NAGAR - 135 001

Dr. J.K. Gulati

M.D., D.N.B. (AIIMS, New Delhi)
Consultant Physician & Heart Specialist

Dr. Sarita Gulati

D.G.O., DCH (Gynaecologist)
Ex. SMO, Civil Hospital, YNR.

MEDICAL EXAMINATION

I have examined Mr. Divyansh for today and his particulars are given below

No h/o Cough / Expectoration/ Breathlessness/ Pain Chest

No evidence of Anaemia/ Cyanosis/ Jaundice/ Edema

Pulse - 84/mt

BP - 110/80mmhg

Age - 27yrs

No Abnormality Detected

DR. J.K. GULATI
MD, DNB
GULATI HOSPITAL
Near Bus Stand, Yamuna Nagar

भारत सरकार
Government of India

दिव्यांश
Divyansh
जन्म तिथि/DOB: 08/10/1995
पुरुष/ MALE

Download Date: 10/09/2020

Issue Date: 29/02/2020

2628 8521 3422
VID : 9154 8210 6502 9818
मेरा आधार, मेरी पहचान

Divyansh

भारतीय विशिष्ट पहचान प्राधिकरण
Unique Identification Authority of India

पता:
S/O: Umesh Kumar Dua, हाउस नं 248-ए, वार्ड नं 29,
गान्धी धाम जगधरी, जगधरी, यमुना नगर,
हरियाणा - 135001

Address:
S/O: Umesh Kumar Dua, house no 248-
A, ward no 29, gandhi dham jagadhri,
jagadhri, Yamuna Nagar,
Haryana - 135001

2628 8521 3422
VID : 9154 8210 6502 9818

1947 | help@uidai.gov.in | www.uidai.gov.in

Dr. J.K. Gulati

DR. J.K. GULATI
MD, DNB
GULATI HOSPITAL
Near Bus Stand, Yamuna Nagar



K.V. CLINICAL COMPUTERISED LABORATORY

GULATI HOSPITAL

Equipped with Latest Computerised Analyzer (CBA-300)

169, Sarojini Colony, Phase-I, YAMUNA NAGAR - 135 001

NAME MR. DIVYANSH AGE:-27/Yrs DATE 11.03.2023

BLOOD PROFILE

TEST	RESULT	NORMAL VALUE
B.SUGAR-F	88.0mg/dl	60-110mg/dl
B. Sugar-PP	100.0mg/dl	70-140mg/dl
BLOOD GROUP	'AB'+VE	
S.CREATININE	1.0mg%	0.1 -1.5mg%
B.U N	18.0mg%	10-20mg%
S. Uric Acid	5.0mg%	3.0-7.0mg%
S. BILIRUBIN	0.5 mg%	0.2- 1.0mg%
DIRECT	0.1 mg%	0.0 -0.2 mg%
INDIRECT	0.4mg%	0.1 - 1.0 mg%
SGOT	35 IU/L	5-40 IU/L
SGPT	32 IU/L	5 -35 IU/L
GGTP	45 IU/L	M 11-49U/L F 7-32 U/L
HBA1C	5.0%	<6%
Alkaline Phosphatate	185.0 U/L	70-270 U/L
TOTAL PROTEINS	7.05gm/dl	5.5 - 8.0 gm/dl
ALBUMIN	4.0 gm/dl	3.5 -5.5 gm/dl
GLOBULIN	3.0 gm/dl	2.5 -3.5 gm/dl
A:G Ratio	1:33	1:0-1:7
TOTAL CHOLESTROL	195mg%	(130- 200)
L D L	131mg%	< 150)
H D L	40 mg%	(30 - 55)
V L D L	24mg%	(5- 35)
TRIGLYCERIDES	120mg%	(65- 170)
CHOLESTROL / HDL RATIO	4.8	

DR. J.K. GULATI
MD, DNB
GULATI HOSPITAL
Near Bus Stand, Yamuna Nagar

Lab Incharge



K.V. CLINICAL COMPUTERISED LABORATORY

GULATI HOSPITAL

Equipped with Latest Computerised Analyzer (CBA-300)

169, Sarojini Colony, Phase-I, YAMUNA NAGAR - 135 001

MR. DIVYANSH

AGE:- 27 /MALE

DATE 11.03.2023

TEST NAME

RESULTS

UNITS

BIO.REF.INTERVAL

THYROID PROFILE, TOTAL, SERUM

(CLIA)

T3.TOTAL

0.85

ng/mL

0.60-1.81

T4.TOTAL

5.45

ug/dL

5.01-12.45

TSH

3.21

uIU/mL

0.35-5.50

DR. J.K. GULATI
MD, DNB
GULATI HOSPITAL
Near Bus Stand, Yamuna Nagar

Lab Incharge



K.V. CLINICAL COMPUTERISED LABORATORY
GULATI HOSPITAL

Equipped with Latest Computerised Analyzer (CBA-300)
169, Sarojini Colony, Phase-I, YAMUNA NAGAR - 135 001

NAME: MR. DIVYANSH

AGE/SEX:-27/M

DATE: 11/03/2023

VITAMIN D ASSAY

TEST	RESULT	UNIT	INTERPRETATION
VITAMIN D	42.00	Ng/ml	Deficiency:<20 ng/ml Insufficiency:20-29 ng/ml Sufficiency:30-100 ng/ml Toxicity: >100 ng/ml

DR. J.K. GULATI
MD, DNB
GULATI HOSPITAL
Near Bus Stand, Yamuna Nagar

Lab Incharge



K.V. CLINICAL COMPUTERISED LABORATORY

GULATI HOSPITAL

Equipped with Latest Computerised Analyzer (CBA-300)

169, Sarojini Colony, Phase-I, YAMUNA NAGAR - 135 001

Patient's Name MR.DIVYANSH

Age/Sex: 27/M

Advised By Dr. J.K. Gulati MD.

Date: 11-03-2023

INVESTIGATION	REPORT	NORMAL
---------------	--------	--------

URINE EXAMINATION

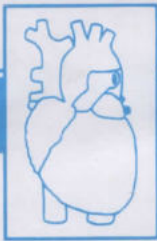Reaction (PH)	Acidic	Acidic
Albumin	Nil	Nil
Sugar	Nil	Nil
Specific gravity	1021	1008-1025

MICROSCOPI EXAM

Pus cell	Nil	/HPF
RBCs	Nil	/HPF
Epithelial Cell	Nil	/HPF
Crystals	Nil	/HPF
Casts	Nil	/HPF
Any other findings	Nil	/HPF

DR. J.K. GULATI
MD, DNB
GULATI HOSPITAL
Near Bus Stand, Yamuna Nagar

Lab Incharge



GULATI HOSPITAL

169, Sarojini Colony, Near Bus Stand,
YAMUNA NAGAR - 135 001

Dr. J.K. Gulati

M.D., D.N.B. (AIIMS, New Delhi)
Consultant Physician & Heart Specialist

Dr. Sarita Gulati

D.G.O. DCH (Gynaecologist)
Ex SMO, Civil Hospital, YNR

ULTRASONOGRAPHY (WHOLE ABDOMEN)

NAME MR DIVYANSH AGE & SEX 27 M 11.03.23

LIVER - Liver size is normal and it shows normal echopattern with normal vasculature and normal intrahepatic biliary radical pattern. No mass lesion seen.

GALL BLADDER -It shows normal echopattern with normal smooth wall. No evidence of hyperechoic shadow or acoustic shadow is seen in the region.

CBD measures within normal limits.

PANCREAS -Part of head visualized- shows normal echo pattern. Rest-obscured by gases.

KIDNEYS- Both kidneys measure within normal limits with normal echogenic Pattern and well maintained corticomedullary distinction. No evidence of hydronephrotic change is seen. No calculus seen.

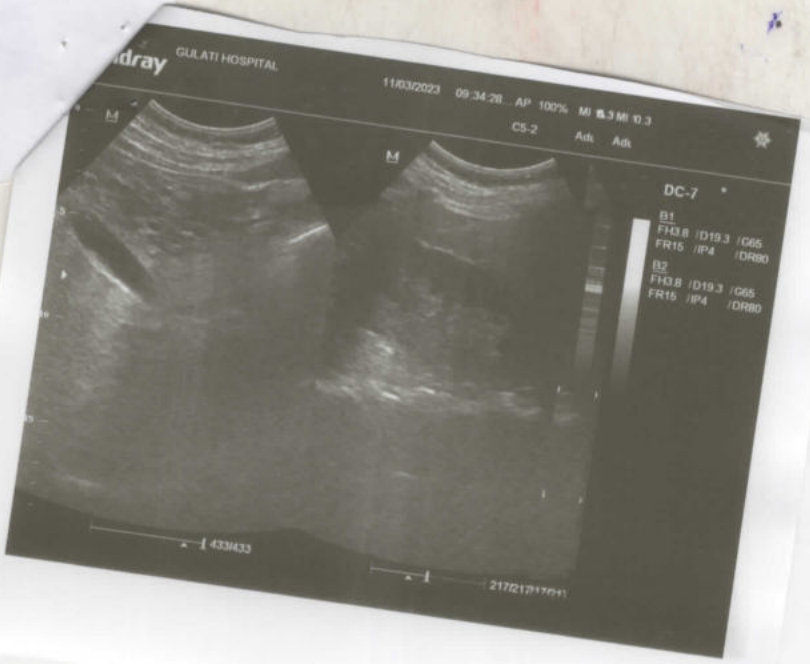
SPLEEN -No abnormal echoes detected from the splenic area.

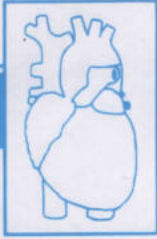
URINARY BLADDER -Bladder is well distended and has normal smooth wall. No mass lesion is seen

PROSTATE- It is normal in size.No abnormal echoes could be seen from it.
No free fluid seen in the peritoneal cavity.

CONCLUSION :- NO ABNORMALITY IN THE PRESENT STUDY.

DR. J.K. GULATI
MD, DNB
GULATI HOSPITAL
Near Bus Stand, Yamuna Nagar





GULATI HOSPITAL

169, Sarojini Colony, Near Bus Stand,
YAMUNA NAGAR - 135 001

Dr. J.K. Gulati

M.D., D.N.B. (AIIMS, New Delhi)
Consultant Physician & Heart Specialist
ECHOCARDIOGRAPHY

Dr. Sarita Gulati

D.G.O. DCH (Gynaecologist)
Ex SMO, Civil Hospital, YNR.

NAME MR DEVYANSH

AGE & SEX 27 M

DATED 11.03.23

M-MODE PARAMETERS

		Normal Values
Left Ventricular ED Dimension	4.8 cm	(3.7-5.6cm)
Left Ventricular ES Dimension	3.5 cm	(2.2-4.0cm)
Right Ventricular ED Dimension	2.1 cm	(0.7-2.6cm)
Inter Ven. Septum thickness (D)	1.0 cm	(0.6-1.1cm)
LV Posterior Wall thickness (D)	0.9 cm	(0.6-1.1cm)
Aortic root diameter	2.7 cm	(2.0-3.7cm)
Left Atrial Diameter	3.2 cm	(1.9-4.0cm)

INDICES OF LV SYSTOLIC FUNCTIONS (NORMAL VALUES)

Ejection Fraction	60 %	(54-76%)
Fractional Shortening	35 %	(25-46%)

MITRAL VALVE ↓

Thin, and it moves posteriorly during diastole. No subvalvular pathology, no anterior leaflet pathology, no prolapsed or flutter or systolic anterior motion

TRICUSPID VALVE

Valve is normal looking, no prolapse is seen

AORTIC VALVE

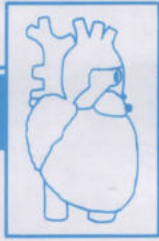All three cusps seen, opens fully during systole with central closure

PULMONARY VALVE

Thin opens well, Pulmonary Artery not dilated

LEFT VENTRICLE

No hypertrophy, Chamber slightly dilated No segmental wall motion abnormality



GULATI HOSPITAL

169, Sarojini Colony, Near Bus Stand,
YAMUNA NAGAR - 135 001

Dr. J.K. Gulati

M.D., D.N.B. (AIIMS, New Delhi)
Consultant Physician & Heart Specialist

Dr. Sarita Gulati

D.G.O., DCH (Gynaecologist)
Ex SMO, Civil Hospital, YNR.

PULSE & CONTINUOUS WAVE DOPPLER

No mitral regurgitation.
No aortic regurgitation.
No Tricuspid regurgitation .
No pulmonary regurgitation.
Predicted PA pressure (S)=25MM of Hg

COLOUR FLOW IMAGING

No Mitral regurgitation.
No aortic regurgitation.
No tricuspid regurgitation.
No pulmonary regurgitation.

COMMENTS

No LA, LAA, LV CLOT seen.
No vegetation on any valve
No intra cardiac mass.
Pericardial effusion.
IAS, IVS intact.

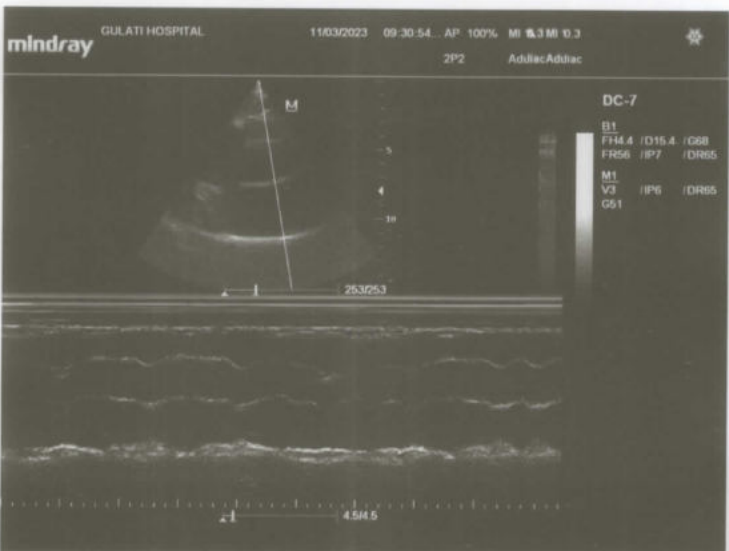
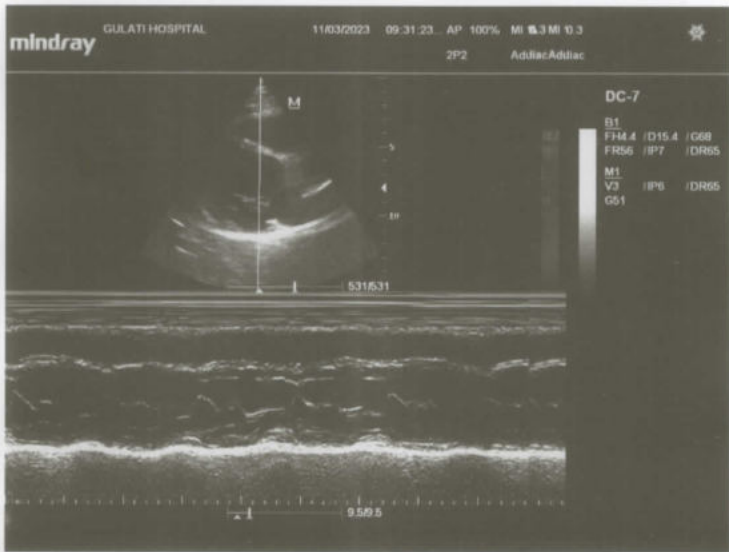
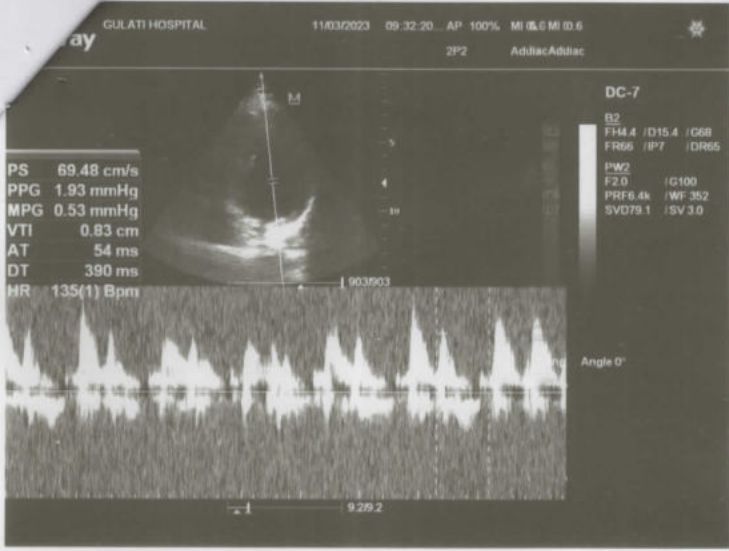
IMPRESION:- Echocardiography Findings are suggestive of

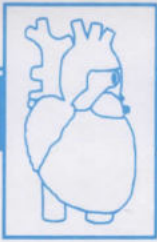Normal systolic and normal diastolic Functions

No Evidence of Hypertrophy

Dr J K Gulati MD, DNB (Medicine)

DR. J.K. GULATI
MD, DNB
GULATI HOSPITAL
Near Bus Stand, Yamuna Nagar





GULATI HOSPITAL

169, Sarojini Colony, Near Bus Stand,
YAMUNA NAGAR - 135 001

Dr. J.K. Gulati

M.D., D.N.B. (AIIMS, New Delhi)
Consultant Physician & Heart Specialist

Dr. Sarita Gulati

D.G.O., DCH (Gynaecologist)
Ex. SMO, Civil Hospital, YNR.

X - RAY Chest PA

Date:- 11/03/2023

Name:-Mr.Divyansh

Age /Sex:-27 Y/M

Skin and soft tissue normal


Bony and skeleton normal

Trachea is central

Mediastinum is normal

Heart size and shape Normal

No Abnormality

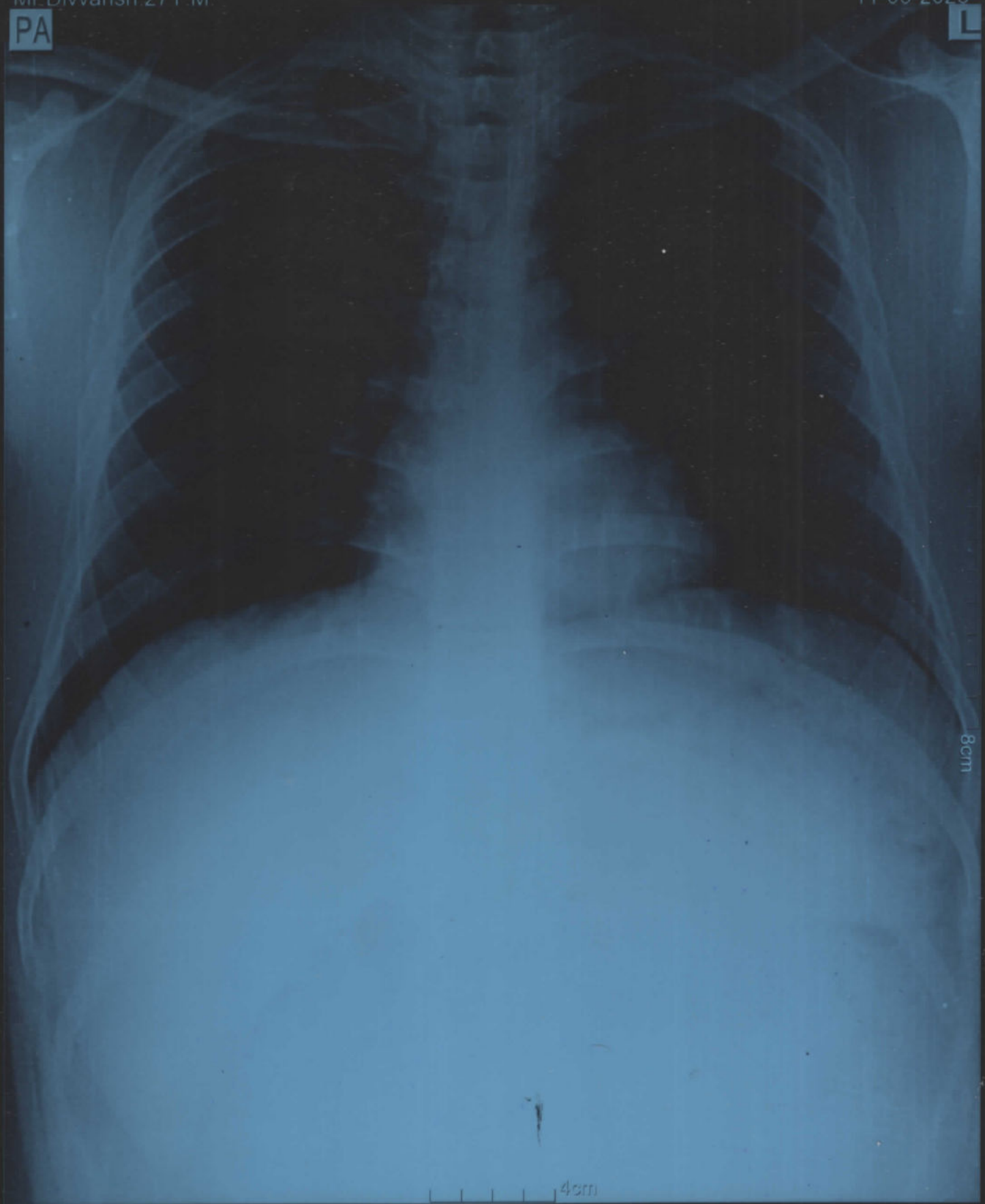

DR. J.K. GULATI
MD, DNS
GULATI HOSPITAL
Near Bus Stand, Yamuna Nagar

Mr. Divvansh 27Y M.

11-03-2023

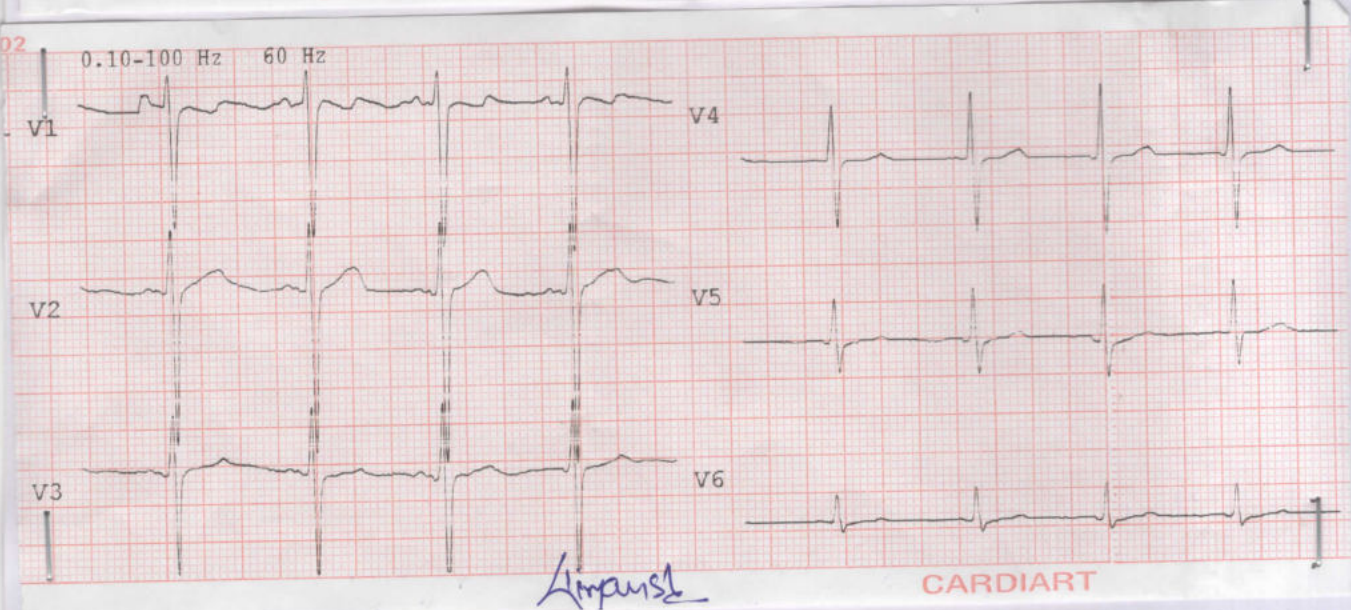
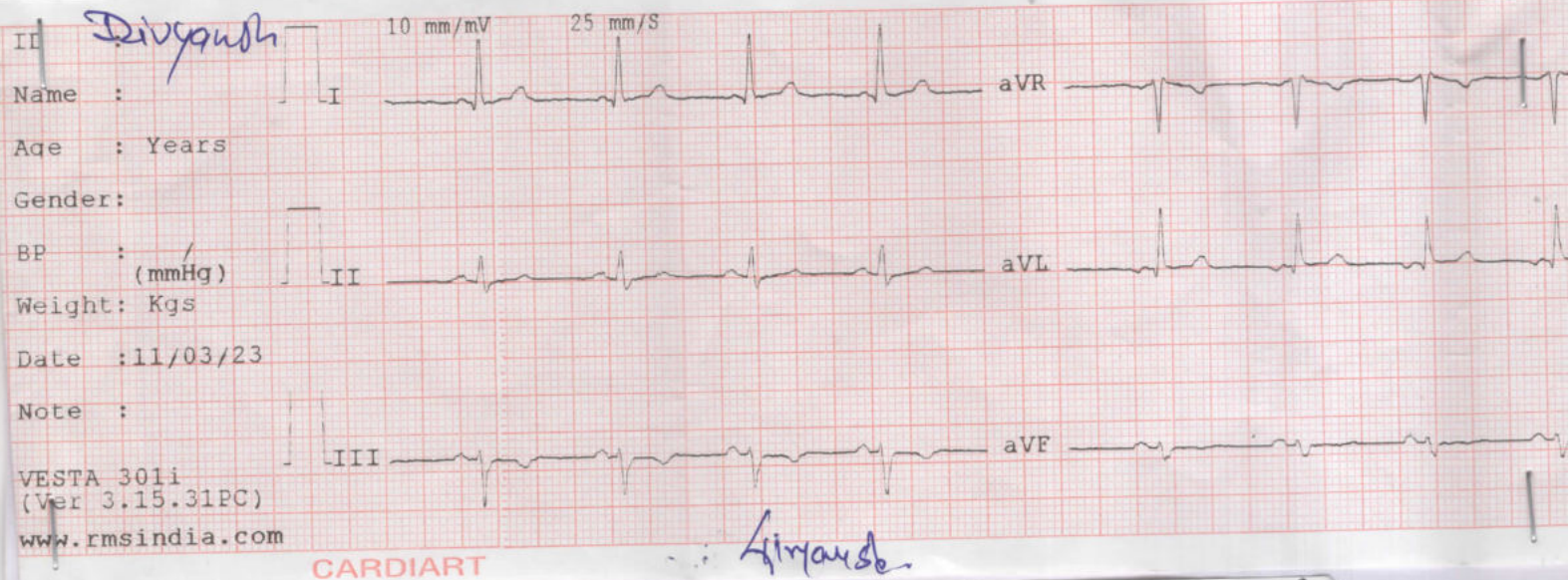
PA

L



Gulati Hospital Near Bus Stand Yamuna Nagar

Divyansh



ECG REPORT:-Within Normal Limits

Amrinder
Signature

DR. J.K. GULATI
MD, DNB
GULATI HOSPITAL
Near Bus Stand, Yamuna Nagar