



# Bangalore Diagnostics & Multi-Speciality Centre

Quality Assurance : EQAP from AIIMS & CMC- Vellore

Quality. Trust. Since 1982.

# 198, 12th Main, 3rd Block, (Above Namma MTR, Next to SBI), Rajajinagar, Bangalore- 560 010.

Ph. : 080-23505407, 9448079978 e-mail : bangalore.d.s@gmail.com

**Name :** MRS. C.M.CHANDRAMMA

**Reg. No :** C7221

**Age/Sex:** 59 Year(s) / Female

**Date :** 25/06/2022

**Ref. by :** DR. BANK OF BARODA

**Corporate:** NON CORPORATE

Test Name

Result

Reference Range

Page 1 of 4

## HAEMATOLOGY REPORT

BLOOD GROUP(ABO)

"A"

Rh Type (D)

NEGATIVE

### **COMPLETE BLOOD COUNT**

Haemoglobin

13.8 gms %

Male : 13.0 - 18.0 gms %

Female: 11.0 - 15.0 gms %

Red Blood Cell Count

4.53 million/cumm

Male : 4.5-6.5 millions/cumm

Female : 3.7-5.5 million/cumr

Packed Cell Volume

38.7 %

Females: 32 - 45 %

Males: 39 - 54%

Total Count

5,300 cells /cumm

4000-11000 cells /cumm

### **Differential Count**

Neutrophils

50.6 %

40 - 75%

Lymphocytes

38.0 %

20 - 45%

Monocytes

7.9 %

01 - 10%

Eosinophils

3.0 %

01 - 06 %

Basophils

0.5 %

00 to 01 %

### **COMPLETE BLOOD COUNT**

Platelet count

2,67,000 cells/cumm

150000-400000 cells/cumm

Mean Corpuscular Volume

85 fL

78 - 98 fL

Mean Corpuscular Heamoglobin

30.3 pg

27 - 32 pg

Mean Corpuscular Haemoglobin Concentration

35.5 g/dl

31 - 36 g/dl

ESR

04 mm/hour

Male: 0 - 10 mm/ hour

Female: 0 - 20 mm/hour

ABSOLUTE EOSINOPHIL COUNT

160 cells/cumm

40 - 440 cells/cumm

## BIOCHEMISTRY REPORT

FASTING BLOOD SUGAR

89 mg/dl

70 to 100 mg/dl

FASTING URINE SUGAR

NIL

NIL

Dr. MAHADEVA. K.C.  
M.D., (Path)  
KMC. No.1 17647



# Bangalore Diagnostics & Multi-Speciality Centre

Quality Assurance : EQAP from AIIMS & CMC- Vellore

Quality. Trust. Since 1982.

# 198, 12th Main, 3rd Block, (Above Namma MTR, Next to SBI), Rajajinagar, Bangalore- 560 010.

Ph. : 080-23505407, 9448079978 e-mail : bangalore.d.s@gmail.com

**Name :** MRS. C.M.CHANDRAMMA

**Reg. No :** C7221

**Age/Sex:** 59 Year(s) / Female

**Date :** 25/06/2022

**Ref. by :** DR. BANK OF BARODA

**Corporate:** NON CORPORATE

Test Name

Result

Reference Range

Page 2 of 4

## BIOCHEMISTRY REPORT

POST PRANDIAL BLOOD SUGAR 99 mg/dl 80 to 140 mg/dl

POST PRANDIAL URINE SUGAR NIL NIL

### **Glycosylated Haemoglobin (HbA1c)**

Glycosylated Haemoglobin (HbA1c) 6.3 %  
Normal <6.0 %  
Good control 6.0-7.0 %  
Fair control 7.0-8.0 %  
Unsatisfactory 8.0-10.0 %  
Poor control >10 %

### **LIPID PROFILE**

TOTAL CHOLESTEROL 219.3 mg/dl up to 200 mg/dl  
TRIGLYCERIDES 108.9 mg/dl <150 : Normal  
HDL Cholesterol 43.2 mg/dl Male: >40 mg/dl  
Female: > 50 mg/dl  
LDL Cholesterol 154.4 mg/dl <100 mg/dl  
VLDL Cholesterol 21.7 mg/dl <40 mg/dl  
CHOLESTEROL/HDL RATIO 5.1:1.0 up to 6.0 %

### **LIVER FUNCTION TESTS**

Total Bilirubin 0.87 mg/dl up to 1.2 mg/dl  
Direct Bilirubin 0.14 mg/dl 0 to 0.3 mg/dl  
Indirect Bilirubin 0.73 mg/dl up to 1.5 mg/dl  
S.G.O.T. (AST) 13.8 U/L 0 - 46 U/L  
S.G.P.T. (ALT) 11.1 U/L 0 - 49 U/L  
ALKALINE PHOSPHATASE 63.0 U/L  
Men : 80-306  
Women : 64-306  
Children upto 15 Yrs : upto 644  
Children upto 17 yrs : upto 483  
Gamma Glutamyl Transpeptidase (GGT) 15.8 IU/L 0 - 55 IU/L  
Total Protein 7.5 gms/dl 6.6 - 8.3 gms/dl  
Albumin 3.8 gms/dl 3.4 - 5.0 gms/dl  
Globulin 3.7 gms/dl 2.3 - 3.5 gms/dl  
A/G Ratio 1.0:1.0 1.2 : 1.0

*Keablew*

Dr. MAHADEVA. K.C.  
M.D., (Path)  
KME: No: 17647



# Bangalore Diagnostics & Multi-Speciality Centre

Quality Assurance : EQAP from AIIMS & CMC- Vellore

Quality. Trust. Since 1982.

# 198, 12th Main, 3rd Block, (Above Namma MTR, Next to SBI), Rajajinagar, Bangalore- 560 010.

Ph. : 080-23505407, 9448079978 e-mail : bangalore.d.s@gmail.com

**Name :** MRS. C.M.CHANDRAMMA

**Reg. No :** C7221

**Age/Sex:** 59 Year(s) / Female

**Date :** 25/06/2022

**Ref. by :** DR. BANK OF BARODA

**Corporate:** NON CORPORATE

Test Name

Result

Reference Range

Page 3 of 4

## BIOCHEMISTRY REPORT

UREA	16.7 mg/dl	10 to 45 mg/dl
BLOOD UREA NITROGEN (BUN)	7.80 mg/dl	7-18 mg/dl
URIC ACID	4.34 mg/dl	M: 3.5 -7.2 mg/dl F: 2.6 - 6.0 mg/dl
SERUM CREATININE	0.86 mg/dl	Females 0.6 - 1.2 mg/dl Males 0.7 - 1.4 mg/dl
SERUM PHOSPHORUS	3.12 mg/dl	2.1 to 5.6 mg/dl

## URINE EXAMINATION REPORT

### **PHYSICAL EXAMINATION**


COLOUR	LIGHT YELLOW
APPEARANCE	CLEAR
REACTION	ACIDIC

### **BIOCHEMICAL EXAMINATION**

PROTEIN	NIL	
GLUCOSE	NIL	
BILE SALT	NIL	
BILE PIGMENT	NIL	
SPECIFIC GRAVITY	1.018	1.003 - 1.035

### **MICROSCOPIC EXAMINATION**

PUS CELLS	1-2/HPF
EP CELLS	2-3/HPF
MACROPHAGES	NIL
R.B.C.s	ABSENT
CASTS	NIL

  
Dr. MAHADEVA. K.C.  
M.D., (Path)  
KMC. No.: 17647



# Bangalore Diagnostics & Multi-Speciality Centre

Quality Assurance : EQAP from AIIMS & CMC- Vellore

Quality. Trust. Since 1982.

# 198, 12th Main, 3rd Block, (Above Namma MTR, Next to SBI), Rajajinagar, Bangalore- 560 010.

Ph. : 080-23505407, 9448079978 e-mail : bangalore.d.s@gmail.com

**Name :** MRS. C.M.CHANDRAMMA

**Reg. No :** C7221

**Age/Sex:** 59 Year(s) / Female

**Date :** 25/06/2022

**Ref. by :** DR. BANK OF BARODA

**Corporate:** NON CORPORATE

Test Name

Result

Reference Range

Page 4 of 4

## URINE EXAMINATION REPORT

### **MICROSCOPIC EXAMINATION**

CRYSTALS


NIL

----- End of Report -----

**Biochemist**

**Microbiologist**

**Pathologist**

  
**Dr. MAHADEVA. K.C.**  
M.D., (Path)  
KMC. No.: 17647



**Name :** MRS. C.M.CHANDRAMMA

**Date :** 25/06/2022

**Age/Sex:** 59 Year(s) / Female

**Reg. No :** C7221

**Ref. by :** DR. BANK OF BARODA

**Corporate:** 0

Page 1 of 1

## **HAEMATOLOGY REPORT**

### **Peripheral Smear (P/S)**

R B C's are normocytic and normochromic with mild anisopoikilocytosis.

W B C's are normal in number, morphology and distribution.

PLATELETS are adequate in number.

Parasites/Abnormal cells are none evident.

IMPRESSION :: NORMOCYTIC NORMOCHROMIC BLOOD PICTURE.

----- End of Report -----

**Biochemist**

**Microbiologist**

**Pathologist**

Dr. MAHADEVA. K.C.  
M.D., (Path)  
KMC. No.: 17647



# Bangalore Diagnostics & Multi-Speciality Centre

PROCESSED AT:  
Thyrocare,

5CA-711, 3rd Floor,  
HRBR 2nd Block,

Hennur, Bengaluru-560043

Quality Assurance : EQAP from AIIMS & CMC- Vellore

Quality. Trust. Since 1982.

# 198, 12th Main, 3rd Block, (Above Namma MTR, Next to SBI), Rajajinagar, Bangalore- 560 010.

Ph. : 080-23505407, 9448079978 e-mail : bangalore.d.s@gmail.com

**NAME** : C M CHANDRAMMA (59Y/F)  
**REF. BY** : B O D LAB  
**TEST ASKED** : T3-T4-TSH

**SAMPLE COLLECTED AT :**  
BANGALORE DIAGNOSTIC CENTER

TEST NAME	TECHNOLOGY	VALUE	UNITS	REFERENCE RANGE
TOTAL TRIIODOTHYRONINE (T3)	C.L.I.A	92	ng/dl	60-200
TOTAL THYROXINE (T4)	C.L.I.A	7.47	µg/dl	4.5-12
THYROID STIMULATING HORMONE (TSH)	C.L.I.A	3.46	µIU/ml	0.3-5.5

**Comments :**

Please correlate with clinical conditions.

**Method :**

T3 - Competitive Chemi Luminescent Immuno Assay

T4 - Competitive Chemi Luminescent Immuno Assay

TSH - SANDWICH CHEMI LUMINESCENT IMMUNO ASSAY

-- End of report --

**Sample Collected on (SCT)** : 25 Jun 2022 12:00  
**Sample Received on (SRT)** : 25 Jun 2022 15:53  
**Report Released on (RRT)** : 25 Jun 2022 17:14  
**Sample Type** : SERUM  
**Labcode** : 2506074822/BAN03  
**Barcode** : Z2549210

Dr Syeda Sumaiya MD(Path)

Dr Ajeet Prajapati MD(Path)

Page : 1 of 2





**Abdomen And Pelvic Ultrasound Scan Report**

**Name : Mrs.Chandramma.C.M**

**Date:25/06/2022**

**Ref By : Bank Of Baroda**

**Age/ Gender: 59 Years/Female**

**Liver** : Normal in size, shape and increased echotexture. No focal lesion seen.

No intrahepatic biliary dilatation seen. PV & CBD is normal

**Gall Bladder:** GB is normal. Normal in wall thickness. No abnormal intraluminal echoes.

**Pancreas** : Normal in size and echo texture. No focal lesion, Pancreatic duct appears normal.

**Spleen** : Normal in size, shape and echo texture

**Kidneys** : Both kidney's are normal in size, shape and position.

No calculi / hydronephrosis seen. Corticomedullary differentiation is good.

**Right Kidney : 112 x 18 mm**      **Left kidney : 109 x 16 mm**

**Urinary Bladder:** Normal in contour and wall thickness with clear contents.

Post void = Nil.

**Uterus** : Anteverted, Measures 63 x 25 x 34 mm, normal in size, shape and echotexture. Endometrial thickness = 6 mm.POD is empty.

**Ovaries** : Both ovaries are visualized in adnexa, appears normal.

**IMPRESSION:**

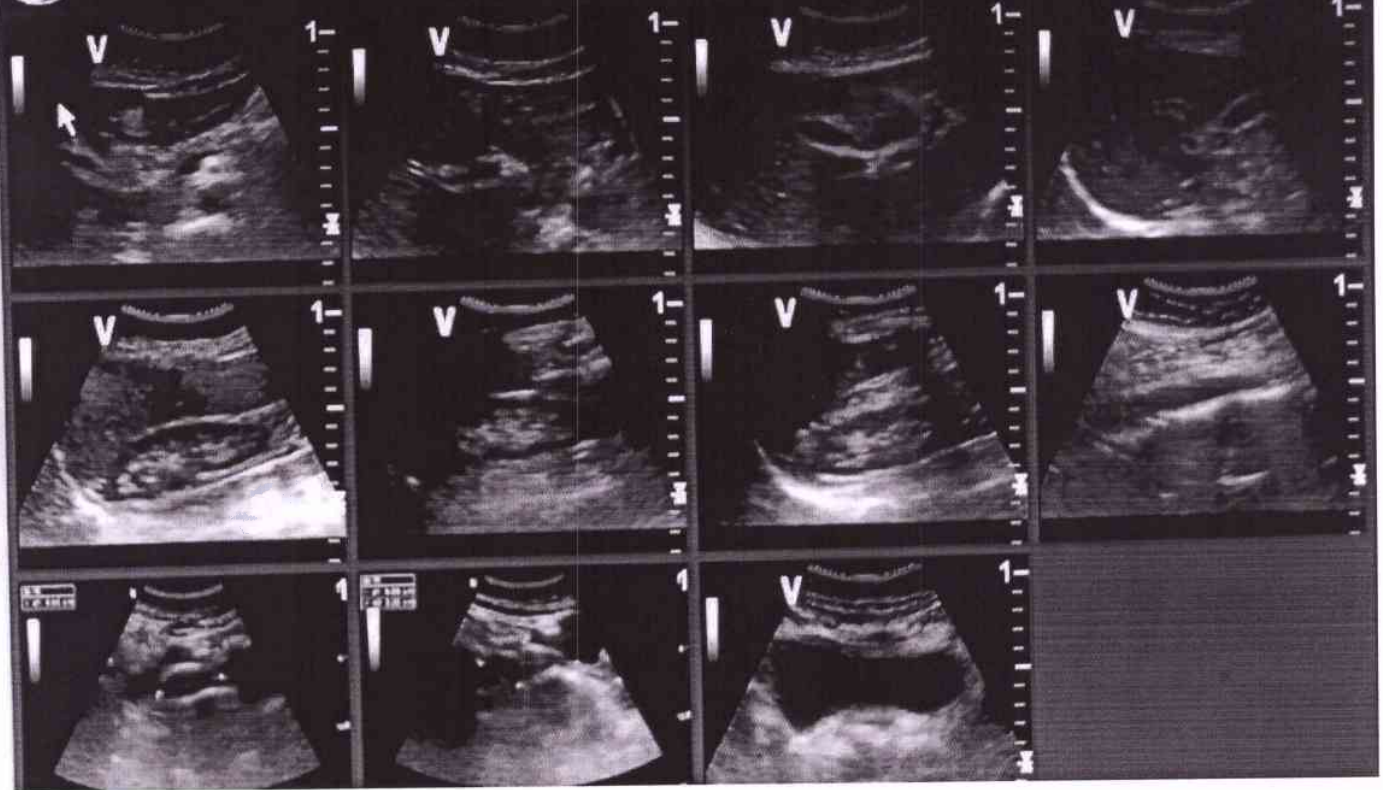- **NO SONOLOGIC ABNORMALITY IS EVIDENT.**

  
**Dr. Consultant Sonologist**



GE Healthcare  
25/06/22 12:39:48 PM

CHANDRAMMA 59 Y,  
ADM 25622-19B



BANGALORE DIAGNOSTICS &  
MULTI-SPECIALITY CENTRE  
# 198, 12th Main, 3rd Block  
Rajajinagar, Bangalore-560 010





### Echocardiography Report

**Name : Mrs. Chandramma .C.M**

**Date: 25/06/2022**

**Ref By : Bank of Baroda**

**Age/ Gender: 59Years/Female**

LA : 35 mm

MV : E 0.86 A : 0.90 m/sec

AO : 25 mm

AV : 1.87 m/sec

RVID : 19 mm

TV : 0.45 m/sec

LVIDD : 36 mm

PV : 0.90 m/sec

LVIDS : 24 mm

IVSD : 10 mm

MR : NIL

IVSS : 16 mm

AR : NIL

LVPWD : 11 mm

TR : NIL

LVPWS : 20 mm

PR : NIL

FS : 34.12 %

EF : 61.59 %

**LV mass : 169.70 gm**

#### IMPRESSION

- Normal Chamber Dimensions.
- No RWMA.
- Normal LV Systolic Function. LVEF 59%
- Normal Valves.
- Normal Color Flow Doppler Study.
- No Thrombus / PE.

  
**Dr. Consultant Cardiologist**

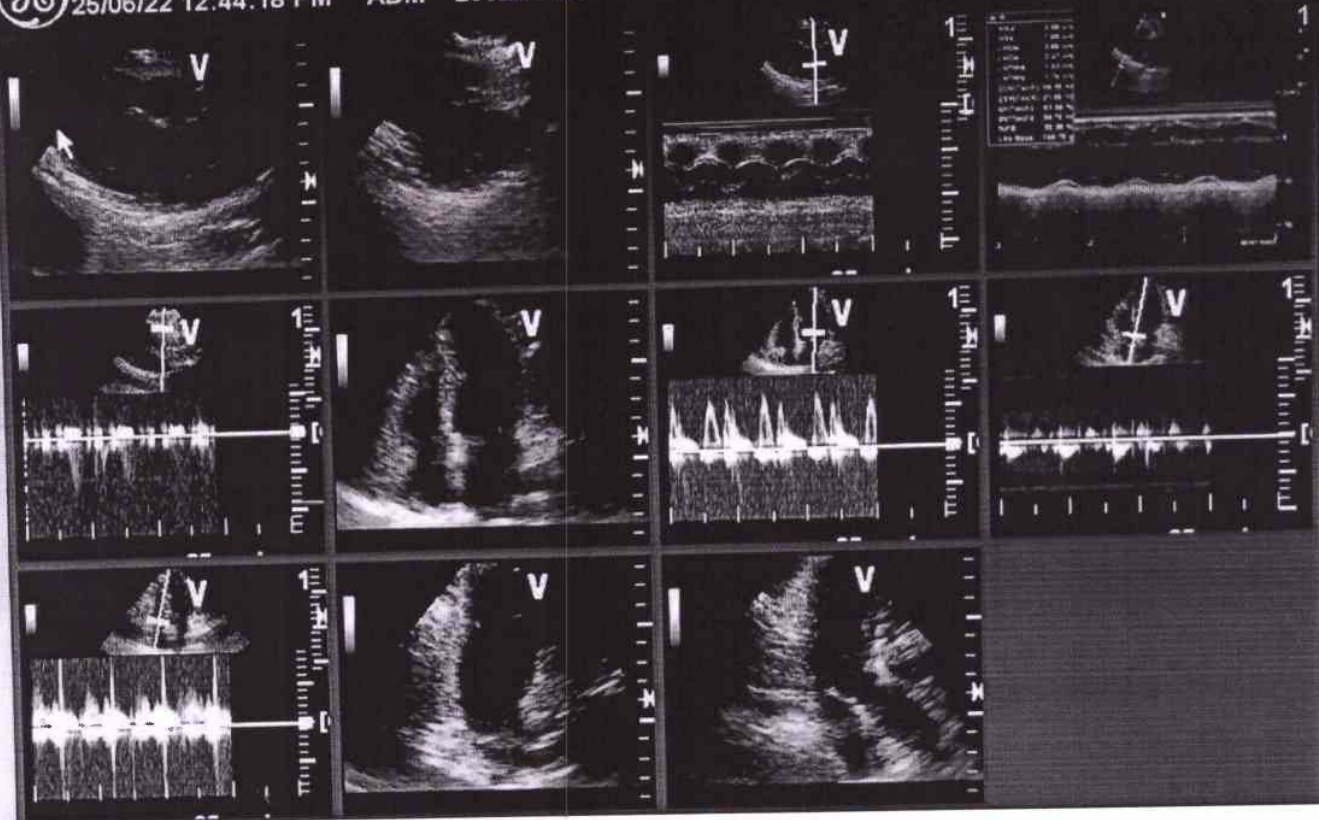
**BANGALORE DIAGNOSTICS &  
MULTI-SPECIALITY CENTRE**  
# 198, 12th Main, 3rd Block  
Rajajinagar, Bangalore-560 010



25/06/22 12:44:18 PM

ADM

CHANDRAMMA 59 Y,  
25622-19B



BANGALORE DIAGNOSTICS &  
MULTI-SPECIALITY CENTRE  
# 198, 12th Main, 3rd Block  
K. J. Somaiya Nagar, Bangalore-560 076



# Bangalore Diagnostics & Multi-Speciality Centre

Quality Assurance : EQAP from AIIMS & CMC- Vellore

Quality. Trust. Since 1982.

# 198, 12th Main, 3rd Block, (Above Namma MTR, Next to SBI), Rajajinagar, Bangalore- 560 010.  
Ph. : 080-23505407, 9448079978 e-mail : bangalore.d.s@gmail.com

## Breast Ultrasound Scan Report

Name : Mrs. Chandramma .C.M

Date: 25/06/2022

Ref By : Bank of Baroda

Age/ Gender: 59Years/Female

**Right Breast:** Shows normal echotexture of glandular and adipose soft tissue.

There is no evidence of Solid or Cystic Foci's

Nipple and Retroareolar regions appeared normal.

No ductal dilatation seen.

**Left Breast:** Shows normal echotexture of glandular and adipose soft tissue.

There is no evidence of solid or Cystic Foci's.

Nipple and Retroareolar regions appeared normal.

No ductal dilatation seen.

There is no evidence of enlarged lymphnode's seen.

### **IMPRESSION:**

➤ Normal Sonologic Study.

**BIRAD'S Score : I. ( Routine Screening)**

  
Dr. Consultant Radiologist

BANGALORE DIAGNOSTIC &  
MULTI-SPECIALITY CENTRE  
# 198, 12th Main, 3rd Block  
Rajajinagar, Bangalore-560 010



GE Healthcare

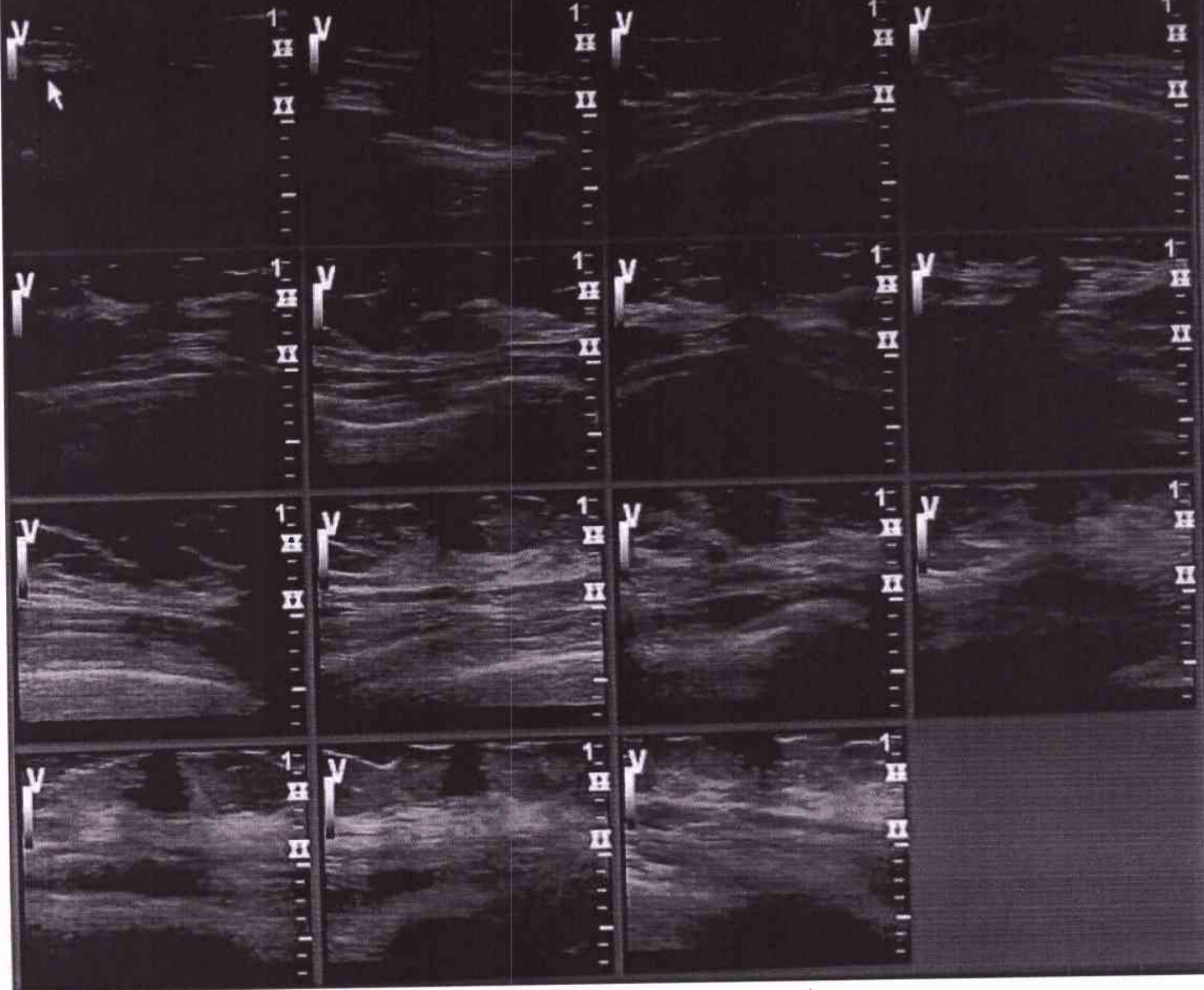
25/06/22 12:48:21 PM

ADM

CHANDRAMMA 59 Y,

25622-19B

---:---:---



BANGALORE DIAGNOSTICS &  
MULTI-SPECIALITY CENTRE  
# 198, 12th Main, 3rd Block  
Rajajinagar, Bangalore-560 010



# Bangalore Diagnostics & Multi-Speciality Centre

Quality Assurance : EQAP from AIIMS & CMC- Vellore

Quality. Trust. Since 1982.

# 198, 12th Main, 3rd Block, (Above Namma MTR, Next to SBI), Rajajinagar, Bangalore- 560 010.


Ph. : 080-23505407, 9448079978 e-mail : bangalore.d.s@gmail.com

<b>REG.NO :: C-7221</b>	<b>DATE :: 28/06/2022</b>
<b>NAME :: Mrs.C.M.CHANDRAMMA</b>	<b>AGE &amp; SEX :: 59 YRS;FEMALE</b>
<b>REF.BY :: BANK OF BARODA</b>	

## CYTOLOGY REPORT

<b>NATURE OF SPECIMEN ::</b> Cervico-vaginal smear.	
<b>SPECIMEN ADEQUACY ::</b> Satisfactory for evaluation	
<b>GENERAL CATEGORISATION ::</b> With in normal limits	
<b>MICROSCOPY</b>	<b>::</b> Smears show low cellular yield of epithelial cells. The background is mucoid with no inflammatory cells. The epithelial cells identified are predominantly Parabasal cells with few superficial and intermediate cells and all are showing isodiametric nucleus.Plenty of endocervical cells in polypoidal configurations and in monolayered sheets identified.  There is no evidence of metaplastic/dysplastic cells/ Candidiasis/Trichomoniasis/cellular changes suggesting viral infection.
<b>EPITHELIAL CELL ABNORMALITIES ::</b> None evident.	
<b>HORMONAL EVALUATION ::</b> Maturation Index :: 50/20/30	
<b>IMPRESSION</b>	<b>::</b> POLYPOIDAL ENDOCERVICITIS. NEGATIVE FOR INTRAEPITHELIAL LESION.

**BANGALORE DIAGNOSTICS &  
MULTI-SPECIALITY CENTRE**  
# 198, 12th Main, 3rd Block  
Rajajinagar, Bangalore-560 010

  
**Dr. MAHADEVA. K.C.**  
M.D., (Path)  
KMC. No.: 17647





# Bangalore Diagnostics & Multi-Speciality Centre

Quality Assurance : EQAP from AIIMS & CMC- Vellore

Quality. Trust. Since 1982.

# 198, 12th Main, 3rd Block, (Above Namma MTR, Next to SBI), Rajajinagar, Bangalore- 560 010.  
Ph. : 080-23505407, 9448079978 e-mail : bangalore.d.s@gmail.com

Patient Name	MRS.CHANDRAMMA .C.M.	Patient Id	X-RAY-124
Age/DOB	59/	Gender	F
Ref.Doctor	BANK OF BARODA	Date	26/06/2022

Thank you for referring the patient for XRay

## X-RAY CHEST PA VIEW

### OBSERVATION:

The trachea is central.

The mediastinal and cardiac silhouette are normal.

Cardiothoracic ratio is normal.

Cardiophrenic and costophrenic angles are normal.

Both hila are normal.

The lung fields are clear.

Bones of the thoracic cage are normal.

Soft tissues of the chest wall are normal.

### IMPRESSION:

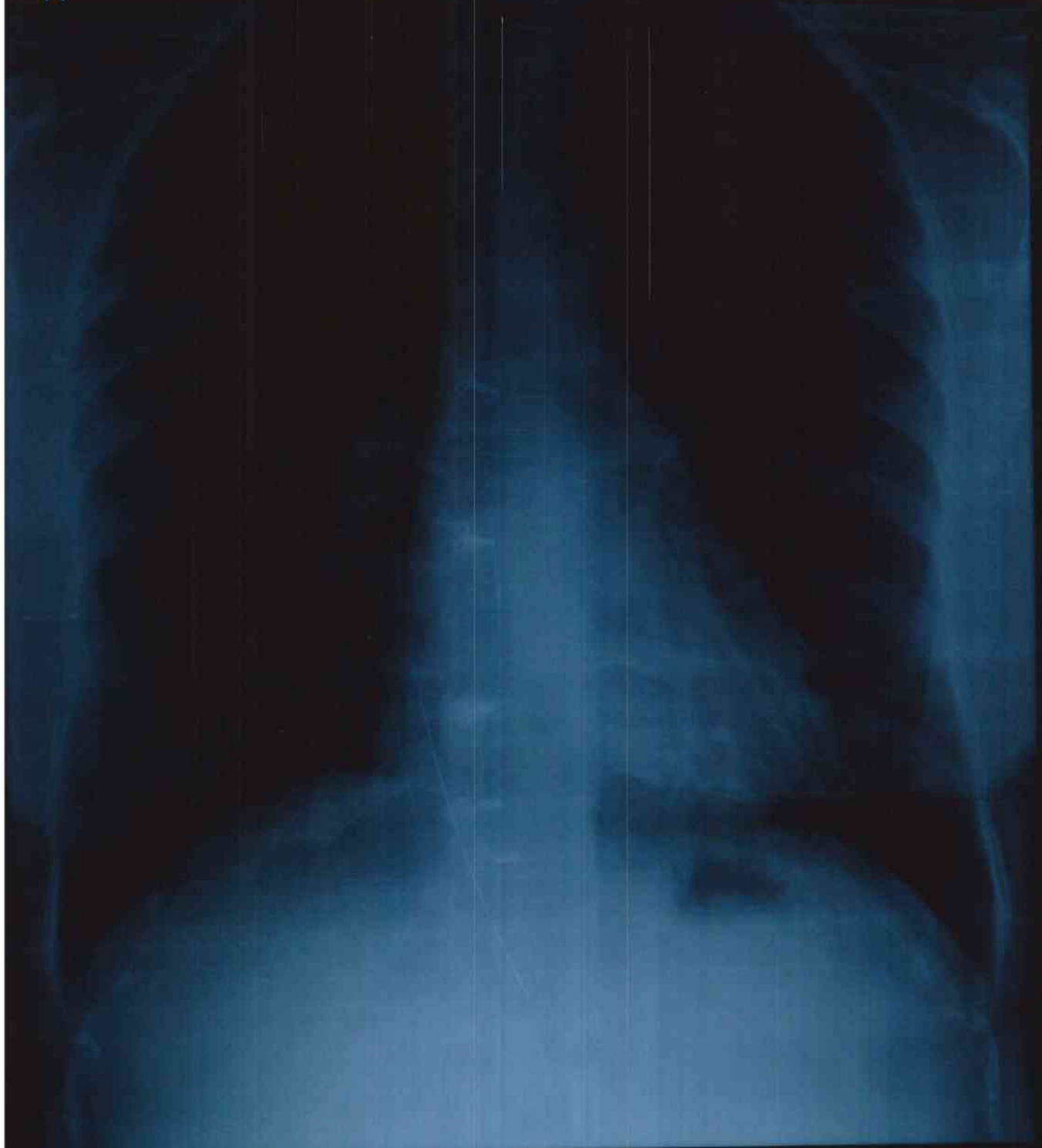
- No significant abnormality seen.

Dr. Shankar Poudel  
MD Radiodiagnosis  
Consultant Radiologist

BANGALORE DIAGNOSTICS &  
MULTI-SPECIALITY CENTRE  
# 198, 12th Main, 3rd Block  
Rajajinagar, Bangalore-560 010



R



BZ124 MRS CHANDRAMMA C.M. 59 F 25.06.2022 12:50:03  
BANGALORE DIAGNOSTIC SERVICE RAJAJINAGAR BANGALORE 560010



# Bangalore Diagnostics & Multi-Speciality Centre

Quality Assurance : EQAP from AIIMS & CMC- Vellore

Quality. Trust. Since 1982.

# 198, 12th Main, 3rd Block, (Above Namma MTR, Next to SBI), Rajajinagar, Bangalore- 560 010.  
Ph. : 080-23505407, 9448079978 e-mail : bangalore.d.s@gmail.com

## ELECTROCARDIOGRAM

NAME/AGE : mes. C.M. Chandramma

Lab No.: Bank of Baroda DATE: 25/06/2022

## ECG FINDINGS

Standardization	<u>Low</u>	Rate	<u>69b</u>
Rhythm	<u>sin</u>	Axis	<u>N</u>
P Wave	<u>✓</u>	PR Interval	<u>Other</u>
Q Wave	<u>✓</u>	QRS Voltage	<u>80/110/120</u>
QRS Duration	<u>Other</u>	ST Segment	<u>ST Elevation</u>
QT interval	<u>Other</u>		
U Wave		Wave	<u>✓</u>
Recommendations			
<u>Normal</u>			

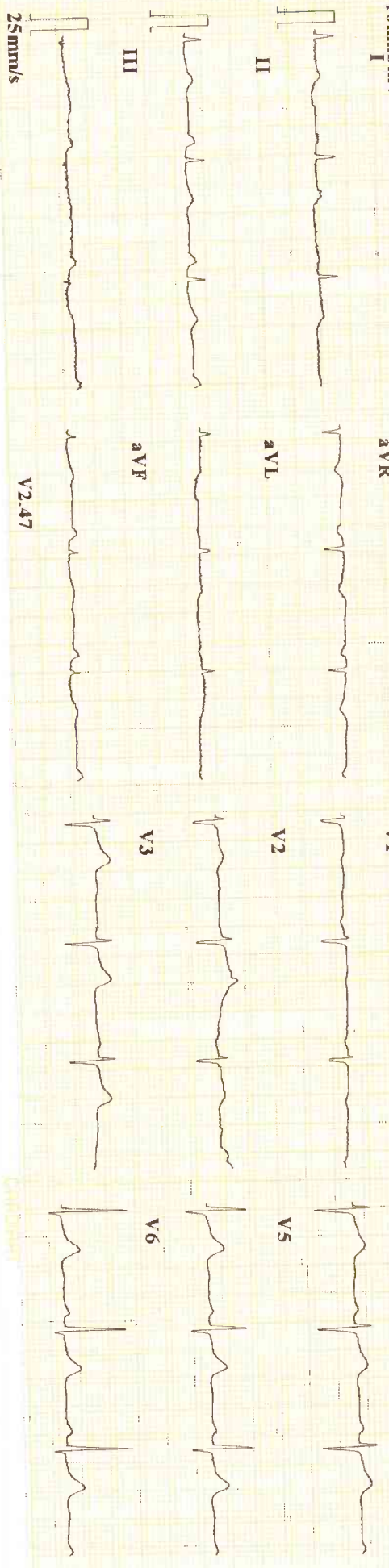
Dr. \_\_\_\_\_

Dr. ASHOK  
MD (Internal Medicine)  
Reg No 13444

BANGALORE DIAGNOSTICS &  
MULTI-SPECIALITY CENTRE  
# 198, 12th Main, 3rd Block  
Rajajinagar, Bangalore-560 010

10mm/mV 0.15-35Hz

2022-06-25 15:59:31  
aVR



C-7891

@

ID : 220625-1559  
 Name : *Chendran*  
 Age : 60 yr  
 Sex : Female  
 BP :  
 Height : cm  
 Weight : kg  
 HR : 69 bpm  
 P Dur : 101 ms  
 PR int : 148 ms  
 QRS Dur : 77 ms  
 QT/QTc int : 389/419 ms  
 P/QRS/T axis : 86/23/67 °  
 RV5/SV1 amp : 0.674/0.355 mV  
 RV5+SV1 amp : 1.029 mV  
 RV6/SV2 amp : 1.106/0.426 mV

Minnesota Code:  
 9-1-1(I,II,III)  
 9-4-2(V4)

Diagnosis Information:  
 800: Sinus Rhythm  
 131: Low Voltage(Limb Leads)

Report Confirmed by: