




बैंक ऑफ बरोडा
Bank of Baroda

नाम
Name
विजय कुमार
VIJAY KUMAR

ए.सी. नं.
E.C. No. 79812

आधिकारित
आधिकारिता
Issuing Authority



हस्ताक्षर
Signature Holder's

Compose

Inbox

Starred

Snoozed

Sent

Drafts

More

Meet

New meeting

Join a meeting

Fwd: Health Check up Booking Request Code(PKG10000228),Beneficiary Co



Vijay Kumar <VIJAY.KUMAR12@bankofbaroda.com>
to me

[Get Outlook for Android](#)

From: Mediwheel <customercare@policywheel.com>

Sent: Monday, August 8, 2022 4:43:17 PM

To: Vijay Kumar <VIJAY.KUMAR12@bankofbaroda.com>

Cc: Mediwheel CC <customercare@mediwheel.in>; Mediwheel

Subject: Health Check up Booking Request(bobS14806),Pack

****सावधान:** यह मेल बैंक डोमेन के बाहर से आया है.
****CAUTION:** THIS MAIL IS ORIGINATED FROM
ATTACHME





Bill of Supply (Interim Bill)



Patient ID : 20220803679
Age/Sex : 39y / M
Patient Name : VIJAY . KUMAR
Dr. Name : DR HIREN PATEL
Referred By : self
SAC : 9993 "Service covered under healthcare services"
Class : Contract
PAN Card : AAQCS5566G

Visit No. : OPD20220810243(OPD)
Bill No. : OPD20220810243
Bill Date : N/A
Speciality : Intensivist
Company Name : Mediwheel Health Check Up
GSTIN : 24AAQCS5566G2ZW
City/Village : Vadodara

Expense Details	Qty	Rate	Gross Amount	Waive	Net Amount
Visit Charge					
13-Aug-2022 Physician First Consultation OPD	1.0	0.00	0.0	0.0	0.00
Ophthalmologist First Consultation OPD	1.0	0.00	0.0	0.0	0.00
Visit Charge (Subtotal)			0.0	0.0	0.00
PATHOLOGY					
13-Aug-2022 CBC, ESR	1.0			0.0	
Urine R/M	1.0			0.0	
STOOL EXAMINATION	1.0			0.0	
Blood Group	1.0			0.0	
TFT (Thyroid Function Test)	1.0			0.0	
Lipid Profile	1.0			0.0	
RENAL FUNCTION TEST	1.0			0.0	
LFT (Liver Function Test)	1.0			0.0	
FBS & PPBS	1.0			0.0	
HBA1C	1.0			0.0	
MediWheel Full Body Health Check-Up(Male Below 40)	1.0	2000.00	2000.0	0.0	2000.00
PATHOLOGY (Subtotal)			2000.0	0.0	2000.00
Radiology					
13-Aug-2022 X-RAY CHEST PA	1.0			0.0	
USG WHOLE ABDOMEN SCREENING	1.0			0.0	
X-RAY CHEST PA	1.0	0.00	0.0	0.0	0.00
USG WHOLE ABDOMEN SCREENING	1.0	0.00	0.0	0.0	0.00
Radiology (Subtotal)			0.0	0.0	0.00
Non Invasive Cardiology					
13-Aug-2022 ECG Charge(OPD Base)	1.0	0.00	0.0	0.0	0.00
ECHO COLOUR DOPPLER SCREENING	1.0	0.00	0.0	0.0	0.00
Non Invasive Cardiology (Subtotal)			0.0	0.0	0.00
Total Bill Amount					2000.00
Net payable amount					2000.00
Bill Outstanding					2000.00

Received With Thanks From VIJAY . KUMAR of Rs 0.0 /-
(Rs Zero Only)

Printed By : (Vishali Salunke)
For Savita Hospital-Live





PHYSICIAN EXAMINATION

Name:- VIJAY KUMAR
Reg.No: 20220803679

Age: 39/MALE
DOE: 13/08/2022

Physical Examination:

Height: 170CM **Weight: 66KG** **PULSE: 83** **Temperature: NORMAL**
BMI: 22.8 **BP: 130/80** **SPO2- 99%**

Chief Complaint: NAD

Past History: NAD

General Examination: NAD

Systemic Examination: NAD

INVESTIGATION :

ADVICE: NAD

DR HIREN PATEL.





Examination By Ophthalmologist

Name:- VIAJY KUMAR
Reg.No: 20220803679

Age:39/MALE
DOE: 13/08/2022

Present Complaints: NAD

Medical History: NAD

Examination Of Eye:	<u>Right</u>	<u>Left</u>
External Examination :	NAD	NAD
Ati Seg Examination:	A/S WNL	NAD
Schiotz Tonometry IOP:		RRRL

Fundus: NILL

Without Glass Distant Vision: _____

Near Vision: N6 _____ N6

With Glass Distant Vision: 6/6 _____ 6/6

Near Vision: _____

Colour Vision (With Ishihara Chart): WNL

Advice: NAD

DR CHETAN CHAUHAN



CANON RK-F2
13/AUG/2022 13:06
No. : 003108
NAME : _____ M/F


<RIGHT>
[REF] VD: 0.0
SPH CYL AX
-2.00 -0.50 156

<LEFT >
[REF]
-1.75 -0.75 59

2.8
PD : 64 mm

SOLACE HEALTH CARE
WAGHODIA ROAD,
VADODARA.




Patient Name :	VIJAY . KUMAR	Sample No. :	20220806065 
Patient ID :	20220803679	Visit No. :	OPD20220810243
Age/Sex :	39y/Male	Call. Date :	13-Aug-2022 11:32
Consultant :	DR HIREN PATEL	S. Coll. Date :	13-Aug-2022 13:23
Ward :	-	Report Date :	13-Aug-2022 15:59

CBC, ESR

Investigation	Result	Normal Value
Hemoglobin :	13.8 gm/dl	13.5 to 18.0 gm/dl
P.C.V. :	41.7 % [L]	42.0 to 52.0 %
M.C.V. :	80.2 fL	78 to 100 fL
M.C.H. :	26.5 pg [L]	27 to 31 pg
M.C.H.C. :	33.1 g/dl	32 to 36 g/dl
RDW :	13.1 %	11.5 to 14.0 %
RBC Count :	5.20 X 10 ⁶ / cumm	4.7 to 6.0 X 10 ⁶ / cumm
Polymorphs :	59 %	38 to 70 %
Lymphocytes :	37 %	15 to 48 %
Eosinophils :	02 %	0 to 6 %
Monocytes :	02 % [L]	3 to 11 %
Basophils :	00 %	0.0 to 1.0 %
Total :	100	< 100 > 100
WBC Count :	8700 /cmm	4000 to 10000 /cmm
Platelets Count :	187000 /cmm	1,50,000 to 4,50,000 /cmm
ESR - After One Hour :	40 mm/hr [H]	1 to 13 mm/hr
P/S :		

Dr. Mehul Desai
G-9521



Patient Name :	VIJAY . KUMAR	Sample No. :	20220806065 
Patient ID :	20220803679	Visit No. :	OPD20220810243
Age/Sex :	39y/Male	Call. Date :	13-Aug-2022 11:32
Consultant :	DR HIREN PATEL	S. Coll. Date :	13-Aug-2022 13:23
Ward :	-	Report Date :	13-Aug-2022 15:59

Blood Group


Investigation	Result	Normal Value
BLOOD GROUP :		
ABO	B	
Rh	Positive	

FBS & PPBS

Investigation	Result	Normal Value
Blood Sugar (FBS) :	114 mg/dl [H]	74 - 100 mg/dl
Urine Sugar (FUS) :	Nil	
Blood Sugar (PP2BS) :	180 mg/dl [H]	70 to 120 mg/dl
Urine Sugar (PP2US) :	Nil	


HBA1C

Investigation	Result	Normal Value
Glycosylated Hb :	5.7 %	Near Normal Glycemia : 6 to 7 Excellent Control : 7 to 8 Good Control : 8 to 9 Fair Control : 9 to 10 Poor Control : > 10
Average Plasma Glucose of Last 3 Months :	116.89	




Dr. Mehul Desai
G-9521



Patient Name :	VIJAY . KUMAR	Sample No. :	20220806065 
Patient ID :	20220803679	Visit No. :	OPD20220810243
Age/Sex :	39y/Male	Call. Date :	13-Aug-2022 11:32
Consultant :	DR HIREN PATEL	S. Coll. Date :	13-Aug-2022 13:23
Ward :	-	Report Date :	13-Aug-2022 15:59

RENAL FUNCTION TEST

Investigation	Result	Normal Value
Creatinine :	1.0 mg/dl	0.6 - 1.4 mg/dl
Urea :	20 mg/ dl	13 - 45 mg/dl
Uric Acid :	5.3 mg/dl	3.5 - 7.2 mg/dl
Calcium :	9.4 mg/dl	8.5 - 10.5
Phosphorus :	4.1 mg/dl	1.5 - 6.8



Dr. Mehul Desai
G-9521



Savita

Superspeciality Hospital
(A Unit of Solace Healthcare Pvt. Ltd.)

Parivar Char Rasta, Waghodia-Dabhoi Ring Road, Vadodara-390019

☎ 0265-2578844 / 2578849 ✉ mh@savitahospital.com 🌐 savitahospital.com

Patient Name : VIJAY . KUMAR

Sample No. : 20220806065



Patient ID : 20220803679

Visit No. : OPD20220810243

Age/Sex : 39y/Male

Call. Date : 13-Aug-2022 11:32

Consultant : DR HIREN PATEL

S. Coll. Date : 13-Aug-2022 13:23

Ward : -

Report Date : 13-Aug-2022 15:59

LFT (Liver Function Test)

Investigation	Result	Normal Value
Total Bilirubin :	0.7 mg/dl	0.2 to 1.0 mg/dl
Direct Bilirubin :	0.3 mg/dl	0.0 to 0.2 mg/dl
Indirect Bilirubin :	0.4 mg/dl	0.0 to 0.8 mg/dl
AST (SGOT) :	18 U/L	5 to 34 U/L
ALT (SGPT) :	24 U/L	0 to 55 U/L
Total Protein (TP) :	7.4 g/dL	6.4 to 8.3, g/dl
Albumin (ALB) :	3.9 g/dl	3.5 to 5.2 g/dl
Globulin :	3.5 g/dl	2.3 to 3.5 g/dl
A/G Ratio :	1.11	
Alkaline Phosphatase (ALP) :	179 U/L [H]	40 to 150 U/L
GAMMA GT. :	24 U/L	7 to 35 U/L

Dr. Mehul Desai
G-9521



Savita

Superspeciality Hospital
(A Unit of Solace Healthcare Pvt. Ltd.)

Parivar Char Rasta, Waghodia-Dabhoi Ring Road, Vadodara-390019

☎ 0265-2578844 / 2578849 ✉ mh@savitahospital.com 🌐 savitahospital.com

Patient Name : VIJAY . KUMAR

Sample No. : 20220806065



Patient ID : 20220803679

Visit No. : OPD20220810243

Age/Sex : 39y/Male

Call. Date : 13-Aug-2022 11:32

Consultant : DR HIREN PATEL

S. Coll. Date : 13-Aug-2022 13:23

Ward : -

Report Date : 13-Aug-2022 15:59


Lipid Profile

Investigation	Result	Normal Value
Sample :	Fasting	
Sample Type :	Normal	
Cholesterol (Chol) :	204 mg/dl [H]	Low risk : < 200 Moderate risk : 200 - 239 High risk : > or = 240
Triglyceride :	185 mg/dl	Normal : < 200.0 High : 200 - 499 Very High : > or = 500
HDL Cholesterol :	44 mg/dl	Low risk : > or = 60 mg/dL High risk : Up to 35 mg/dL
LDL :	123 mg/dl [L]	131.0 to 159.0(N) < 130.0(L) > 159.0(H)
VLDL :	37 mg/dl [H]	Up to 0 to 34 mg/dl
LDL/HDL Ratio :	2.8	Low risk : 0.5 to 3.0 Moderate risk : 3.0 to 6.0 Elevated level high > 6.0
Total Chol / HDL Ratio :	4.64	Low Risk : 3.3 to 4.4 Average Risk : 4.4 to 7.1 Moderate Risk : 7.1 to 11.0 High Risk : > 11.0
Total Lipids :	733 mg/dl [H]	400 to 700 mg/dl

Note :- Lipemic samples give high triglyceride value and falsely low LDL value.

Dr. Mehul Desai
G-9521



Patient Name : VIJAY . KUMAR	Sample No. : 20220806065 
Patient ID : 20220803679	Visit No. : OPD20220810243
Age/Sex : 39y/Male	Call. Date : 13-Aug-2022 11:32
Consultant : DR HIREN PATEL	S. Coll. Date : 13-Aug-2022 13:23
Ward : -	Report Date : 13-Aug-2022 15:59

Urine R/M

Investigation	Result	Normal Value
Quantity - :	20 ml	
Colour - :	Pale Yellow	
Reaction (pH) :	6.0	4.6-8.0
Turbidity :	Clear	
Deposit :	Absent	Absent
Sp.Gravity :	1.010	1.005-1.010
Protein :	Absent	Absent
Glucose :	Absent	Absent
Bile Salts :	Absent	Absent
Bile pigments :	Absent	Absent
Ketones :	Absent	Absent
Urobilinogen :	Absent	
Blood :	Absent	Absent
Pus Cells :	Absent /hpf	0-5/hpf
Red Blood Cells :	Absent /hpf	Absent
Epithelial Cells :	0-1 /hpf	



Dr. Mehul Desai
G-9521



TEST REPORT

Name	: VIJAYKUMAR	Acc. ID	: 221014653
Age/Sex	: 39 Years / Male	Birthdate	: Regd. Dt : 13-Aug-2022 03:19 PM
Refd. By	: SAVITA SUPERSPECIALITY HOSPITAL	Status	: Final
Sample	: Serum	PassportNo:	: Coll Dt. TM. : 13-Aug-2022 02:52 PM
Client Details	: SAVITA SUPERSPECIALITY HOSPITAL	Mobile	: Recd. Dt. Tm. : 13-Aug-2022 03:19 PM
			: Report Dt. Tm. : 13-Aug-2022 04:31 PM

IMMUNOLOGY


Test Name	Result	Unit	Biological Ref. Interval
-----------	--------	------	--------------------------

THYROID FUNCTION TEST

T3 (Triiodothyronine) <small>CHEMILUMINESCENT MICROPARTICLE IMMUNOASSAY</small>	2.15	ng/mL	0.97 - 1.69
T4 (Thyroxine) <small>CHEMILUMINESCENT MICROPARTICLE IMMUNOASSAY</small>	9.62	µg/dL	5.5 - 11.0
TSH <small>CHEMILUMINESCENT MICROPARTICLE IMMUNOASSAY</small>	7.020	µIU/ml	0.4 - 4.2

----- End Of Report -----

This is an Electronically Authenticated Report.


DR KHUSHBU SHAH
M.D. PATHOLOGY
GMC No. G-28946

Verified By
Auto

Dr. Kinjal Patel
M. D. PATHOLOGY
GMC No. G-33123

KUMAR, VIJAY
Male

39 Years

Rate 75

PR 148

QRS 82

QT 344

QTc 385

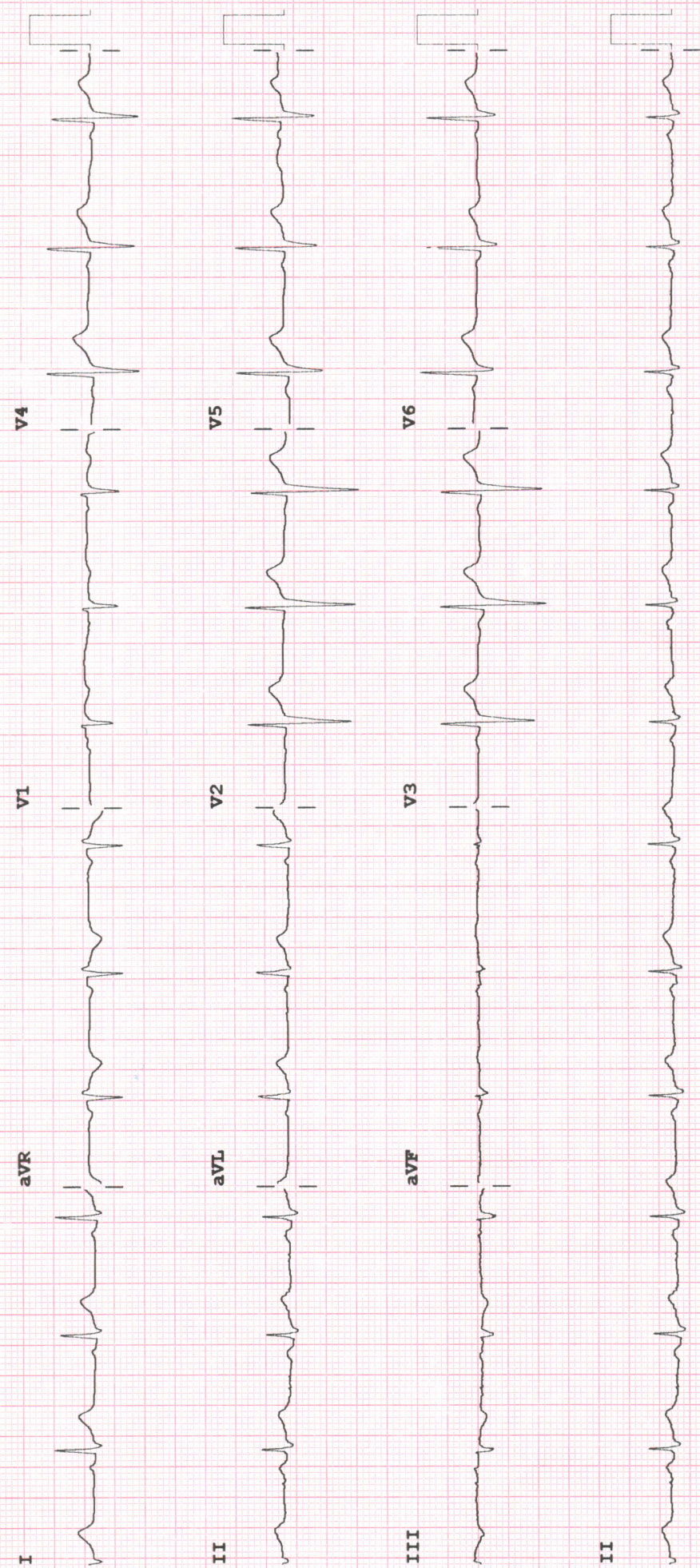
--AXIS--

P 43

QRS -1

T 9

12 Lead; Standard Placement





2D-ECHOCARDIOGRAPHY AND COLOR DOPPLER REPORT

NAME: VIJAY KUMAR

DATE : 13/08/2022

AGE/SEX: 39YRS/MALE

REF BY: DR. HIREN PATEL

OBSERVATION:

- NORMAL LV SIZE AND NORMAL LV SYSTOLIC FUNCTION. LVEF = 60% (VISUAL).
- NO E/O LV DIASTOLIC DYSFUNCTION.
- MILD CONCENTRIC LVH PRESENT.
- NO RWMA AT REST.
- NO MR. NO MS.
- NO AR. NO AS.
- NO TR. NO PAH.
- NORMAL SIZED LA, RA & RV WITH NORMAL RV SYSTOLIC FUNCTION.
- NORMAL SIZED MPA, RPA & LPA.
- INTACT IAS AND IVS.
- NO E/O INTRACARDIAC CLOT/VEGETATION/ PE.
- NORMAL IVC.

CONCLUSION:

- NORMAL LV/RV SIZE AND SYSTOLIC FUNCTION.
- MILD CONCENTRIC LVH PRESENT.
- NO RWMA AT REST.
- LVEF = 60% (VISUAL).

DR.NIRAV BHALANI
[CARDIOLOGIST]

DR.ARVIND SHARMA
[CARDIOLOGIST]

DR. CHIRAG SHETH
[CARDIOLOGIST]



Saturday, August 13, 2022

VIJAY KUMAR

39 YEARS/MALE

ULTRASONOGRAPHY OF ABDOMEN AND PELVIS SCREENING

Liver shows normal size and echogenicity. No mass lesion detected.
PV, CBD and intrahepatic biliary radicals shows no dilatation.

The gall bladder is distended and show normal gall bladder wall thickness. There is no evidence of gallstones.

Spleen appears normal in size and echotexture. No evidence of focal lesion.
Pancreas appears normal in size and echotexture. No focal lesion.

Both kidneys show normal size, position and cortical echogenicity.
Corticomedullary differentiation is preserved bilaterally.
No calculus or hydronephrosis on either side.

The urinary bladder is distended and appears normal. No evidence of any calculus or mass lesion is noted.
Prostate appears normal in size. No focal lesion.
No evidence of Lymphadenopathy or ascites seen.
No e/o dilated bowel loops seen.

CONCLUSION:

NO SONOGRAPHIC ABNORMALITY IS DETECTED.


DR SARJAN VASAVA, DMRD



Saturday, August 13, 2022

VIJAY KUMAR

39 YEARS/MALE

CHEST X RAY PA VIEW

Both the lung fields appear normal.

Both costophrenic angles appear clear.

Cardiac silhouette appear normal.

Both hila appears normal.

Mediastinum and aorta appear normal.

Bony thorax appears normal.

No evidence of free gas seen under dome of diaphragm.

COMMENTS:

- **NORMAL BOTH LUNG FIELDS.**
- **NORMAL CARDIAC SIZE.**

Dr. Sarjan Vasava
DMRD