



Swaminarayan Nagar, Off Mumbai-Agra Highway,
Panchvati, Nashik - 422 003.
+91- 253 - 2510250 / 350 / 450 / 550 / 750
apoltonashik@apollohospitals.com
www.askapollo.com

QFAHN/BILL/003/V1



Name : Mrs. SUNITA B SHINDE (51 /F)

Date : 10/12/2022

Address : SARIKA RAW HOUSE B SAMBAJI NAGAR ASHOK NAGAR SATPUR NASHIK,
NASHIK, NASHIK, MAHARASHTRA, INDIA

Examined by:

UHID : MHN1.0000130024

Package : MediWheel Full Body Health Checkup Female Above 40
Package

AHC No : NSKAH28485



CHIEF COMPLAINTS

For corporate health checkup
No specific complaints

PRESENT KNOWN ILLNESS

No history of - Diabetes mellitus,
Hypertension, Thyroid
disorder, Heart disease,
Stroke, Asthma, COPD,
Cancer

No. of children - 03
Diet - Vegetarian
Alcohol - does not consume alcohol
Smoking - No
Chews tobacco - No
Physical activity - Active



Family history

Coronary artery
disease - none
Cancer - None



DRUG ALLERGY

NO KNOWN ALLERGY

: 10/12/2022



SYSTEMIC REVIEW

Cardiovascular system
- Nil Significant



Past medical history

Do you have any - No
allergies?
Do you have any drug - No
allergies?
Past medical history - nil significant
Covid 19 - No



Surgical history

Surgical history - Nil

Immunization history

- Covid Dose1, Covid Dose2



Personal history

Marital status - Married

PHYSICAL EXAMINATION



General

General appearance - normal
Build - normal
Height - 147
Weight - 59.4
BMI - 27.49
Pallor - No
Oedema - no
Temperature - 34 c
SpO2 - 98



Cardiovascular system

Heart rate (Per minute) - 73
Rhythm - Regular
- B.P. Supine
Systolic(mm of Hg) - 120
Diastolic(mm of Hg) - 80
Heart sounds - S1S2+

Respiratory system

Breath sounds - Normal vesicular breath
sounds



Swaminarayan Nagar, Off Mumbai-Agra Highway,
Panchvati, Nashik - 422 003.
+91- 253 - 2510250 / 350 / 450 / 550 / 750
apollonashik@apollohospitals.com
www.askapollo.com

QFAHN/BILL/003/V1



Apollo
HOSPITALS
NASHIK


Name : Mrs. SUNITA B SHINDE (51 /F)

UHID : MHN1.0000130024

Date : 10/12/2022

Package : MediWheel Full Body Health Checkup Female Above 40 Package

AHC No : NSKAH28485

 **Abdomen**

Organomegaly - No
Tenderness - No





Swaminarayan Nagar, Off Mumbai-Agra Highway,
Panchvati, Nashik - 422 003.
+91- 253 - 2510250 / 350 / 450 / 550 / 750
apoltonashik@apollohospitals.com
www.askapollo.com

QFAHN/BILL/003/V1



Apollo
HOSPITALS
NASHIK

Name : Mrs. SUNITA B SHINDE (51 /F)

UHID : MHN1.0000130024

Date : 10/12/2022

Package : MediWheel Full Body Health Checkup Female Above 40 Package

AHC No : NSKAH28485

URINE ROUTINE (CUE)

| Test Name | Result | Unit | Level | Range |
|--|-------------|------|-------|-------------|
| Specific Gravity | 1.030 * | | ● | 1.016-1.026 |
| Color,: | PALE YELLOW | | | |
| Transparency: | Clear | | | |
| Reaction: | Acidic | | | 7.2-7.8 |
| Protein : | Negative | | | |
| Sugar: | Negative | | | |
| | 5.0 | | ● | 4.6-8 |
| Blood: | 1+ | | | |
| Ketone | Negative | | | |
| Bile Pigments: | Negative | | | |
| Bile Salts : | Negative | | | |
| Urobilinogen | Normal | | | |
| Nitrite | Negative | | | |
| RBC | 3-4 | /hpf | | 0-2 |
| WBC/Pus Cells | 8-10 | /hpf | | |
| Tc/Sqc(Transitional/Squamous epithelial cells) | 3-4 | /hpf | | |

| | | | | |
|--------------------------------------|----|-----------|---|-------|
| Lymphocytes | 37 | % | ● | 20-45 |
| Eosinophils | 03 | % | ● | 1-6 |
| Monocytes | 05 | % | ● | 1-10 |
| Basophils | 00 | % | ● | 0-1 |
| ERYTHROCYTE SEDIMENTATION RATE (ESR) | 11 | mm/1st hr | ● | 0-20 |

BLOOD GROUPING AND TYPING (ABO and Rh)

| Test Name | Result | Unit | Level | Range |
|--------------|----------|------|-------|-------|
| ABO Group: | O | | | |
| Rh (D) Type: | POSITIVE | | | |

LIVER FUNCTION TEST (PACKAGE)

| Test Name | Result | Unit | Level | Range |
|--|--------|------|-------|---------|
| ALT(SGPT) - SERUM / PLASMA | 25 * | U/L | ● | 30-65 |
| ALBUMIN - SERUM | 4.2 | g/dL | ● | 3.5-5 |
| GLOBULIN - SERUM: (Calculated) | 4.3 * | g/dL | ● | 1.8-3.6 |
| ALBUMIN:GLOBULIN - SERUM(RATIO) (Calculated) | 0.1 * | | ● | 1.1-1.8 |

C B C WITH ESR (AUTOMATION + STANDARD METHOD)

| Test Name | Result | Unit | Level | Range |
|-----------------------------------|--------|---------------------------------|-------|-----------|
| Hemoglobin | 11.8 | g/dl | ● | 11.0-16.0 |
| Haematocrit | 35.8 | % | ● | 34.0-48.0 |
| RBC COUNT | 4.64 | Million/ul | ● | 3.7-5.6 |
| MCV | 77.1 | fl | ● | 75.0-95.0 |
| MCH | 25.4 * | pg | ● | 26.0-32.0 |
| MCHC | 33 | g/dl | ● | 31.0-36.0 |
| RDW | 17.1 * | % | ● | 11-16 |
| Platelet Count(Optical/Impedance) | 242 | 10 ³ /m ³ | ● | 140-440 |
| TLC Count | 6.85 | 10 ³ /m ³ | ● | 4.0-11.0 |
| Neutrophils | 55 | % | ● | 40-75 |

| | | | | |
|-------------------------------------|-------|-------|---|---------|
| ALKALINE PHOSPHATASE - SERUM/PLASMA | 125 * | U/L | ● | 0-100 |
| AST (SGOT) - SERUM | 25 | U/L | ● | 15-37 |
| BILIRUBIN, TOTAL - SERUM | 0.2 | mg/dL | ● | 0.0-1.0 |

LIPID PROFILE TEST (PACKAGE)

| Test Name | Result | Unit | Level | Range |
|-------------------|--------|-------|-------|-------|
| Total Cholesterol | 128 | mg/dL | ● | 0-200 |

CREATININE - SERUM / PLASMA

| Test Name | Result | Unit | Level | Range |
|-----------------------------|--------|-------|-------|---------|
| CREATININE - SERUM / PLASMA | 0.6 | mg/dL | ● | 0.6-1.0 |

● Within Normal Range ● Borderline High/Low ● Out of Range



Swaminarayan Nagar, Off Mumbai-Agra Highway,
Panchvati, Nashik - 422 003.
+91- 253 - 2510250 / 350 / 450 / 550 / 750
apollonashik@apollohospitals.com
www.askapollo.com

QFAHN/BILL/003/V1



Apollo
HOSPITALS
NASHIK

Name : Mrs. SUNITA B SHINDE (51 /F)

UHID : MHN1.0000130024

Date : 10/12/2022

Package : MediWheel Full Body Health Checkup Female Above 40 Package

AHC No : NSKAH28485

LIVER FUNCTION TEST (PACKAGE)

| Test Name | Result | Unit | Level | Range |
|---|--------|------|-------|-------|
| GGTP: GAMMA GLUTAMYL TRANSPEPTIDASE - SERUM | 20 | U/L | ● | 0-50 |

GLUCOSE - SERUM / PLASMA (FASTING)

| Test Name | Result | Unit | Level | Range |
|--|--------|-------|-------|--------|
| Glucose - Plasma (Fasting) | 93 | mg/dL | ● | 70-100 |
| URINE GLUCOSE(FASTING): (Strip Method) | Nil | | | |

GLUCOSE - SERUM / PLASMA (POST PRANDIAL)

| Test Name | Result | Unit | Level | Range |
|----------------------------------|--------|-------|-------|--------|
| Glucose - Plasma (POST PRANDIAL) | 97 | mg/dL | ● | 70-140 |

GLYCOSYLATED HEMOGLOBIN (HbA1C) - WHOLE BLOOD

| Test Name | Result | Unit | Level | Range |
|-----------------------------------|--------|-------|-------|---------|
| Glycosylated Hemoglobin (HbA1c) | 5.5 | % | ● | 0.0-6.0 |
| Mean Plasma Glucose (G) Estimate: | 118.50 | mg/dL | | |

LIPID PROFILE TEST (PACKAGE)

| Test Name | Result | Unit | Level | Range |
|---|--------|-------|-------|---------|
| HDL CHOLESTEROL - SERUM / PLASMA | 41 | mg/dL | ● | 40-60 |
| TOTAL CHOLESTEROL/HDL CHOLESTEROL RATIO(Calculated) | 3.1 | | ● | 0.0-4.5 |
| LDL Cholesterol (Direct LDL) | 90 | mg/dL | | |

LIVER FUNCTION TEST (PACKAGE)

| Test Name | Result | Unit | Level | Range |
|-----------|--------|------|-------|-------|
|-----------|--------|------|-------|-------|

| | | | | |
|---------------------------------|-------|------|---|---------|
| PROTEIN, TOTAL - SERUM / PLASMA | 8.5 * | g/dL | ● | 6.4-8.2 |
| PROTEIN, TOTAL - SERUM / PLASMA | 8.5 * | g/dL | ● | 6.4-8.2 |

THYROID PROFILE - I(T3,T4 AND TSH)

| Test Name | Result | Unit | Level | Range |
|-------------------------------------|--------|-------|-------|---------------------------|
| TOTAL T3: TRI IODOTHYRONINE - SERUM | 184 | ng/dL | ● | Healthy Adults: 69 - 215 |
| TOTAL T4: THYROXINE - SERUM | 9.3 | µg/dL | ● | Healthy Adults:5.2 - 12.7 |

LIPID PROFILE TEST (PACKAGE)

| Test Name | Result | Unit | Level | Range |
|-----------------------|--------|-------|-------|-------|
| Triglycerides - Serum | 206 * | mg/dL | ● | 0-150 |

THYROID PROFILE - I(T3,T4 AND TSH)

| Test Name | Result | Unit | Level | Range |
|--|--------|--------|-------|---------------------------|
| TSH: THYROID STIMULATING HORMONE - SERUM | 3.3 | uIU/mL | ● | Healthy Adults: 0.3 - 4.5 |

UREA - SERUM / PLASMA

| Test Name | Result | Unit | Level | Range |
|--|--------|-------|-------|-------|
| UREA - SERUM / PLASMA | 18 | mg/dL | ● | 15-38 |
| UREA NITROGEN SERUM/PLASMA: (Calculated) | 8 | mg/dL | ● | 7-18 |

URIC ACID - SERUM

| Test Name | Result | Unit | Level | Range |
|-------------------|--------|-------|-------|---------|
| URIC ACID - SERUM | 4.3 | mg/dL | ● | 2.6-6.0 |

LIVER FUNCTION TEST (PACKAGE)

| Test Name | Result | Unit | Level | Range |
|---------------------------------------|--------|-------|-------|---------|
| BILIRUBIN CONJUGATED (DIRECT) - SERUM | 0.1 | mg/dL | ● | 0.0-0.3 |

● Within Normal Range ● Borderline High/Low ● Out of Range



Swaminarayan Nagar, Off Mumbai-Agra Highway,
Panchvati, Nashik - 422 003.
+91- 253 - 2510250 / 350 / 450 / 550 / 750
apollonashik@apollohospitals.com
www.askapollo.com

QFAHN/BILL/003/V1



Apollo
HOSPITALS
NASHIK

Name : Mrs. SUNITA B SHINDE (51 /F)

UHID : MHN1.0000130024

Date : 10/12/2022

Package : MediWheel Full Body Health Checkup Female Above 40 Package

AHC No : NSKAH28485

BILIRUBIN 0.1 mg/dL ● 0.0-0.7
UNCONJUGATED -
SERUM(Calculated)

CARDIAC STRESS TEST - (TMT)

ECG

MAMMOGRAPHY

1) No significant abnormality is seen on this study.
2) BI - RADS - Category 1.

Suggest : Clinical correlation.

ULTRASOUND - WHOLE ABDOMEN

Grade I fatty infiltration of liver.
No other significant abnormality is detected.

X-RAY CHEST PA

No significant abnormality is detected.


INVESTIGATIONS NOT DONE / NOT YET REPORTED / NOT
PART OF PACKAGE(LAB,RADIOLOGY & CARDIOLOGY)

Haematology

STOOL ROUTINE

Histopathology

CERVICAL/VAGINAL SMEAR II SLIDE



● Within Normal Range ● Borderline High/Low ● Out of Range



Swaminarayan Nagar, Off Mumbai-Agra Highway,
Panchvati, Nashik - 422 003.
+91- 253 - 2510250 / 350 / 450 / 550 / 750
apollonashik@apollohospitals.com
www.askapollo.com

QFAHN/BILL/003/V1



Apollo
HOSPITALS
NASHIK

Name : Mrs. SUNITA B SHINDE (51 /F)

UHID : MHN1.0000130024

Date : 10/12/2022

Package : MediWheel Full Body Health Checkup Female Above 40 Package

AHC No : NSKAH28485

Printed By :

AHC Physician / Consultant Internal Medicine

cut low

- healthy diet

Daily exercise

[Signature]

- 2D echo yearly.

- tab mycopar 0-10, 1-0-1 - 3 day

[Signature]

Note :- The Health Check-up examinations and routine investigations have certain limitations and may not be able to detect all the diseases. Any new or persisting symptoms should be brought to the attention of the Consulting Physician. Additional tests, consultations and follow up may be required in some cases.



Swaminarayan Nagar, Off Mumbai-Agra Highway,
Panchvati, Nashik - 422 003.
+91- 253 - 2510250 / 350 / 450 / 550 / 750
apollonashik@apollohospitals.com
www.askapollo.com

QFAHN/BILL/003/V1



Apollo
HOSPITALS
NASHIK

Name : Mrs. SUNITA B SHINDE (51 /F)

UHID : MHN1.0000130024

Date : 10/12/2022

Package : MediWheel Full Body Health Checkup Female Above 40 Package

AHC No : NSKAH28485

AICVD RISK SCORE REPORT

RISK STATUS

Low Risk

YOUR SCORE

3

ACCEPTABLE SCORE

5

Your cardiovascular disease risk in the next 10 years is within the Normal limits for your age and gender. The AICVD risk score developed by Apollo Hospitals is a novel artificial intelligence-based risk scoring system that predicts your risk of having Coronary Artery Disease (CAD) related events in the next ten years. This scoring system uses Indian data and has been validated by multiple national and international institutions. This risk score is more than 92% accurate and has been compiled based on your physical parameters, heart health attributes, lifestyle and medical history. **Note:** The risk category is determined through the ratio between guest score and acceptable score at multiple decimal points. The outputs are shown in whole numbers.

Based on your AICVD risk score you are advised the following:

- Follow the guidance and education on lifestyle and dietary management provided through the ProHealth program. Maintain a healthy BMI (<25). Avoid tobacco in any form and if you are a smoker, stop smoking.
- Continue with medications for high blood pressure, diabetes, or dyslipidemia, if advised by your physician. Maintain HbA1c <7% (<53mmol/mol), blood pressure <140/90mmHg.
- Follow your physician's advice regarding follow up tests, consults and annual health assessment

DISCLAIMER

- This is not a diagnostic tool and it does not guarantee accuracy of the result and cannot be acted upon independently.
- This risk score and clinical algorithm is a general guideline for physicians. Any additional laboratory investigations, diagnostic imaging, treatment or patient education related to lifestyle management is under the physician's or cardiologist's discretion.
- To ensure the information in the report is up to date, accurate and correct, doctor shall be consulted for interpretation of the report.
- Apollo Hospitals and its staff does not offer any assurance on the information made available or be liable for any loss or damage as the said report is based on the AICVD risk score without any intervention from their side.
- By usage of the AICVD risk score, it is deemed that the beneficiary of this service has agreed to get the same done at his own risk and further agrees with this disclaimer without any limitation or any clauses or sub-clauses.

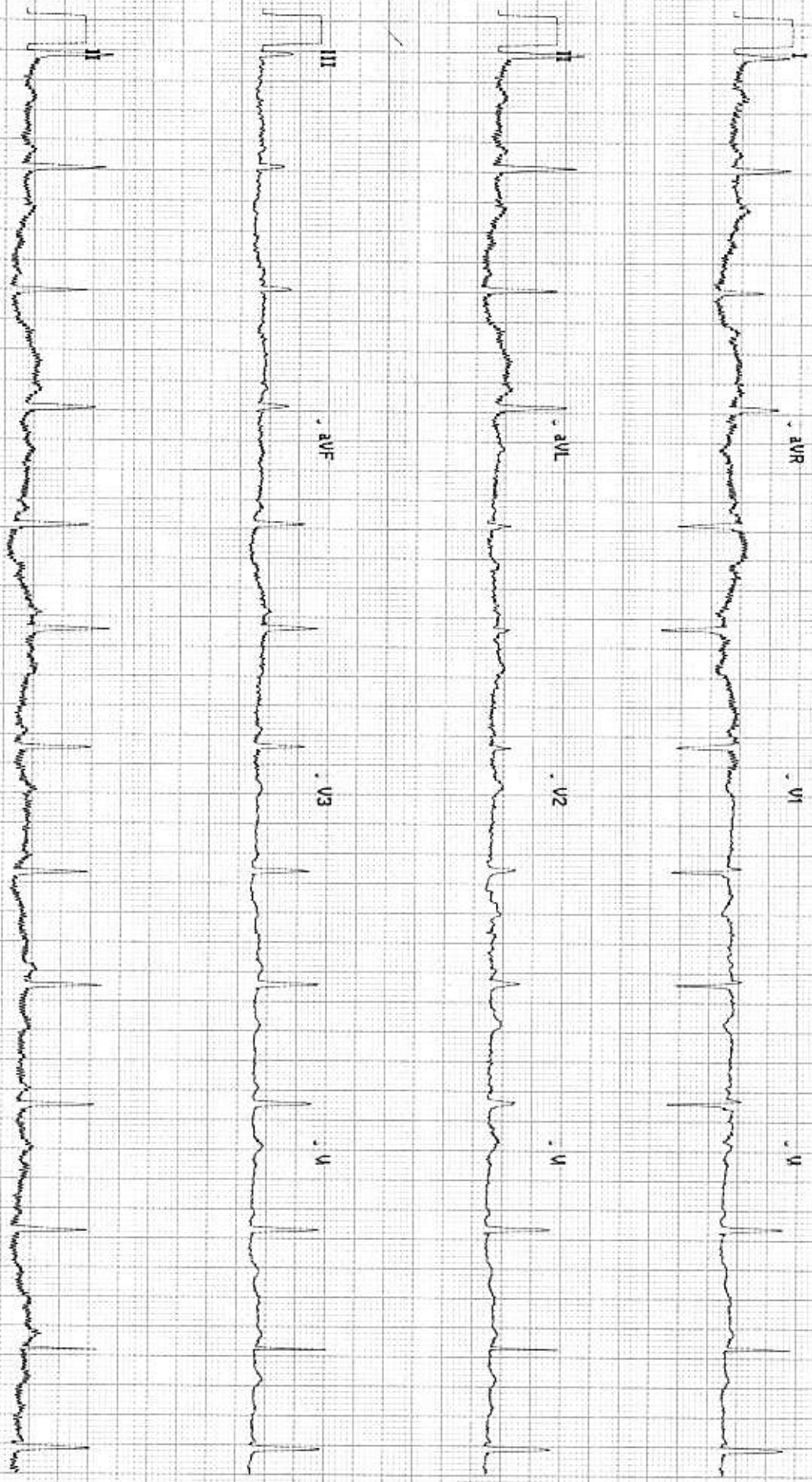
The Clinical AI Models and APIs used at Apollo Hospitals are certified by ISO 13485 : 2016 vide certificate no. MD 763515

Shinde, Sunita
ID:
DOB:
55yr, Female

10-Dec-2022 10:21:1

Vent rate: 73 BPH
PR int: 116 ms
QRS dur: 82 ms
QT/QTc: 368/393 ms
P-R-T axes: 33 47 -1

SINUS RHYTHM WITH SHORT PR INTERVAL
POSSIBLE RIGHT VENTRICULAR CONDUCTION DELAY (RSR (R) IN V1/V2)
NONSPECIFIC ST & T-WAVE ABNORMALITY
BORDERLINE ECG
UNCONFIRMED REPORT



11350018B213

No Site Name

ite # 0 Carl # 2 Version 2.0.4.0 Sequence #21169 25mm/s 10m/mV 0.05-40 Hz



Swaminarayan Nagar, Off Mumbai-Agra Highway,
Panchvati, Nashik - 422 003.
+91- 253 - 2510250 / 350 / 450 / 550 / 750
apollonashik@apollohospitals.com
www.askapollo.com

QFAHN/BILL/003/V1



Apollo
HOSPITALS
NASHIK

Screening Echocardiography Report

Name: - Mrs.SUNITA SHINDE
UHID No: - MHN1.0000130024
Referred by: -Dr. Nrmal kolte
Echo window: - Good

Age/Sex: 51/F
DATE: 10/12/2022
Echo No: -31418

Rheumatic Heart Disease.
Sclerodegenerative Aortic and Mitral valves. Mild MR.
Normal all rest of valves and chambers.
Normal LV systolic function. No RWMA at rest.
Normal RV systolic function.
LV diastolic dysfunction.
AO/LA= 28 mm/ 32mm, LVIDd/LVIDs= 43mm/27mm, IVS/PW= 11 mm/ 11 mm.
No PAH.
No Clot/ Vegetation/Pericardial effusion.
No Coarctation.

Impression: -

Sclerodegenerative Aortic and Mitral valves. Mild MR.
Normal all valves and chambers.
Normal LV systolic function. No RWMA at rest.
Normal RV systolic function.
LV diastolic dysfunction.
No PAH.
No clot/ vegetation/pericardial effusion.
No Coarctation.


DR.NIRMAL KOLTE




Swaminarayan Nagar, Off Mumbai-Agra Highway,
Panchvati, Nashik - 422 003.
+91- 253 - 2510250 / 350 / 450 / 550 / 750
apollonashik@apollohospitals.com
www.askapollo.com

QFAHN/BILL/003/V1



Apollo
HOSPITALS
NASHIK

MD (Radiology)

Patient Details : Mrs. SUNITA B SHINDE | Female | 51Yr 0Mth 24Days
UHID : MHN1.0000130024 **Patient Location:** AHC
Patient Identifier: NSKAH28485 
DRN : 1322003426 **Completed on :** 10-DEC-2022 13:28
Ref Doctor : Dr. Rajashri Dhongade

MAMMOGRAPHY

Bilateral mammograms have been obtained using a low radiation dose film screen technique in the craniocaudal and oblique projections. Film markers are in the axillary/lateral portions of the breasts.

The study reveals :

Both breasts reveal mixed fatty and fibroglandular parenchyma.

There is no obvious evidence of a focal spiculated mass lesion, architectural distortion, focal asymmetry or clusters of microcalcifications seen to suggest presence of a malignancy.

Nipple and subcutaneous tissues are normal.

Impression

- 1) No significant abnormality is seen on this study.
- 2) BI - RADS - Category 1.

Suggest : Clinical correlation.

--- END OF THE REPORT ---

Kunal Kalyanrao Patil

Consultant - MD (Radiodiagnosis)



Swaminarayan Nagar, Off Mumbai-Agra Highway,
Panchvati, Nashik - 422 003.
+91- 253 - 2510250 / 350 / 450 / 550 / 750
apollonashik@apollohospitals.com
www.askapollo.com

QFAHN/BILL/003/V1



Apollo
HOSPITALS
NASHIK

MD (Radiology)

Patient Details : Mrs. SUNITA B SHINDE | Female | 51Yr 0Mth 24Days

UHID : MHN1.0000130024

Patient Location: AHC

Patient Identifier: NSKAH28485



DRN : 122049018

Completed on : 10-DEC-2022 09:43

Ref Doctor : Dr. Rajashri Dhongade

X-RAY CHEST PA

Both lung fields are clear.

Both hila are normal in size and position.

Costophrenic and cardiophrenic angles are clear.

Cardiac size and contour are within normal limits.

Rib cage is normal.

Soft tissues are normal.

Impression

No significant abnormality is detected.

--- END OF THE REPORT ---

Kunal Kalyanrao Patil

Consultant - MD (Radiodiagnosis)




Swaminarayan Nagar, Off Mumbai-Agra Highway,
Panchvati, Nashik - 422 003.
+91- 253 - 2510250 / 350 / 450 / 550 / 750
apollonashik@apollohospitals.com
www.askapollo.com

QFAHN/BILL/003/V1



Apollo
HOSPITALS
NASHIK

MD (Radiology)

Patient Details : Mrs. SUNITA B SHINDE | Female | 51Yr 0Mth 24Days
UHID : MHN1.0000130024 **Patient Location:** AHC
Patient Identifier: NSKAH28485 
DRN : 222029982 **Completed on :** 10-DEC-2022 11:24
Ref Doctor : Dr. Rajashri Dhongade

ULTRASOUND - WHOLE ABDOMEN

LIVER : Normal in size. Diffuse increase in echogenicity of the liver parenchyma is suggestive of fatty infiltration.
No I.H.B.D./ focal lesions.

PORTAL VEIN: Normal in size.

GALL BLADDER: Well distended with normal walls and lumen.
No calculi/pericholecystic fluid.

COMMON BILE DUCT: Normal in size.

PANCREAS : Visualized portion of head and body of pancreas appears normal in size and echotexture. Rest of the pancreas is obscured due to bowel gases.

AORTA, IVC and para aortic areas are normal.

SPLEEN : Normal in size and echotexture.

KIDNEYS: Both kidneys are normal in site, size and echotexture.

No evidence of calculi/ hydronephrosis.

Right kidney measures: 10.5 x 4.2 cm.

Left kidney measures : 10.1 x 4.9 cm.

URINARY BLADDER: Well distended with normal walls.

No evidence of calculi/ growth/ diverticula .

UTERUS: Retroverted. Retroflex. Normal in size and echotexture.

Uterus measures :3.6 x 4.3 x 7.7 cm.



Swaminarayan Nagar, Off Mumbai-Agra Highway,
Panchvati, Nashik - 422 003.
+91- 253 - 2510250 / 350 / 450 / 550 / 750
apollonashik@apollohospitals.com
www.askapollo.com

QFAHN/BILL/003/V1



Apollo
HOSPITALS
NASHIK

Mrs. SUNITA B SHINDE

MHN1.0000130024

NSKAH28485

ULTRASOUND - WHOLE ABDOMEN

Combined endometrial thickness is normal and measures 8.4mm.

OVARIES:

Right ovary measures : 2.9 x 2.2 cm.

Left ovary measures : 3.0 x 2.1 cm.

Normal in size and echotexture.

Visualized bowel loops appear grossly normal.

No evidence of any free fluid in the peritoneal cavity.

Impression

Grade I fatty infiltration of liver.

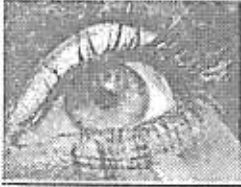No other significant abnormality is detected.

--- END OF THE REPORT ---

Kunal Kalyanrao Patil

Consultant - MD (Radiodiagnosis)

Apollo
HOSPITALS
NASHIK



OPHTHALMOLOGY



| | |
|---|---|
| Name : <u>Mrs. Sumita B. Shinde</u> Occupation : _____ Age : <u>52</u> Sex : Male <input type="checkbox"/> Female <input type="checkbox"/> S/M/W/D Address : <u>Nsle</u> Tel. No. _____ | Date <u>20/12/22</u> UNIT _____ Room No. _____ Out Patient <input type="checkbox"/> Ref. Physician : _____ Copies to : _____ |
|---|---|

REPORT ON OPHTHALMIC EXAMINATION

HISTORY : _____

PRESENT COMPLAINT : No Complaint

PAST HISTORY : DM / HTN / ALLERGY

ON EXAMINATION

VISION :

| | | | | | | | | | | |
|--|------|---------------|-----|-----|------|---------------|-----|-----|------|----|
| | | RE | | | | LE | | | | |
| | | <u>VA 6/6</u> | | | | <u>VA 6/6</u> | | | | |
| | | RIGHT | | | | LEFT | | | | |
| | | PGP | SPH | CYL | AXIS | VA | SPH | CYL | AXIS | VA |
| | DIST | | | | | | | | | |
| | NEAR | | | | | | | | | |

AR / Retinoscopy :

| | | | | | | |
|--|----------|-------------|------------|-------------|-------------|------------|
| | RIGHT | | | LEFT | | |
| | SPH | CYL | AXIS | SPH | CYL | AXIS |
| | <u>+</u> | <u>+</u> | <u>81°</u> | <u>+</u> | <u>+</u> | <u>72°</u> |
| | <u>-</u> | <u>0.25</u> | | <u>0.25</u> | <u>0.50</u> | |

Refraction or Acceptance :

| | | | | | | | | |
|--|-------------|-----------|------|------------|-------------|-----------|------|------------|
| | RIGHT | | | | LEFT | | | |
| | SPH | CYL | AXIS | VA | SPH | CYL | AXIS | VA |
| | | | | | | | | |
| | | <u>pl</u> | | <u>6/6</u> | | <u>pl</u> | | <u>6/6</u> |
| | <u>+</u> | | | <u>Nil</u> | <u>+</u> | | | <u>Nil</u> |
| | <u>2.25</u> | | | | <u>2.25</u> | | | |

Add

[Handwritten Signature]

[Handwritten Signature]

CONSULTANT OPTOMETRIST