



A ISO 9001: 2015 Certified Lab  
Bal. 2590

# S.V. SCIENTIFIC PATHOLOGY MEDEXIQ

SONKH ROAD, KRISHNA NAGAR, MATHURA

**DR. SHIKHA VYAS**

D.C.P. (PATH.)

R.NO. 52957/ 17.08.2006

Date	22/09/2022	Srl No.	106	Sex	F
Name	MRS. PREETI VERMA	Age	30 Yrs.	OUT SIDE SAMPLE	
Ref. By	C/O BOB				

Investigation Name	Result Value	Unit	Biomedical Ref Range
--------------------	--------------	------	----------------------

### HAEMATOLOGY - TEST REPORT

#### C. B. C

HAEMOGLOBIN (HB)	9.1	gm/dl	11.5 - 16.0
TOTAL LEUCOCYTIC COUNT (TLC)	8,700	/cumm	4000 - 11000
<b>DIFFERENTIAL LEUCOCYTE COUNT (DLC)</b>			
NEUTROPHIL	64	%	40 - 80
LYMPHOCYTE	31	%	20 - 40
EOSINOPHIL	03	%	1 - 6
MONOCYTE	02	%	2 - 10
BASOPHIL	00	%	1 - 2
R B C	4.85	millions/cmm	3.8 - 4.8
P.C.V / HAEMATOCRIT	28.6	%	36.0 - 46.0
M C V	59.0	fl.	82.0 - 101.0
M C H	18.8	picogram	27.0 - 32.0
M C H C	31.8	gm/dl	31.5 - 34.5
PLATELET COUNT	158	$\times 10^3/\mu\text{L}$	150 - 450
MEAN PLATELET VOLUME	10.2	fl	7.5 - 11.5
RDW-CV	14.9	%	11.5 - 14.5
ERYTHROCYTE SED.RATE(WGN)	18	mm/1st hr.	0.00 - 20.0
Automated Mini ESR			

### BIOCHEMISTRY - TEST REPORT

BLOOD SUGAR RANDOM	98.7	mg/dl	80 - 160
--------------------	------	-------	----------

### L.F.T / LIVER FUNCTION TEST

TOTAL BILIRUBIN	0.56	mg/dl	0.20 - 1.00
-----------------	------	-------	-------------

Reference range



Contd...2

All Tests have Technical Limitations. Collaborative clinicopathological interpretation is mandatory. In Case of disparity Test may be repeated immediately. Test marked with an (\*) are not accredited by NABL.

**Mathura Lab Details :**

Opp. Vipin Nursing Home, Shankar Vihar, Krishna Nagar, Mathura- 281004

Mob. ☎ 08954464646, ☎ 7055111414 | Email : svspathology@gmail.com

Website : www.svscientificpathology.com

Sample Collection Facility from Home & Nursing Home is available.

If required get your report Via  
**SMS & Email**

**NOT VALID FOR  
MEDICOLEGAL PURPOSE**

# S.V. SCIENTIFIC PATHOLOGY MEDEXIQ

DR. SHIKHA VYAS

D.C.P. (PATH.)

R.NO. 52957/ 17.08.2006

SONKH ROAD, KRISHNA NAGAR, MATHURA

Scientific Pathology  
A ISO 9001: 2015 Certified Lab  
Bal. 2590

Date	22/09/2022	Srl No.	106	Sex	F
Name	MRS. PREETI VERMA	Age	30 Yrs.	OUT SIDE SAMPLE	
Ref. By	C/O BOB				

Investigation Name	Result Value	Unit	Biomedical Ref Range
--------------------	--------------	------	----------------------

Reference range according to Thomas

Total bilirubin : up tp 1.1 mg/dl

Reference range according to Sherlock and Meites

Adults and children : up to 1.0 mg/dl

**New born**

**Age of new born**

24 hours

48 hours

3 - 5 days

**Age of new born**

24 hours

48 hours

3-5 days

**Premature**

1.0 - 6.0 mg/dl

6.0 - 8.0 mg/dl

10.0 - 15.0 mg/dl

**Full term**

2.0 - 6.0 mg/dl

6.0 - 7.0 mg/dl

4.0 - 12.0 mg/dl

CONJUGATED (D. Bilirubin)	0.32	mg/dl	0.1 - 0.4
UNCONJUGATED (I.D. Bilirubin)	0.24	mg/dl	0.2 - 0.7
TOTAL PROTEINS	6.85	gm/dl	6.0 - 8.2
ALBUMIN	3.91	gm/dl	3.5 - 5.2
GLOBULIN	2.94	gm/dl	2.3 - 3.5
A/G RATIO	1.33	gm/dl	0.8 - 2.0
S.G.O.T (AST)	25.9	U/L	0.0 - 35.0
S G.P.T (ALT)	24.1	U/L	0.0 - 45.0
ALKALINE PHOSPHATASE OPTIMIZED	102.3	U/L	0 - 0

**Expected Values :**

Aged 1 Day	< 250 U/L
Aged 2 to 5 Days	< 231 U/L
Aged 6 Days to 6 Months	< 449 U/L
Aged 7 Months to 1 Year	< 426 U/L
Aged 1 - 3 Yrs	< 281 U/L
Aged 4 - 6 Yrs	< 269 U/L
Aged 7 - 12 Yrs	< 300 U/L
Aged 13 - 17 Yrs ( Male)	< 390 U/L

Contd...3



All Tests have Technical Limitations. Collaborative clinicopathological interpretation is mandatory. In Case of disparity Test may be repeated immediately. Test marked with an (\*) are not accredited by NABL.

**Mathura Lab Details :**

Opp. Vipin Nursing Home, Shankar Vihar, Krishna Nagar, Mathura- 281004

Mob. ☎ 08954464646, ☎ 7055111414 | Email : svspathology@gmail.com

Website : www.svscientificpathology.com

Sample Collection Facility from Home & Nursing Home is available.

If required get your report Via

**SMS & Email**

**NOT VALID FOR  
MEDICOLEGAL PURPOSE**



# S.V. SCIENTIFIC PATHOLOGY MEDEXIQ

DR. SHIKHA VYAS

D.C.P. (PATH.)

R.NO. 52957/ 17.08.2006

SONKH ROAD, KRISHNA NAGAR, MATHURA

Scientific Pathology  
A ISO 9001: 2015 Certified Lab  
Bal. 2590

Date	22/09/2022	Srl No.	106	Sex	F
Name	MRS. PREETI VERMA	Age	30 Yrs.	OUT SIDE SAMPLE	
Ref. By	C/O BOB				

Investigation Name	Result Value	Unit	Biomedical Ref Range
Aged 13 - 17 Yrs ( Female)	< 187 U/L		
Men ( Adult)	40 - 129 U/L		
Women ( Adult)	35 - 104 U/L		
<b>G G T P</b>	20.50	U/L	0.80 - 55.0
<b>LIPID PROFILE</b>			
<b>SERUM CHOLESTEROL</b>	154.7	mg/dl	
Optimal	< 200	mg/dl	
Border Line High Risk	200 - 239	mg/dl	
High Risk	> 240	mg/dl	
<b>TRIGLYCERIDES</b>	89.6	mg/dL	
Optimal	< 150	mg/dl	
Border Line High Risk	150 - 199	mg/dl	
High Risk	200 - 499	mg/dl	
Very High Risk	> 500	mg/dl	
<b>H D L CHOLESTEROL( direct )</b>	52.1		
Optimal>	<u>Male</u> 55 mg/dl	<u>Female</u> > 65 mg/dl	
Border Line High Risk	35 - 55 mg/dl	45 - 65 mg/dl	
High Risk	< 35 mg/dl	< 45 mg/dl	
<b>L D L CHOLESTEROL ( DIRECT )</b>	84.68	mg/dl	
Optimal	<100	mg/dl	
Near or Above Optimal	100 - 129	mg/dl	
Border Line High Risk	130 - 159	mg/dl	
High Risk	160 - 189	mg/dl	
Very High Risk	> 190	mg/dl	
<b>V L D L</b>	17.92	mg/dl	25.0 - 40.0

Contd...4



All Tests have Technical Limitations. Collaborative clinicopathological Interpretation is mandatory. In Case of disparity Test may be repeated immediately. Test marked with an (\*) are not accredited by NABL.

## Mathura Lab Details :

Opp. Vipin Nursing Home, Shankar Vihar, Krishna Nagar, Mathura- 281004

Mob. 08954464646, 7055111414 | Email : svspathology@gmail.com

Website : www.svscientificpathology.com

Sample Collection Facility from Home & Nursing Home is available.

If required get your report Via  
SMS & Email

NOT VALID FOR  
MEDICOLEGAL PURPOSE

Date	22/09/2022	Srl No.	106	Sex	F
Name	MRS. PREETI VERMA	Age	30 Yrs.	OUT SIDE SAMPLE	
Ref. By	C/O BOB				

Investigation Name	Result Value	Unit	Biomedical Ref Range
SERUM CHOLESTEROL/HDL RATIO	2.969		
LDL / HDL CHOLESTEROL RATIO	1.625		0.00 - 3.55

### R.O. risk factor

Risk Factor of Coronary Heart Disease.

Positive Risk Factors

1. Age - Males >45 Yrs.  
Females >55 Yrs. or premature menopause without estrogen replacement therapy.
  2. Family history of premature coronary heart disease.
  3. Cigarette smoking.
  4. Hypertension (>140/90 mm Hg or on antihypertensive medication)
  5. Low HDL Cholesterol <30 mg/dl
  6. Diabetes mellitus
- Negative Risk Factor
1. High HDL Cholesterol >60 mg/dl

### K.F.T / KIDNEY FUNCTION TEST

BLOOD UREA	31.2	mg /dl	15.0 - 45.0
CREATININE	0.78	mg/dl	0.50 - 1.30

Neonates(premature): 0.29 - 1.04  
Neonates(Full term): 0.24 - 0.85  
2 - 12 Months : 0.17 - 0.42  
1 - <3 Yrs : 0.24 - 0.41  
3 - <5 Yrs : 0.31 - 0.47  
5 - <7 Yrs : 0.32 - 0.59  
7 - <9 Yrs : 0.40 - 0.60  
9 - <11 Yrs : 0.39 - 0.73  
11 - <13 Yrs : 0.53 - 0.79  
13 - <15 Yrs : 0.57 - 0.87

URIC ACID	4.10	mg/dl	2.4 - 5.70
-----------	------	-------	------------

Contd...5



All Tests have Technical Limitations. Collaborative clinicopathological interpretation is mandatory. In Case of disparity Test may be repeated immediately. Test marked with an (\*) are not accredited by NABL.

### Mathura Lab Details :

Opp. Vipin Nursing Home, Shankar Vihar, Krishna Nagar, Mathura- 281004

Mob. 08954464646, 7055111414 | Email : svspathology@gmail.com

Website : www.svscientificpathology.com

Sample Collection Facility from Home & Nursing Home is available.

If required get your report Via  
SMS & Email

NOT VALID FOR  
MEDICOLEGAL PURPOSE



# S.V. SCIENTIFIC PATHOLOGY MEDEXIQ

DR. SHIKHA VYAS

D.C.P. (PATH.)

R.NO. 52957/ 17.08.2006

SONKH ROAD, KRISHNA NAGAR, MATHURA

Scientific Pathology  
A ISO 9001: 2015 Certified Lab  
Bal. 2590

Date	22/09/2022	Srl No.	106	Sex	F
Name	MRS. PREETI VERMA	Age	30 Yrs.	OUT SIDE SAMPLE	
Ref. By	C/O BOB				

Investigation Name	Result Value	Unit	Biomedical Ref Range
INORGANIC PHOSPHORUS	3.85	mg/dl	2.7 - 4.5

### BIOCHEMISTRY - TEST REPORT

S.SODIUM	140.2	mmol/L	137.0 - 145.0
S.POTASSIUM	4.45	mmol/L	3.6 - 5.0
CALCIUM	9.36	mg/dl	8.4 - 10.2

### URINE EXAMINATION -TEST REPORT

#### PHYSICAL EXAMINATION

COLOUR	LIGHT YELLOW
TRANSPARENCY	TURBID
SPECIFIC GRAVITY	1.020
pH	6.5

#### CHEMICAL EXAMINATION

ALBUMIN	TRACE
REDUCING SUGAR	NIL
BILE SALTS	NEGATIVE
BILE PIGMENT	NEGATIVE
KETONE BODIES /ACETONE	NEGATIVE

#### MICROSCOPIC EXAMINATION

PUS CELLS	8-9	/HPF
EPITHELIAL CELLS	10-12	/HPF
RBC's	2-3	/HPF
CRYSTALS	NIL	
CASTS	NIL	
BACTERIA	NIL	

Contd...6



All Tests have Technical Limitations. Collaborative clinicopathological interpretation is mandatory. In Case of disparity Test may be repeated immediately. Test marked with an (\*) are not accredited by NABL.

#### Mathura Lab Details :

Opp. Vipin Nursing Home, Shankar Vihar, Krishna Nagar, Mathura- 281004

Mob. 08954464646, 7055111414 | Email : svspathology@gmail.com

Website : www.svscientificpathology.com

Sample Collection Facility from Home & Nursing Home is available.

If required get your report Via  
SMS & Email

NOT VALID FOR  
MEDICOLEGAL PURPOSE



# S.V. SCIENTIFIC PATHOLOGY

## MEDEXIQ

**DR. SHIKHA VYAS**

D.C.P. (PATH.)

R.NO. 52957/ 17.08.2006

SONKH ROAD, KRISHNA NAGAR, MATHURA

Date 22/09/2022

Name MRS. PREETI VERMA

Ref. By C/O BOB

Srl No. 106

Age 30 Yrs.

Sex F

OUT SIDE SAMPLE

OTHERS

NIL

\*\*\*\* Report Completed\*\*\*\*



**DR. SHIKHA VYAS**

D.C.P ( Path.)

R.NO 52957 / 17.08.2006

All Tests have Technical Limitations. Collaborative clinicopathological interpretation is mandatory. In Case of disparity Test may be repeated immediately. Test marked with an (\*) are not accredited by NABL.

**Mathura Lab Details :**

**Opp. Vipin Nursing Home, Shankar Vihar, Krishna Nagar, Mathura- 281004**

**Mob. 08954464646, 7055111414 | Email : svspathology@gmail.com**

**Website : www.svscientificpathology.com**

**Sample Collection Facility from Home & Nursing Home is available.**

**If required get your report Via SMS & Email**

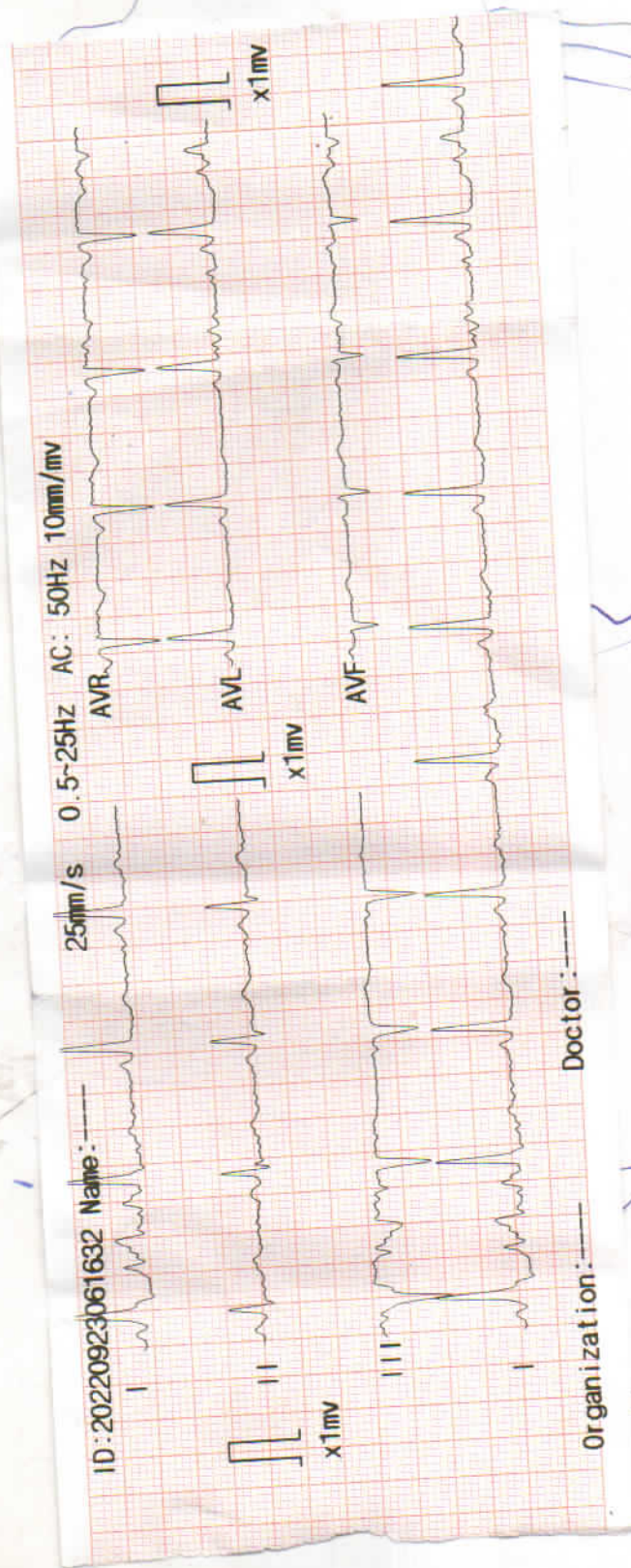
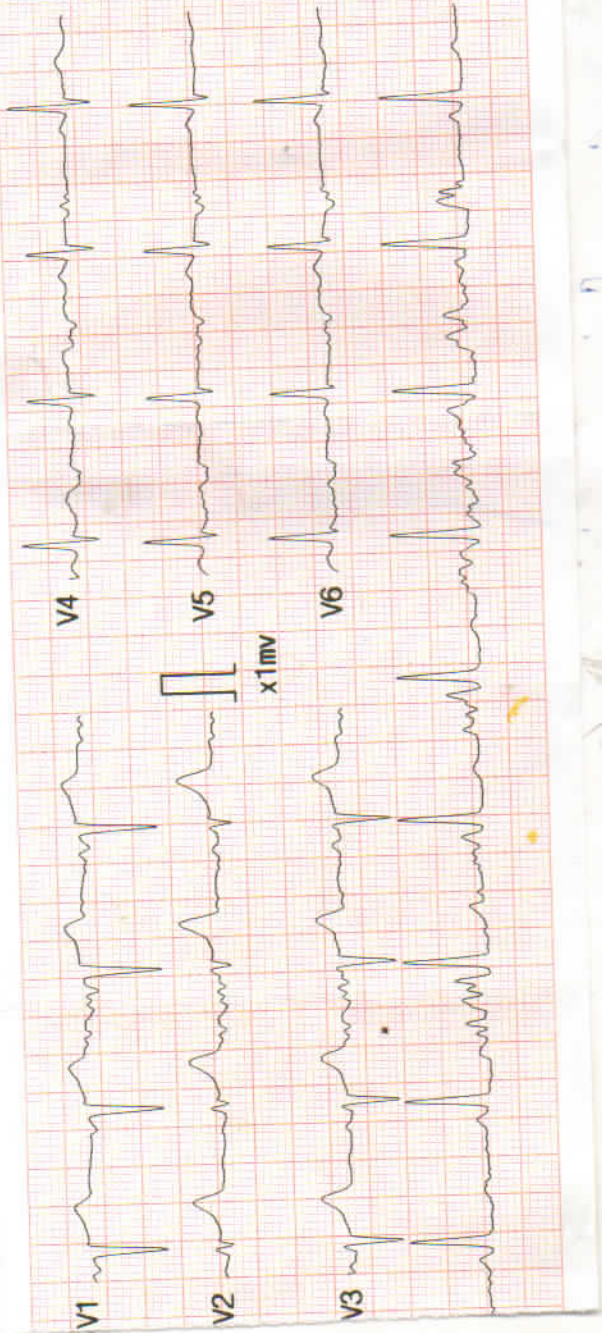
**NOT VALID FOR MEDICOLEGAL PURPOSE**



ID : 20220923061632

Name : *Breeti Singh*  
Sex : Female

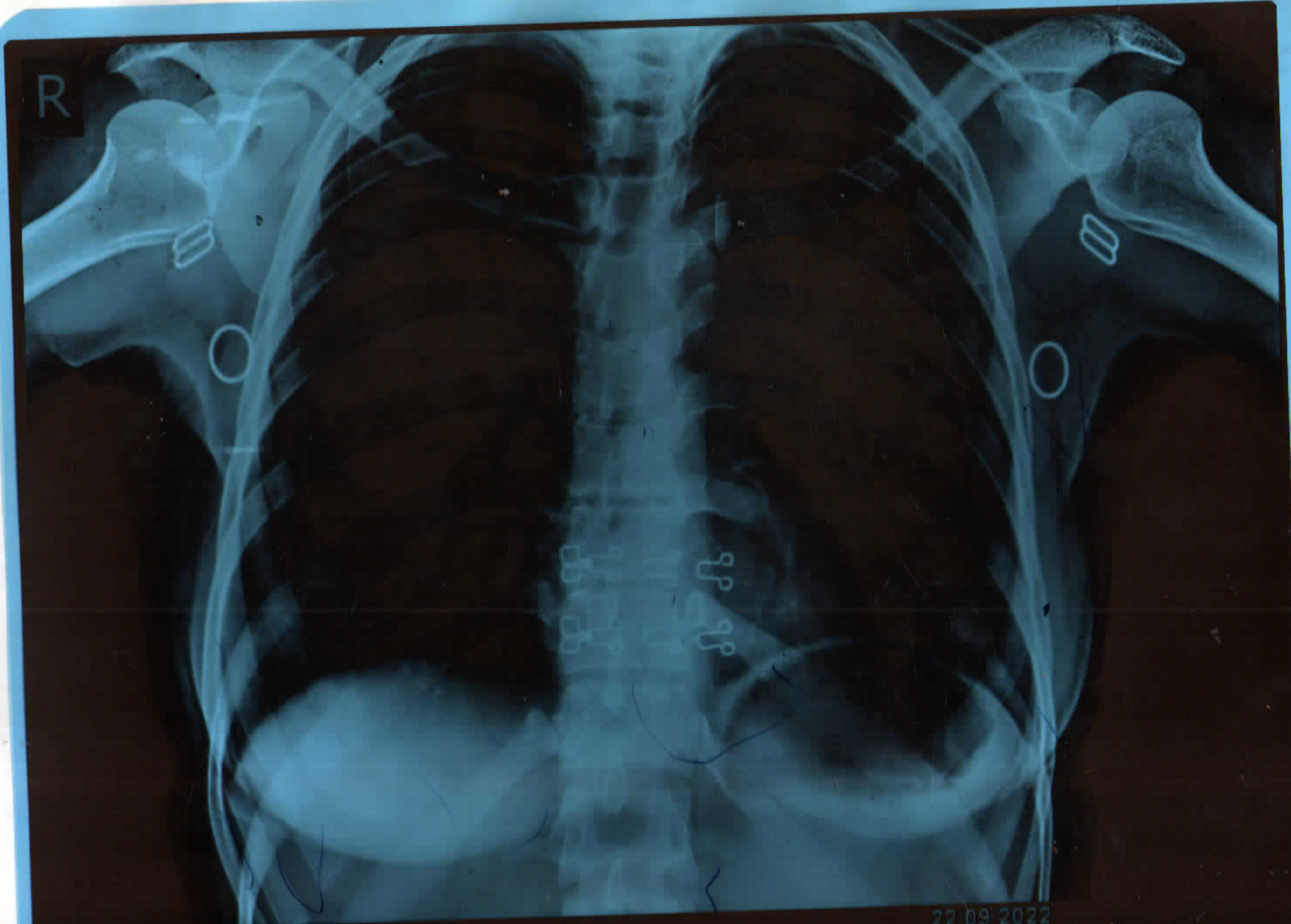Age : 1  
HR : 79 bpm  
R-R : 746 ms  
P-R : 156 ms  
QRS : 82 ms  
QT/QTc : 357/411 ms  
P/QRS/T : 160/-11/ 66  
RV5/SV1 : 0.630/-0.914 mV  
RV5+SV1 : -0.283 mV  
QTcf : 0.478



25mm/s 0.5-25Hz AC: 50Hz 10mm/mv

ID: 20220923061632 Name: ---

Organization: --- Doctor: ---



PRITI 30Y Female

Chest PA

BHARTI HOSPITAL SONKH ROAD, KRISHNA NAGAR, MATHURA

22/09/2022





# Bharti Hospital

An ISO 9001 : 2008 (QMS) Certified Hospital

Date : .....

REG...NO: 2022-902502  
NAME: MRS. PREETI VERMA  
REF...BY: BOB

DATE: 25/09/2022  
AGE: 30 Y/F

## ECHOCARDIOGRAPHY REPORT

### Measurements

Aortic root diameter:	26 mm	(20-37mm)
Aortic valve diameter:	15 mm	(15-26mm)
LV dimension:		(19-40mm)
LVD(systolic):	29 mm	(22-40mm)
LVD(diastolic):	40 mm	(37-56mm)
RVD(diastolic):	12 mm	(7-23mm)
IVST	ES:12.2	ED: 9.0
LVPWT	ES:11.3	ED: 8.6
LA(diastolic):	28.6mm	(19-40mm)

### INDICES OF LV FUNCTION:

EPSS		(< 9mm)
Fractional shortening	30%	(24-42%)
Ejection fraction	60%	(50-70%)

### IMAGING:

M mode examination revealed normal movements of both mitral leaflets during diastole(DE-18mm,EF-130mm/sec). No mitral valve prolapse is seen.

Aortic cusps are not thickened and closure line is central, tricuspid and pulmonary valves are normal. Aortic root is normal in size.

Dimension of left atrium and left ventricle are normal.

**2D imaging in PLAX, SAX and apical view** revealed a normal size left ventricle.

No regional wall motion abnormality present.

Global LVEF is 60%.

Mitral valve opening is normal. No mitral valve prolapse is seen.

Aortic valve has three cusps and its opening is not restricted.

Tricuspid valve leaflets move normally. Pulmonary valve is normal.

Interatrial and interventricular septa are intact.

**No intra cardiac mass or thrombus is seen. No pericardial effusion is seen.**

Facilities

ICU, Facility for Medical & Cardiac Emergency, ECG, Nebulizer, Centralized Oxygen, Monitor BIPAP, Defibrillator, Echo Cardiography, TMT, X-ray, PFT, Computerised Pathology

यहाँ भ्रूण-लिंग परीक्षण नहीं किया जाता है। यह एक दृष्टनीय अपराध है।

This Report is only A Professional Opinion & Should Be Clinically Co-related

NOT VALID FOR MEDICO-LEGAL PURPOSE

सभी प्रकार के हैल्थ चैकअप पैकेज उपलब्ध



# Bharti Hospital

An ISO 9001 : 2008 (QMS) Certified Hospital

Date : .....

## DOPPLER :

MV	0.92/0.51m/sec.	MR : nil
AV	0.87 m/sec.	AR : nil
TV	0.48 m/sec.	TR : nil
PV	0.73 m/sec.	PR : nil

## COLOUR FLOW

Normal flow signals are seen across all cardiac valves.  
No flow signals are seen across IAS and IVS.

## FINAL DIAGNOSIS :

Normal cardiac chamber dimension  
No regional wall motion abnormality is present.  
Systolic left ventricle function is normal with EF 60%.  
Diastolic left ventricle function is normal.  
Colour flow through all the valves is normal with no structural abnormality.  
No intracardiac thrombus or mass is seen.  
No pericardial effusion is present.

DR. BHARTI GUPTA (M.D)

All congenital heart defect can not be detected by transthoracic echocardiography.  
In case of disparity test should be repeated at higher cardiac centre. Not valid for medico-legal purpose.

### Facilities

ICU, Facility for Medical & Cardiac Emergency, ECG, Nebulizer, Centralized Oxygen, Monitor BIPAP, Defibrillator, Echo Cardiography, TMT, X-ray, PFT, Computerised Pathology

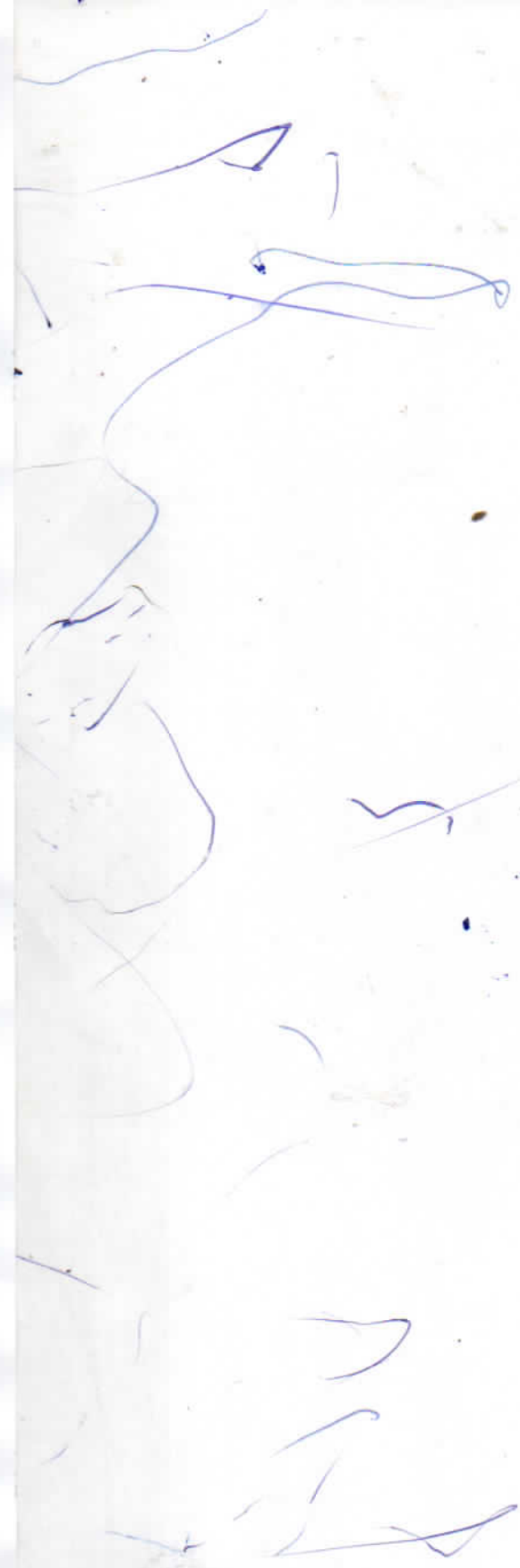
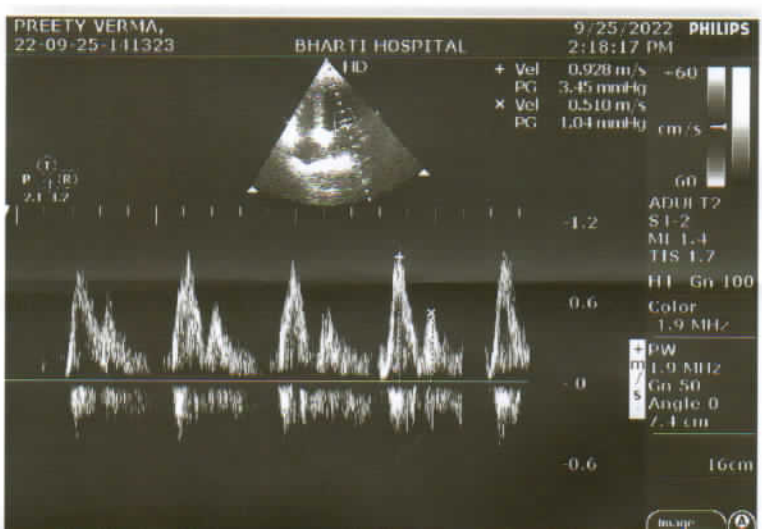
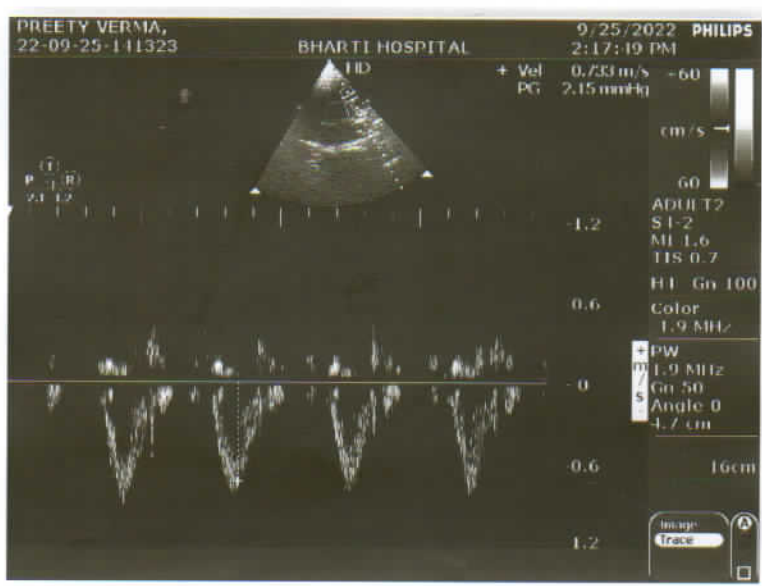
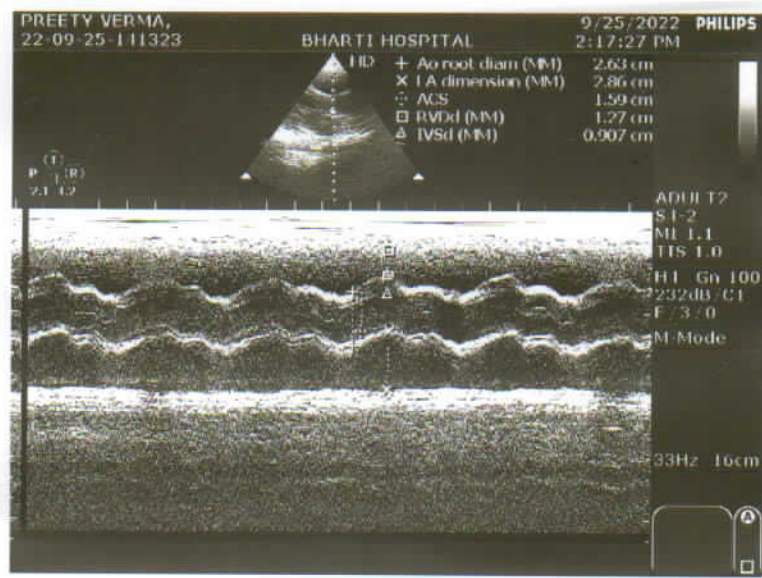
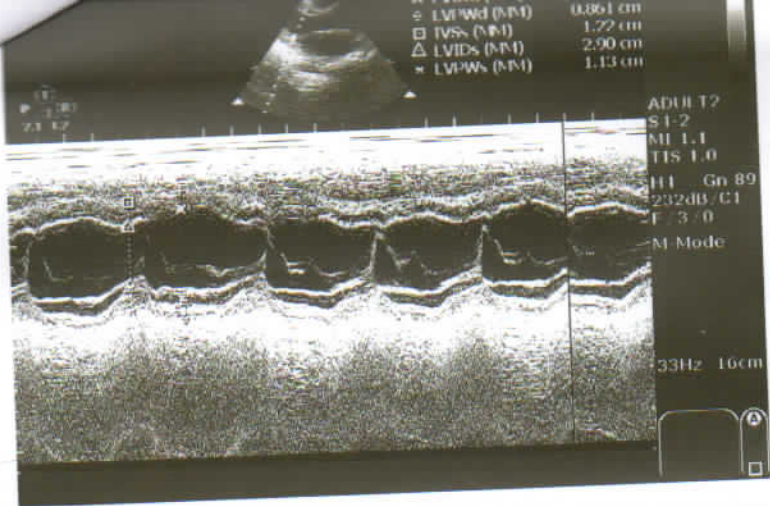
यहाँ भ्रूण-लिंग परीक्षण नहीं किया जाता है। यह एक दण्डनीय अपराध है।

This Report is only A Professional Opinion & Should Be Clinically Co-related

NOT VALID FOR MEDICO-LEGAL PURPOSE

सभी प्रकार के हेल्थ चैकअप पैकेज उपलब्ध







# Bharti Hospital

An ISO 9001 : 2008 (QMS) Certified Hospital

Date : .....

REG...NO : 2022-902503  
NAME : MRS. PREETI SINGH  
REF...BY: B O B

DATE : 25/09/2022

AGE /SEX: 30 Y/F

## 2D REAL TIME GENERAL SONOLOGICAL STUDY OF WHOLE ABDOMEN

**LIVER:** Is normal in size & parenchymal echotexture. Margins are regular. Intra hepatic bile ducts (IHD) are not dilated. No focal mass seen. Portal Vein & C.B.D. is normal in caliber.

**GALL BLADDER:** No calculi/mass lesion is seen in its lumen. No pericholecystic collection is seen.

**SPLEEN:** is normal in size and shape. Echotexture appears normal.

**PANCREAS:** Shows normal size and echotexture. No focal mass / peripancreatic collection is seen.

**RIGHT KIDNEY:** Shows normal position, size, shape and contour. Cortical echotexture is normal. CMD is maintained. No calculus /hydronephrosis is seen.

**LEFT KIDNEY:** Shows enlarged in size, shape and contour. Cortical echotexture is normal. CMD is maintained. No hydronephrosis.

No free fluid/ retroperitoneal adenopathy is seen.

**U.BLADDER:** is normal in distension and in wall thickness. Lumen is clear. No calculus or mass lesion is seen.

**UTERUS:** is bulky. Normal in size and echotexture. Endometrial thickness is 8.0mm. No focal or diffuse mass lesion is seen. Cervix appears normal.

Both ovaries are normal in size and echotexture.

*Small amount of fluid is seen in cul de sac.*

**NOTE-** Excessive Gas is Present in Abdomen.

**IMPRESSION:** Mild PID.

**ADVICE:** Clinical Correlation.

SONOLOGIST

Best efforts were made during investigation, however in case of any Confusion/ Confirmation review can be done, free of cost. Not valid for medico-legal purpose.

Facilities

ICU, Facility for Medical & Cardiac Emergency, ECG, Nebulizer, Centralized Oxygen, Monitor BIPAP, Defibrillator, Echo Cardiography, TMT, X-ray, PFT, Computerised Pathology

यहाँ भ्रूण-लिंग परीक्षण नहीं किया जाता है। यह एक दण्डनीय अपराध है।

This Report is only A Professional Opinion & Should Be Clinically Co-related

NOT VALID FOR MEDICO-LEGAL PURPOSE

सभी प्रकार के हेल्थ चेकअप पैकेज उपलब्ध



