

# डॉ. सविता क्लिनिक

34, भूतल, मोहिनी अदिति आर्केड, शाहपुरा मस्जिद के पास  
भरत नगर रोड, ई-7/194, अरेरा कॉलोनी, भोपाल - 462038

Mob. : 8989649694, 9516333619

Clinic Registration : CL/5392/Jun/2017

PNDT Registration : MPPCPNDT/BPL/2017/206



Name : Mrs. Rani Paiswa Age 35 YRS./F.  
R/B Health check-up No. .... Date 9/8/2022

## WHOLE ABDOMES ULTRASOUND REPORT

### Indication:

Liver appears normal in size and shape with normal outline. Normal/  
increased perenchymal echogenicity is noted. No E/O focal lesion/ IHBR  
dilatation is seen. Hepatic veins and portal veins appear normal.

No E/O subdiaphragmatic Collection.

Gall Bladder is physiologically well distended. No. E/O echogenic foci in GB  
lumen. GB wall is normal / thickened. No E/O pericholecystic collection.  
Common duct reveals normal course and caliber.

Pancreas appear normal in size, shape and echo texture with smooth  
contour. No peripancreatic pathology seen. (Not seen due to gases)

Spleen is normal in size and echo texture.

IVC and aorta appear to be normal.

No evidence of lymphadenopathy is noted.

No evidence of free fluid is noted.

Right Kidney is normal in size, size, shape and position. Corticomedullary  
differentiation (CMD) is well maintained. Normal cortical thickness is  
noted. No E/O hydronephrosis or calculus is noted.

PTO



**Left Kidney** is normal in size, shape and position. CMD is well maintained. Normal cortical thickness is noted. No E/O hydronephrosis or calculus is noted.

**Urinary Bladder** is well distended (physiological). its contents are echo free. No E/O bladder wall thickening is noted. Post-void residue is insignificant.

**Prostate** is normal in size. Shape and echo texture with smooth outline. No E/O focal lesion is noted.

**Uterus** is ante/~~retro~~ verted and normal in size, shape and echotexture with smooth outline. No E/O focal lesion is noted. Endometrial echo appear normal. Cervical and vaginal shadows appear normal.

**Right Ovary** appears ~~enlarged~~ / Normal in size, shape and echo texture.

**Left Ovary** appears ~~enlarged~~ / Normal in size, shape and echo texture.

**Impression : Normal study.**

**Advised clinical Correlation.**

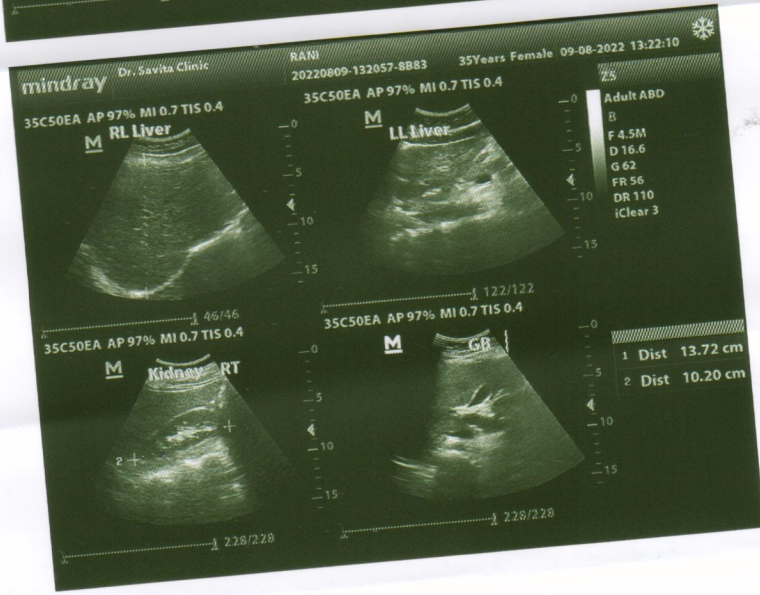
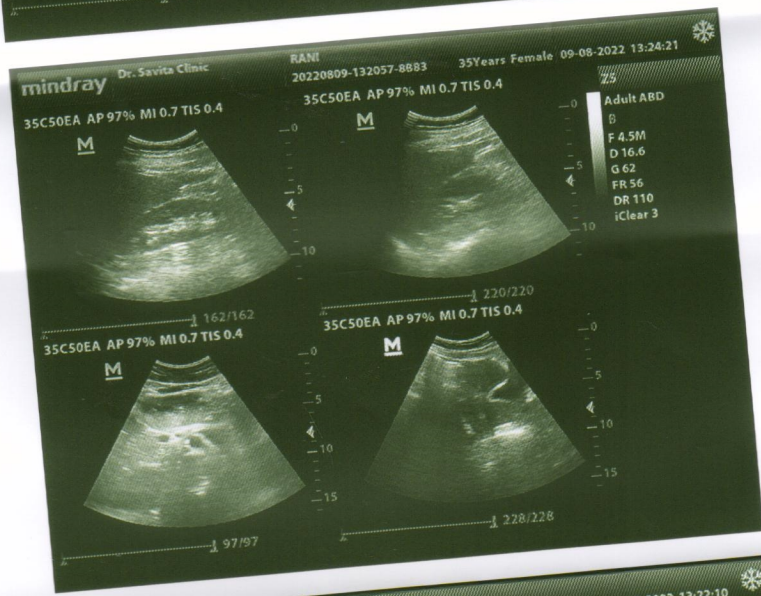
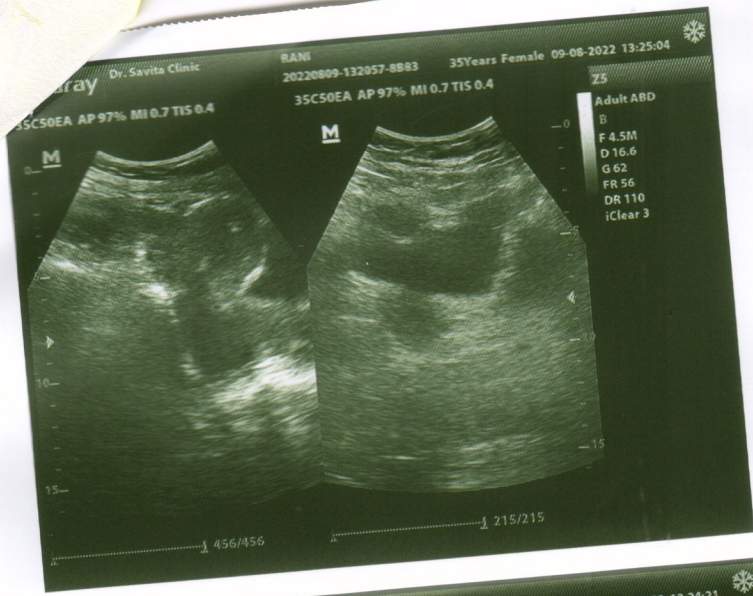
*Dr. P. Savita*

**Dr. P. Savita, MD**  
MBBS, MD (O&G) Reg. No. 9971  
स्त्री रोग विशेषज्ञ

**Dr. Jayant Yadav, MD**  
MBBS, MD (Radiologist) Reg. No. 4166  
रेडियोलॉजिस्ट



ained.  
us is







# दिवाकर डायग्नोस्टिक सेंटर


E-7/636, पंजाब नेशनल बैंक के पास, मॉन रोड, अरेरा कॉलोनी भोपाल ( म.प्र. )  
फोन: 0755-2465288, 0755-3520545 मो: 9826340190

Pt.Name :-	Mrs. Rani Jaiswal
Age :-	36y/F
Refd. By :-	BOB
Lab.pNo.:-	281
Date :-	09/08/2022

## URINE ANALYSIS

<u>A. PHYSICALEXAMINATION</u>		<u>C. MICROSCOPIEXAMINATION</u>	
1. Colour	Yellow	Pus Cells	3-4/HPF
2. Appearance	Clear	R.B.C.	Nil
3. Specific Gravity	Q.N.S.	Epithelial Cell	1-2/HPF
<u>B. CHEMICAL EXAMINATION</u>		Cast	Nil
1.Reaction	Acidic	Crystals(Cal.Oxa)	Nil
2.Albumin	Absent	Bacteria	Nil
3.Sugar	Nil	Amorphous	Nil
4.Bile Salts	Absent	T. Vaginitis	Nil

URINE COTININE	Negative	By Card method
----------------	----------	----------------



*Dr. B. M. Agarwal*  
MBBS DCP  
Consultant Pathologist

All test have technical limitation. Collaborative clinic pathological interpretation is mandatory. In case of disparity test may be repeated immediately. Typographic mistakes should be get correct instantly. This report is not valid for medico legal purpose.





# द्विवकर डायग्नोस्टिक सेंटर

E-7/636, पंजाब नेशनल बैंक के पास, मैन रोड, अरेा कॉलोनी भोपाल ( म.प्र. )


फोन: 0755-2465288, 0755-3520545 मो: 9826340190

Pt.Name :-	Mrs. Rani Jaiswal
Age :-	36y/F
Refd. By :-	BOB
Lab.pNo.:-	281
Date :-	09/08/2022

## EXAMINATION OF BLOOD

TEST	RESULT	NORMAL VALUE
Haemoglobin	11.8mgs%	Female 12-16gms%, Male 14-18gms%
Red Cell count	4.8	4.5-5.6 million /cumm
Platelet Count	2.16	1.5-5.6 Lac/cumm
Leucocytes per.cu.mm	7100/cumm	5000-11000/cumm
Neutrophils	55%	50-70%
Lymphocytes	33%	20-40%
Eosinophils	08%	0-7%
Monocytes	04%	2-8%
PCV	37.0	37-47
MCV	76.6	76-96
MCH	29.5	27-32
MCHC	31.8	31-35
ESR	12	Male 0-9, Female 0-20mm/FHR
Blood Group	"B"Positive	By Slide Method
S.Bilirubin(Total)	0.78	0.2-1.0mg/dl
Direct	0.30	0.0-0.25mg/dl
Indirect	0.48	
SGOT	19.5	5-35U/L
SGPT	23.0	8-40U/L
Alk Phosphatase	8.2	3-13 KA units
S. Protein(Total)	6.8	6.0-8.0mg%
Albumin	3.9	3.7-5.3mg%
Globulin	3.1	1.5 to 3.5 mg%
AG Ratio	1.25	1.-2.0
Blood Urea Nitrogen (BUN)	12.8	7-20 mg/dl
S.Creatinine	0.82	0.5-1.4mg/dl
Uric Acid	4.9	4.8 to 7.5 mg/dl
Calcium	8.7	8.5-10.5 gm/dl
GGTP	29.6	5-35 UL/dl
Fasting Blood Sugar	74.3	70 to 110mg/dl
Post Prandial Blood Sugar	121.8	
Total Serum Cholesterol	158.9	100-250 mg%
Serum Triglyceride	102.6	Up to 160 mg%
Serum Cholesterol HDL	37.3	Up to 65 mg%
Serum Cholesterol LDL	101.0	Up to 125 mg%
VLDL	20.5	Up to 30 mg%
TC/HDL Ratio	3.22	Bellow 5
Glycosylated Hemoglobin HBA1c	5.2	Below - 6.0 % -Non Diabetic control 6-7 % -Excellent control Above- 8 % -Poor control

All test have technical limitation. Collaborative clinic pathological interpretation is mandatory. In case of disparity test may be repeated immediately. Typographical mistakes should be get correct instantly. This report is not valid for medico legal purpose.



Dr. B. M. Agarwal  
Pathologist  
MSB, DCP  
Consultant Pathologist





# दिवाकर डायग्नोस्टिक सेंटर

E-7/636, पंजाब नेशनल बैंक के पास, मैन रोड, अरेरा कॉलोनी भोपाल ( म.प्र. )

फोन: 0755-2465288, 0755-3520545 मो: 9826340190

Pt.Name :-	Mrs. Rani Jaiswal
Age :-	36y/F
Refd. By :-	BOB
Lab.pNo.:-	281
Date :-	09/08/2022
Skigram	X Ray Chest PA View
Radiologist	Dr. B.M.Agarwal MD (Radiology)

## REPORT

Tricia Central

Thoracic cage normal

Both Lungs Field Clear.

Both hilers normal

Cardiac border normal

Both cp angles clear

Both domes and diaphragm normal


## IMPRESSION

\*\*\*\*\*

-NO CARDIO PULMONARY PATHOLOGY

-COORELATE WITH CLINICAL FINDINGS.

Dr. B. M. Agarwal  
MD, Radiology  
Consultant Radiologist  
Radiologist





# दिवाकर डायग्नोस्टिक सेंटर

E-7/636, पंजाब नेशनल बैंक के पास, मैन रोड, अरेा कॉलोनी भोपाल ( म.प्र. )  
फोन: 0755-2465288, 0755-3520545 मो: 9826340190

Name :-	Mrs. Rani Jaiswal
Age :-	36y/F
Refd. By :-	BOB
Lab.pNo.:-	281
Date :-	09/08/2022


## EXAMINATION OF BLOOD

### Thyroid profile

TEST	RESULT	NORMAL VALUE
T3 - TOTAL	116.8	82-213 ng/dL
T4 - TOTAL	8.35	6.09-12.23 ug/dL
THYROID STIMULATING HORMONE (TSH)	3.28	0.45-4.25 ul/mL

Interpretation:  
TSH Levels will be elevated in primary hypothyroidism, TSH levels will be low in Hyperthyroidism there is decreased production of thyroid hormones by the thyroid hence the person may experience symptoms such as weight gain, constipation, cold intolerance and fatigue. Iodine deficiency and Hashimoto thyroiditis is the most common cause of hypothyroidism It makes Thyroid stimulating hormone. If TSH levels are abnormally high it could mean you have an underactive thyroid or hypothyroidism.

All test have technical limitation. Collaborative clinic pathological interpretation is mandatory. In case of disparity test may be repeated immediately. Typographic mistakes should be get correct instantly. This report is not valid for medico legal purpose




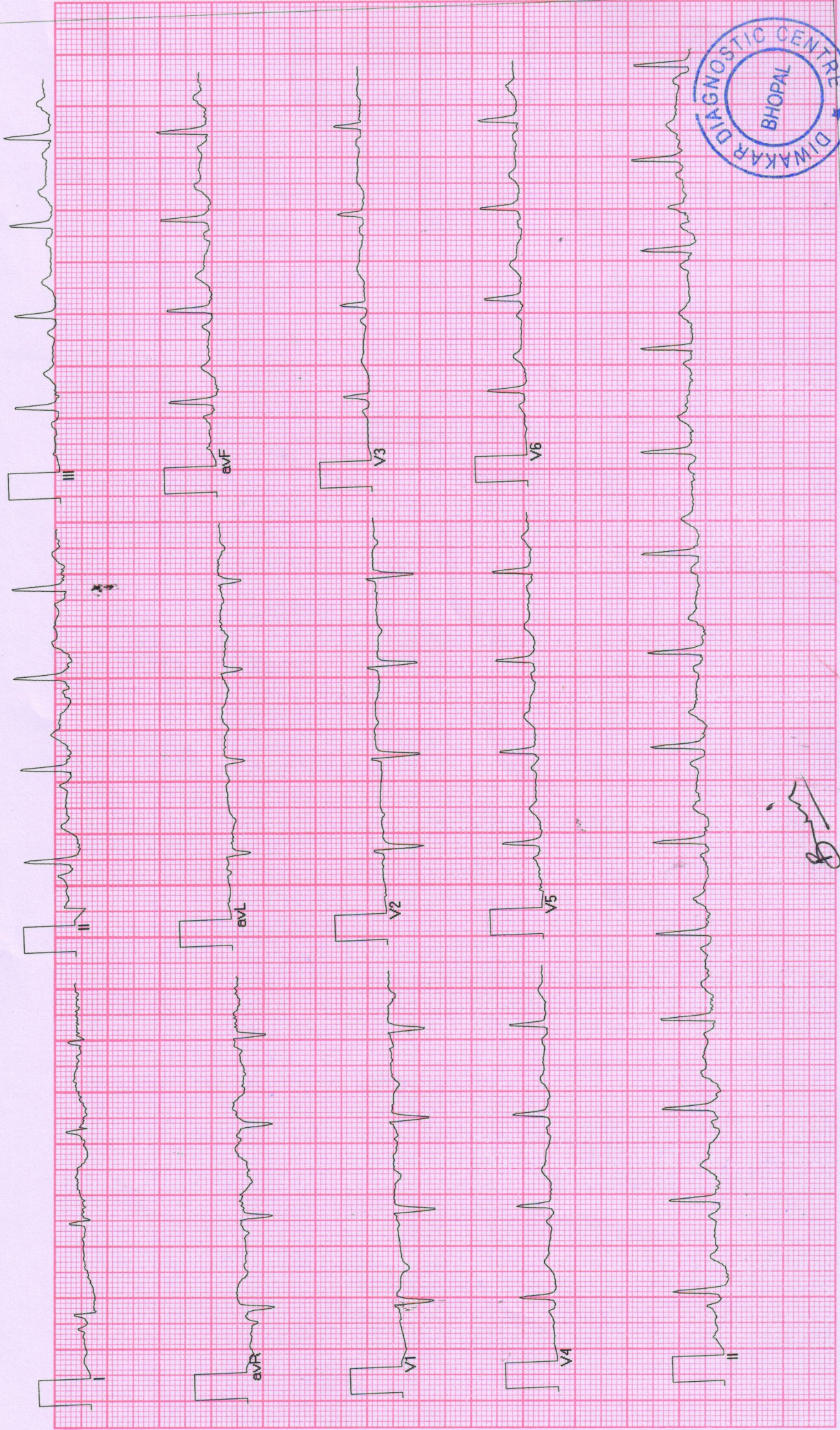
Dr. B. M. Agarwal  
MBBS, DCP  
Pathologist  
Consultant Pathologist





ECG

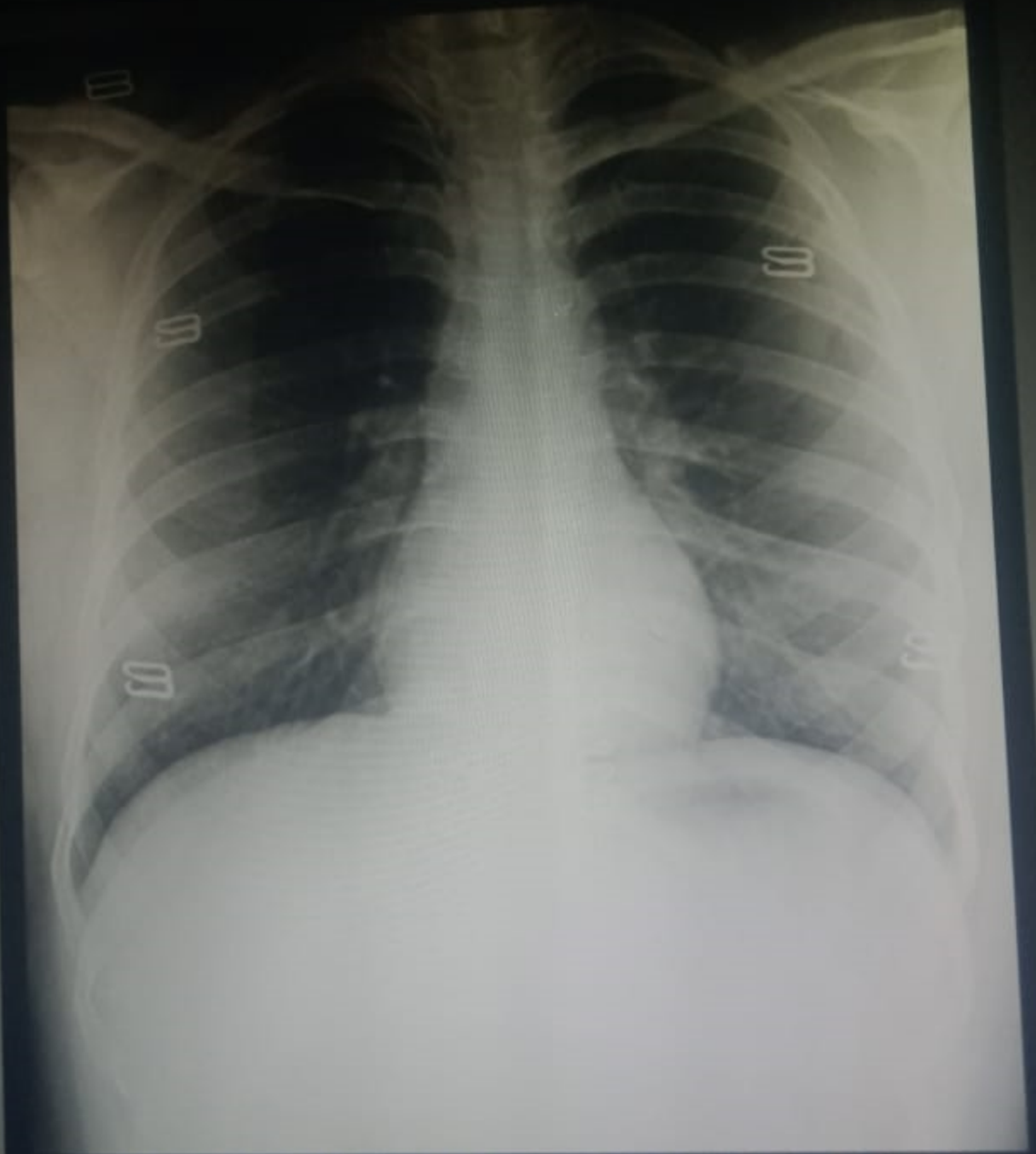Allengers Global Healthcare Pvt Ltd.,  
151 / MRS. RANI JAISWAL / 36 Yrs / F / 165Cms. / 63Kgs.  
Heart Rate : 82 bpm / Tested On : 09-Aug-22 10:01:38 / HF 0.05 Hz - LF 100 Hz / Notch 50 Hz / Sn 1.00 Cm/mV / Sw 25 mm/s  
/ Refd By.: BOB



*[Handwritten signature]*

BPL-DYNATRAC





MRS RANI JAISWAL 35Y 1245 CHEST,FRN P->A 09-Aug-22  
DIWAKAR DIAGNOSTIC CENTRE , ARERA COLONY ,BHOPAL



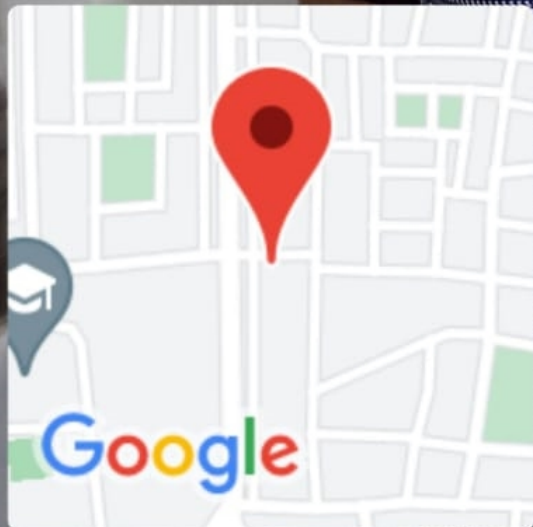


# Divyadar Diagnostic Centre

पेशेवर एकस-रे | ई.सी.जी. | एको कार्डियो ग्राफी | सोनोग्राफी



GPS Map Camera



**Bhopal, Madhya Pradesh, India**

636, Champion School Rd, E-7, Arera Colony, Bhopal, Madhya Pradesh 462016, India

Lat 23.205875°

Long 77.431613°

09/08/22 01:07 PM