



To,

The Coordinator,
Mediwheel (Arcofemi Healthcare Limited)
Helpline number: 011- 41195959

Dear Sir / Madam,

Sub: Annual Health Checkup for the employees of Bank of Baroda

This is to inform you that the following spouse of our employee wishes to avail the facility of Cashless Annual Health Checkup provided by you in terms of our agreement.

PARTICULARS OF HEALTH CHECK UP BENEFICIARY	
NAME	RINA KAUSHIK
DATE OF BIRTH	06-07-1976
PROPOSED DATE OF HEALTH CHECKUP FOR EMPLOYEE SPOUSE	11-09-2021
BOOKING REFERENCE NO.	21S162002100003872S
SPOUSE DETAILS	
EMPLOYEE NAME	MR. KAUSHIK SURESH
EMPLOYEE EC NO.	162002
EMPLOYEE DESIGNATION	SMELF HEAD
EMPLOYEE PLACE OF WORK	BILASPUR,RO BILASPUR
EMPLOYEE BIRTHDATE	29-12-1975

This letter of approval / recommendation is valid if submitted along with copy of the Bank of Baroda employee id card. This approval is valid from **10-09-2021** till **31-03-2022**.The list of medical tests to be conducted is provided in the annexure to this letter. Please note that the said health checkup is a **cashless facility** as per our tie up arrangement. We request you to attend to the health checkup requirement of our employee's spouse and accord your top priority and best resources in this regard. The EC Number and the booking reference number as given in the above table shall be mentioned in the invoice, invariably.

We solicit your co-operation in this regard.

Yours faithfully,

Sd/-

**Chief General Manager
HRM Department
Bank of Baroda**

(Note: This is a computer generated letter. No Signature required. For any clarification, please contact Mediwheel (Arcofemi Healthcare Limited))


SUGGESTIVE LIST OF MEDICAL TESTS

FOR MALE	FOR FEMALE
CBC	CBC
ESR	ESR
Blood Group & RH Factor	Blood Group & RH Factor
Blood and Urine Sugar Fasting	Blood and Urine Sugar Fasting
Blood and Urine Sugar PP	Blood and Urine Sugar PP
Stool Routine	Stool Routine
Lipid Profile	Lipid Profile
Total Cholesterol	Total Cholesterol
HDL	HDL
LDL	LDL
VLDL	VLDL
Triglycerides	Triglycerides
HDL / LDL ratio	HDL / LDL ratio
Liver Profile	Liver Profile
AST	AST
ALT	ALT
GGT	GGT
Bilirubin (total, direct, indirect)	Bilirubin (total, direct, indirect)
ALP	ALP
Proteins (T, Albumin, Globulin)	Proteins (T, Albumin, Globulin)
Kidney Profile	Kidney Profile
Serum creatinine	Serum creatinine
Blood Urea Nitrogen	Blood Urea Nitrogen
Uric Acid	Uric Acid
HBA1C	HBA1C
Routine urine analysis	Routine urine analysis
USG Whole Abdomen	USG Whole Abdomen
General Tests	General Tests
X Ray Chest	X Ray Chest
ECG	ECG
2D/3D ECHO / TMT	2D/3D ECHO / TMT
Stress Test	Thyroid Profile (T3, T4, TSH)
PSA Male (above 40 years)	Mammography (above 40 years) and Pap Smear (above 30 years).
Thyroid Profile (T3, T4, TSH)	Dental Check-up consultation
Dental Check-up consultation	Physician Consultation
Physician Consultation	Eye Check-up consultation
Eye Check-up consultation	Skin/ENT consultation
Skin/ENT consultation	Gynaec Consultation



भारत सरकार

Government of India




रीना कौशिक

Rina Kaushik

जन्म तिथि / DOB : 06/07/1976

लिंग / Female

7548 7428 6756



आधार - आज आदर्शी का अधिकार



Unique Identification Authority of India

पता:

संबंधित: सुरेश काशिक, एल आई जी
- 159, दीनदयाल हाउसिंग परिसर,
शंकरा कालेज के पास, जुनवाणी,
मोतीलाल नेहरु नगर बिलाई, दुर्ग,
मोतीलाल नेहरु नगर बिलाई,
छत्तीसगढ़, 490020

Address:

W/O: Suresh Kaushik, L I G - 159,
deendayal housing parisar, near
shankara collage, junwani, Motilal
Nehru Nagr Bhilai, Durg, Motilal
Nehru Nagr Bhilai, Chhattisgarh,
490020

7548 7428 6756



1947

1800 300 1947



help@uidai.gov.in

www.uidai.gov.in

IDENTITY CERTIFICATE

Certified that Shri. Suresh Kaushik S/O M. L. Kaushik, is a permanent employee of Bank of Baroda since 04.11.2009 and is at present holding the post of Chief Manager at our SME Cell (Bilaspur, C.G). Shri M. L. Kaushik , Smt. Shashi Kaushik, Smt. Rina Kaushik, Shreyansh Kaushik and Olivia Kaushik are dependent family members of Shri Suresh Kaushik and his identity is certified. Bank of Baroda has no objection to his acquiring/renewing Indian passport. The undersigned, is duly authorized to sign this identity certificate. I have read the provision of Section 6(2) of the passports Act, 1967 and certify that these are not attracted in case of this applicant. I recommend issue/renewal of an Indian Passport to him. It is certified that Bank of Baroda is a Public sector undertaking. The Identity card number of Mr. Suresh Kaushik is **162002 (EC No)**



RO/BILA/HRM/2021/134
Date: 03-06-2021
Bank of Baroda
Regional Office (Bilaspur)
Jeevan Prakash,
Jeevan Bima Marg,
Pandri, Raipur (C.G.) 492004

Name : Barun Meher
Designation: Regional Head (AGM)
Bilaspur Region



क्षेत्रीय कार्यालय (बिलासपुर), द्वितीय तल, एल.आई.सी. इन्वेस्टमेंट बिल्डिंग, पंडरी, रायपुर (छ.ग.) 492 004 भारत (प्र.का. बड़ौदा)
फोन : 0771 4034214 (उप क्षेत्रीय प्रबंधक), 4034639, 4033065, 4034446

Regional Office (Bilaspur), Second Flour, LIC Investment Building, Pandri, Raipur (C.G.) 492 004 India (H.O. Baroda)
Phone : 0771 4034214 (Dy. R.M.), 4034639, 4033065, 4034446
Email : rm.bilaspur@bankofbaroda.com Visit us at : www.bankofbaroda.com



SHRIANANT SAIHOSPITAL
SECURE + WE PROTECT

SHRI ANANT SAI HOSPITAL

A Unit of Parth Sheel Health Care Pvt. Ltd.

Name	MRS. RINA KAUSHIK	Reg. No.	:202109110003	IPD/OPD Status	:OPD
Age/Sex	:44 Y/	Accession No.	:20210911005	Category	:TPA
consultant	:Dr. PARTH STHAPAK/ CARDIOLOGY	IPD/Bill No	:21B-002456	Location/Bed.No	:

Sample Collected at: 11/09/2021 3:02:57 PM

Accept Time at: 11/09/2021 3:02:57 PM

Report Gen at: 11/09/2021 9:22:12 PM



Accession No

PATHOLOGY

Registration No

SAMPLE TYPE : EDTA BLOOD

PATHOLOGY ANALYSIS REPORT

Investigations	Status	Result	Unit	Biological Reference Interval
COMPLETE BLOOD COUNT				
HAEMOGLOBIN				
PCV		12.0	g/dl	14.9-16.5
RBC		36.9	%	35-55
MCV		4.52	million/cumm	4.0 - 6.20
MCH		81.7	f	80 - 100
MCHC		26.5	pg	26 - 34
RDW		32.5	%	31.5 - 34.5
PLATELET COUNT		12.6	%	10 - 20
TOTAL LEUCOCYTES COUNT		1.75	lacs/cumm	1.5 - 4.5
		7300	thousand/cumm	4000 - 11000
DLC				
Neutrophils		59	%	50 - 75
Lymphocytes		26	%	20 - 45
Monocytes		08	%	2 - 10
Eosinophils	H	07	%	1 - 6
Basophils		00	%	0 - 1

Checked By:

AKASH DILAWAR

Address : Beside Kingsway Hotel, Near Airtel Office, Ring Road No. 1, Telibandna, Raipur (C.G.)

Contact Us : 9109152271, 0771-4982222, Email : anantsai99@gmail.com

Client is advised to contact prior care in case of any emergency.



SHRI ANANT SAI HOSPITAL
BE CARE + WE PROTECT

SHRI ANANT SAI HOSPITAL

A Unit of Parth Sheel Health Care Pvt. Ltd.

Name	MRS. RINA KAUSHIK	Reg. No.	:202109110003	IPD/OPD Status	:OPD
Age/Sex	:44 Y/	Accession No.	:20210911005	Category	:TPA
consultant	:Dr. PARTH STHAPAK/ CARDIOLOGY	IPD/Bill No	:21B-002455	Location/Bed.No	

Sample Collected at: 11/09/2021 3:02:57 PM

Accept Time at: 11/09/2021 3:02:57 PM

Report Gen at: 11/09/2021 9:21:26 PM



Accession No

Registration No

HAEMATOLOGY

SAMPLE TYPE : BLOOD

HAEMATOLOGY REPORT

Investigations	Status	Result	Unit	Biological Reference Interval
Blood Group		O		
Rh Typing		POSITIVE		

*** End of Report ***

Checked By:

AKASH DILAWAR

Address : Beside Kingsway Hotel, Near Airtel Office, Ring Road No. 1, Telibandha, Raipur (C.G.)
 Contact Us : 9109152271, 0771-4982222, Email : anantsai99@gmail.com

Client is advised to contact plus care in case of any unexpected or alarming results for possible corrective measures.



SHRIANANT SAI HOSPITAL
EST 2011 • WE PROTECT

SHRI ANANT SAI HOSPITAL

A Unit of Parth Sheel Health Care Pvt. Ltd.

Name	MRS. RINA KAUSHIK	Reg. No.	:202109110003	IPD/OPD Status	:OPD
Age/Sex	:44 Y/	Accession No.	:20210911005	Category	:TPA
consultant	:Dr. PARTH STHAPAK/ CARDIOLOGY	IPD/Bill No	:21B-002456	Location/Bed.No	

Sample Collected at: 11/09/2021 3:02:57 PM

Accept Time at: 11/09/2021 3:02:57 PM

Report Gen at: 11/09/2021 9:21:14 PM



HAEMATOLOGY



Accession No

Registration No

SAMPLE TYPE : EDTA BLOOD

HAEMATOLOGY REPORT

Investigations	Status	Result	Unit	Biological Reference Interval
ESR	H	40	mm/h	0-20

*** End of Report ***

Checked By: AKASH DILAWAR

Address : Beside Kingsway Hotel, Near Airtel Office, Ring Road No. 1, Telibandha, Raipur (C.G.)
 Contact Us : 9109152271, 0771-4982222, Email : anantsai99@gmail.com

Client is advised to contact plus care in case of any unexpected or alarming results for possible corrective measures.



SHRI ANANT SAI HOSPITAL
ESTD 2008 - WE PROTECT

SHRI ANANT SAI HOSPITAL

A Unit of Parth Sheel Health Care Pvt. Ltd.

Name	MRS. RINA KAUSHIK	Reg. No.	:202109110003	IPD/OPD Status	:OPD
Age/Sex	:44 Y/	Accession No.	:20210911005	Category	:TPA
consultant	Dr. PARTH STHAPAK/ CARDIOLOGY	IPD/Bill No	:21B-002456	Location/Bed.No	:

Sample Collected at: 11/09/2021 3:02:57 PM

Accept Time at: 11/09/2021 3:02:57 PM

Report Gen at: 11/09/2021 3:20:45 PM



Accession No

BIOCHEMISTRY

Registration No

SAMPLE TYPE : SERUM

LIVER FUNCTION TEST

Investigations	Status	Result	Unit	Biological Reference Interval
Bilirubin Total		0.29	mg/dl	0.00 - 2.0
Bilirubin Direct		0.16	mg/dl	0.00-0.40
Bilirubin Indirect		0.13	mg/dl	0.0 - 1.0
SGOT (AST)		19.6	U/L	15-40
SGPT (ALT)		15.6	U/L	10-40
ALKALINE PHOSPHATASE		89	U/L	30-120
TOTAL PROTEIN		7.2	g/dl	6.6-8.3
ALBUMIN		4.14	g/dl	3.5 - 5.2
GLOBULIN		3.06	g/dl	1.9 - 3.5
A-G Ratio		1.35		1.0 - 2.2

*** End of Report ***

Checked By:

AKASH DILAWAR

Address : Beside Kingsway Hotel, Near Airtel Office, Ring Road No. 1, Telibandra, Raipur (C.G.)

Contact Us : 9109152271, 0771-4982222, Email : anantsai99@gmail.com

Client is advised to contact plus care in case of any unexpected or alarming results for possible corrective measures.



SHRIANANT SAI HOSPITAL
WE CARE • WE PROTECT

SHRI ANANT SAI HOSPITAL

A Unit of Parth Sheel Health Care Pvt. Ltd.

Name: MRS. RINA KAUSHIK	Reg. No. :202109110003	IPD/OPD Status :OPD
Age: 44 Yr	Accession No. :20210911005	Category :TPA
consultant :Dr. PARTH STHAPAK/ CARDIOLOGY	IPD/Bill No. :21B-002456	Location/Bed.No. :

Sample collected at: 11/09/2021 3:02:57 PM

Accept Time at:11/09/2021 3:02:57 PM

Report Gen at: 11/09/2021 9:23:43 PM



CLINICAL BIOCHEMISTRY



Accession No

SAMPLE TYPE : SERUM

Registration No

CLINICAL BIOCHEMISTRY

Investigations	Status	Result	Unit	Biological Reference Interval
CHOLESTROL		172.0	mg/dl	<200
TRIGLUCERIDES	HH	195.4	mg/dl	30-150
HDL CHOLESTROL		55.2	mg/dl	30-60
LDL CHOLESTROL		77.52	mg/dl	50-140
VLDL CHOLESTROL	H	39.28	mg/dl	<35
TRIGLUCERIDE RATIO		3.12		Up To 5
LDL/C Ratio	L	1.40		2.5 - 3.5
LDL CHOLESTROL		116.80	mg/dl	0-120

*** End of Report ***

Lipid profile should performed on 12 hr fasting state.
 If triglyceride values are more than 400 mg/dl, the assumptions to calculate LDL and VLDL are invalid.

AKASH DILAWAR

Address : Beside Kingsway Hotel, Near Airtel Office, Ring Road No. 1, Telibandia, Raipur (C.G.)

Contact Us : 9109152271, 0771-4982222, Email : anantsai99@gmail.com

Client is advised to contact plus care in case of any unexpected or alarming results for possible corrective measures.



Name	: MRS. RINA KAUSHIK	Reg. No.	: 202109110003	IPD/OPD Status	: OPD
Age/Sex	: 44 Y/Female	Accession No.	: 20210911005	Category	: TPA
consultant	: Dr. PARTH STHAPAK/ CARDIOLOGY	IPD/Bill No	: 21B-002456	Location/Bed.No	:

Sample Coll. at: 11/09/2021 3:02:57 PM


ACCEPT TIME AT: 11/09/2021 3:02:57 PM

ReportGen at: 11/09/2021 9:22:50 PM



Accession No

PATHOLOGY



Registration No

Glycosylated Hb (Hba1c)

	Result	Units	Ref.Range
Glycosylated Hb	7.0	%	4-5.9 (non-diabetics) 6-7 (controlled diabetics) >7 (uncontrolled diabetics)

Method: Dual system of nephelometry and turbidimetric.

INTRPRETATION:

Glycosylated Hb(%)	Mean Plasma Glucose (mg/dl)
1) 6	135
2) 7	170
3) 8	205
4) 9	240
5) 10	275
6) 11	310

Checked By:

Address : Beside Kingsway Hotel, Near Airtel Office, Ring Road No. 1, Telibandra, Raipur (C.G.)

Contact Us : 9109152271, 0771-4982222, Email : anantsai99@gmail.com



**SHRIANANT
SAIHOSPITAL**
011 22821 - we respect

SHRI ANANT SAI HOSPITAL

A Unit of Parth Sheel Health Care Pvt. Ltd.

Name	:MRS. RINA KAUSHIK	Reg. No.	:202109110003	IPD/OPD Status	:OPD
Age/Sex	:44 Y/Female	Accession No.	:202109110005	Category	:TFA
consultant	Dr. PARTH STHAPAKI CARDIOLOGY	IPD/Bill No.	:21B-002456	Location/Bed.No	:

Sample Coll. at: 11/09/2021 3:02:57 PM

ACCEPT TIME AT: 11/09/2021 3:02:57 PM

Report Gen at: 11/09/2021 9:23:04 PM



CLINICAL PATHOLOGY



URINE ROUTINE EXAMINATION REPORT

Registration No

INVESTIGATION	RESULT	UNIT	NORMAL RANGE
PHYSICAL EXAMINATION			
QUANTITY	15 ML		<30 ML
APPEARANCE	CLEAR		CLEAR
COLOR	P. YELLOW		P. YELLOW
CHEMICAL EXAMINATION			
REACTION(Ph)	6.0		5.5 - 7.5
SPECIFIC GRAVITY	1.015		1.012-1.025
PROTEIN	NIL		ABSENT
SUGAR	ABSENT		ABSENT
KETON BODY	ABSENT		ABSENT
NITRATE	NEGATIVE		NEGATIVE
BLOOD	NEGATIVE		NEGATIVE
MICROSCOPIC EXAMINATION			
PUS CELLS	2-3	/HPF	4-5
RBC	NIL	/HPF	NIL
EPITHELIAL CELL	2-3	/HPF	3-4
CASTS	NIL	/HPF	NIL
CRYSTALS	NIL	/HPF	NIL

Checked by:

Handwritten signature

Address : Beside Kingsway Hotel, Near Airtel Office, Ring Road No. 1, Telibandna, Raipur (C.G.)

Contact Us : 9109152271, 0771-4982222, Email : anantsai99@gmail.com

Client is advised to contact plus care in case of any unexpected or alarming results for possible corrective measures.

Mrs. RINA KAUSHIK



Report Status : Final

AGE : 44 Years SEX : FEMALE

REF. BY : DR. P STHAPALA

REFERENCE

SAMPLE COLLECTED AT:

Shri Anant Sai Hospital Raipur

Beside Kingsway hotel Near Airtel Office
Ring Road No 1 Telibandha Raipur - CG

LAB ID:109102659

RECEIVED ON :

11-Sep-2021 07:04 PM

COLLECTED ON :

REPORTED ON :

11-Sep-2021 09:50 PM

TEST NAME	RESULT	UNIT	BIOLOGICAL REF. RANGE
Thyroid Function Test			
T3 (Triiodothyronine) (ECLIA)	1.25	ng/mL	0.8 - 2.02
T4 (Thyroxine) † (ECLIA)	8.73	µg/dL	5.1 - 14.06
TSH (ECLIA)	2.64	µIU/ml	0.27 - 4.2

Interpretation(s)

TSH stimulates the production and secretion of the metabolically active thyroid hormones, thyroxine (T4) and triiodothyronine (T3), by interacting with a specific receptor on the thyroid cell surface. The synthesis and secretion of TSH is stimulated by Thyrotropin releasing hormone (TRM) in response to low levels of circulating thyroid hormones. Elevated Levels of T3 and T4 suppress the production of TSH via a classic negative feedback mechanism. Failure at any level of regulation of the Hypothalamic-pituitary- thyroid axis will result in either underproduction (hypothyroidism) or overproduction (hyperthyroidism) of T4 and/ or T3.

Limitations:

T3 and T4 circulates in reversibly bound form with Thyroid binding globulins (TBG), and to a lesser extent albumin and thyroid binding Pre Albumin, So Conditions in which TBG and protein levels alter Such as pregnancy, excess estrogens, androgens, steroids may falsely affect the T3 and T4 levels. Normal levels of T4 can also be seen in Hyperthyroid patients with: T3 Thyrotoxicosis, hypoproteinemia Or ingestion of certain drugs. Serum T4 levels in neonates and infants are higher than values in the normal adult, due to the increased concentration of TBG in neonate serum. TSH may be normal in central hypothyroidism recent rapid correction of hyperthyroidism or hypothyroidism pregnancy, Phenytoin therapy, Autoimmune disorders may produce spurious results. Various drugs can interfere With the test result, TSH has a diurnal rhythm so values may vary if sample collection is done at different times of the day.



Plus Care Internationals Pvt. Ltd.

2nd Floor , Piyank Tower , Near Hotel Vansh, Raja Talab Road, Raipur. 492001, Chhattisgarh

T: +91-771-2437200 | Customer Care: +91-6231 49100 | E: care@pluscare.org | www.pluscare.org

Client is advised to contact plus care in case of any unexpected or alarming results for possible corrective measures.

Mrs. RINA KAUSHIK

REFERENCE

LAB ID:109102659

Report Status : Final

SAMPLE COLLECTED AT:

RECEIVED ON :

AGE : 44 Years SEX : FEMALE

Shri Anant Sai Hospital Raipur

11-Sep-2021 07:04 PM

REF. BY : DR. P STHAPALA

Beside Kingsway hotel Near Airtel Office
Ring Road No 1 Telibandha Raipur - CG

COLLECTED ON :

REPORTED ON :

11-Sep-2021 09:50 PM

Parameter name	Unit	AGE Group	Expected valueswomen	Expected valuesMen
T3	ng/mL	20 - 69	0.83 - 2.00	0.83 - 2.00
		First Trimester	1.05 - 2.3	
		Second Trimester	1.29 - 2.62	
		Third Trimester	1.35 - 2.62	
		0-6 days	0.73 - 2.88	0.73 - 2.88
		>6 days - < 3months	0.8 - 2.75	0.8 - 2.75
		>3 - <12 months	0.86 - 2.65	0.86 - 2.65
		>1 - <6 yrs.	0.92 - 2.48	0.92 - 2.48
		>6 - <11 yrs.	0.93 - 2.31	0.93 - 2.31
		>11 - <20 yrs.	0.91 - 2.18	0.91 - 2.18
T4	ug/dl	20 - 69	5.13 - 14.1	5.13 - 14.1
		First Trimester	7.33 - 14.8	
		Second Trimester	7.93 - 16.1	
		Third Trimester	6.95 - 15.7	
		0-6 days	5.04 - 18.5	5.04 - 18.5
		>6 days - < 3months	5.41 - 17.0	5.41 - 17.0
		>3 - <12 months	5.67 - 16	5.67 - 16
		>1 - <6 yrs.	5.95 - 14.7	5.95 - 14.7
		>6 - <11 yrs.	5.99 - 13.8	5.99 - 13.8
		>11 - <20 yrs.	5.91 - 13.2	5.91 - 13.2
Thyroid Stimulating Hormone	µIU/ml	20 - 69	0.27-4.2	0.27-4.2
		First Trimester	0.33 - 4.59	
		Second Trimester	0.35 - 4.1	
		Third Trimester	0.21 - 3.15	
		0-6 days	0.7 - 15.2	0.7 - 15.2
		>6 days - < 3months	0.72 - 11.0	0.72 - 11.0
		>3 - <12 months	0.73 - 8.35	0.73 - 8.35
		>1 - <6 yrs.	0.7 - 5.97	0.7 - 5.97
		>6 - <11 yrs.	0.6 - 4.84	0.6 - 4.84
		>11 - <20 yrs.	0.51 - 4.3	0.51 - 4.3



Plus Care Internationals Pvt. Ltd.

2nd Floor, Piyank Tower, Near Hotel Vansh, Raja Talab Road, Raipur, 492001, Chhattisgarh
T: +91-771-2437200 | Customer Care: +91-6231 49100 | E: care@pluscare.org | www.pluscare.org

Client is advised to contact plus care in case of any unexpected or alarming results for possible corrective measures.

Mrs. RINA KAUSHIK

REFERENCE

LAB ID:109102659

SAMPLE COLLECTED AT:

RECEIVED ON :

Report Status : Final

11-Sep-2021 07:04 PM

AGE : 44 Years SEX : FEMALE

Shri Anant Sai Hospital Raipur

COLLECTED ON :

REF. BY : DR. P STHAPALA

Beside Kingsway hotel Near Airtel Office
Ring Road No 1 Telibandha Raipur - CG

REPORTED ON :

11-Sep-2021 09:52 PM

TEST NAME

RESULT

UNIT

BIOLOGICAL REF. RANGE

Clinical Pathology


STOOL OCCULT BLOOD

Peroxidase Reaction with α-Diaminodiphenylamine

Negative

Plus
Care™

End Of Report


Dr. D. Prasad
MD. Path
Pathologist



Plus Care Internationals Pvt. Ltd.

2nd Floor , Piyank Tower , Near Hotel Vansh, Raja Talab Road, Raipur. 492001, Chhattisgarh

T: +91-771-2437200 | Customer Care: +91-6231 49100 | E: care@pluscare.org | www.pluscare.org

Client is advised to contact plus care in case of any unexpected or alarming results for possible corrective measures.

PLUS CARE INTERNATIONAL LAB
SATYA HOUSE, 7th FLOOR, HISTOPATHOLOGY DEPT,
NEXT TO LODHA ARIA, RAM TEKDI ROAD, SEWRI,
MUMBAI 400015, MAHARASHTRA, INDIA.



PATIENT NAME: MRS RINA KAUSHIK
REF. BY DOCTOR: DR. PARTH SHAPAK
CUSTOMER NAME: SHRI ANANT SAI HOSPITAL
CLIENT NAME: PLUSCARE RAIPUR

AGE/SEX: 44YEAR/FEMALE
REG.DATEANDTIME: 11/09/2021; 05:15PM
REG.DATEANDTIME: 11/09/2021; 06:25PM
REPORTDATE/TIME: 12/09/2021; 09:40PM

CYTOPATHOLOGY REPORT

LAB NUMBER: PCC 273/2021

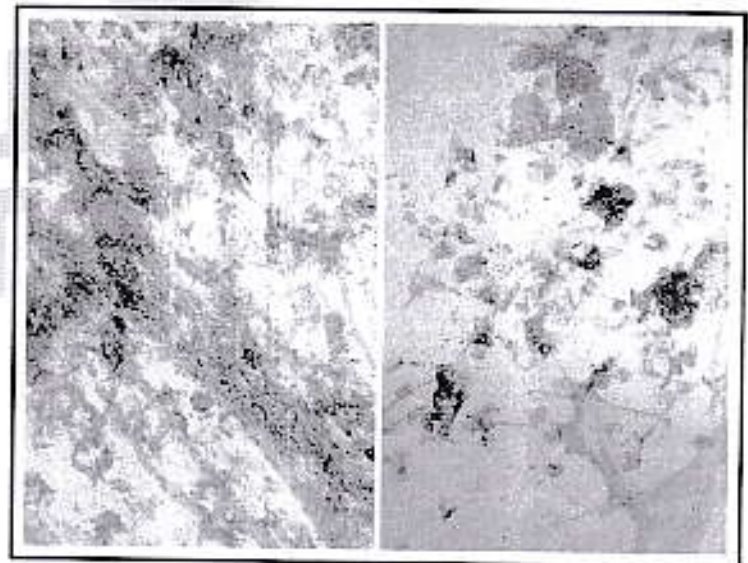
SPECIMEN:

Smear for examination.
Slides air/alcohol fixed and stained by PAP stain

IMPRESSION: NILM -Negative for intraepithelial lesion/malignancy - Inflammatory.

MICROSCOPY:

Smear shows abundant intermediate and few superficial squamous cells. Transitional zone is sampled. Endocervical cells identified. Focal squamous metaplasia present. There is moderate inflammation in the material studied including neutrophils. Few koilocytes seen. Trichomonas, bacteria, candida identified. There is no evidence of malignancy in the material studied.



--- END OF REPORT ---

DR. ARPITA NEELAKANTAN
Pathology
Reg No: 3054

DR. SHILPA MISHRA
M.D Pathology
Reg No: 0604

DR. RAKESH RAJIV PATKAR
M.D , D.N.B Pathology
Reg No: 1660



Plus Care Internationals Pvt. Ltd.

2nd Floor , Piyank Tower , Near Hotel Vansh, Raja Talab Road, Raipur. 492001, Chhattisgarh

Plus Care Internationals Pvt. Ltd. Customer Care: +91-6231 49100 | E: care@pluscare.org | www.pluscare.org

Client is advised to contact plus care in case of any inconsistency or discrepancy. For any possible corrective measures.

Customer Care: 782 819 9199 | E: care@pluscare.org | www.pluscare.org

EXAMINATION OF EYES:- (BY OPHTHALMOLOGIST)

Patient Name... Pratibha Singh Date... 01/09/2021

Age/ sex: 44 / F MR No. Employment ID.....

EXTERNAL EXAMINATION				
SQUINT	- No			
NYSTAGMUS	- No			
COLOUR VISION	- <u>Normal</u> Positive			
FUNDUS: (RE) :-			(LE):-	
INDIVIDUAL COLOUR IDENTIFICATION				
DISTANT VISION: (RE):-	<u>6/24f</u>	(LE):-	<u>6/18f</u>	
NEAR VISION : (RE):-	<u>N.6</u>	(LE):-	<u>N.6</u>	
NIGHT BLINDNESS	- <u>Negative</u>			
	SPH	CYL	AXIS	ADD
RIGHT				
LEFT				
REMARKS:-	<u>Retina specimen</u>			



Cons. Dr. PARTH STHAPAK

Designation :

Consultant M.No. PARTH STHAPAK

Reg.No.	: 202109110003	Fees	: 0.00
Name	: MRS. RINA KAUSHIK		
Age	: 44 Y	Department	: CARDIOLOGY
Ref. DR	: SELF	OPD Date	:
Mob No.	: 7693051777	Category	: TPA
Address	: AKRITI VIHAR AMLIDIH		

BP - 110/70. SpO2 100%. Pulse 99. WT 71.2 kg.

date 13/9/21
BB 115/70

C/O ~~A~~ on backache ⊕

Physical Examination:

Dental examination

O/E

Treatment Plan:

No gross abnormality noted

Calculus deposits noted in lower anterior region and upper posterior region.

Investigations:

Advice Oral prophylaxis

Medications:



Follow Up Due On:

Name & Signature Of Consultant:

Mrs. Pooja Kulkarni / Mrs

13/09/17

Examination of
 hands - falls like

Adc
Diabetic 76

BP charts

T. Pantaid (40) 01
 → Marfanic LL SOS
 → Pulmonary - SOS

(152)

SHRI ANANT SAI HOSPITAL
 Dr. [Name] (Thapak
 aroringy)
 Cardiologist
 Co. Reg. No. 7343/2017



REG. No.	202109110003	IPD No.	
Acc. No.	20210911005	Date	11-09-2021
Name	MRS. RINA KAUSHIK	Ref. By	Dr. SELF
Age/ Sex	44 Y/Female	Consultant	Dr. PARTH STHAPAK

SONOMAMMOGRAPHY

Clinical information: Health check-up, for evaluation.

Clinical indication: To rule out benign or malignant pathology.


Limitations: No.

FINDINGS:





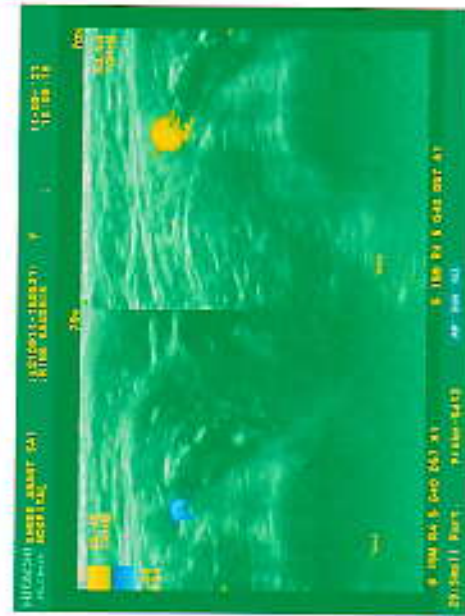




- Breast composition (ACR II).
- Both breast parenchyma including fat lobules and lactiferous ducts normal.
- Nipple and areolar region appears normal.
- No evidence of focal lesion.
- Skin and subcutaneous tissues normal.
- No axillary lymph nodes enlargement seen.
- Chest wall and muscles normal.

OPINION:

1. No significant abnormality detected in both the breast.
2. According to ACR BI-RADS 2013 – BIRADS I.


DR. VIJENDRA M RUPRELA
 MBBS, DMRD, DNB (RADIO DIAGNOSIS)
 MNAMS (NAMS) CGMC /1413/2008
 CONSULTING RADIOLOGIST & SONOLOGIST
 (GOLD MEDALIST)

Disclaimer: Impression is a professional opinion and not a diagnosis. The science of radiological diagnosis is based on the interpretation of various shadows and is neither complete nor accurate. All modern machines/procedures have their limitations. Further pathological and radiological investigations with clinical correlations are required to enable the clinician to reach the final diagnosis. In case of any clinical/radiological discrepancy, please contact. Hard copy is attached for review. Not for medico-legal purposes. Patient identity cannot be verified.



REG. No.	202109110003	IPD No.	
Acc. No	20210911005	Date	11-09-2021
Name	MRS. RINA KAUSHIK	Ref. By	Dr. SELF
Age/ Sex	44 Y/Female	Consultant	Dr. PARTH STHAPAK

ULTRA SOUND SCAN – ABDOMEN AND PELVIS

Clinical Information: Health Check-up, for evaluation.

Clinical indicator: To rule out intra-abdominal pathology.


Limitations: Suboptimal examination of the bowel signature.

- Liver: Normal in size, shape and diffuse fatty infiltration of parenchyma. IHBR/ CBD – not dilated. Hepatic and portal veins branching appear normal. No focal / diffuse lesions. Main portal vein – Normal.
- Gall bladder: Normal in distension, caliber and outline. No echogenic focus seen in the body.
- Pancreas: Appears normal in size and shape with normal parenchymal echotexture. Pancreatic duct is not dilated.
- Spleen: Normal in size (8.1 cm) with normal shape and position with normal echotexture.
- Aorta & Para Aortic region: Normal.
- Right Kidney: Normal in size, shape and parenchymal echotexture. It measures 10.3 cms in length and 1.7cms parenchymal thickness. Corticomedullary differentiation is normal. No pelvicalyceal system dilatation. No calculi.
- Left Kidney: Normal in size, shape and parenchymal echotexture. It measures 9.8 cms in length and 1.4 cms parenchymal thickness. Corticomedullary differentiation is normal. No pelvicalyceal system dilatation. No calculi.
No free fluid noted in the abdomen / pleural space.
- Urinary bladder: Normal in distension, caliber and outline. No evidence of calculi or mass lesion.
- Uterus: Normal in size (8.9 X 5.0 X 3.9 cms), No evidence of diffuse focal mass lesion.
- Endometrium appears normal. Endometrial cavity empty. Measuring 7 mm.
- Both ovaries: Are normal. **Right ovary** measures: 2.9 x 1.3cms. **Left ovary** measures 2.2 x 1.0 cms.

Visualized bowel loops appear normal. No definite evidence of wall thickening or mass lesions.

OPINION:

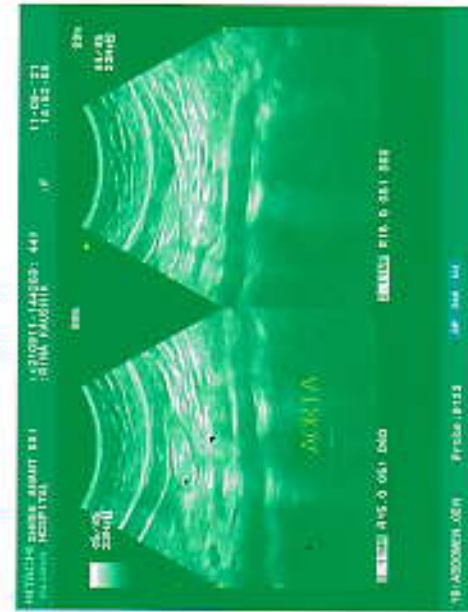
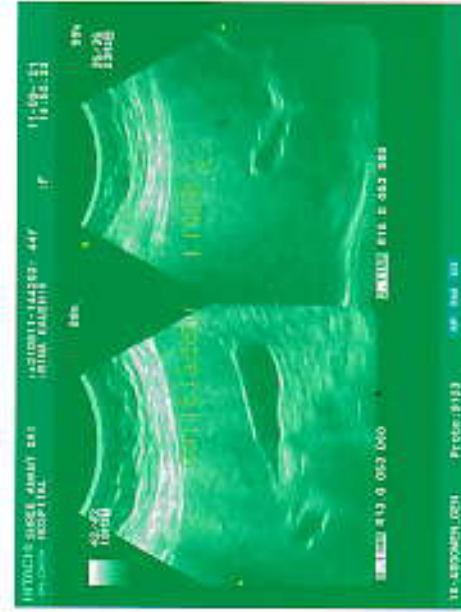
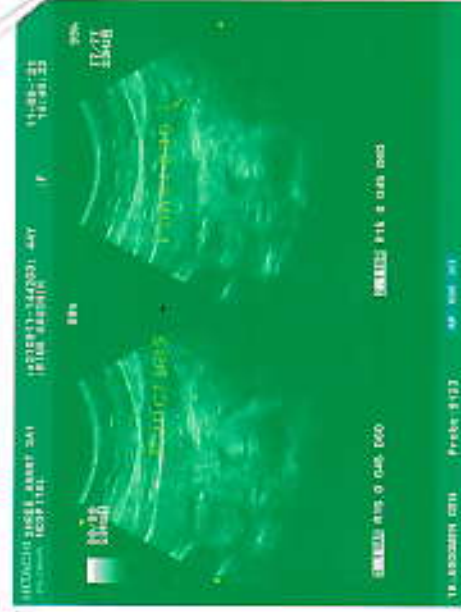
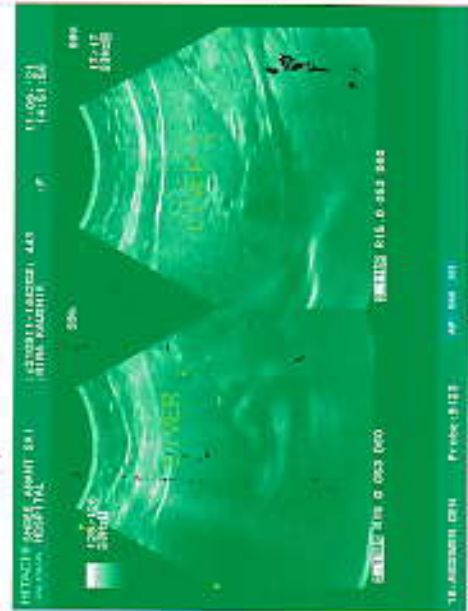
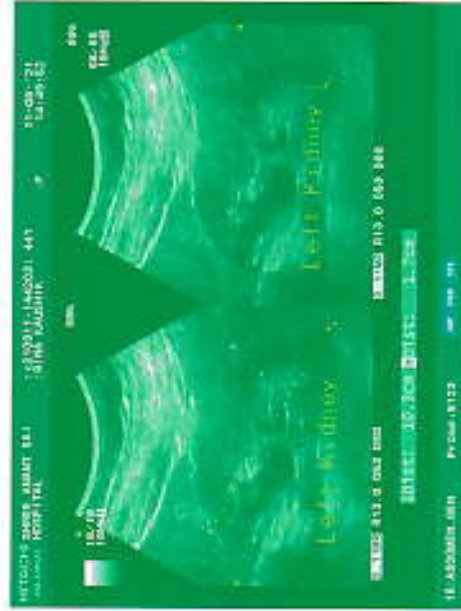
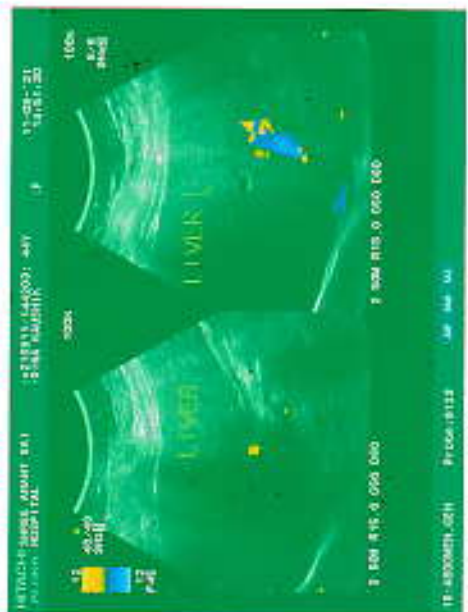
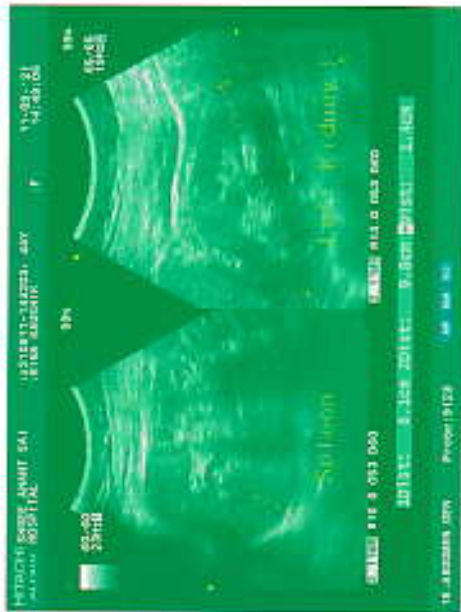
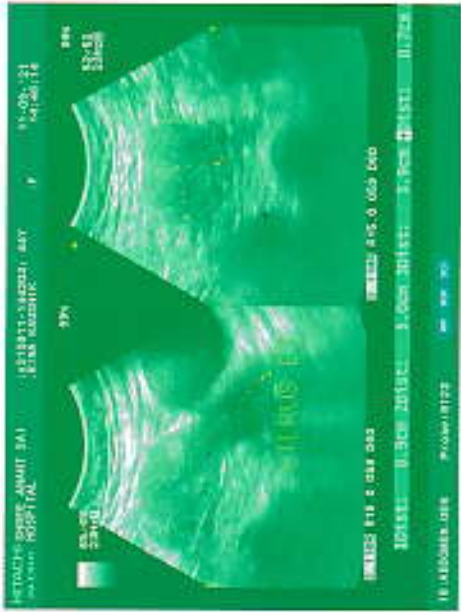
1. Diffuse fatty infiltration of liver parenchyma. No focal parenchymal lesion.
2. No other significant abnormality detected in abdomen and pelvis.


DR. VIJENDRA M RUPRELA
MBBS, DMRD, DNB (RADIODIAGNOSIS)
MNAMS (NAMS) CGMC /1413/2008
CONSULTING RADIOLOGIST & SONOLOGIST
(GOLD MEDALIST)

Disclaimer: Impression is a professional opinion and not a diagnosis. The science of radiological diagnosis is based on the interpretation of various shadows and is neither complete nor accurate. All modern machines/procedures have their limitations. Further pathological and radiological investigations with clinical correlations are required to enable the clinician to reach the final diagnosis. In case of any clinical/radiological discrepancy, please contact. Hard copy is attached for review. Not for medico-legal purposes. Patient identity cannot be verified.

Address : Beside Kingsway Hotel, Near Airtel Office, Ring Road No. 1, Telibandha, Raipur (C.G.)

Contact Us : 9109152271, 0771-4982222, Email : anantsai99@gmail.com



REG. No.	202109110003	IPD No.	
Acc. No	20210911005	Date	11-09-2021
Name	MRS. RINA KAUSHIK	Ref. By	Dr. SELF
Age/ Sex	44 Y/Female	Consultant	Dr. PARTH STHAPAK

X-RAY CHEST (PA VIEW)

Clinical information: Health check-up , for evaluation.

Clinical indication: To rule out cardiopulmonary pathology.

Limitation: No.


Comparison: No.

FINDINGS:

- Bilateral lung parenchyma is clear.
- Both apices free.
- Trachea in mid line.
- C T ratio within normal limits.
- Both hila are normal.
- Both costo & cardiophrenic angles are clear.
- Bony cage normal.
- Soft tissue appears normal.

OPINION -

- No acute cardiopulmonary pathology detected.



DR. VIJENDRA M RUPRELA
MBBS, DMRD, DNB (RADIOLOGICALS)
MNAMS (NAMS) CGMC /1413/2008
CONSULTING RADIOLOGIST & SONOLOGIST
(GOLD MEDALIST)

Disclaimer: Impression is a professional opinion and not a diagnosis. The science of radiological diagnosis is based on the interpretation of various shadows and is neither complete nor accurate. All modern machines/procedures have their limitations. Further pathological and radiological investigations with clinical correlations are required to enable the clinician to reach the final diagnosis. In case of any clinical/radiological discrepancy, please contact. Hard copy is attached for review. Not for medico-legal purposes. Patient identity cannot be verified.

Name: Mrs. Rina Kaushik

Age/Sex: 44 Yrs/F

MRD No: 110003

Date: 11.09.2021

IPD/OPD: OPD

Ref. by Dr.: Dr. Parth Sthapak MD, DM (Cardiology)

Indication: R/O CAD, ACS.

M- Mode [All Measurements in cms]

Aortic Root	2.4	(2.0 - 3.5)	LV end-diastolic diameter	4.6	(3.6 - 5.2)
Left Atrium	3.5	(1.9 - 3.9)	LV end-systolic diameter	2.5	(2.3 - 3.9)
IVS (D)	0.9	(0.6 - 1.1)	IVS (S)	1.2	(0.4 - 1.4)
PW (D)	1.0	(0.6 - 1.1)	PW (S)	1.1	(0.5 - 1.5)

2D Echo & Colour Flow Assessment:

Mitral Valve: Normal Tricuspid Valve: Normal

Aortic Valve: Normal Pulmonic Valve: Normal

Chambers:

LA: Normal RA: Normal

LV: Normal RV: Normal

Septae:

IAS: Intact IVS: Intact

Doppler Study:-

LV EJECTION FRACTION: 60% (Normal Value: 60%)

WALL MOTION ABNORMALITY: No RWMA at rest

Final Impression:

Grade I LV Diastolic Dysfunction
No MR/AR/TR/PR Seen
Normal Biventricular Systolic Function
No I/C Clot /PE /Vegetation

Dr. Parth Sthapak (Director & Chief)
MD (Medicine), DM (Cardiology)
Sr. Consultant Interventional Cardiologist

2021-9-11 12:49:58

TO: 00004297

<< Conduction >>

Name: King
Age: 44y
Weight(kg): 71.2kg

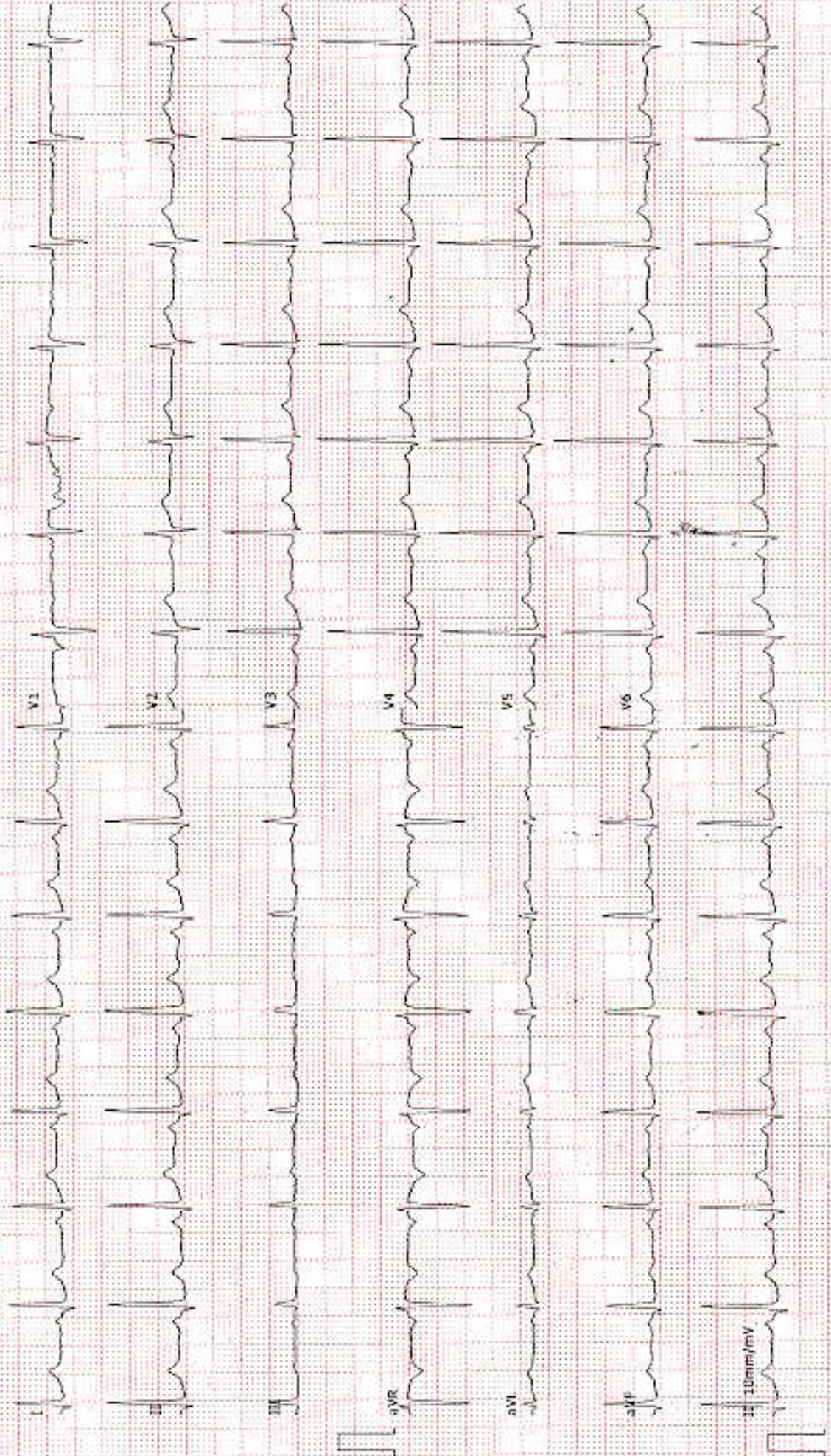
Gender:
Height(cm):
BP(mmHg):

HR: bpm 87
P-R: ms 85
Q-R-S: ms 123
QT/QTc: ms 340/112
P/QRS/T AXES: deg 197/51/93
RV5/SV1: mV 1.64/0.38
RV5+SV1: mV 2.02

Sinus rhythm
Unintentional ventricular conduction delay
** ABNORMAL ECG **

Report Confirmed by DR. PARTH STHAPAK

11/9/21



BILL CUM RECEIPT.

REG NO.	: 202109110003	DATE	: 11-09-2021/10:26AM
NAME	: MRS. RINA KAUSHIK	FATHER/HUSBAND	: SURESH KAUSHIK
BILL NO.	: 21B-002456	RECEIPT NO.	:
AGE	: 44 Y	GENDER	: Female
CONSULTANT DR.	: PARTH STHAPAK	DEPARTMENT	: CARDIOLOGY
REF. BY	: SELF	CATEGORY	: TPA
MOBILE NO.	: 7693951777	DIAGNOSTIC NO	: 20210911005
ADDRESS	: AKRITI VIHAR AMLIDIH,RAIPUR		

S.No.	Code	Particulars	QTY	Performed	Amount(Rs.)
		MEDIWHEEL FULL BODY HEALTH CHECKUP FEMALE ABOVE 40 YAERS	1.00		2200.00
Total					2200.00
Net Amount Received					2200.00
DUE BALANCE					2200.00

PAYMENT MODE :

ALL service:COMPLETE BLOOD COUNT (CBC),ESR,URINE R/M,STOOL OCCULT BLOOD,BLOOD GROUP & RH TYPING (ABO-RH),BLOOD SUGAR (FASTING & PP),HBA1C (GLYCOCYLATED HB),THYROID PROFILE (T3,T4,TSH),LIPID PROFILE,SERUM URIC ACID,SERUM CREATININE,UREA,LIVER FUNCTION TEST (LFT),TOTAL PROTEIN A/G RATIO,ECG,2D ECHO,USG,SONO MEMMOGRAPHY,PAP SMEAR,X-RAY CHEST AP,CONSULTATION,PHYSICIAN CONSULTATION



Authorized Signat