

## Health Check up Booking Request(bobE29707), Beneficiary Code-39343

1 message

**Mediwheel** <wellness@mediwheel.in>  
 To: vidhidiagnostics@gmail.com  
 Cc: mediwheelwellness@gmail.com

16 February 2023 at 14:33

**011-41195959**
**Email:wellness@mediwheel.in**

 Dear **VIDHI DIAGNOSTICS**,

**City** : Ahmedabad . **Address** : L-86 Swatantra - Senani Nagar , Opp- Akhbarnagar Bus Terminals, New Wadaj , Ahmedabad -13,

We have received the confirmation for the following booking .

**Name** : MRS. DESAI NEHAL KAUSHIKKUMAR  
**Age** : 36  
**Gender** : Female  
**Package Name** : Medi-Wheel Metro Full Body Health Checkup Female Below 40  
**User Location** : NEAR SHANTHIVAN BUS STAND,AHMEDABAD,Gujarat,380007  
**Contact Details** : 99098 20943  
**Booking Date** : 16-02-2023  
**Appointment Date** : 25-02-2023

Member Information			
Booked Member Name	Age	Gender	Cost(In INR)
MRS. DESAI NEHAL KAUSHIKKUMAR	36	Female	Cashless
<b>Total amount to be paid</b>			<b>Cashless</b>

We will get back to you with confirmation update shortly. Please find the package details as attached for your reference.

**Package Name** : Medi-Wheel Metro Full Body Health Checkup Female Below 40 - Includes (37 )Tests

**Tests included in this Package** : Ecg, TSH, X-ray Chest, Stress Test (tmt)/ 2d Echo, Blood Sugar Postprandial, A:g Ratio, Blood Group, Total Cholesterol, Triglycerides, Fasting Blood Sugar, Ultrasound Whole Abdomen , Glycosylated Haemoglobin (hba1c), Hdl, Vldl, Urine Analysis, LDL, Total Protine, General Consultation, HDL/ LDL ratio, GGT(Gamma-glutamyl Transferase), Eye Check-up consultation, ALP (ALKALINE PHOSPHATASE), Uric Acid, AST/ALT Ratio, Serum Protein, CBC with ESR, Stool Analysis, Urine Sugar Fasting, Urine Sugar PP, T3, T4, Cholesterol Total / HDL Ratio, BUN, BUN/Creatinine Ratio, Bilirubin Total & Direct and Indirect, Albumin, Globulin

Medical Examination Report

Date : 25/02/2023

1. Personal Particulars

Name : Nehal Kaushik Kumar Desai

Age : 38 years Gender : Male / Female

Marital Status : Married

Past & Present Medical History : <sup>Pregnant</sup> No ectopic rupture with tubal rupture in 2020 operated by Dr. Harshvardh Desai at Resonance Hospital Surbhay Ahmedabad.

2. Clinical Medical Examination

Height : 156 cm Weight : 44 kg  
Blood Pressure : 106/78 mmHg Pulse : 68 p/min

General Condition : Good Skin : Good  
Central Nervous System : Good Head & Neck : Good  
Cardiovascular System : Good Chest : Good  
Abdomen : Good Limbs : Good  
Last menstrual period : -

Vision: : Right: 6/6 Left: 6/6  
N/G N/G

Colour vision : Normal/Colour Blind

Personal Habit : NO

Remarks : Fit / Unfit for employment

Dr. Vidhi D. Modh  
MBBS  
Reg. No. 1540  
Dr's name, signature & chop

Vidhi Diagnostics  
L-86, Swatantra-Senani Nagar,  
Opp. Akhbarnagar Bus Terminals,  
Nr. Akhbarnagar Circle,  
New Wadaj, Ahmedabad-13.


## Dr. Dinesh S. Modh

M.D., D.M.R.E. (Radiodiagnosis)

Consultant Radiologist & Sonologist

Ex. Junior Lecturer, B.J. Medical College, Civil Hospital, A'bad.

**VIDHI**  
DIAGNOSTICS



Patient's name : NEHAL KAUSHIKKUMAR DESAI  
Reg. ID : R-13594-23  
Referred by : Dr. MEDIWHEEL

Age/Sex : 38 Years/Female  
Accession : 469  
Date : 25/02/2023

### X-RAY CHEST (PA VIEW)

Both lung fields appear normal.  
No e/o consolidation or cavitations is seen.  
Both costo-phrenic angles appear clear.  
Cardiac size is with in normal limits.  
Both domes of diaphragm appear normal.  
Bony thoracic cage appears normal.

Thanks for reference.

Dr. Dinesh S. Modh

MD DMRE (Radiodiagnosis)

DR DINESH S. MODH

M.D. DMRE(RADIODIAGNOSIS)

ISO 9001:2015 Certified Diagnostics Center

Vidhi Imaging Center

L-86, Swatantra Senani Nagar, Opp. Indian Oil Petrol Pump, Akhbarnagar Circle, Nava Vadaj, Ahmedabad - 380 013.

Phone : (Radiology) 079-2762 1406 | M. 98799 29406, 98250 09406 | Time (Radiology) : Mon. to Sat. 9 am to 2 pm, 5 to 9 pm, Sunday 9 am to 12 Noon

E-mail : vidhidiagnostics@gmail.com, Website : www.vidhidiagnostics.com

Multislice CT Scan | CBCT-Dental Scan | Live 3D-4D Sonography | Colour Doppler | Echo Cardiography | Interventional Radiology | Maxillofacial Radiology | Fetal Medicine  
Digital X-Ray | Digital Mammography | Digital OPG/TMJ | ECG/TMT/PFT/EEG/EMG | Audiometry | Pathology Laboratory | Health Check Up Plans | Pre Employment Check Up

**CT SCAN & CBCT FACILITY NOW AVAILABLE**

HR : 68 bpm  
 PR : 162 ms  
 QRS : 82 ms  
 QT/QTc : 374/398 ms  
 P/QRS/T : 20/53/78 deg.  
 RV5/SV1 : 0.671/-0.421 mv  
 RV5+SV1 : 1.092 mv

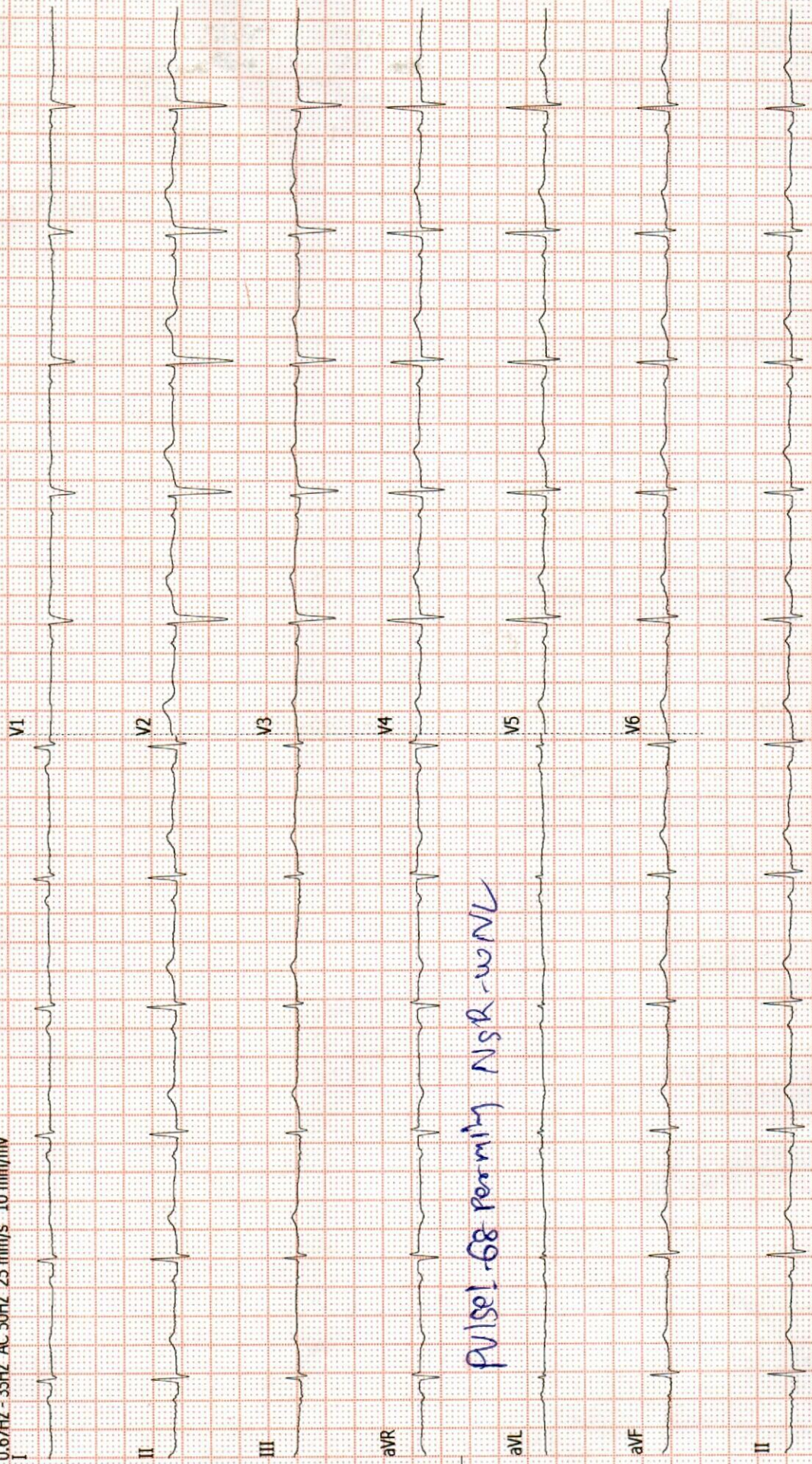**Sinus Brady**  
**\*\* normal ECG \*\***  
**Prithvi Diagnostics**  
 I-66, Swatantra-Senani Nagar,  
 Opp. Akhbarnagar Bus Terminals,  
 Nr. Akhbarnagar Circle,  
 New Wadaj, Ahmedabad-13.

ID: 8089  
 Name: nehal kaushikkumar desai  
 Age: 38yrs  
 Sex: Female  
 Hospital:

**Dr. Avinash Bhasakar**  
~~AVINASH BHASAKAR~~  
 MD, MBBS, D-Cardio  
 Reg. No.: G-45946

Department:  
 Need to be confirmed by doctor. Doctor Name:

0.67Hz - 35Hz AC 50Hz 25 mm/s 10 mm/mv



*Pulse 68 Per min NsR - wNL*

# Dr. Dinesh S. Modh

M.D., D.M.R.E. (Radiodiagnosis)  
Consultant Radiologist & Sonologist  
Ex. Junior Lecturer, B.J. Medical College, Civil Hospital, A'bad.



Patient's name : NEHAL KAUSHIKKUMAR DESAI  
Reg. ID : R-13594-23  
Referred by : Dr. MEDIWHEEL

Age/Sex : 38 Years/Female  
Accession : 469  
Date : 25/02/2023

## 2D- ECHO REPORT

### FINAL CONCLUSION:

LV IS NORMAL SIZE. GOOD LV SYSTOLIC FUNCTION NO RWMA.  
LVEF - 60%. NO CONCENTRIC LVH.  
NORMAL LV COMPLIANCE.  
LA IS NORMAL SIZE. NO LA CLOT.  
RV IS NORMAL SIZE. GOOD RV SYSTOLIC FUNCTION.  
RA IS NORMAL SIZE.  
MITRAL VALVE IS NORMAL. NO MS. MILD MR (15%). NO MVP.  
AORTIC VALVE IS NORMAL. NO AS. NO AR.  
TRICUSPID VALVE IS NORMAL. NO TR. RVSP-26 mmHg. NO PAH.

NO CLOT, NO VEGETATION, NO PERICARDIAL EFFUSION.

### DIMENSIONS:

AORTA	2.6 C.M
LEFT ATRIUM	2.7 C.M
LVDD	4.1 C.M.
IVSD	1.0 C.M
PWD	1.0 C.M
LVDS	2.6 C.M.

### COLOUR DOPPLER FINDING:

STRUCTURE	VELOCITY m/sec
	Max
PULMONARY VALVE	0.7
MITRAL VALVE	E : 0.7 A: 0.4
AORTIC VALVE	1.0

Dr. Avinash Bhaskar  
M.D. D Cardiol  
Reg. No.: G-45946  
**DR AVINASH BHASKAR**

ISO 9001:2015 Certified Diagnostics Center

Vidhi Imaging Center

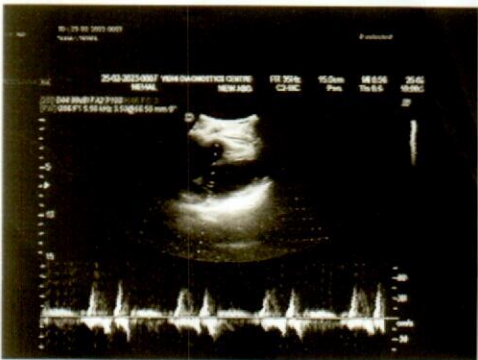
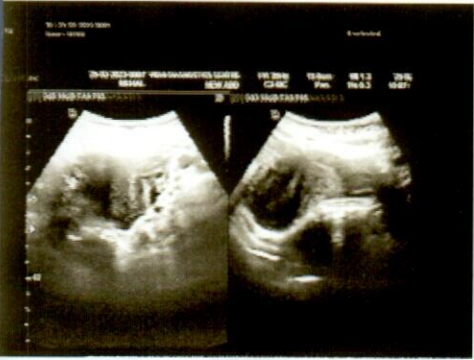
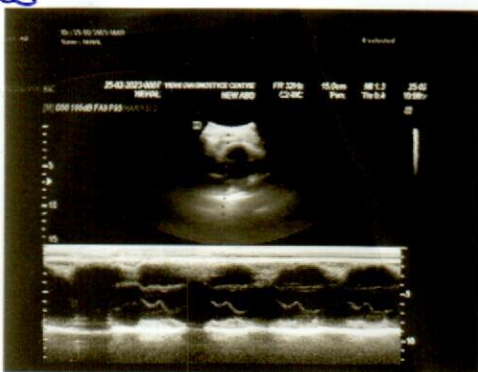
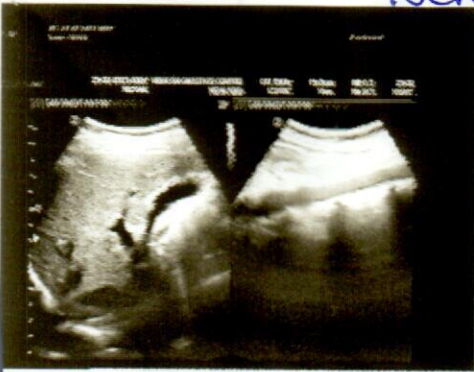L-86, Swatantra Senani Nagar, Opp. Indian Oil Petrol Pump, Akharnagar Circle, Nava Vadaj, Ahmedabad - 380 013.

Phone : (Radiology) 079-2762 1406 | M. 98799 29406, 98250 09406 | Time (Radiology) : Mon. to Sat. 9 am to 2 pm, 5 to 9 pm, Sunday 9 am to 12 Noon  
E-mail : vidhidiagnostics@gmail.com, Website : www.vidhidiagnostics.com

Multislice CT Scan | CBCT-Dental Scan | Live 3D-4D Sonography | Colour Doppler | Echo Cardiography | Interventional Radiology | Maxillofacial Radiology | Fetal Medicine  
Digital X-Ray | Digital Mammography | Digital OPG/TMJ | ECG/TMT/PFT/EEG/EMG | Audiometry | Pathology Laboratory | Health Check Up Plans | Pre Employment Check Up

**CT SCAN & CBCT FACILITY NOW AVAILABLE**

*Neheal*



## Dr. Dinesh S. Modh

M.D., D.M.R.E. (Radiodiagnosis)

Consultant Radiologist & Sonologist

Ex. Junior Lecturer, B.J. Medical College, Civil Hospital, A'bad.



Patient's name : NEHAL KAUSHIKKUMAR DESAI  
Reg. ID : R-13594-23  
Referred by : Dr. MEDIWHEEL

Age/Sex : 38 Years/Female  
Accession : 469  
Date : 25/02/2023

### **USG ABDOMEN**

**LIVER:** - Liver appears normal in size & show normal echotexture. No evidence of diffuse or focal lesion is seen. Intrahepatic biliary radicals appear normal. Portal vein and CBD appear normal. No e/o calculus is seen in bile duct.

**GALL BLADDER:** - Gall bladder is distended & appears normal. No evidence of calculus or cholecystitis is seen. No evidence of pericholecystic fluid is seen.

**SPLEEN:** - Spleen appears normal in size & shows normal echotexture. No evidence of diffuse or focal lesion is seen.

**PANCREAS:** - Pancreas appears normal size and echopattern. No e/o diffuse or focal lesion is seen. Main pancreatic duct appears normal.

**KIDNEY:**-Both Kidneys appear normal in size & echotexture.

**No e/o calculus or hydronephrosis or hydroureter is seen in either side.**

Cortico-medullary differentiation is maintained on either side.

Both suprarenal regions appear normal.

**RIF & BOWEL LOOPS (By high frequency probe):-Normal.**

No evidence of pre & para aortic lymphadenopathy is seen.

No evidence of free fluid is seen in abdomen.

No evidence of dilated or thickened bowel loops is seen.

**Urinary bladder:** - appears normal. No e/o calculus or mass lesion is seen in bladder.

Uterus appears normal in size and echopattern.

No evidence of diffuse or focal lesion is seen.

Cervical region appears normal.

Endometrial thickness is 6.4mm.

Both ovaries and adnexal regions appear normal.

No e/o free fluid is seen in pouch of Douglas.

Thanks for reference.

Dr. Dinesh S. Modh  
MD DMRE (Radiodiagnosis)  
@-23825

DR DINESH S. MODH

M.D. DMRE(RADIODIAGNOSIS)

ISO 9001:2015 Certified Diagnostics Center

Vidhi Imaging Center

L-86, Swatantra Senani Nagar, Opp. Indian Oil Petrol Pump, Akhbarnagar Circle, Nava Vadaj, Ahmedabad - 380 013.

Phone : (Radiology) 079-2762 1406 | M. 98799 29406, 98250 09406 | Time (Radiology) : Mon. to Sat. 9 am to 2 pm, 5 to 9 pm, Sunday 9 am to 12 Noon

E-mail : vidhidiagnostics@gmail.com, Website : www.vidhidiagnostics.com

Multislice CT Scan | CBCT-Dental Scan | Live 3D-4D Sonography | Colour Doppler | Echo Cardiography | Interventional Radiology | Maxillofacial Radiology | Fetal Medicine  
Digital X-Ray | Digital Mammography | Digital OPG/TMJ | ECG/TMT/PFT/EEG/EMG | Audiometry | Pathology Laboratory | Health Check Up Plans | Pre Employment Check Up

**CT SCAN & CBCT FACILITY NOW AVAILABLE**


## Dr. Dinesh S. Modh

M.D., D.M.R.E. (Radiodiagnosis)

Consultant Radiologist & Sonologist

Ex. Junior Lecturer, B.J. Medical College, Civil Hospital, A'bad.

Panel Doctor of L.I.C.



I have no require stool routine test so  
I don't want to give sample  
@weedin

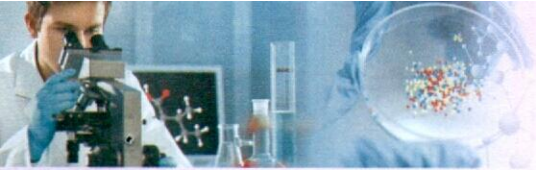ISO 9001:2015 Certified Diagnostics Center

Vidhi Imaging Center, L-86, Swatantra Senani Nagar, Opp. Akhbarnagar Petrol Pump, Nr. Akhbarnagar Circle, Nava-Vadaj, Ahmedabad - 380 013.

Phone : 079-2762 1406, Mobile : 98799 29406, 98250 09406, E-mail : vidhidiagnostics@gmail.com, Website : www.vidhidiagnostics.com

FACILITIES : Live 3D-4D Sonography | Colour Doppler | Echo Cardiography | Interventional Radiology | Fetal Medicine | Digital X-Ray  
Digital Mammography | Digital OPG / TMJ | ECG / TMT / PFT / EEG / EMG | Pathology Laboratory | Health Check Up Plans | Pre Employment Check Up





Pathology Department

**VIDHI**<sup>®</sup>  
**DIAGNOSTICS**



Patient's name : NEHAL KAUSHIKKUMAR DESAI  
Age/Sex : 38 Years/Female  
Referred by : Dr. MEDIWHEEL  
Collection Time : 09:52

Reg. ID : P-7599-23  
Accession : 467  
Order Dt/time : 25/02/2023 09:52

**Complete Blood Count**

Sample Type: EDTA

Test Name	Result	Units	Biological Reference Interval
<b><u>Blood Counts</u></b>			
Haemoglobin :	<b>12.1</b>	Gms%	12.5 - 16.0
Total R.B.C. :	<b>4.13</b>	mill/c.mm	4.2 - 5.4
Total W. B. C. :	7,150	/cu mm	4000 - 10500
Platelet Count :	2,90,000	/cu.mm	1,50,000 - 4,50,000
<b><u>Differential Count</u></b>			
Neutrophils :	60	%	40 - 70
Lymphocytes :	36	%	20 - 40
Eosinophils :	02	%	1 - 4
Monocytes :	02	%	2 - 6
Basophils :	00	%	0 - 01
<b><u>Blood Indices</u></b>			
P. C. V :	<b>36.1</b>	%	37 - 47
M. C. V. :	87.3	fl	78 - 100
M.C.H :	29.2	pg	27 - 31
M. C. H. C :	33.5	%	32 - 36
R.D.W :	12.8	%	11.5 - 14.0
<b><u>E.S.R.( Westergren Method )</u></b>			
After one hour :	10	mm/hr	3 - 12

TESTS DONE ON FULLY AUTOMATED HEMATOLOGY ANALYZER.

*Dr. Gayatri M. Mehta*

M. D. (Patho)  
Reg. No. G-32215

DR GAYATRI MEHTA  
MD(PATHOLOGY)

DR. ANAND D. PARIKH  
MD(PATHOLOGY)

LAB USE ONLY (Entered by :GM Enter Date/Time:25/02/2023 2:08:00 PM) (Verify by :GM Verify Date/Time:25/02/2023 2:08:00 PM)

ISO 9001:2015 Certified Diagnostics Center

Vidhi Imaging Center | Pathology Department

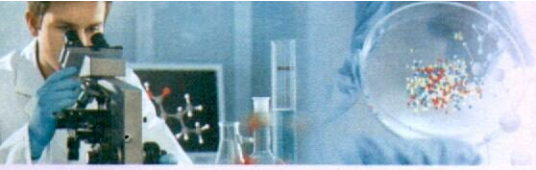L-86, Swatantra Senani Nagar, Opp. Akhbarnagar Petrol Pump, Nr. Akhbarnagar Circle, Nava-Vadaj, Ahmedabad - 380 013.

Ph. (Pathology) : 079-2762 1406, 8849893954 M. 98799 29406, 98250 09406, E-mail : vidhidiagnostics@gmail.com, Web. : www.vidhidiagnostics.com

Time (Pathology) : Mon. to Sat. 8.30 am to 8.00 pm, Sunday 9 am to 12 Noon

*Pathology means science behind medicine*

**CT SCAN & CBCT FACILITY NOW AVAILABLE**



Patient's name : NEHAL KAUSHIKKUMAR DESAI  
Age/Sex : 38 Years/Female  
Referred by : Dr. MEDIWHEEL  
Collection Time : 09:52

Reg. ID : P-7599-23  
Accession : 467  
Order Dt/time : 25/02/2023 09:52

**Blood Group**

Sample Type: EDTA sample.

Test Name	Result
BG :	" B "
RH :	POSITIVE
Remarks	Done by forward grouping method.

**Blood Glucose**

Sample Type: Serum

Test Name	Result	Units	Biological Reference Interval
Fasting Blood Glucose :	80.0	mg/dl	70 - 110
<i>GOD-POD Method.</i>			

**Blood Glucose**

Sample Type: Serum

Test Name	Result	Units	Biological Reference Interval
Post Prandial Blood Glucose After 2hr. :	113.7	mg/dl	80 - 140
<i>GOD-POD Method.</i>			

*Dr. Gayatri M. Mehta*  
M. D. (Patho)

Reg. No. G-32215

DR GAYATRI MEHTA  
MD(PATHOLOGY)

DR. ANAND D. PARIKH  
MD(PATHOLOGY)

LAB USE ONLY (Entered by :GM Enter Date/Time:25/02/2023 4:32:00 PM) (Verify by :GM Verify Date/Time:25/02/2023 4:32:00 PM)

ISO 9001:2015 Certified Diagnostics Center  
Vidhi Imaging Center | Pathology Department

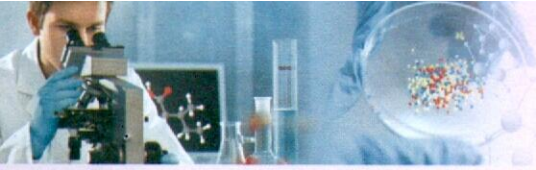L-86, Swatantra Senani Nagar, Opp. Akhbarnagar Petrol Pump, Nr. Akhbarnagar Circle, Nava-Vadaj, Ahmedabad - 380 013.

Ph. (Pathology) : 079-2762 1406, 8849893954 M. 98799 29406, 98250 09406, E-mail : vidhidiagnostics@gmail.com, Web. : www.vidhidiagnostics.com

Time (Pathology) : Mon. to Sat. 8.30 am to 8.00 pm, Sunday 9 am to 12 Noon

*Pathology means science behind medicine*

**CT SCAN & CBCT FACILITY NOW AVAILABLE**



Pathology Department



Patient's name : NEHAL KAUSHIKKUMAR DESAI  
Age/Sex : 38 Years/Female  
Referred by : Dr. MEDIWHEEL  
Collection Time : 09:52

Reg. ID : P-7599-23  
Accession : 467  
Order Dt/time : 25/02/2023 09:52

### Lipid Profile

Sample Type: Serum

Test Name	Result	Units	Biological Reference Interval
<b>S. Cholesterol :</b> Oxidase-esterase method.	177.0	mg/dl	0 - 200
<b>S. Triglyceride :</b> Enzymatic Colorimetry method	<b>227.0</b>	mg/dL	0 - 200
<b>S. HDL - Cholesterol :</b> Serum by Enzymatic method.	56.6	mg/dL	35 - 65
<b>S. LDL - Cholesterol :</b> Serum by Enzymatic method	75	mg/dL	0 - 130
<b>S. VLDL - Cholesterol :</b>	<b>45.4</b>	mg/dL	0 - 30
<b>S. Chole/HDL.Ratio :</b>	3.13		1 - 6
<b>S. LDL / HDL Cholesterol Ratio :</b>	1.33		0 - 3.5

*Dr. Gayatri M. Mehta*

M. D. (Patho)

Reg. No. G-32215  
DR. GAYATRI MEHTA  
MD(PATHOLOGY)

DR. ANAND D. PARIKH  
MD(PATHOLOGY)

LAB USE ONLY (Entered by :GM Enter Date/Time:25/02/2023 4:32:00 PM) (Verify by :GM Verify Date/Time:25/02/2023 4:32:00 PM)

ISO 9001:2015 Certified Diagnostics Center

Vidhi Imaging Center | Pathology Department

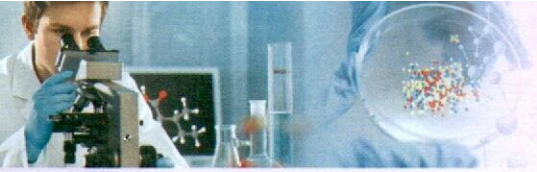L-86, Swatantra Senani Nagar, Opp. Akhbarnagar Petrol Pump, Nr. Akhbarnagar Circle, Nava-Vadaj, Ahmedabad - 380 013.

Ph. (Pathology) : 079-2762 1406, 8849893954 M. 98799 29406, 98250 09406, E-mail : vidhidiagnostics@gmail.com, Web. : www.vidhidiagnostics.com

Time (Pathology) : Mon. to Sat. 8.30 am to 8.00 pm, Sunday 9 am to 12 Noon

*Pathology means science behind medicine*

**CT SCAN & CBCT FACILITY NOW AVAILABLE**



Pathology Department

**VIDHI**  
**DIAGNOSTICS**



Patient's name : NEHAL KAUSHIKKUMAR DESAI  
Age/Sex : 38 Years/Female  
Referred by : Dr. MEDIWHEEL  
Collection Time : 09:52

Reg. ID : P-7599-23  
Accession : 467  
Order Dt/time : 25/02/2023 09:52

**HbA1C**

Sample Type: Serum

Test Name	Result	Units	Biological Reference Interval
HbA1C :	5.2	%	Non-diabetic: 4.2-6.2 Pre-diabetic : 6.3-7.2 Diabetic : 7.3-8.2
Mean Blood Glucose of Last 03 months.	102.54	mg/dl	

**Comment**

\*As per the new 2009 update of American Diabetes Association regarding HbA1C & Mean Blood Glucose relationship.

**NOTE:**

This test is used to monitor diabetic patients compliance with the therapeutic regimen and log it's level is proportional to both the average blood glucose concentration and the life span of the red blood cells (RBC) in circulation. HbA1c values are free of day to day glucose fluctuations and are unaffected by exercise or recent food intake.

*Dr. Gayatri M. Mehta*

M. D. (Patho)

Reg No. G-32215

DR GAYATRI MEHTA  
MD(PATHOLOGY)

DR. ANAND D. PARIKH  
MD(PATHOLOGY)

LAB USE ONLY (Entered by :GM Enter Date/Time:25/02/2023 4:32:00 PM) (Verify by :GM Verify Date/Time:25/02/2023 4:32:00 PM)

ISO 9001:2015 Certified Diagnostics Center

Vidhi Imaging Center | Pathology Department

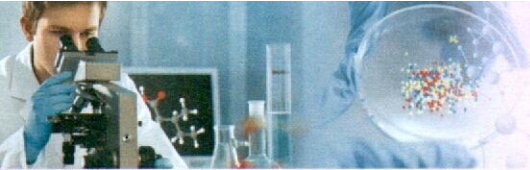L-86, Swatantra Senani Nagar, Opp. Akhbarnagar Petrol Pump, Nr. Akhbarnagar Circle, Nava-Vadaj, Ahmedabad - 380 013.

Ph. (Pathology) : 079-2762 1406, 8849893954 M. 98799 29406, 98250 09406, E-mail : vidhidiagnostics@gmail.com, Web. : www.vidhidiagnostics.com

Time (Pathology) : Mon. to Sat. 8.30 am to 8.00 pm, Sunday 9 am to 12 Noon

*Pathology means science behind medicine*

**CT SCAN & CBCT FACILITY NOW AVAILABLE**



Pathology Department

**VIDHI**  
DIAGNOSTICS



Patient's name : NEHAL KAUSHIKKUMAR DESAI  
Age/Sex : 38 Years/Female  
Referred by : Dr. MEDIWHEEL  
Collection Time : 09:52

Reg. ID : P-7599-23  
Accession : 467  
Order Dt/time : 25/02/2023 09:52

**BIOCHEMISTRY**

Sample type :Serum

Test Name	Result	Units	Biological Reference Interval
Urea, (Serum by GLDH method) :	17.8	mg/dl	10 - 50
S.Uric acid, (Serum by Uricase method) :	4.1	mg/dl	2.6-6.0
Bun :	8.3	mg/dl	6-20
Creatinine, (Serum by Enzymatic reaction) :	0.59	mg/dl	0.5-1.2
S.G.P.T (ALT) : (Serum by IFCC method)	13.0	U/L	0 - 40
S.G.O.T (AST) : (Serum by IFCC method)	15.4	U/L	0 - 37
ALK.PHOSPHATASE : (Serum by PNP method)	56.0	U/L	35-104
G.G.T :	12.2	U/L	8 - 78
<b><u>BILIRUBIN</u></b>			
Total :	0.37	mg/dl	Up to 1.2
Direct :	0.18	mg/dl	0-0.7
Indirect :	0.19	mg/dl	0 - 0.5
<b><u>SERUM PROTEINS</u></b>			
Total Protein (Serum by Biuret method) :	7.24	gms/dl	6.4 - 8.5
Albumin (Serum by BCG method) :	4.30	gms/dl	3.97-4.94
Globulins :	2.94	gms/dl	2.3 - 3.5
A/G Ratio :	1.463		0.9 - 2.9

*Dr. Gayatri M. Mehta*

M. D. (Patho)

Reg. No. G-32215

DR GAYATRI MEHTA  
MD(PATHOLOGY)

DR. ANAND D. PARIKH  
MD(PATHOLOGY)

LAB USE ONLY (Entered by :GM Enter Date/Time:25/02/2023 4:32:00 PM) (Verify by :GM Verify Date/Time:25/02/2023 4:32:00 PM)

ISO 9001:2015 Certified Diagnostics Center

Vidhi Imaging Center | Pathology Department

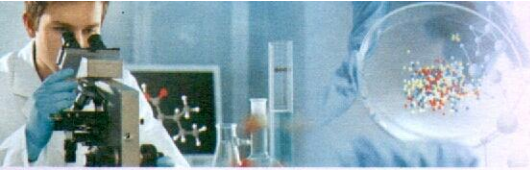L-86, Swatantra Senani Nagar, Opp. Akharnagar Petrol Pump, Nr. Akharnagar Circle, Nava-Vadaj, Ahmedabad - 380 013.

Ph. (Pathology) : 079-2762 1406, 8849893954 M. 98799 29406, 98250 09406, E-mail : vidhidiagnostics@gmail.com, Web. : www.vidhidiagnostics.com

Time (Pathology) : Mon. to Sat. 8.30 am to 8.00 pm, Sunday 9 am to 12 Noon

*Pathology means science behind medicine*

**CT SCAN & CBCT FACILITY NOW AVAILABLE**



Pathology Department



Patient's name : NEHAL KAUSHIKKUMAR DESAI  
Age/Sex : 38 Years/Female  
Referred by : Dr. MEDIWHEEL  
Collection Time : 09:52

Reg. ID : P-7599-23  
Accession : 467  
Order Dt/time : 25/02/2023 09:52

### Thyroid Function Test

Sample Type: Serum

Test Name	Result	Units	Biological Reference Interval
TOTAL T3 :	1.20	ng/ml	0.84 - 2.0
TOTAL T4 :	7.95	ug/dl	5.1 - 14.0
TSH(Ultra sensitive) :	1.842	mIU/L	0.27 - 4.2

*Dr. Gayatri M. Mehta*

M. D. (Patho)

Reg. No. G-32215  
DR. GAYATRI MEHTA  
MD(PATHOLOGY)

DR. ANAND D. PARIKH  
MD(PATHOLOGY)

LAB USE ONLY (Entered by :GM Enter Date/Time:25/02/2023 4:32:00 PM) (Verify by :GM Verify Date/Time:25/02/2023 4:32:00 PM)

ISO 9001:2015 Certified Diagnostics Center

Vidhi Imaging Center | Pathology Department

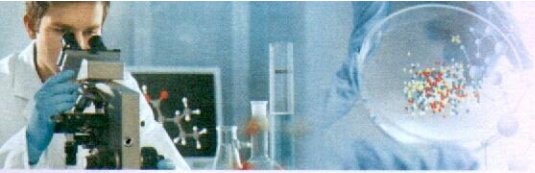L-86, Swatantra Senani Nagar, Opp. Akhbarnagar Petrol Pump, Nr. Akhbarnagar Circle, Nava-Vadaj, Ahmedabad - 380 013.

Ph. (Pathology) : 079-2762 1406, 8849893954 M. 98799 29406, 98250 09406, E-mail : vidhidiagnostics@gmail.com, Web. : www.vidhidiagnostics.com

Time (Pathology) : Mon. to Sat. 8.30 am to 8.00 pm, Sunday 9 am to 12 Noon

*Pathology means science behind medicine*

**CT SCAN & CBCT FACILITY NOW AVAILABLE**



Pathology Department



Patient's name : NEHAL KAUSHIKKUMAR DESAI  
Age/Sex : 38 Years/Female  
Referred by : Dr. MEDIWHEEL  
Collection Time : 09:52

Reg. ID : P-7599-23  
Accession : 467  
Order Dt/time : 25/02/2023 09:52

### Urine Analysis

Sample Type: Urine

Test Name	Result	Units	Biological Reference Interval
<b><u>Physical Examination</u></b>			
Quantity :	20	ml	0 - 500 ml
Colour :	Pale Yellow		Pale Yellow
Transparency :	Slight Turbid.		Clear
Reaction :	Acidic		4.6 - 8.0
Specific Gravity :	1.030		1.016 - 1.022
Sediment :	Present		
<b><u>Chemical Examination</u></b>			
Albumin :	Present (Faint Trace)		Absent
Sugar :	NIL		Absent
Acetone :	Absent		Absent
Bile Salts :	Absent		Absent
Bile Pigments :	Absent		Absent
Urobilogen :	Absent		Absent
Nitrites :	Absent		Absent
<b><u>Microscopic Examination</u></b>			
Red blood Cells :	2-3	/h.p.f	Absent
Pus Cells :	1-2	/h.p.f	Absent
Epithelial Cells :	1-2	/h.p.f	< 10.0
Amorphous :	Absent	/h.p.f	Absent
Bacteria :	Absent	/h.p.f	Absent
Crystals :	Absent	/h.p.f	Absent
Casts :	Absent	/h.p.f	Absent
Fungus :	Not seen	/h.p.f	Absent

*Dr. Gayatri M. Mehta*  
M. D. (Patho)

Reg. No. G-32215

DR GAYATRI MEHTA  
MD(PATHOLOGY)

DR. ANAND D. PARIKH  
MD(PATHOLOGY)

ISO 9001:2015 Certified Diagnostics Center

LAB USE ONLY (Entered by: GM Verify Date/Time: 25/02/2023 4:33:00 PM) (Entered by: GM Verify Date/Time: 25/02/2023 4:33:00 PM)

L-86, Swatantra Senani Nagar, Opp. Akhbarnagar Petrol Pump, Nr. Akhbarnagar Circle, Nava-Vadaj, Ahmedabad - 380 013.

Ph. (Pathology) : 079-2762 1406, 8849893954 M. 98799 29406, 98250 09406, E-mail : vidhidiagnostics@gmail.com, Web. : www.vidhidiagnostics.com

Time (Pathology) : Mon. to Sat. 8.30 am to 8.00 pm, Sunday 9 am to 12 Noon

*Pathology means science behind medicine*

**CT SCAN & CBCT FACILITY NOW AVAILABLE**



भारत सरकार  
GOVERNMENT OF INDIA



नेहल कौशिककुमार देसाई  
Nehal Kaushikkumar Desai  
जन्म तारीख/DOB: 13/02/1985  
स्त्री/ FEMALE  
Mobile No: 9909820943  
**6716 4485 5735**

भारो आधार, भारी ओलप



*Neeedlin*

Dr. Vidhi D. Madh  
MBBS  
Reg. No. G-74540

**Vidhi Diagnostics**  
L-86, Swatantra Senani Nagar,  
Opp. Akhbarnagar Bus Terminal,  
Nr. Akhbarnagar Circle,  
New wadaj, Ahmedabad-13.



भारतीय विशिष्ट पहचान प्राधिकरण  
UNIQUE IDENTIFICATION AUTHORITY OF INDIA

संख्या :  
ब्लॉक 2, 502 त्रंबकेश्वर अपार्टमेंट, शरल  
रेसिडेन्सी पार्क, चांदखेडा, अमदावाड, अमदावाड,  
गुजरात - 382424  
Address :  
C/O, Block 2, 502 Trambakeshwar Apartment,  
Near Sharnam Residency, Chandkheda,  
Ahmedabad, Ahmedabad,  
Gujarat - 382424



**6716 4485 5735**

1947  
1800 300 1947

help@uidai.gov.in


www.uidai.gov.in

P.O. Box No.1947,  
Bengaluru-560 001





 **GPS Map Camera**



**Ahmedabad, Gujarat, India**

3H96+6PR, Chandlodiya Rd,


Swatantra Senani Nagar, Nava Vadaj,

Ahmedabad, Gujarat 380013, India

Lat 23.068138°

Long 72.561784°

25/02/23 09:47 AM GMT +05:30

Dr.  Vidhi D. Modh  
MBBS  
Reg. No. G-74540

**Vidhi Diagnostics**  
L-86, Swatantra Senani Nagar,  
Opp. Akhbarnagar Bus Terminals,  
Nr. Akhbarnagar Circle,  
New Wadaj, Ahmedabad-13,