



Dept. of Radiology
(For Report Purpose Only)



REQ. DATE : 12-FEB-2022
NAME : MRS. PATIL ROHINI S
PATIENT CODE : 105745
REFERRAL BY : HOSPITAL PATIENT

REP. DATE : 12-FEB-2022
AGE/SEX : 38 YR(S) / FEMALE

USG ABDOMEN AND PELVIS

OBSERVATION :

Liver : Is normal in size (12.3 cms), shape & echotexture. No focal lesion / IHBR dilatation.

CBD / PV : Normal.

G.B. : Moderately distended, normal.

Spleen : Is normal in size (9.2 cms), shape & echotexture. No focal lesion.

Pancreas : Normal in size, shape & echotexture.

Both kidneys are normal in size, shape & echotexture, CMD maintained. No calculus/ hydronephrosis / hydroureter on either side.

Right kidney measures : 9.6 x 4.2 cm.

Left kidney measures : 9.9 x 4.4 cm.

Urinary bladder : Moderately distended, normal.

Uterus : Anteverted, normal in size (6.8 x 3.2 x 4.7cms), shape, echotexture. Endometrium show normal appearance. ET = 6.6 mm.

Small anterior wall intramural uterine fibroid is noted measuring 1.1 x 1.1 cms.

Both ovaries : show normal features. Adnexa clear.

Right ovary : 2.3 x 1.5 cms.

Left ovary : 2.7 x 1.3 cms.

No obvious demonstrable small bowel / RIF pathology.

Normal Aorta, IVC, adrenals and other retroperitoneal structures.

No ascites / lymphadenopathy / pleural effusion.

IMPRESSION :

Small anterior wall intramural uterine fibroid.

- Kindly co-relate clinically.

Dr. PIYUSH YEOLE
(MBBS, DMRE)
CONSULTANT RADIOLOGIST



Dept. of Radiology
(For Report Purpose Only)



REQ. DATE : 12-FEB-2022
NAME : MRS. PATIL ROHINI S
PATIENT CODE : 105745
REFERRAL BY : HOSPITAL PATIENT

REP. DATE : 12-FEB-2022
AGE/SEX : 38 YR(S) / FEMALE

CHEST X-RAY PA VIEW

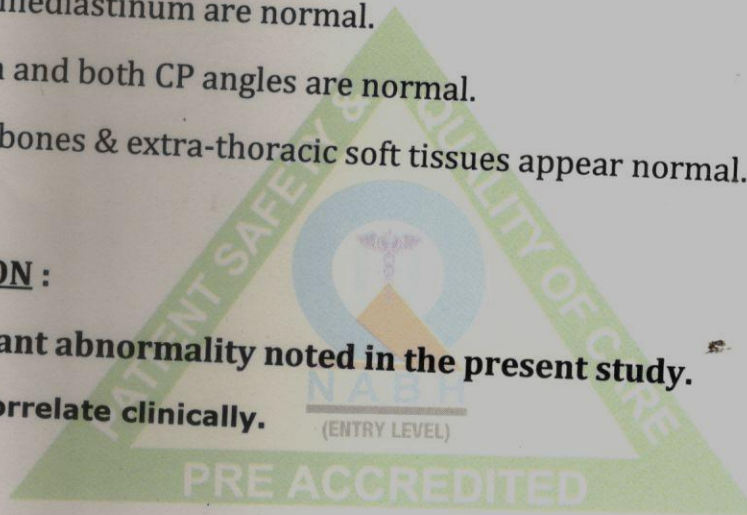
OBSERVATION :

Both lungs appear clear.
Heart and mediastinum are normal.
Diaphragm and both CP angles are normal.
Visualised bones & extra-thoracic soft tissues appear normal.

IMPRESSION :

No significant abnormality noted in the present study.

-Kindly correlate clinically.



Dr. PIYUSH YEOLE
(MBBS, DMRE)
CONSULTANT RADIOLOGIST



Dept. of Radiology
(For Report Purpose Only)



REQ. DATE : 12-FEB-2022
NAME : MRS. PATIL ROHINI S
PATIENT CODE : 105745
REFERRAL BY : HOSPITAL PATIENT

REP. DATE : 12-FEB-2022
AGE/SEX : 38 YR(S) / FEMALE

BILATERAL SONOMAMMOGRAPHY

OBSERVATION :

RT. BREAST.

Fibro-glandular tissues appear normal.
Skin and subcutaneous tissue appear normal.
Nipple shows normal features.
No significant axillary adenopathy.

LT. BREAST.

Fibro-glandular tissue appear normal.
Skin and subcutaneous tissue appear normal.
Nipple appear normal.
No e/o axillary lymphadenopathy.

IMPRESSION :

No sonologically demonstrable focal breast lesion.
- Kindly correlate clinically.

Dr. PIYUSH YEOLE
(MBBS, DMRE)
CONSULTANT RADIOLOGIST