

ভারত সরকার  
GOVERNMENT OF INDIA

বিনয় কৰ্মাকার  
Binoy Karmakar  
পিতা: অজিত কৰ্মাকার  
Father: AJIT KARMAKAR

জন্ম তারিখ/Year of Birth: 1989  
লিঙ্গ / Male

7253 6632 1759

আধার - সাধারণ মানুষের অধিকার



Binoy Karmakar

অজিত কৰ্মাকার

*Bireng kar markor.*

  
ভারতীয় বিশিষ্ট পরিচয় প্রাধিকারণ  
UNIQUE IDENTIFICATION AUTHORITY OF INDIA

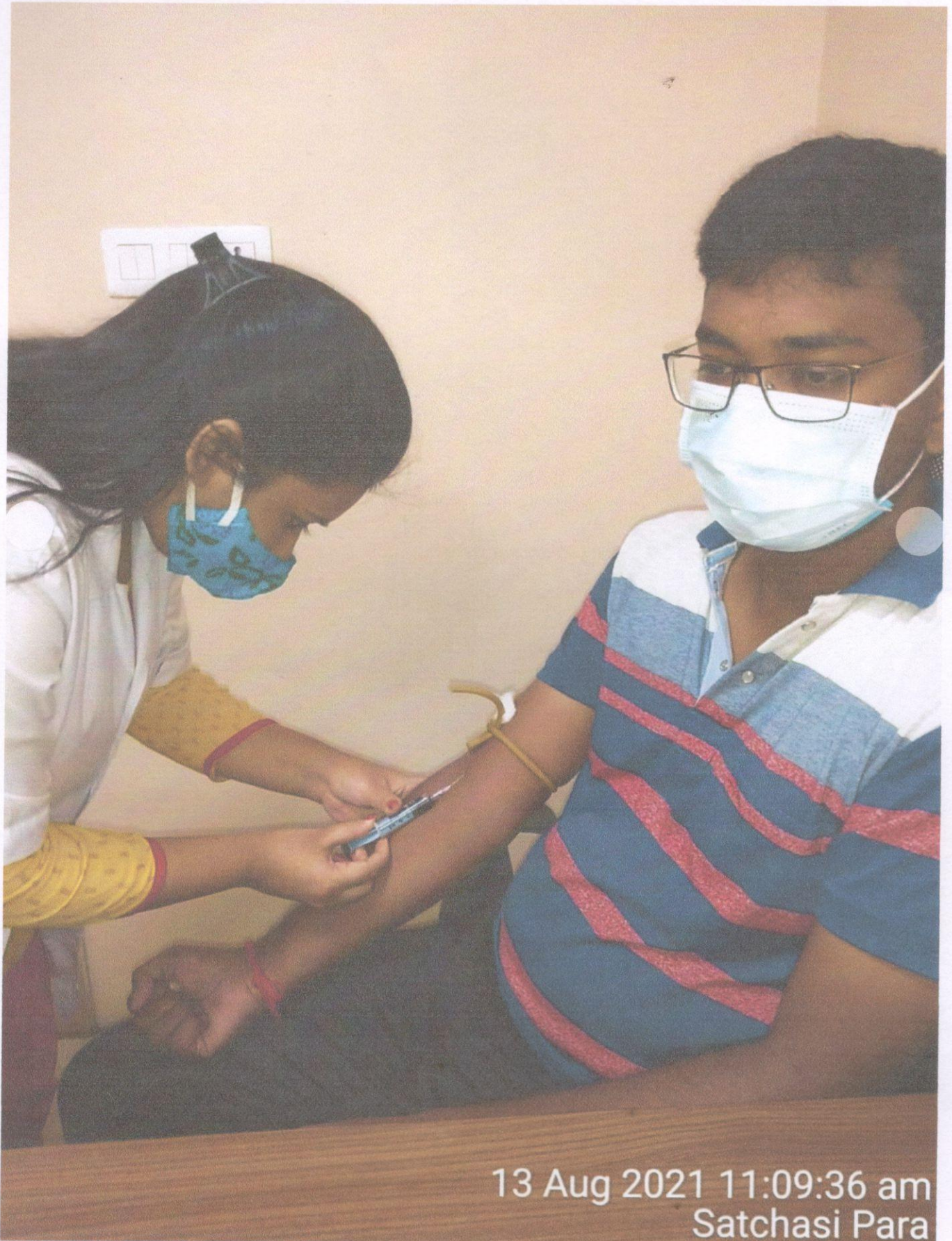Address: 208, D. H. ROAD,  
Paschim Barisha,  
Thakurpukur, South Twenly  
Four Parganas, West  
Bengal, 700063

ওয়েব  
www.uidai.gov.in

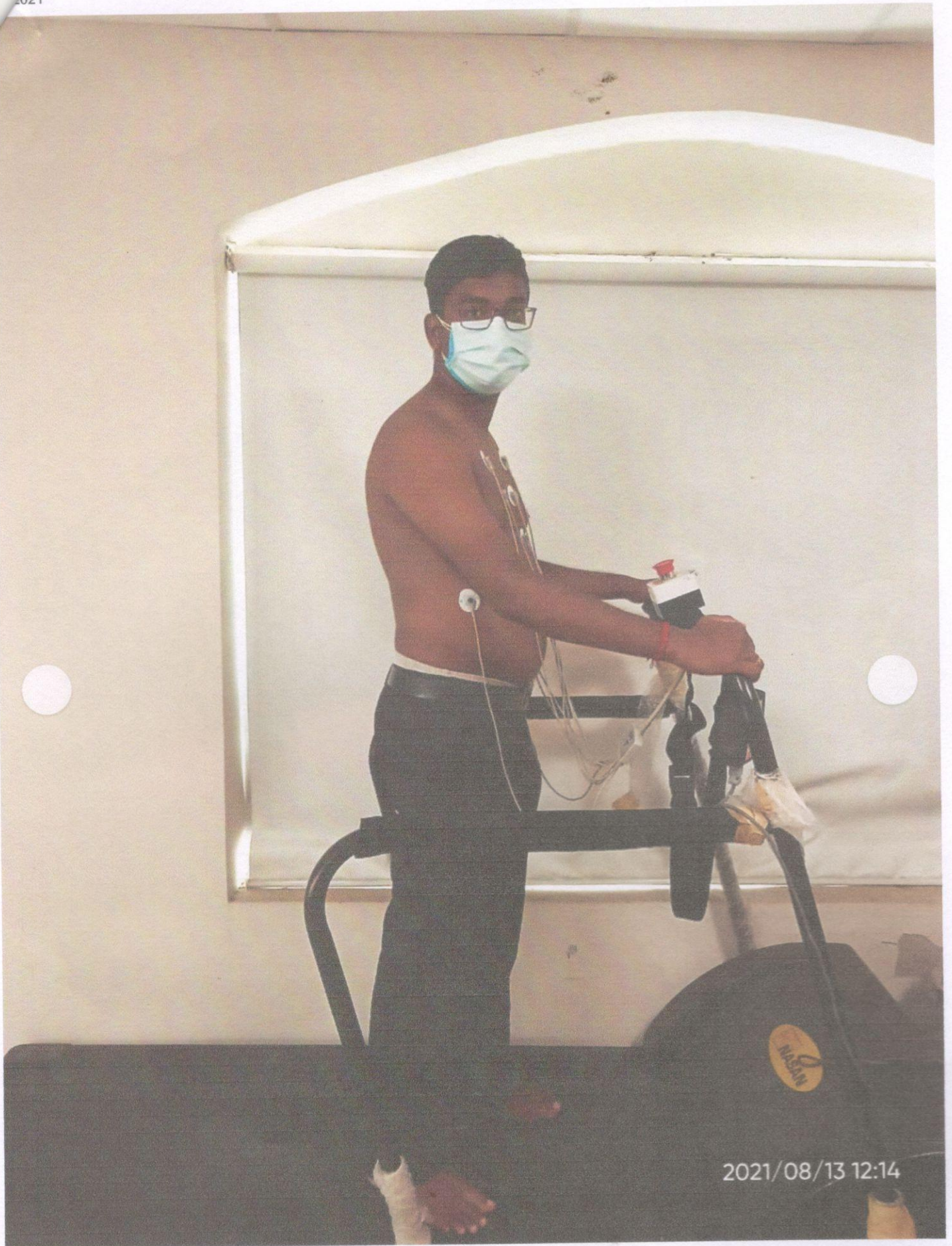
ইমেইল  
help@uidai.gov.in

ফোন  
1800 160 1947

P.O. Box No.1947,  
Bangalore-560 001



13 Aug 2021 11:09:36 am  
Satchasi Para



2021/08/13 12:14

## DEPARTMENT OF RADIOLOGY X-RAY OF CHEST (PA) VIEW

MR. NO- FSIN.0000000

SEX-MALE

NAME: -MR. BINOY KARMAKAR

EXAMINATION DATE- 13/08/2021


AGE- 31 YRS

REPORT DATE- 13/08/2021

REF DR.: -SELF

### FINDINGS:

- Bilateral lung fields are clear.
- Tracheal shadow is in the midline.
- Bilateral CP angle are clear
- Both hilum appear normal .
- CTR appears normal .
- No definite bone fracture is noted.

  
**DR. ARNAB MANDAL**

MD, Physician, PGDUS (Delhi) CEPT-USG (WBUHS KOLKATA)  
Fellow of Jefferson Ultrasound Radiology and Education Institute  
Philadelphia Ex-Radiology Resident (S.E. Railway)  
Regd.No:72022(WBMC)

<b>NAME: MR. BINOY KARMAKAR</b>	<b>AGE:31YRS</b>	<b>SEX:MALE</b>
<b>REF BY: CORPORATE (SELF)</b>	<b>MR NO:FSIN-0000</b>	<b>DATE: 13.08.2021</b>

**ULTRASOUND OF WHOLE ABDOMEN**

**LIVER:** Liver is normal in size(16.05cm), shape outline and echotexture.The intrahepatic tubular structures are normal.No focal area of altered echogenicity is noted. The porta hepatis is normal. The common bile duct at porta measures **4mm** . The portal vein measures **9mm** at porta.

**GALL BLADDER:** Gall bladder is distended. Wall is normal limits.No calculus or mass is seen within the gall bladder.

**PANCREAS:** It is normal in size, Shape, Outline and echotexture. Pancreatic duct is not dilated.

**SPLEEN:** Spleen in normal size, **8.86cm** hape, Outline and echotexture. No parenchymal lesion is noted.

**RIGHT KIDNEY:** kidneys are normal in position, size, shape, outline and echotexture. The cortico medullary differentiation is maintained. No calculus or hydronephrosis is seen.

**RIGHT KIDNEY:** measures – **9.86cm**.

**LEFT KIDNEY:** kidneys are normal in position, size, shape, outline and echotexture.The cortico medullary differentiation is maintained.No calculus or hydronephrosis is seen.

**LEFT KIDNEY:** measures – **10.36cm**.

**URINARY BLADDER:** : It is well distended with normal wall thickness . No calculus or mass is seen within the urinary bladder. The post void residual volume of urine is insignificant.

**PROSTATE:** It is normal in size, Shape & homogenous echotexture. The prostatic outline is smooth.The periprostatic plane is normal. It is normal measures (**3.74cmX2.45cmX3.69cm**) Vol-17.06ml.

**IMPRESSION:**

- HEPATOMEGALY.



**DR.A.K.ROY**

M.B.B.S, Dip BMSc, DTM&H (Cal)  
Certificate on CEBT Abdomino Pelvic, USG(WBHSU)

Resting ECG Report

Patient Name: Mr. BINOY KARMAKAR 31/M

August 13, 2021

Time: 11:59:55

QT/QTc: 0.372 / 0.405 Sec

P-QRS-T Axis (45)-(44)-(36) deg

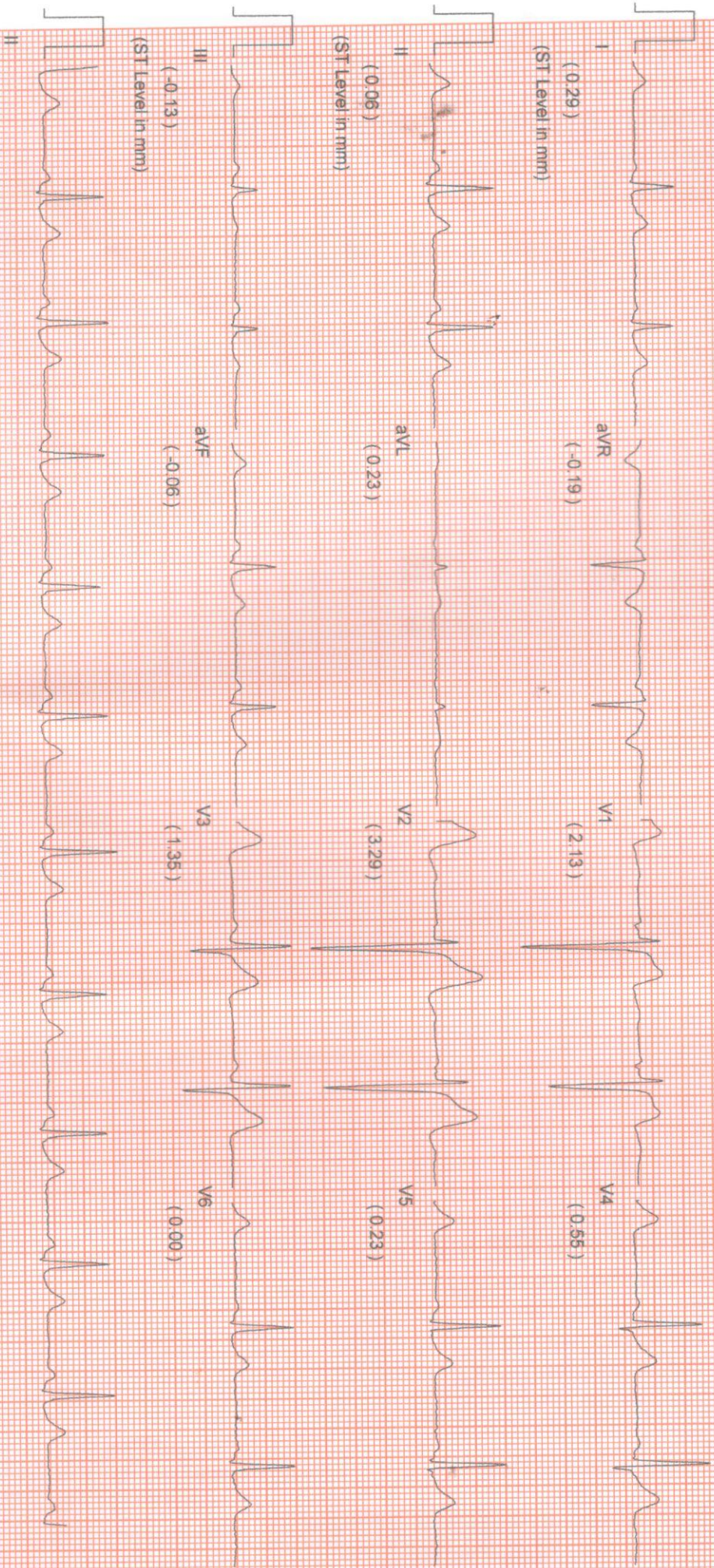
PR Interval: 0.15 sec

QRS Duration: 0.076 Sec

RR Interval: 0.84 sec

HR: 71 bpm

BP: 120 / 80 mmHg



Comments :-

*Binoy karmakar*

NAME:MR. BINOY KARMAKAR	MR NO: FSIN-0000	DATE : 13.08.2021
AGE: 31YRS.	SEX:MALE	REF BY: SELF(CORPORATE)

ECG REPORT

HR : 71 b/min  
AXIS : NORMAL  
RHYTHM : SINUS  
PR INTERVAL : 0.15 sec  
QT INTERVAL : 0.405 sec  
QRS DURATION : 0.076 sec  
T-WAVE : NORMAL

IMPRESSION:

- RESTING ECG IS WITHIN NORMAL LIMITS.



**Dr. SIDDHARTHA KUNDU**

MBBS (Cal), PGDCC, CCEBDM  
Clinical Cardiologist

Ex Sr Resident, Cardiology Dept  
B.R Singh Hospital, Eastern Railway

**APOLLO CLINIC @ OM TOWER**  
Opp. of Rabindra Bharati University  
Licensee : **Satyam Credit Pvt. Ltd.**

36C, B.T. Road, Kolkata - 700 002

E-mail : [sinthimor@theapolloclinic.com](mailto:sinthimor@theapolloclinic.com)  
[satyamcreditpvtltd@gmail.com](mailto:satyamcreditpvtltd@gmail.com)



033 2556 3333



033 2556 5555



+91 98521 66666



+91 74392 97827