



Aakriti Labs

3 Mahatma Gandhi Marg, Gandhi Nagar Mod
Tonk Road, Jaipur (Raj.) Ph.: 0141-2710661
www.aakritilabs.com
CIN NO.: U85195RJ2004PTC019563

PATIENT: MR. RAM KISHORE MEENA.	AGE /SEX: 31Y/MALE
REF: BY : MEDI WHEEL	DATE: 15 .03.2022

REPORT: DIGITAL X-RAY CHEST PA VIEW

Soft tissue shadow and bony cages are normal.

Trachea is central.

Bilateral lung field and both CP angle is clear.

Domes of diaphragm are normally placed.

Transverse diameter of heart appear with normal limits.

IMPRESSION:- NO OBVIOUS ABNORMALITY DETECTED.

**DR. NEERA MEHTA
MBBS, DMRD**

NAME	MR . RAM KISHORE MEENA	AGE	31Y	SEX	MALE
REF BY	MEDI WHEEL	DATE	15/03/2022	REG NO	

ECHOCARDIOGRAM REPORT

WINDOW- POOR/ADEQUATE/GOOD VALVE

MITRAL	NORMAL	TRICUSPID	NORMAL
AORTIC	NORMAL	PULMONARY	NORMAL

2D/M-MOD

IVSD mm	9.5	IVSS mm	13.9	AORTA mm	25.0
LVID mm	44.7	LVIS mm	29.4	LA mm	29.4
LVPWD mm	9.5	LVPWS mm	13.9	EF%	60%

CHAMBERS

LA	NORMAL	RA	NORMAL
LV	NORMAL	RV	NORMAL
PERICARDIUM	NORMAL		

DOPPLER STUDY MITRAL

PEAK VELOCITY m/s E/A	0.98/0.92	PEAK GRADIANT MmHg	
MEAN VELOCITY m/s		MEAN GRADIANT MmHg	
MVA cm ² (PLANIMETERY)		MVA cm ² (PHT)	
MR			

AORTIC

PEAK VELOCITY m/s	1.74	PEAK GRADIANT MmHg	
MEAN VELOCITY m/s		MEAN GRADIANT MmHg	
AR			

TRICUSPID

PEAK VELOCITY m/s	0.60	PEAK GRADIANT MmHg	
MEAN VELOCITY m/s		MEAN GRADIANT MmHg	
TR		PASP mmHg	

PULMONARY

PEAK VELOCITY m/s	1.55	PEAK GRADIANT MmHg	
MEAN VELOCITY m/s		MEAN GRADIANT MmHg	
PR		RVEDP mmHg	

IMPRESSION

- NORMAL LV SYSTOLIC & DIASTOLIC FUNCTION
- NO RWMA LVEF 60%
- NORMAL RV FUNCTION
- NORMAL CHAMBER DIMENSIONS
- NORMAL VALVULAR ECHO
- INTACT IAS / IVS
- NO THROMBUS, NO VEGETATION, NORMAL PERICARDIUM.
- IVC NORMAL

CONCLUSION : FAIR LV FUNCTION.


Dr. NITIZ GOYAL
M.B.B.S., M.D.
RMC - 023319

PATIENT NAME: MR RAM KISHORE MEENA	AGE & SEX: 31Y/M
REF. by: MEDIWHEEL	DATE: 15.03.2022

USG: WHOLE ABDOMEN (Male)

- LIVER** : Is **enlarged** in size & shape with **bright** echogenecity.
The IHBR and hepatic radicals are not dilated.
No evidence of focal echopoor/echorich lesion seen.
Portal vein diameter and common bile duct appear normal.
- GALL** : Is normal in size,shape and echotexture.Walls are smooth and
BLADDER regular with normal thickness.There is no evidence of cholelithiasis.
- PANCREAS** : Is normal in size,shape and echotexture.Pancreatic duct is not dilated.
SPLEEN : Is normal in size,shape and echogenecity.Splenic hilum is not dilated.
- KIDNEYS** : Right Kidney:-Size: 94x44 mm, Left Kidney:-Size: 104x52 mm.
Bilateral Kidneys are normal in size,shape and echotexture,
corticomedullary differentiation is fair and ratio appears normal.
Pelvi calyceal system is normal.No evidence of hydronephrosis/ nephrolithiasis.
- URINARY** : Bladder walls are smooth,regular and normal thickness.
BLADDER : No evidence of mass or stone in bladder lumen.
- PROSTATE**: Is normal in size, shape and echotexture,
measures: 29x29x25 mm, wt: 11 gms.
Its capsule is intact and no evidence of focal lesion.
- SPECIFIC** : No evidence of retroperitoneal mass or free fluid seen in peritoneal cavity.
: NO evidence of lymphadenopathy or mass lesion in retroperitoneum.
: Visualized bowel loop appear normal.Great vessels appear normal.

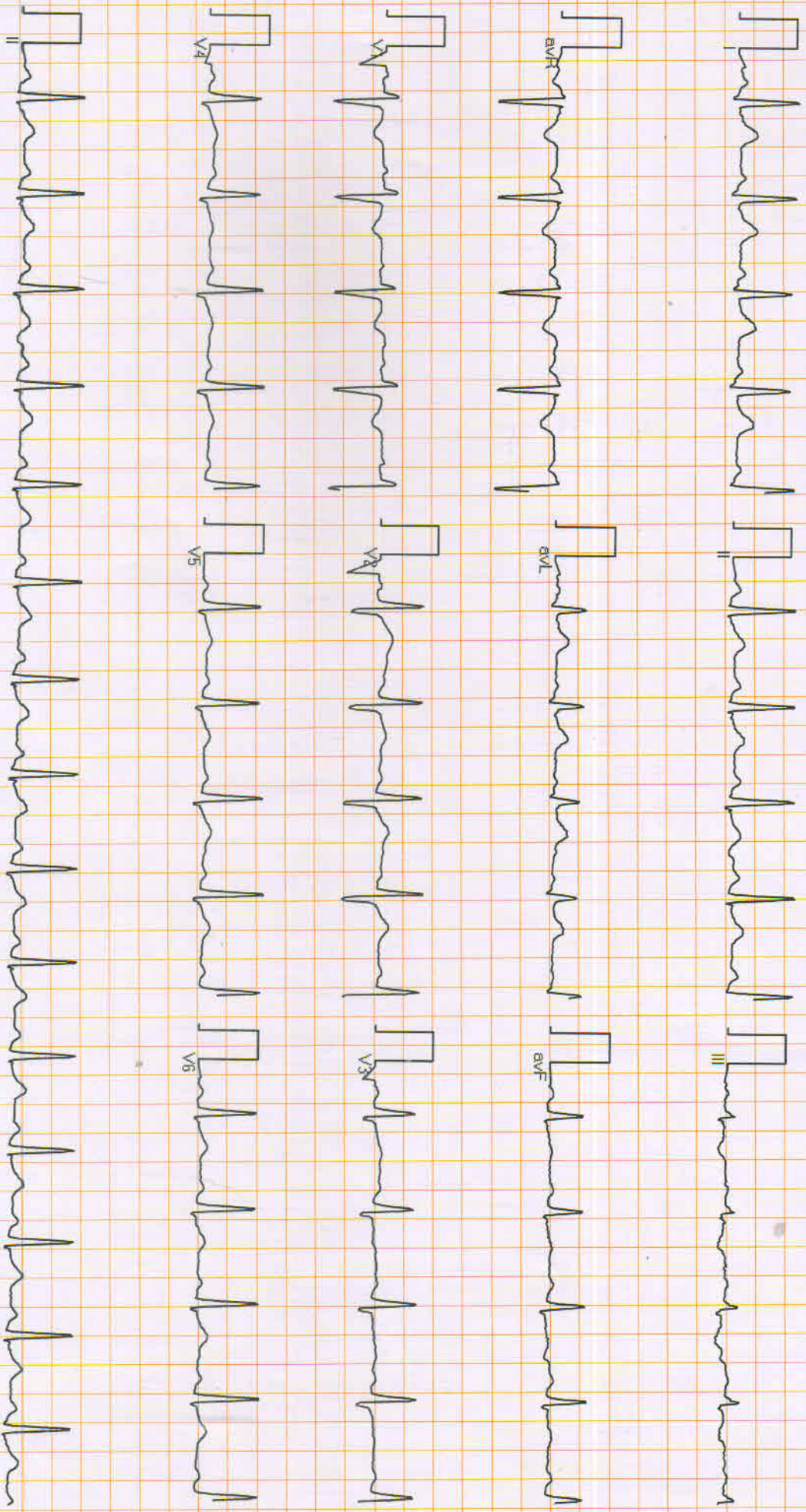
IMPRESSION:- Hepatomegaly with fatty changes.


DR NEERA MEHTA
MBBS, DMRD
RMCNO.005807/14853

AAKRITI LABS PVT.LTD JAIPUR

18807 / MR. RAM KISHORE MEENA / 31 Yrs / M / Non Smoker
Heart Rate : 91 bpm / Tested On : 15-Mar-22 10:30:08 / HF 0.05 Hz - LF 1.00 Hz / Notch 50 Hz / Sn 1.00 Cm/mV / Sw 25 mm/s
/ Revd By: MEDIWHEEL

ECG



Vent Rate : 91 bpm
PR Interval : 152 ms
QRS Duration: 102 ms
QT/QTc Int : 358/412 ms
P-QRS-T axis: 44.00 • 36.00 • 10.00
Allengers ECG (Piscos)(PIS21519057)

Handwritten signature

Reported By: **DR. NITIZ GOYAL**
MBBS, M.D.

DR. NITIZ GOYAL