



Shubham Imaging & ALC Diagnostic Center

ISO 9001:2015 Certified center

(A Unit of P.K. Arogyam Health & Wellness Center)

E-95, P.C. Colony, Near Sai Netryalaya Transformer, Kankarbagh, Patna - 20

alcdiagnostics@gmail.com

www.pkarogyamhealthcheckup.com

7050037694, 8271206196

OPINION MUST BE CORRELATES WITH CLINICALLY & OTHER INVESTIGATION FOR FINAL DIAGNOSIS. NOT FOR MEDICO LEGAL PURPOSE

Pt. Name :- **MANOJ KUMAR**
Ref. By :- **DR. / MEDIWHEEL**

Date:- **26-Mar-23**
Age / Sex - **36 Yrs. M.**

REAL TIME U.S.G. OF WHOLE ABDOMEN

Thanks for your kind referral

(Report.)

- LIVER** :- Measures 16.60 cm. Mild Enlarged in shape , size and echo texture fatty change Seen in liver parenchyma .I.H.B.R. are not dilated. Hepatic veins are normal. No SOL seen.
- G.BL. :- Lumen is echo free. Wall thickness appears normal.
- C.B.D. :- Measures 3.5 mm in diameter with echo free lumen. No calculi or mass seen.
- P.V. :- Measures 7.7 mm in diameter. Appears normal. No thrombus seen.
- PANCREAS :- Normal in shape, size and echo texture. No calcification mass seen.
- SPLEEN :- Measures 10.76 cm. Normal in shape, size and echo texture. No SOL seen.
- KIDNEY :- Both kidney shows normal shape, size & echotexture. C.M.D.intact. P.C.S.is not dilated.
Right Kidney :- Measures 9.11 X 4.1 cm.
Left Kidney :- Measures 10.13 X 4.3cm.
- URETER :- Not dilated .No apparent calculi seen.
- U.BLADDER:- Shows normal in outline with echo free lumen. No calculi or mass seen.
Pre void – 350 ml. Post void – is in significant
- PROSTATE :- Measures 18 gms.(approx). Appears Normal in size, shape, and echo texture. No calcification , mass ,growth seen. capsule is intact.
- R.I.F. :- Son graphically no appendicular mass or collection seen.
- OTHERS :- No Ascites . no Lymph Adenopathy. No pleural effusion seen on either side .

IMPRESSION

- **Mild Hepatomegaly With Fatty liver G-I**
- **Adv:- Further work up/ other investigation**
Otherwise son graphically normal scan. of rest organs

26/3/23

ESTB BY:-

Dr. P. K. Tiwari
MD, M.Sc (Radio Imaging)
Ph.D (Alt Nuclear Medicine)
Consultant Imagiologist & Sonologist

Dr. S. Kumar
MD (Pat)
Consultant Pathologist

Dr. Abhishek Kumar
MBBS, MD
Consultant Neuropathology Physiologist

Dr. Kumari Suman
MBBS, DGO, MD
Consultant (TVS & HSG Specialist)

Dr. A. K. Singh
MBBS, PGDMCH
Consultant Radiologist & Sonologist

Consultant Radiologist

PRINTING MISTAKE SHOULD BE REPORTED BACK IMMEDIATELY/ यहाँ जन्म से पहले भ्रुण का लिंग जाँच नहीं होता है ।



Shubham Imaging & ALC Diagnostic Center

ISO 9001:2015 Certified center

(A Unit of P.K. Arogyam Health & Wellness Center)

E-95, P.C. Colony, Near Sai Netryalaya Transformer, Kankarbagh, Patna - 20

alcdiagnostics@gmail.com

www.pkarogayamhealthcheckup.com

7050037694, 8271206196

OPINION MUST BE CORRELATES WITH CLINICALLY & OTHER INVESTIGATION FOR FINAL DIAGNOSIS. NOT FOR MEDICO LEGAL PURPOSE

Pt. Name :- MANOJ KUMAR
Ref. By :- DR. / MEDIWHEEL

Date:- 26-Mar-23
Age / Sex - 36 Yrs. M.

Thanks for your kind referral

X-RAYCHEST (P.A.VIEW)

The lungs on the either side show equal translucency.

The peripheral pulmonary vasculature is normal.

No focal lung lesion is seen.

The pleural spaces are normal.

Both hila are normal in size, have equal density and bear normal relationship.

The heart and trachea are central in position and no mediastinal abnormality is visible.

The cardiac size is normal.

The domes of the diaphragms are normal in position, and show smooth outline.

IMPRESSION

- NO EVIDENCE OF PULMONARY OR CARDIAC PATHOLOGY IS NOTED.

[Handwritten signature]
26/3/23

ESTB BY:-

Dr. P. K. Tiwari
MD, M.Sc (Radio Imaging)
Ph.D (Alt Nuclear Medicine)
Consultant Imaginationologist & Sonologist

Dr. S. Kumar
MD (Pat)
Consultant Pathologist

Dr. Abhishek Kumar
MBBS, MD
Consultant Neuropathologist

Dr. Kumari Suman
MBBS, DGO, MD
Consultant (TVS & HSG Specialist)

Dr. A. K. Singh
MBBS, PGDMCH
Consultant Radiologist & Sonologist

Consultant Radiologist

PRINTING MISTAKE SHOULD BE REPORTED BACK IMMEDIATELY/ यहाँ जन्म से पहले भ्रुण का लिंग जाँच नहीं होता है ।



Shubham Imaging & ALC Diagnostic Center

ISO 9001:2015 Certified center
(A Unit of P.K. Arogyam Health & Wellness Center)

F-95, P.C. Colony, Near Sai Netryalaya Transformer, Kankarbagh, Patna - 20


7050037694, 8271204196
www.pkarogyamhealthcheckup.com
OPINION MUST BE CORRELATES WITH CLINICALLY & OTHER INVESTIGATION FOR FINAL DIAGNOSIS. NOT FOR MEDICO LEGAL PURPOSE

PATIENT NAME : MR. MANOJ KUMAR PATIENT ID : 3463
COL DATE : 26/03/2023 REPORTING DATE: 26/03/2023 AGE SEX : 36 YRS/M
REF. BY : DR. / MEDIWHEEL

TEST NAME	RESULT	Unit	REF. RANGE
BLOOD SUGAR (F)	93.0 mg/dl		70 -110 mg/dl

LIPID PROFILE:-

TOTAL CHOLESTROL	215.4 mg/dl		130 -250 mg/dl
TRIGLYCERIDE	179.1 mg/dl		50 -160 mg/dl
HDL CHOLESTROL	49.0 mg/dl		30 - 60 mg/dl
LDL CHOLESTROL	130.6 mg/dl		80 -130 mg/dl
VLDL CHOLESTROL	35.8 mg/dl		15 - 40 mg/dl
T.CH./HDL RATIO	4.3 : 1		Upto 5 : 1
LDL /HDL RATIO	2.6 : 1		2 - 4 : 1


26/03/2023
Consultant Radiologist

ESTD BY:-

DR. P. K. TIWARI MD, M.Sc (Radio Imaging) F.I.D (AI Nuclear Medicine) Consultant Imaging & Sonology
DR. S. KUMAR MD (P) Consultant Pathologist
DR. ABHISHEK KUMAR MBBS, MD Consultant Neuro Patho Physiologist
DR. KUMARI SUMAN MBBS, DGO, MD Consultant (GYN & HSG Specialist)
DR. A. K. SINGH MBBS, PGD&CH Consultant Radiologist Esrologist

PRINTING MISTAKE SHOULD BE REPORTED BACK IMMEDIATELY/ यदि त्रुटि से पहले मुद्रा का निर्यात नहीं होता है ।

Shubham Imaging & ALC Diagnostic Center



diagnoshtic@gmail.com

E-95, P.C. Colony, Near Sai Nehryalaya Transformer, Kanharbagh, Patna - 20

7959007694, 9271206196

(A Unit of P.K. Arogyam Health & Wellness Center)

OPINION MUST BE CORRELATES WITH CLINICALY & OTHER INVESTIGATION FOR FINAL DIAGNOSIS. NOT FOR MEDICO LEGAL PURPOSE

PATIENT NAME : MR. MANOJ KUMAR

PATIENT ID : 3463


COL DATE : 26/03/2023 REPORTING DATE: 26/03/2023 AGE SEX:- 36 YRS./M

REF BY : DR. / MEDIWHEEL .

TEST NAME	RESULT	Unit	REF. RANGE
-----------	--------	------	------------

LFT:-

SGPT	29.0	IU/L	5 - 40 IU/L	
SGOT	21.2	IU/L	5 - 40 IU/L	
ALKALINE PHOSPHATASE	112.0	IU/L	M - 53 - 165 IU/L F - 42 - 136 IU/L	
TOTAL PROTEIN	7.6	g/dl	6.0 - 8.7 g/dl	
SERUM ALBUMIN	4.8	g/dl	3.5 - 5.4 g/dl	
SERUM GLOBULINE	2.8	g/dl	2.3 - 3.6 g/dl	
AG RATIO	1.7 : 1		1.0 - 2.3 g/dl	
BILIRUBIN				
	TOTAL	0.60	mg/dl	0.1 - 1.1 mg/dl
	DIRECT	0.27	mg/dl	0.0 - 0.32 mg/dl
	INDIRECT	0.33	mg/dl	0.0 - 0.78 mg/dl
GGTP(GGT)	28.0	IU/L	8 - 38 IU/L	
KFT/RFT				
URIC ACID	6.1	mg/dl	3.2 - 7.0 mg/dl	
SERUM CREATININE	1.0	mg/dl	0.6 - 1.5 mg/dl	
BLOOD URIA	27.7	mg/dl	5 - 45 mg/dl	
BLOOD URIA NITROZEN(BUN).	12.9	mg/dl	5 - 23 mg/dl	


 26/03/2023
 Consultant Radiologist

ESTD BY:-

DR. P. K. TIWARI MD, M.Sc (Radio Imaging) R.D (All Nuclear Medicine) Consultant Imaging & Sonology
 DR. S. Kumar MBBS, MD Consultant Neuropropho Physiologist
 DR. Abhishhek Kumar MBBS, MD Consultant Neuropropho Physiologist
 DR. Kumari Suman MBBS, DGO, MD Consultant (TNS & HSG Specialist)
 DR. A. K. Singh MBBS, PGDMMCH Consultant Radiologist Esomologist

PRINTING MISTAKE SHOULD BE REPORTED BACK IMMEDIATELY/ यदि त्रुटि का पता चले तो तुरंत सूचना दें !

Shubham Imaging & ALC Diagnostic Center



ISO 9001:2015 Certified Centre
 (A Unit of P.K. Arogyam Health & Wellness Center)
 E-95, P.C. Colony, Near Sai Netryalaya Transformer, Kanharbagh, Patna - 20
 www.pkarogyamhealthcheckup.com
 7050027494, 8271204156
 OPINION MUST BE CORRELATES WITH CLINICALLY & OTHER INVESTIGATION FOR FINAL DIAGNOSIS. NOT FOR MEDICO LEGAL PURPOSE

PATIENT NAME : Mr. MANOJ KUMAR
 COL. DATE : 26/03/2023 REPORTING DATE: 26/03/2023 AGE SEX:- 33 YRS/M
 REF. BY : DR. / MEDIWHEEL.

PATIENT ID: 3463

TEST NAME	RESULT	Unit	REF. RANGE
ESR	18 mm/hr		<20 mm/hr
CBC			
Total W.B.C. Count	6,600 /cumm		4000 - 11,000 /cumm
R B C COUNT	4.17 Million/ Cumm		4 - 7 Million/ Cumm
Platelets count	1.64 Lakh/ cumm		1.5 - 5.0 Lakh/ cumm
Differential Count of W.B.C.			
Neutrophils	62 %		40 - 70%
Lymphocytes	32 %		25 - 40%
Eosinophils	04 %		01 - 05%
Mnocytes	02 %		00 - 08%
Basophiles	00 %		00 - 0 %
HAEMOGLOBIN	13.4 gm/dl (91.7 %)		14.6 gm/dl = 100%
PCV	40.0 %		35 - 47 %
MCV	95.8 fl		76 - 96 fl
MCH	32.1 pg		29 - 35 pg
MCHC	33.5 %		30 - 38 %

ESTD BY-

Consultant Radiologist

Signature
 26/03/2023

Dr. P. K. Tiwari MD, M.S. (Radio Imaging) Consultant Radiologist
 Dr. S. Kumar MD (Path) Consultant Pathologist
 Dr. Abhishek Kumar MBBS, MD Consultant Neurophysio Physiologist
 Dr. Kumari Sumran MBBS, DGO, MD Consultant (Tvs & HSG Specialist)
 Dr. A. K. Singh MBBS, FCIMACH Consultant Radiologist Esomologist

PRINTING MISTAKE SHOULD BE REPORTED BACK IMMEDIATELY/ यदि त्रुटि पाये तो कृपया तुरंत सूचना दें।

Shubham Imaging & ALC Diagnostic Center

ISO 9001:2015 Certified center

(A Unit of P.K. Arogyam Health & Wellness Center)

E-95, P.C. Colony, Near Sai Nethyalaya Transformer, Kankarbagh, Patna - 20

alcdiagnostics@gmail.com

www.pkrogyamhealthcheckup.com

70560027694, 8271206196

OPINION MUST BE CORRELATES WITH CLINICALLY & OTHER INVESTIGATION FOR FINAL DIAGNOSIS. NOT FOR MEDICO LEGAL PURPOSE

PATIENT NAME : MR. MANOJ KUMAR

PATIENT ID : 3463

COL DATE : 26/03/2023

REPORTING DATE: 26/03/2023

AGE SEX : 36 YRS/M

REF. BY : DR./ MEDIWHEEL.

GLYCOSYLATED HEMOGLOBIN

TEST NAME	RESULT	Unit	REF. RANGE
HbA1c	3.7 %		Below 5.7 % : Normal 5.7 - 6.4 % : Prediabetic > = 6.5 % : Diabetic

AVERAGE PLASMA GLUCOSE	96.0 mg/dl		90 - 120 mg/dl : Good Control 121 - 150 mg/dl : Fair Control 151 - 180 mg/dl: Unsatisfactory Control >180 mg/dl : Poor Control
------------------------	------------	--	---

ESTD BY:-

Consultant Radiologist

ABR
26/03/2023

Dr. P. K. Tiwari
MD, M.Sc (Radio Imaging)
Ph.D (All Nuclear Medicine)
Consultant Imagingologist & Sonologist

Dr. S. Kumar
MD (Path)
Consultant Pathologist

Dr. Abhishek Kumar
MBBS, MD
Consultant Neuropatho Physiologist

Dr. Kumari Suman
MBBS, DCO, MD
Consultant (TUS & HSC specialist)

Dr. A. K. Singh
MBBS, PGDMMCH
Consultant Radiologist esonologist

Shubham Imaging & ALC Diagnostic Center



ISO 9001:2015 Certified center

(A Unit of P.K. Arogyam Health & Wellness Center)

E-95, P.C. Colony, Near Sai Netryalaya Transformer, Kankarbagh, Patna - 20

7050037694, 8271206190

OPINION MUST BE CORRELATES WITH CLINICALITY & OTHER INVESTIGATION FOR FINAL DIAGNOSIS. NOT FOR MEDICO LEGAL PURPOSE

PATIENT NAME : MR. MANOJ KUMAR

PATIENT ID: 3463

COL DATE : 26/03/2023

REPORTING DATE: 26/03/2023

AGE SEX : 36 YRS/M

REF BY : DR. / MEDIWHEEL.

TEST NAME	RESULT	Unit	REF RANGE
-----------	--------	------	-----------

BLOOD GROUP : ' B '

Rh Typing : POSITIVE

Note: Do always cross – matching before blood transfusion

ESTD BY:

Dr. P. K. TIWARI
MD, M.Sc (Radio Imaging)
F.I.D (AI) Nuclear Medicine
Consultant Imaging & Sonologist

Dr. S. Kumar
MD (PND)
Consultant Radiologist

Dr. Abhishek Kumar
MBBS, MD
Consultant Neurophysio Physiologist

Dr. Kumari Surman
MBBS, DGO, MD
Consultant (TVS & HSG Specialist)

Dr. A. K. Singh
MBBS, PGDMCH
Consultant Radiologist Esomologist

Consultant Radiologist

PRINTING MISTAKE SHOULD BE REPORTED BACK IMMEDIATELY

Investigation	Result	Normal Range
Total Triiodothyronin T3	1.29 ng/ml	0.80 - 2.00 µ ng/ml
Total Thyroxin T4	7.56 ug/ml	5.10 - 14.10 ug/dl
Serum TSH	3.80 µg/ml	0.27 - 4.20 µg/ml

THYROID DISORDER (-): Increase: < Decrease: n Normal

1. T3(n) T4(n) TSH(n) : EUTHYROID STATE:
2. T3(>) T4(>) TSH(<): HYPERTHYROIDISM:
3. T3(<) T4(<) TSH(>): HYPOTHYROIDISM:
4. T3(n) T4(n) TSH(>) : SUB-CLINICAL HYPO-THYROIDISM:
5. T3(n) T4(n) TSH(<): SUB-CLINICAL HYPER-THYROIDISM:
6. T3(>) T4(n) TSH(<): T3 THYROTOXICOSIS:

Total T3/T4 level is dependent on level:

So determination of free T3/T4 is a better MARKER of Thyroid Function.

*FREE T3/T4 ESTIMATION FACILITY IS AVAILABALE ON REQUEST.:

ESTD BY:-

DR. P. K. TIWARI MD, M.Sc (Radio Imaging) Ri, D (All Nuclear Medicine) Consultant Imagingologist & Sonologist
 DR. S. KUMAR MD (Gen) Consultant Pathologist
 DR. ABHISHIK KUMAR MBS, MD Consultant Neurophysio Physiologist
 DR. KUMARI SUMAN MBS, DGO, MD Consultant (TNS & HSG Specialist)
 DR. A. K. SINGH MBS, PDDMCH Consultant Radiologist esonologist

AP
 26/03/2023
 Consultant Radiologist

PRINTING MISTAKE SHOULD BE REPORTED BACK IMMEDIATELY/ यदि जन्म से पहले गुण का निग नही होता है ।

Shubham Imaging & ALC Diagnostic Center

ISO 9001:2015 Certified center

(A Unit of P. K. Arogyam Health & Wellness Center)

E-95, P.C. Colony, Near Sai Nehruya Transform, Kankarbagh, Patna - 20

radiology@shubhamimaging.com

www.pkrogyamhealthcheckup.com

20500097694, 8271206194

OPINION MUST BE CORRELATES WITH CLINICALITY & OTHER INVESTIGATION FOR FINAL DIAGNOSIS. NOT FOR MEDICO LEGAL PURPOSE

PATIENT NAME : Mr. MANOJ KUMAR

PATIENT ID: 3463

COL DATE

: 26/03/2023

REPORTING DATE: 26/03/2023

AGE SEX : 36 YRS/M

REF. BY

: DR. / MEDIWHEEL..

ROUTINE EXAMINATION OF URINE

PHYSICAL EXAMINATION

Quantity	40 ml	Colour....	Strow
Appearance...	Clear	Sediment ...	Nil
Specific gravity....	1.010		

CHEMICAL EXAMINATION

Reaction	6.0	Nitrite.....	Not done
Sugar	Nil	Bile Pigment ...	Not done
Albumin	Nil	Urobilinogen....	Not done
Excess of Phosphate....	Nil	Chile.....	Not done
Bile Salt	Not Done	Acetone...	Not done

MICROSCOPIC EXAMINATION

Erythrocytes....	Nil	Casts	Nil
Leucocytes	1-5 / HPE	Crystals....	Nil
Epith. Cell	A, Few	Others	Nil

EST/89/-

Consultant Radiologist

Dr. P. K. TIWARI
MD, M.Sc. (Radio Imaging)
Ph.D. (Adv. Nuclear Medicine)
Consultant Radiologist & Sonologist

Dr. S. Kumar
MD (Part)
Consultant Radiologist

Dr. Abhishek Kumar
MBBS, MD
Consultant Neuropatho Physiologist

Dr. Kumari Suman
MBBS, DGO, MD
Consultant (TNS & HSG Specialist)

Dr. A. K. Singh
MBBS, FRCRCH
Consultant Radiologist Esomologist

PRINTING MISTAKE SHOULD BE REPORTED BACK IMMEDIATELY/ यदि त्रुटि का पता चले तो तुरंत सूचना दें ।

ID: 3463
AGE: 36 Y M D
Cms 74 kg

CASE: MANOJ KUMAR

26/03/2023 10:57:17
ALC ADVANCE IMAGING DIAGNOSTICS
E95 PC COLONY KANKARBAGH PATNA

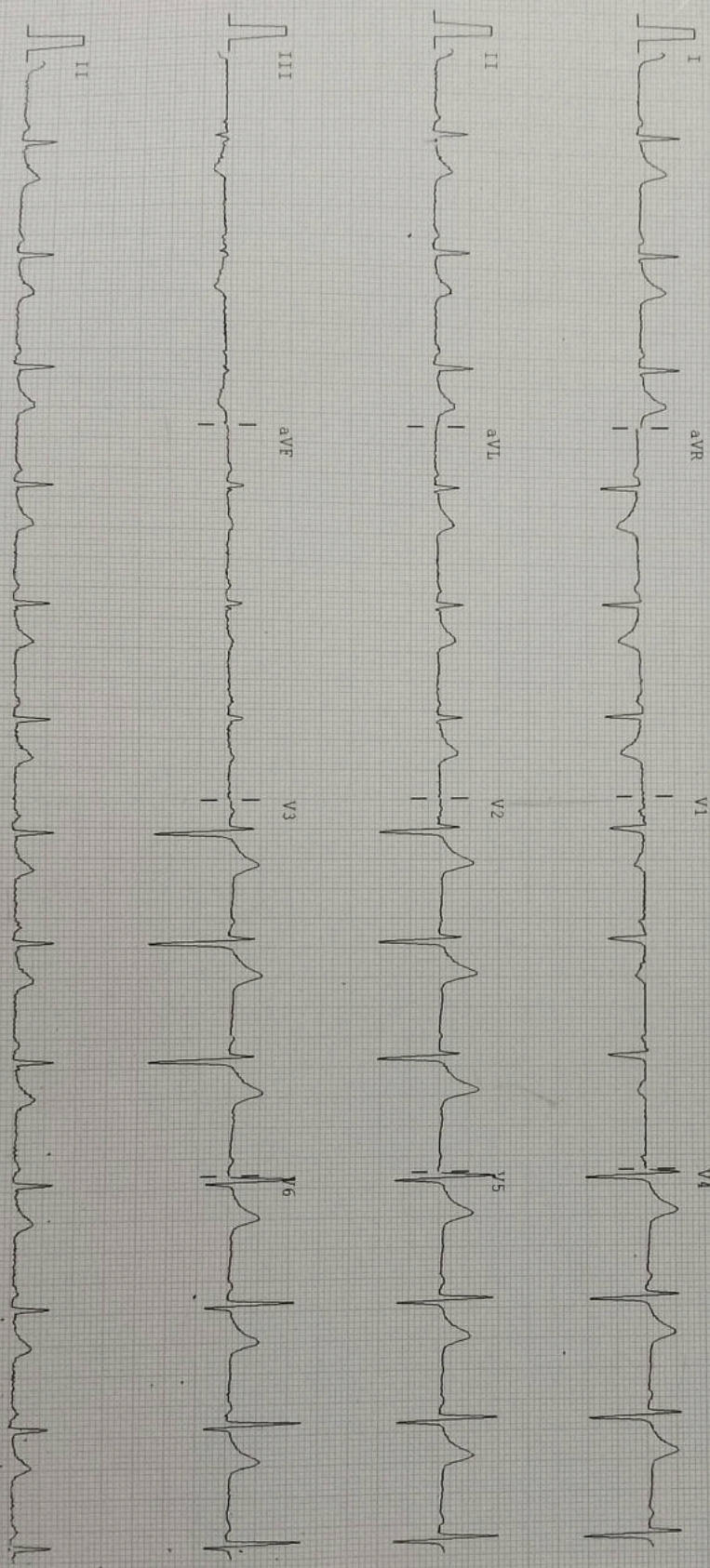
RATE : 76 bpm
R-R : 782 ms
P-R : 128 ms
QRS : 80 ms
QT : 356 ms
QTc : 394 ms

--AXIS--
P : 29°
QRS : 29°
T : 12°

12 SL: REPORT FORMAT: 3x4+1L SQ

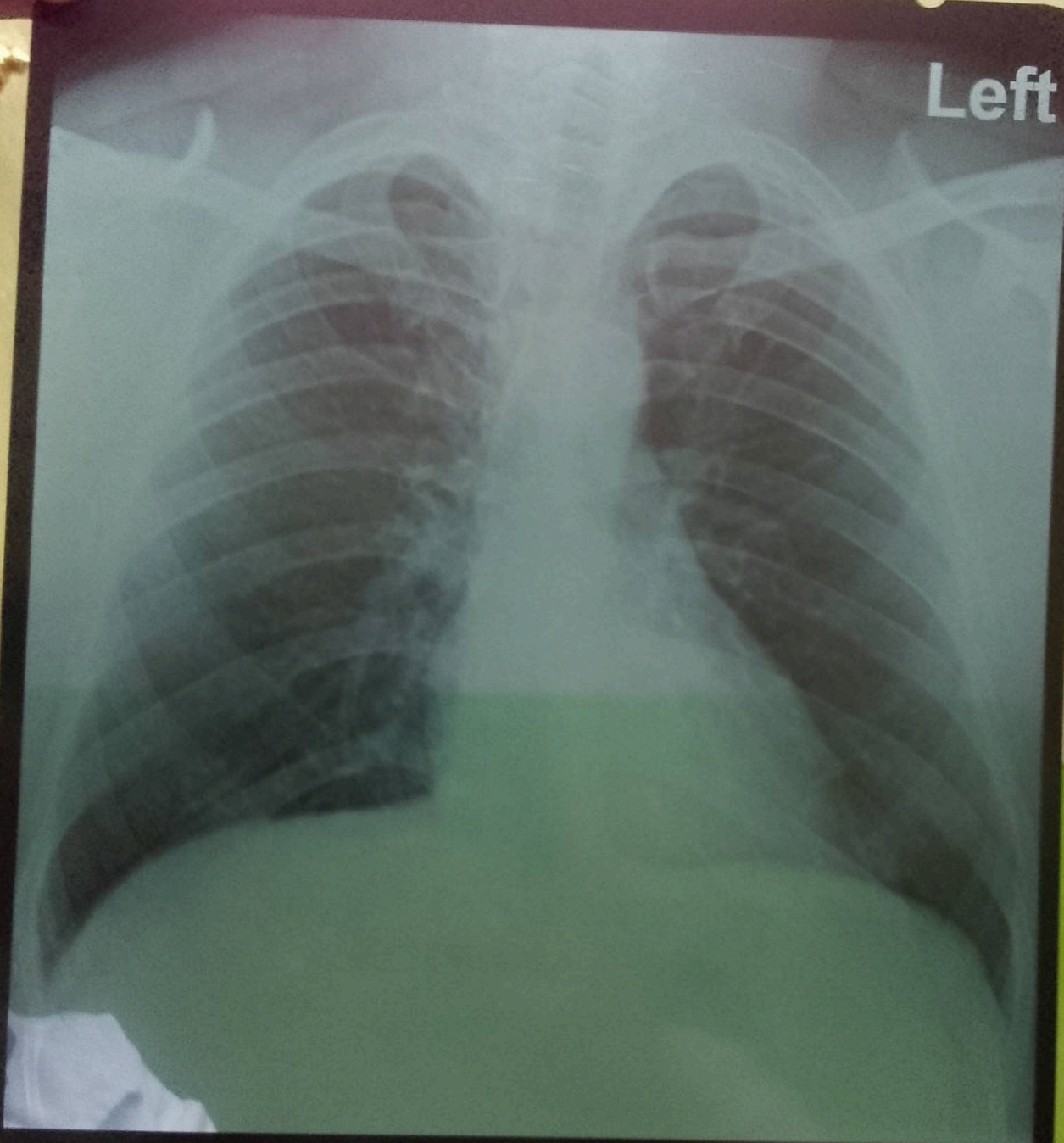
REF: DR MEDH WHEEL

Dr. DR ABHISHEK KUMAR MD



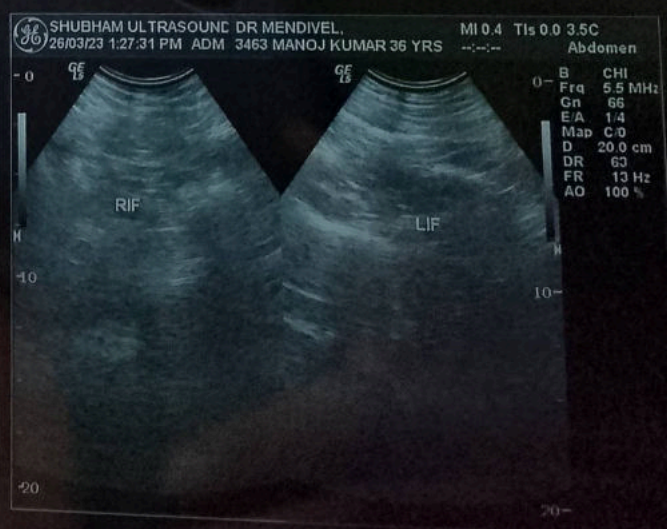
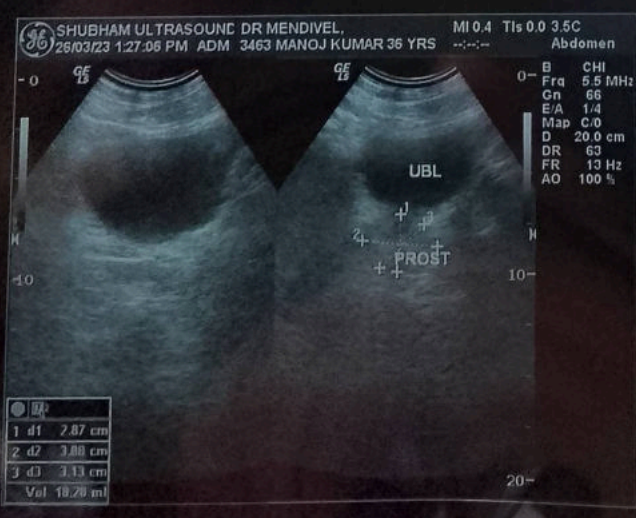
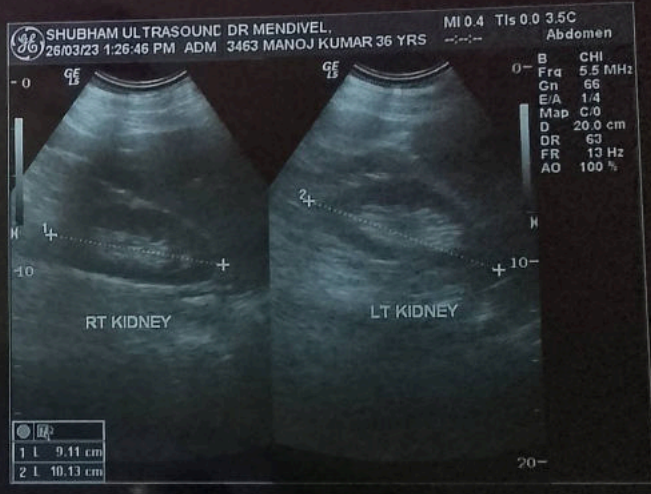
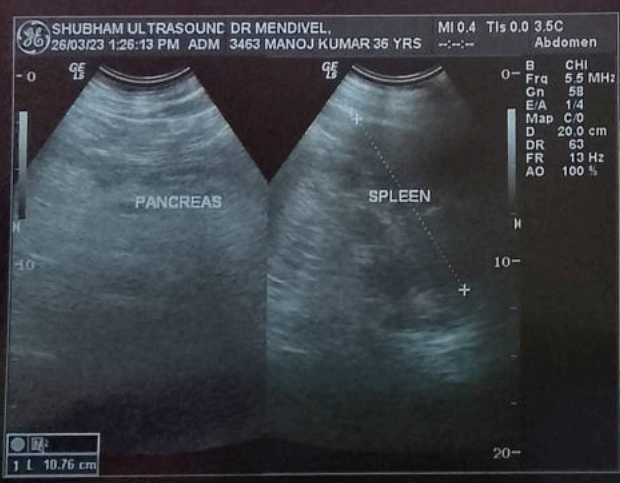
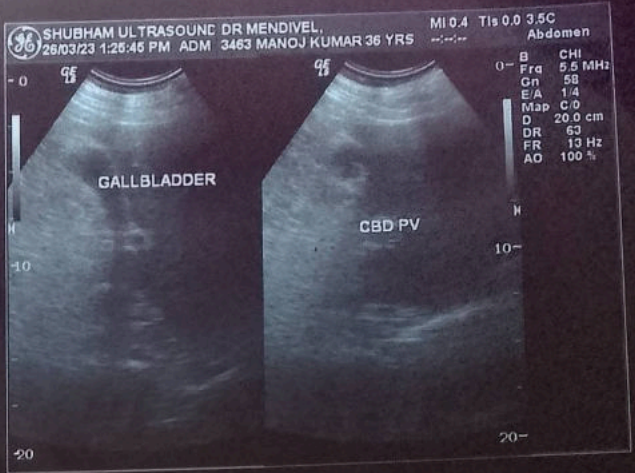
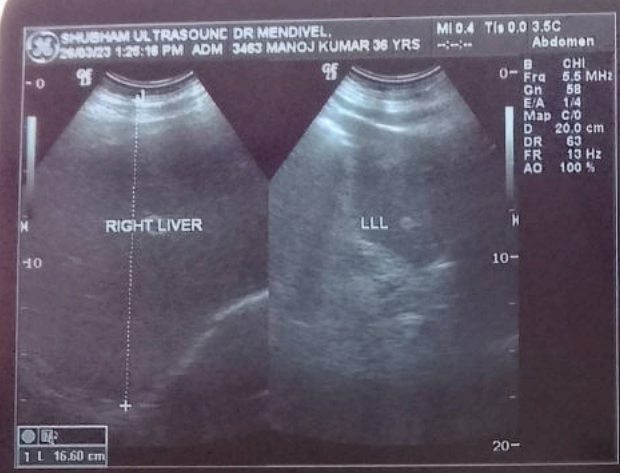25mm/sec 10mm/mV Notch: ON BLC: ON 0.05-35Hz
ALLENGERS PISCES 1012(VER: 1.8) CLINICALLY CORRELATE THE FINDINGS.

Left



MANOJ KUMAR AGE 36 YEARS 3463 BY DR. MEDIWHEEL CHEST,FRN P->A 24-Mar-23

A.L.C. Advance Imaging Diagnostics Centre PATNA - 20



A. L. C. Ad Imaging Dignostics Centre PATNA-20