



Shubham Imaging & ALC Diagnostic Center

ISO 9001:2015 Certified center

(A Unit of P.K. Arogyam Health & Wellness Center)

E-95, P.C. Colony, Near Sai Netryalaya Transformer, Kankarbagh, Patna - 20

alcdiagnostics@gmail.com

www.pkarogyamhealthcheckup.com

7050037694, 8271206196

OPINION MUST BE CORRELATES WITH CLINICALLY & OTHER INVESTIGATION FOR FINAL DIAGNOSIS. NOT FOR MEDICO LEGAL PURPOSE

PATIENT NAME : KUMAR JITENDRA


PATIENT ID: 179

COL DATE : 25/02/2023 REPORTING DATE: 25/02/2023 AGE SEX : 26 YRS/M

REF.BY : DR./ MEDIWHEEL.

GLYCOSYLATED HEMOGLOBIN

TEST NAME	RESULT	Unit	REF.RANGE
HbA1c	3.7 %		Below 5.7 % : Normal 5.7 – 6.4 % : Prediabetic > = 6.5 % : Diabetic
AVERAGE PLASMA GLUCOSE	90.0 mg/dl		90 – 120 mg/dl : Good Control 121– 150 mg/dl : Fair Control 151- 180 mg/dl: Unsatisfactory Control >180 mg/dl : Poor Control


25/02/23
Consultant Radiologist

ESTB BY:-

Dr. P. K. Tiwari
MD, M.Sc (Radio Imaging)
Ph.D (Alt Nuclear Medicine)
Consultant Imacionologist & Sonologist

Dr. S. Kumar
MD (Pat)
Consultant Pathologist

Dr. Abhishek Kumar
MBBS, MD
Consultant Neuropatho Physiologist

Dr. Kumari Suman
MBBS, DGO, MD
Consultant (TVS & HSG Specialist)

Dr. A. K. Singh
MBBS, PGDMCH
Consultant Radiologist & Sonologist

PRINTING MISTAKE SHOULD BE REPORTED BACK IMMEDIATELY/ यहाँ जन्म से पहले भ्रुण का लिंग जाँच नहीं होता है ।

Shubham Imaging & ALC Diagnostic Center

ISO 9001:2015 Certified center

(A Unit of P.K. Arogyam Health & Wellness Center)

E-95, P.C. Colony, Near Sai Netryalaya Transformer, Kankarbagh, Patna - 20

alcdiagnostics@gmail.com

www.pkarogyamhealthcheckup.com

7050037694, 8271206196

OPINION MUST BE CORRELATES WITH CLINICALLY & OTHER INVESTIGATION FOR FINAL DIAGNOSIS. NOT FOR MEDICO LEGAL PURPOSE

PATIENT NAME : KUMAR JITENDRA

PATIENT ID: 179


COL DATE : 25/02/2023 REPORTING DATE: 25/02/2023 AGE SEX : 26 YRS/M

REF.BY : DR. /MEDIWHEEL.

TEST NAME	RESULT	Unit	REF.RANGE
BLOOD SUGAR (F)	69.0 mg/dl		70 - 110 mg/dl
BLOOD SUGAR (PP)	100.0 mg/dl		70 - 140 mg/dl

LIPID PROFILE:-

TOTAL CHOLESTROL	198.0 mg/dl		130 -250 mg/dl
TRIGLYCERIDE	130.4 mg/dl		50 -160 mg/dl
HDL CHOLESTROL	46.0 mg/dl		30 - 60 mg/dl
LDL CHOLESTROL	126.0 mg/dl		80 -130 mg/dl
VLDL CHOLESTROL	26.0 mg/dl		15 - 40 mg/dl
T.CH./HDL RATIO	4.3 :1		Upto 5:1
LDL./HDL RATIO	2.7 :1		2 - 4:1



Consultant Radiologist

ESTB BY:-

Dr. P. K. Tiwari
MD, M.Sc (Radio Imaging)
Ph.D (Ali Nuclear Medicine)
Consultant Imagonologist & Sonologist

Dr. S. Kumar
MD (Pat)
Consultant Pathologist

Dr. Abhishek Kumar
MBBS, MD
Consultant Neuropatho Physiologist

Dr. Kumari Suman
MBBS, DGO, MD
Consultant (TVS & HSG Specialist)

Dr. A. K. Singh
MBBS, PGDMCH
Consultant Radiologist & Sonologist

PRINTING MISTAKE SHOULD BE REPORTED BACK IMMEDIATELY/ यहाँ जन्म से पहले भ्रुण का लिंग जाँच नहीं होता है ।

Shubham Imaging & ALC Diagnostic Center

ISO 9001:2015 Certified center

(A Unit of P.K. Arogyam Health & Wellness Center)

E-95, P.C. Colony, Near Sai Netryalaya Transformer, Kankarbagh, Patna - 20

alcdiagnostics@gmail.com

www.pkarogayamhealthcheckup.com

7050037694, 8271206196

OPINION MUST BE CORRELATES WITH CLINICALLY & OTHER INVESTIGATION FOR FINAL DIAGNOSIS. NOT FOR MEDICO LEGAL PURPOSE

PATIENT NAME : KUMAR JITENDRA

PATIENT ID: 179

COL DATE : 25/02/2023 REPORTING DATE: 25/02/2023 AGE SEX:- 26 YRS/M


REF.BY : DR. / MEDIWHEEL.

TEST NAME	RESULT	Unit	REF.RANGE
-----------	--------	------	-----------

BLOOD GROUP	:	' AB '	
-------------	---	--------	--

Rh Typing	:	NEGATIVE	
-----------	---	----------	--

Note: Do always cross – matching before blood transfusion



Consultant Radiologist

ESTB BY:-

Dr. P. K. Tiwari
MD, M.Sc (Radio Imaging)
Ph.D (Alb Nuclear Medicine)
Consultant Imagonologist & Sonologist

Dr. S. Kumar
MD (Pat)
Consultant Pathologist

Dr. Abhishek Kumar
MBBS, MD
Consultant Neuropatho Physiologist

Dr. Kumari Suman
MBBS, DGO, MD
Consultant (TVS & HSG Specialist)

Dr. A. K. Singh
MBBS, PGDMCH
Consultant Radiologist & Sonologist

PRINTING MISTAKE SHOULD BE REPORTED BACK IMMEDIATELY/ यहाँ जन्म से पहले भुण का लिंग जाँच नहीं होता है ।

Shubham Imaging & ALC Diagnostic Center

ISO 9001:2015 Certified center

(A Unit of P.K. Arogyam Health & Wellness Center)

E-95, P.C. Colony, Near Sai Netryalaya Transformer, Kankarbagh, Patna - 20

alcdiagnostics@gmail.com

www.pkrogyamhealthcheckup.com

7050037694, 8271206196

OPINION MUST BE CORRELATES WITH CLINICALLY & OTHER INVESTIGATION FOR FINAL DIAGNOSIS. NOT FOR MEDICO LEGAL PURPOSE

PATIENT NAME : KUMAR JITENDRA

PATIENT ID: 179

COL DATE : 25/02/2023 REPORTING DATE: 25/02/2023 AGE SEX:- 26 YRS/M

REF.BY : DR. / MEDIWHEEL.

TEST NAME	RESULT	Unit	REF.RANGE
ESR	15 mm/hr		<20 mm/hr
CBC			
Total W.B.C. Count	10,300 /cumm		4,000-11,000 /cumm
R B C COUNT	5.24 Million/ CUmm		4 - 7 Million/ CUmm
Platelets count	1.94 Lakh/ cumm		1.5-5.0 Lakh/ cumm
Differential Count of W.B.C.			
Neutrophils	63 %		40-70%
Lymphocytes	30 %		25-40%
Eosinophils	05 %		01-05%
Mnonocytes	02 %		00-02%
Basophiles	00 %		00 -0%
HAEMOGLOBIN	16.1 gm/dl (110.2 %)		14.6 gm/dl = 100%
PCV	48.8 %		35-47 %
MCV	89.4 fl		76-96 fl
MCH	31.6 pg		29-35 pg
MCHC	35.7 %		30-38 %

1
OR
25/2/23

Consultant Radiologist

ESTB BY:-

Dr. P. K. Tiwari
MD, M.Sc (Radio Imaging)
Ph.D (Alf Nuclear Medicine)
Consultant Imagiologist & Sonologist

Dr. S. Kumar
MD (Pat)
Consultant Pathologist

Dr. Abhishek Kumar
MBBS, MD
Consultant Neuropatho Physiologist

Dr. Kumari Suman
MBBS, DGO, MD
Consultant (TVS & HSG Specialist)

Dr. A. K. Singh
MBBS, PGDMCH
Consultant Radiologist & Sonologist

PRINTING MISTAKE SHOULD BE REPORTED BACK IMMEDIATELY/ यहाँ जन्म से पहले भुण का लिंग जाँच नहीं होता है ।

Shubham Imaging & ALC Diagnostic Center

ISO 9001:2015 Certified center

(A Unit of P.K. Arogyam Health & Wellness Center)

E-95, P.C. Colony, Near Sai Netryalaya Transformer, Kankarbagh, Patna - 20

alcdiagnostics@gmail.com

www.pkarogyamhealthcheckup.com

7050037694, 8271206196

OPINION MUST BE CORRELATES WITH CLINICALLY & OTHER INVESTIGATION FOR FINAL DIAGNOSIS. NOT FOR MEDICO LEGAL PURPOSE


PATIENT NAME : KUMAR JITENDRA

PATIENT ID: 179

COL DATE : 25/02/2023 REPORTING DATE: 25/02/2023 AGE SEX:- 26 YRS/M

REF.BY : DR. / MEDIWHEEL.

TEST NAME	RESULT	Unit	REF.RANGE
LFT:-			
SGPT	35.2	IU/L	5 - 48 IU/L
S G O T	22.7	IU/L	5 - 40 IU/L
ALKALINE PHOSPHATASE	91.1	IU/L	25 - 147 IU/L
TOTAL PROTIN	7.8	g/dl	6.0 - 8.7 g/dl
SERUM ALBUMIN	4.7	g/dl	3.5 - 5.4 g/dl
SERIUM GLUBLINE	3.1	g/dl	2.3 - 3.6 g/dl
AG RATIO	1.5 : 1		1.0 - 2.3 g/dl
BILIRUBIN			
TOTAL	0.61	mg/dl	0.1 - 1.1 mg/dl
IRECT	0.20	mg/dl	0.0 - 0.32 mg/dl
INDIRECT	0.41	mg/dl	0.0 - 0.78 mg/dl
GGTP (GGT)	26.2	iu/L	8 - 38 iu/L
KFT/RFT			
URIC ACID	4.8	mg/dl	3.2 - 7.0 mg/dl
SERUM CREATNINE	1.0	mg/dl	0.6 - 1.5 mg/dl
BLOOD URIA	32.0	mg/dl	5 - 45 mg/dl
BLOOD URIA NITROZEN(BUN).	14.9	mg/dl	5 - 24 mg/dl



Consultant Radiologist

ESTB BY:-

Dr. P. K. Tiwari
MD, M.Sc (Radio Imaging)
Ph.D (Alt Nuclear Medicine)
Consultant Imajonologist & Sonologist

Dr. S. Kumar
MD (Pat)
Consultant Pathologist

Dr. Abhishek Kumar
MBBS, MD
Consultant Neuropatho Physiologist

Dr. Kumari Suman
MBBS, DGO, MD
Consultant (TVS & HSG Specialist)

Dr. A. K. Singh
MBBS, PGDMCH
Consultant Radiologist & Sonologist

PRINTING MISTAKE SHOULD BE REPORTED BACK IMMEDIATELY/ यहाँ जन्म से पहले भ्रुण का लिंग जाँच नहीं होता है ।

Shubham Imaging & ALC Diagnostic Center

ISO 9001:2015 Certified center

(A Unit of P.K. Arogyam Health & Wellness Center)

E-95, P.C. Colony, Near Sai Netryalaya Transformer, Kankarbagh, Patna - 20

alcdiagnostics@gmail.com

www.pkarogayamhealthcheckup.com

7050037694, 8271206196

OPINION MUST BE CORRELATES WITH CLINICALLY & OTHER INVESTIGATION FOR FINAL DIAGNOSIS. NOT FOR MEDICO LEGAL PURPOSE

PATIENT NAME : KUMAR JITENDRA PATIENT ID: 179
COL DATE : 25/02/2023 REPORTING DATE: 25/02/2023 AGE SEX : 26 YRS/M
REF.BY : DR. / MEDIWHEEL..


TEST NAME	RESULT	Unit	REF.RANGE
Total Triiodothyronin T3	1.16	ng/mL	0.80 -2.00 ng/mL
Total Thyroxin T4	7.51	µg/dL	5.10 -14.10 µg/dL
Serum TSH	1.08	µIU/mL	0.27 – 4.20 µIU/mL

THYROID DISORDER (>: Increase: < Decrease: n Normal

1. T3(n) T4(n) TSH(n) :EUTHYROID STATE:
2. T3(>) T4(>) TSH(<): HYPERTHYROIDISM:
3. T3(<)T4(<) TSH(>): HYPOTHYROIDISM:
4. T3(n)T4(n) TSH(>) : SUB-CLINICAL HYPO-THYROIDISM:
5. T3(n)T4(n) TSH(<): SUB-CLINICAL HYPER-THYROIDISM:
6. T3(>) T4(n) TSH(<): T3 THYROTOXICOSIS:

Total T3/T4 level is dependent on Level:

So determination of free T3/T4is a better MARKER of Thyroid Function.


25/02/23

Consultant Radiologist

ESTB BY:-

Dr. P. K. Tiwari
MD, M.Sc (Radio Imaging)
Ph.D (Alt Nuclear Medicine)
Consultant Imagonologist & Sonologist

Dr. S. Kumar
MD (Pat)
Consultant Pathologist

Dr. Abhishek Kumar
MBBS, MD
Consultant Neuropatho Physiologist

Dr. Kumari Suman
MBBS, DGO, MD
Consultant (TVS & HSG Specialist)

Dr. A. K. Singh
MBBS, PGDMCH
Consultant Radiologist & Sonologist

PRINTING MISTAKE SHOULD BE REPORTED BACK IMMEDIATELY/यहाँ जन्म से पहले भ्रुण का लिंग जाँच नहीं होता है ।

Shubham Imaging & ALC Diagnostic Center

ISO 9001:2015 Certified center

(A Unit of P.K. Arogyam Health & Wellness Center)

E-95, P.C. Colony, Near Sai Netryalaya Transformer, Kankarbagh, Patna - 20

alcdiagnostics@gmail.com

www.pkarogyamhealthcheckup.com

7050037694, 8271206196

OPINION MUST BE CORRELATES WITH CLINICALLY & OTHER INVESTIGATION FOR FINAL DIAGNOSIS. NOT FOR MEDICO LEGAL PURPOSE

PATIENT NAME : KUMAR JITENDRA

PATIENT ID: 189

COL DATE : 25/02/2023 REPORTING DATE: 25/02/2023 AGE SEX:- 26 YRS/M

REF.BY : DR. /MEDIWHEEL.

ROUTINE EXAMINATION OF URINE

PHYSICAL EXAMINATION

Quantity	40 ml	Colour... .	Straw
Appearance...	Clear	Sediment ...	Nil
Specific gravity....	1.010		

CHEMICAL EXAMINATION

Reaction	6.0	Nitrite.....	Not done
Sugar	Nil	Bile Pigment	Not done
Albumin	Nil	Urobilinogen....	Not done
Excess of Phosphate....	Nil	Chile.....	Not done
Bile Salt	Not Done	Acetone...	Not done

MICROSCOPIC EXAMINATION

Erythrocytes....	Nil	Casts	Nil
Leucocytes	1-4 / HPE	Crystals....	Nil
Epith. Cell	A, Few	Others	Nil

Consultant Radiologist

ESTB BY:-


Dr. P. K. Tiwari
MD, M.Sc (Radio Imaging)
Ph.D (All Nuclear Medicine)
Consultant Imaginationist & Sonologist

Dr. S. Kumar
MD (Pat)
Consultant Pathologist

Dr. Abhishek Kumar
MBBS, MD
Consultant Neuropathology Physiologist

Dr. Kumari Suman
MBBS, DGO, MD
Consultant (TVS & HSG Specialist)

Dr. A. K. Singh
MBBS, PGDMCH
Consultant Radiologist & Sonologist


25/02/23

PRINTING MISTAKE SHOULD BE REPORTED BACK IMMEDIATELY/ यहाँ जन्म से पहले भ्रुण का लिंग जाँच नहीं होता है ।

ID: 179 CASE: AGE: 26Y 0M 0D Cms 50Kg

CR JITENDRA MALE

25/02/2023 10:45:02
ALC ADVANCE IMAGING DIAGNOSTICS
E95 PC COLONY KANKARBAGH PATNA

RATE : 46 bpm SINUS BRADYCARDIA WITH SINUS ARRHYTHMIA
P-R : 1291 ms LEAD(S) UNSUITABLE FOR ANALYSIS: V1
P-R : 142 ms
QRS : 72 ms
QT : 432 ms
QTc : 408 ms

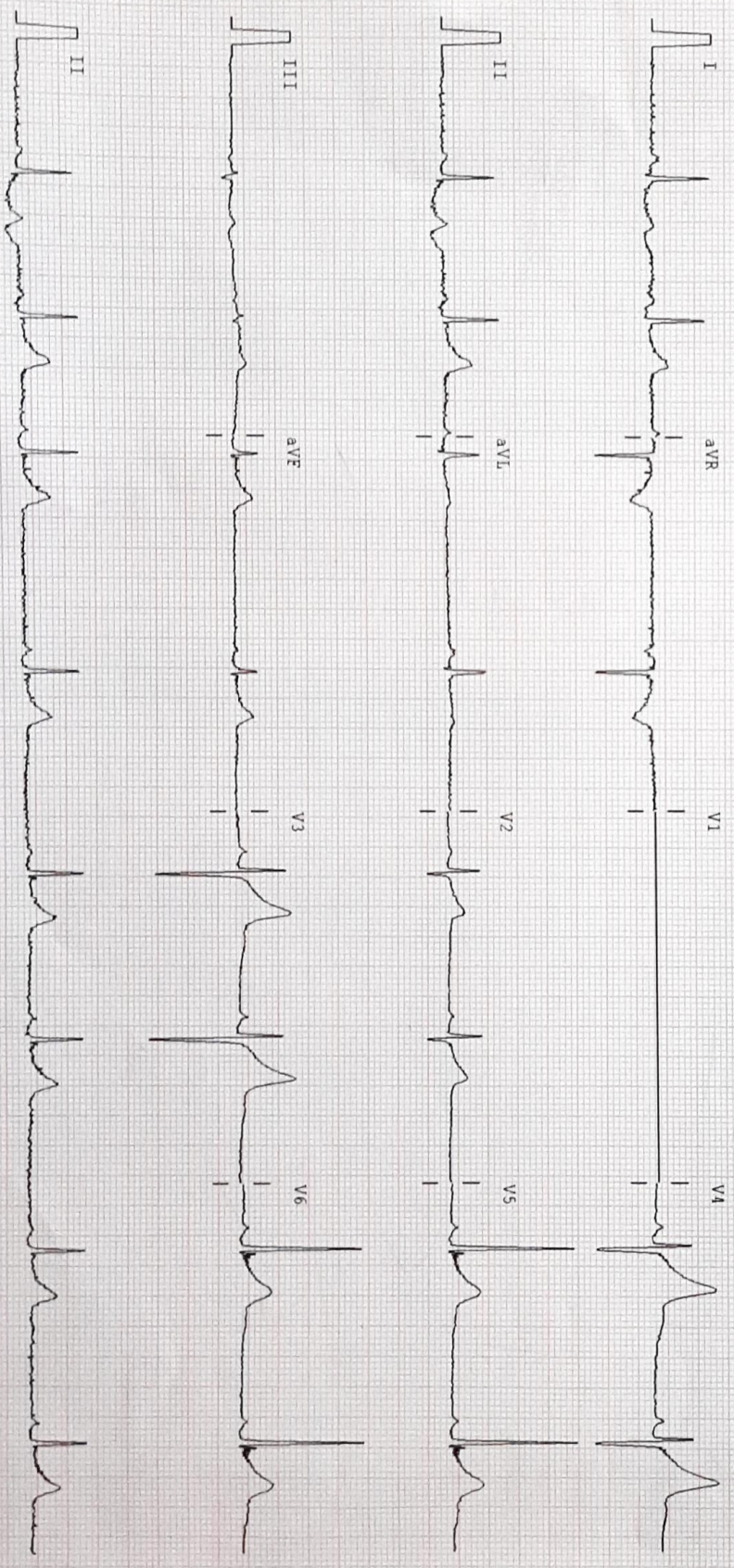
A

--AXIS--
P : 13°
QRS : 28°
T : 54°

12 SL: REPORT FORMAT: 3x4+1L SQ

REF: DR MEDIWHEEL

D: DR ABHISHEK KUMAR MD



A.L.C. ADVANCE IMAGING DIGNOSTICS
E-95, PC COLONY KANKARBAGH PATNA-20



Report

4089 / MR. JITENDRA KUMAR / 26 Yrs / M / 162 Cms / 50 Kg Date: 25-Feb-2023 Technician : MR ARUN

Stage	Time	Duration	Belt Speed (mph)	Elevation	METs	Rate	% THR Achieved	BP	RPP	PVC	Comments
Supine	00:20	0:01	00.0	00.0	01.0	95	49 %	120/80	114	00	
Standing	00:35	0:01	00.0	00.0	01.0	76	39 %	120/80	091	00	
HV	00:49	0:01	00.0	00.0	01.0	075	39 %	120/80	090	00	
Warm Up	01:20	0:01	01.0	00.0	01.0	073	38 %	120/80	087	00	
ExStart	02:03	0:08	01.7	10.0	01.2	104	54 %	120/80	124	00	
BRUCE Stage 1	05:03	3:00	01.7	10.0	04.7	117	60 %	125/85	146	00	
BRUCE Stage 2	08:03	3:00	02.5	12.0	07.1	126	65 %	130/90	163	00	
BRUCE Stage 3	11:03	3:00	03.4	14.0	10.2	140	72 %	130/90	182	00	
PeakEx	11:27	0:25	04.2	16.0	10.7	152	78 %	130/90	197	00	
Recovery	11:56	0:30	00.0	00.0	07.2	118	61 %	130/90	153	00	
Recovery	13:26	2:00	00.0	00.0	01.0	093	48 %	120/80	111	00	
Recovery	14:58	3:32	00.0	00.0	01.0	088	45 %	120/80	105	00	

Findings :

Exercise Time : 09:25
 Max HR Attained : 152 bpm 78% of Target 194
 Max BP Attained : (Sys) 130/90
 Max Workload Attained : 10.7 Good response to induced stress
 Max ST Dep Lead & Value : II & -2.7 mm in PeakEx mm
 Test End Reasons : Test Complete, Test Complete

Report :

(06&c1318072a)(9)AMangers

Doctor : ALC DIAGNOSTIC



ALL.C. ADVANCE IMAGING DIGNOSTICS

4089 / MR. JITENDRA KUMAR / 26 Yrs / M / 162 Cms / 50 Kg / HR : 95

Supine

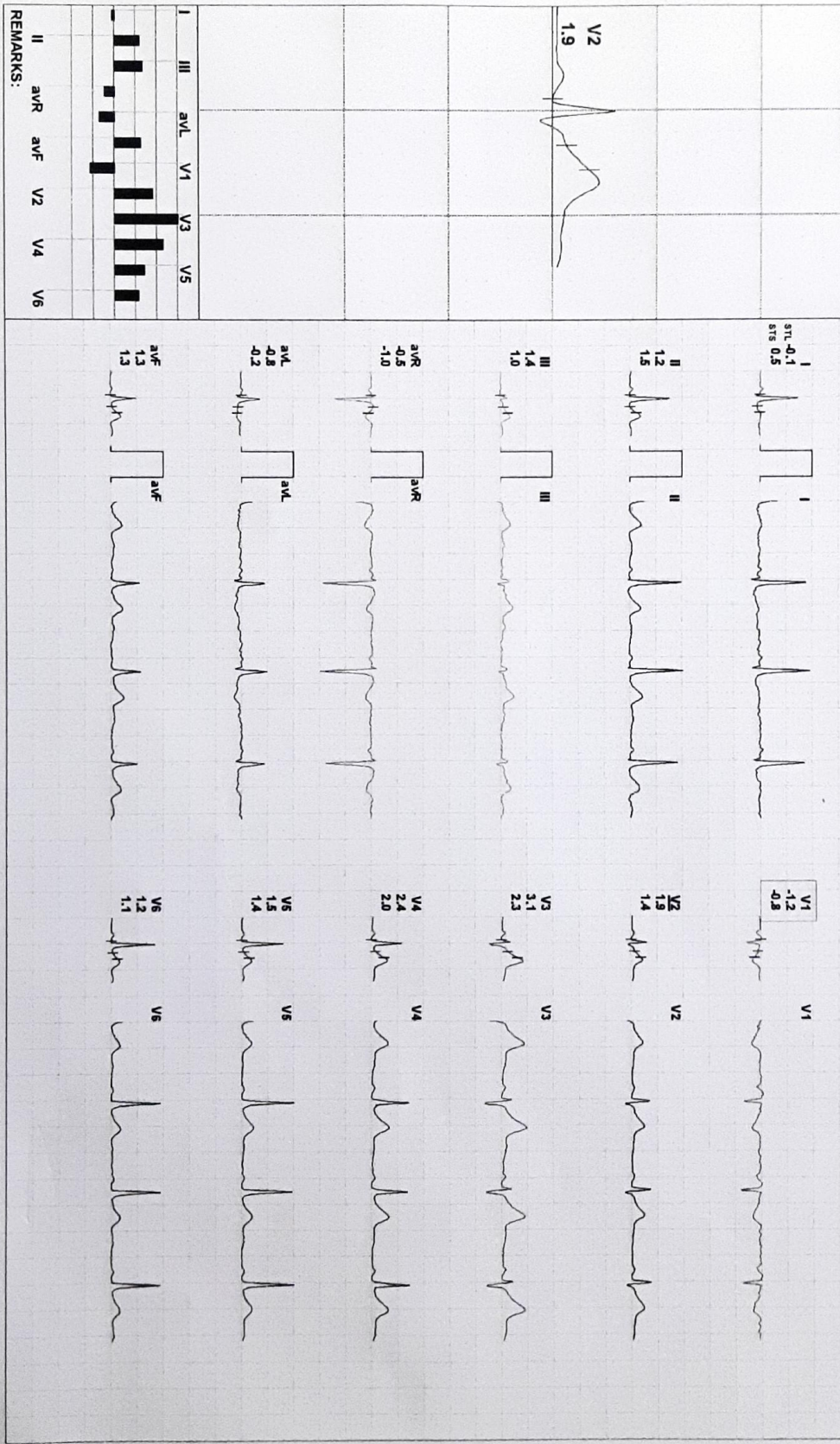


Date: 25-Feb-2023 02:43:43 PM MEETS: 1.0/ 95 bpm 48% of THR BP: 120/80 mmHg Raw ECG/ BLC ON/ Notch ON/ HF: 0.05 Hz/LF: 20 Hz

ExTime: 00:21 0.0 mph 0.0%

4X 80 ms Post J

26 mm/Sec. 1.0 Cm/mV



REMARKS:

(GEM213180726)(R)Allengers

A.L.C. ADVANCE IMAGING DIGNOSTICS

4089 / MR. JITENDRA KUMAR / 26 Yrs / M / 162 Cms / 50 Kg / HR : 76


Standing



Date: 25-Feb-2023 02:43:43 PM METS: 1.0/ 76 bpm 39% of THR BP: 120/80 mmHg Raw ECG BLC ON/ Notch ON/ HF 0.05 Hz/LF 20 Hz

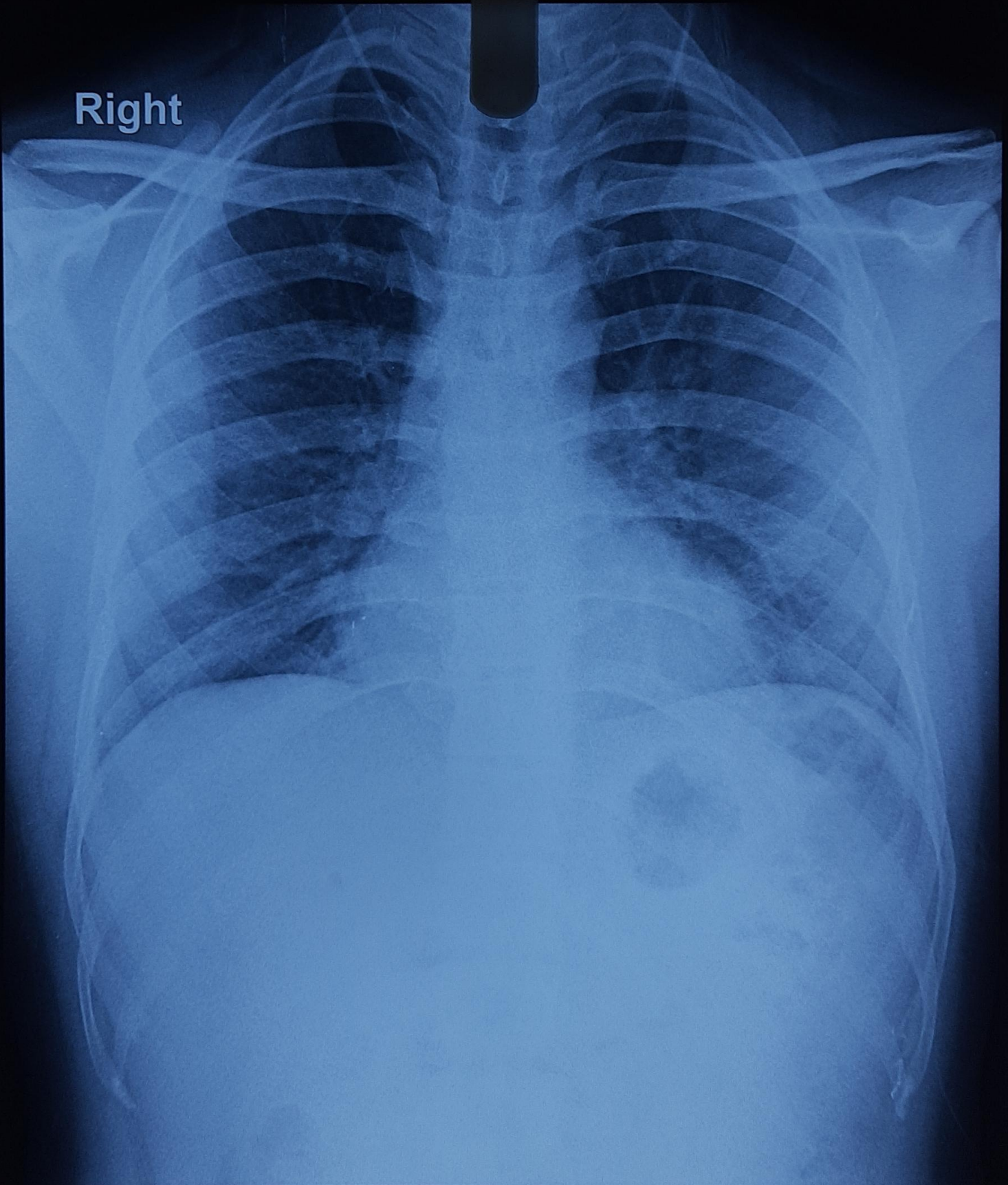
ExTime: 00:36 0.0 mph 0.0%

25 mm/Sec. 1.0 Cm/mV




REMARKS: II aVR aVF V2 V4 V6

Right



JITENDAR KUMAR AGE 26 YEARS 179 DR BO B CHEST,FRN P->A 21-Feb-23

A.L.C. Advance Imaging Diagnostics Centre PATNA - 20



Shubham Imaging & ALC Diagnostic Center

ISO 9001:2015 Certified center

(A Unit of P.K. Arogyam Health & Wellness Center)

E-95, P.C. Colony, Near Sai Netryalaya Transformer, Kankarbagh, Patna - 20

alcdiagnostics@gmail.com

www.pkarogayamhealthcheckup.com

7050037694, 8271206196

OPINION MUST BE CORRELATES WITH CLINICALLY & OTHER INVESTIGATION FOR FINAL DIAGNOSIS. NOT FOR MEDICO LEGAL PURPOSE

Pt. Name :- **JITENDAR KUMAR**
Ref. By :- **DR.MEDIWHEEL**

Date:- **25-Feb-23**
Age / Sex – **26 Yrs. F.**

Thanks for your kind referral

X-RAYCHEST (P.A.VIEW)

The lungs on the either side show equal translucency.

The peripheral pulmonary vasculature is normal.

No focal lung lesion is seen.

The pleural spaces are normal.

Both hila are normal in size, have equal density and bear normal relationship.

The heart and trachea are central in position and no mediastinal abnormality is visible.

The cardiac size is normal.

The domes of the diaphragms are normal in position, and show smooth outline.

IMPRESSION

- NO EVIDENCE OF PULMONARY OR CARDIAC PATHOLOGY IS NOTED.

25/2/23
Consultant Radiologist

ESTB BY:-

Dr. P. K. Tiwari
MD, M.Sc (Radio Imaging)
Ph.D (AlI Nuclear Medicine)
Consultant Imagonologist & Sonologist

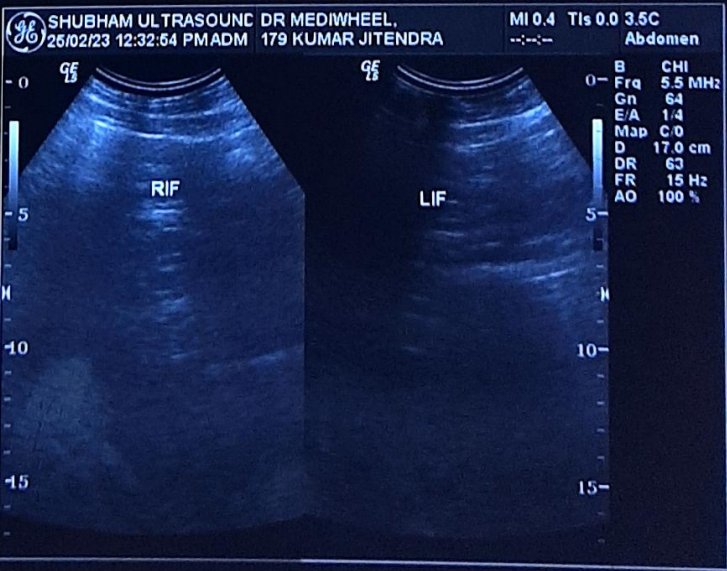
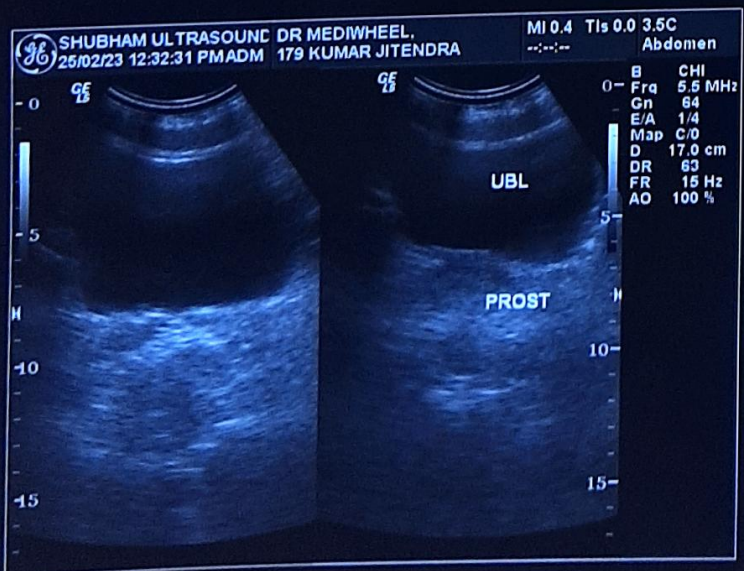
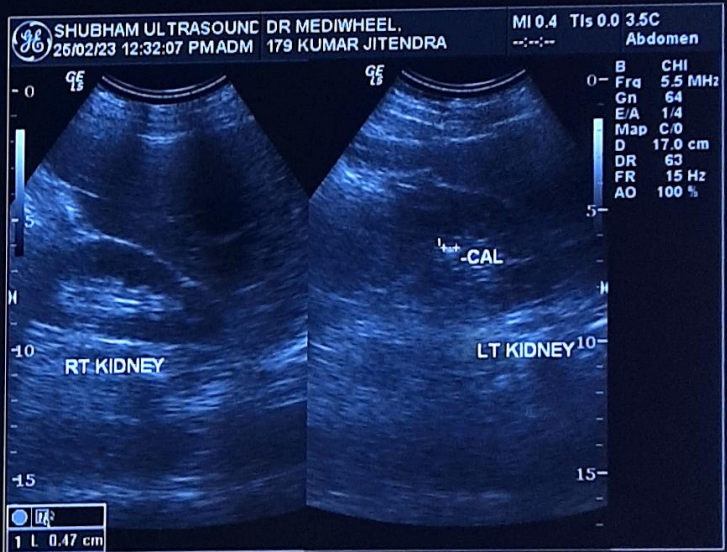
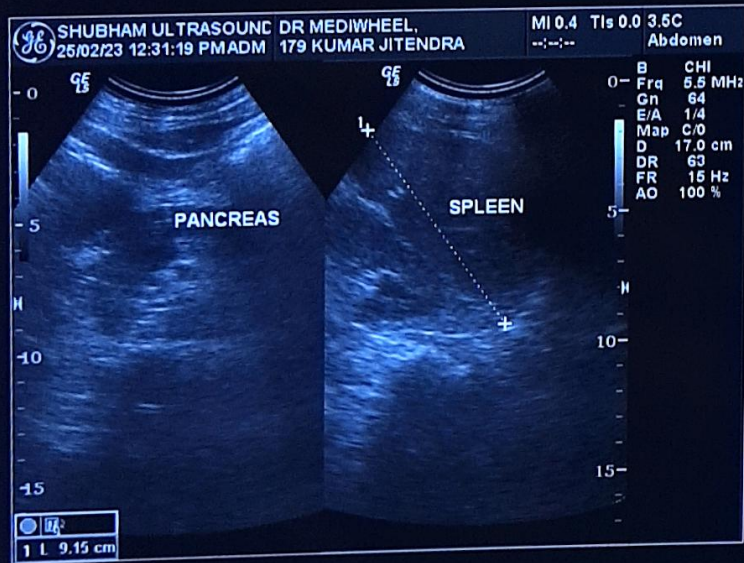
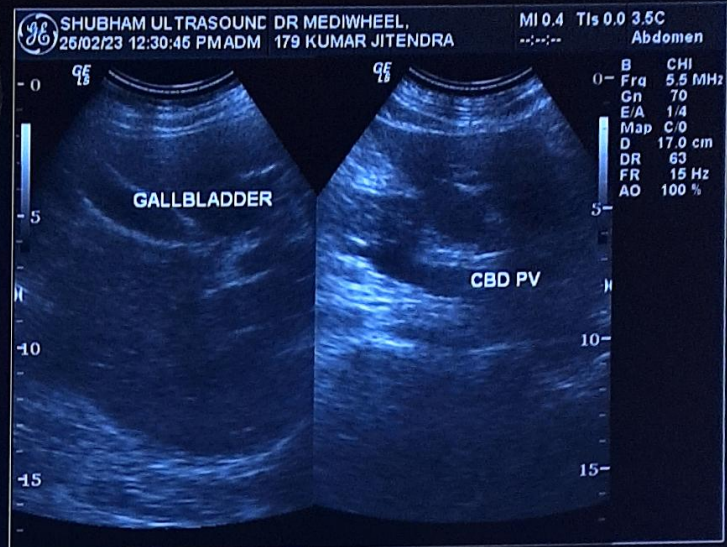
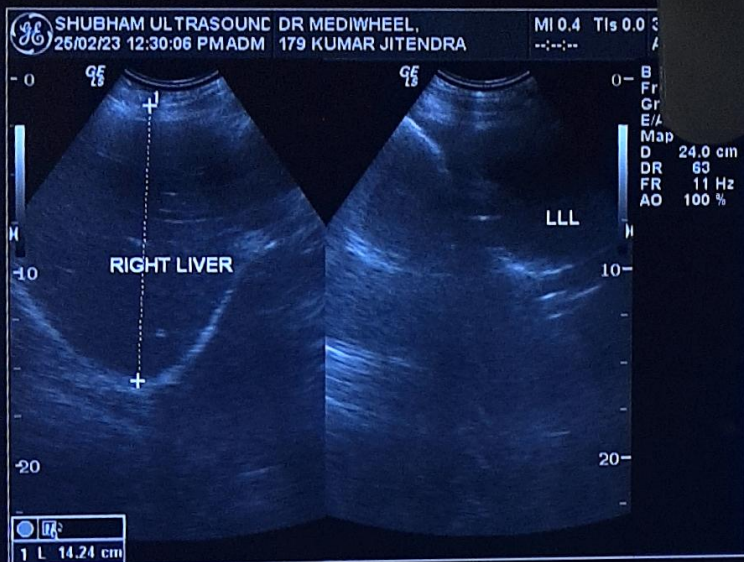
Dr. S. Kumar
MD (Pat)
Consultant Pathologist

Dr. Abhishek Kumar
MBBS, MD
Consultant Neuropathology Physiologist

Dr. Kumari Suman
MBBS, DGO, MD
Consultant (TVS & HSG Specialist)

Dr. A. K. Singh
MBBS, PGDMCH
Consultant Radiologist & Sonologist

PRINTING MISTAKE SHOULD BE REPORTED BACK IMMEDIATELY/ यहाँ जन्म से पहले भुण का लिंग जाँच नहीं होता है ।





Shubham Imaging & ALC Diagnostic Center

ISO 9001:2015 Certified center

(A Unit of P.K. Arogyam Health & Wellness Center)

E-95, P.C. Colony, Near Sai Netryalaya Transformer, Kankarbagh, Patna - 20

alcdiagnostics@gmail.com

www.pkarogayamhealthcheckup.com

7050037694, 8271206196

OPINION MUST BE CORRELATES WITH CLINICALLY & OTHER INVESTIGATION FOR FINAL DIAGNOSIS. NOT FOR MEDICO LEGAL PURPOSE

Pt. Name :- **KUMAR JITENDRA**

Ref. By :- **DR / MEDIWHEEL**

Date:- **25-Feb-23**

Age / Sex - **26 Yrs. M.**

REAL TIME U.S.G. OF WHOLE ABDOMEN

Thanks for your kind referral

(Report.)

LIVER :- Measures 14.24 cm. Mild Enlarged in shape , size and normal echo texture.

I.H.B.R. are not dilated. Hepatic veins are normal. No SOL seen.

G.BL. :- Lumen is echo free. Wall thickness appears normal.

C.B.D. :- Measures 3.5 mm in diameter with echo free lumen. No calculi or mass seen.

P.V. :- Measures 7.7 mm in diameter. Appears normal. No thrombus seen.

PANCREAS :- Normal in shape, size and echo texture. No calcification mass seen.

SPLEEN :- Measures 9.15 cm. Normal in shape, size and echo texture.

No SOL seen.

KIDNEY :- Both kidney shows normal shape, size & echotexture. C.M.D.intact.

P.C.S.is not dilated. A calculi, Measures 4 mm seen at mid pole of Lt. Kidney

Right Kidney :- Measures 9.50 X 3.50 cm.

Left Kidney :- Measures 9.60 X 3.50 cm.

URETER :- Not dilated .No apparent calculi seen.

U.BLADDER:- Shows normal in outline with echo free lumen. No calculi or mass seen.

Pre void – 250 ml. Post void – is in significant

PROSTATE :- Measures 15 gms.(approx). Appears Normal in size, shape, and echo texture.


No calcification , mass ,growth seen. capsule is intact.

R.I.F. :- Son graphically no appendicular mass or collection seen.

OTHERS :- No Ascites . no Lymph Adenopathy. No pleural effusion seen on either side .

IMPRESSION

- **Mild Hepatomegaly**
- **Small Lt. Renal calculi**
- **Adv:- Further work up other investigation**
Otherwise son graphically normal scan. of rest organs


25/02/23

Consultant Radiologist

ESTB BY:-

Dr. P. K. Tiwari

MD, M.Sc (Radio Imaging)

Ph.D (Alt Nuclear Medicine)

Consultant Imagonologist & Sonologist

Dr. S. Kumar

MD (Pat)

Consultant Pathologist

Dr. Abhishek Kumar

MBBS, MD

Consultant Neuropatho Physiologist

Dr. Kumari Suman

MBBS, DGO, MD

Consultant (TVS & HSG Specialist)

Dr. A. K. Singh

MBBS, PGDMCH

Consultant Radiologist & Sonologist

PRINTING MISTAKE SHOULD BE REPORTED BACK IMMEDIATELY/ यहाँ जन्म से पहले भ्रुण का लिंग जाँच नहीं होता है ।