

DAKSH HOSPITAL

396 - 397, Gandhi Nagar, Scheme No. 8, ALWAR -301001

Ref. No.

Date.....

MEDICAL EXAMINATION REPORT

Mediwheel (BOB)

Name: Mrs Prachi Agarawal

Age: 35 yrs

Sex: Female

Date: 14/04/2023

General Physical Examination

Height : 170 cm.

Weight : 89 kg

Pulse : 74/mt

BP : 110/80 mm/hg

Temp. : 97.2 °F

Respiration : 98 %

BMI : 30.8

Systemic Exam:-

NORMAL

Dental Check up :-

NORMAL

Eye check-up :-

NORMAL

Skin Check up:-

NORMAL

ENT Check up:-

NORMAL

Gynae Check up:-

NORMAL

Impression:-

NORMAL

Recommendation:-

NO


 Dr. Muneish Kumar Gupta
 MD Gen. Medicine
 किजिशियल एंड प्रथम रंग विशेषज्ञ
 Reg. No. 3423/16262
 दक्ष हॉस्पिटल, अलवर
 रजि. नं. 5423/16262

Results

Run Date 14/04/2023 10:21:07 AM

Operator DAKSH

Last Name

Sample ID 5

First Name MRS PRACHI AGARWAL

Department

Gender Female Age

Physician DR. MUKESH GUPTA M.D


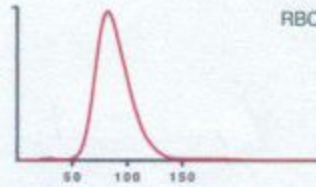
Patient ID AUTO_PID13050

Type Woman

Date of birth

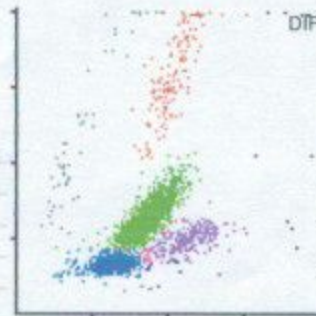
Sample comments

				Range
RBC	4.12	*	10 ⁶ /μL	3.80 - 5.50
HGB	11.8		g/dL	11.5 - 15.2
HCT	38.5	*	%	35.0 - 46.0
MCV	93.6	*	μm ³	77.0 - 97.0
MCH	28.8		pg	26.0 - 34.0
MCHC	30.7	L	g/dL	32.0 - 35.0
RDW-CV	17.1	H	%	11.0 - 17.0
RDW-SD	59.4	H	μm ³	37.0 - 49.0
				Range
PLT	211		10 ³ /μL	150 - 450
PCT	0.23		%	0.15 - 0.40
MPV	11.0		μm ³	8.0 - 11.0
PDW	21.0		μm ³	11.0 - 22.0
P-LCC	83		10 ³ /μL	44 - 140
P-LCR	39.4		%	18.0 - 50.0



Susp. Pathologies
Anisocytosis

			Range	
WBC	4.89		10 ³ /μL	3.50 - 10.00
	#	Range	%	Range
NEU	2.64	1.60 - 7.00	54.4	40.0 - 75.0
LYM	1.79	1.00 - 3.00	36.8	20.0 - 45.0
MON	0.12	0.20 - 0.80	2.6	2.0 - 10.0
EOS	0.24	0.00 - 0.50	4.8	1.0 - 6.0
BAS	0.07	0.00 - 0.15	1.4	0.0 - 1.0
LIC	0.03	0.00 - 0.10	0.6	0.0 - 1.0



डॉ. मुकेश गुप्ता
M.D. F.C.C.S.

फिजिशियन एवं मधुमेह रोग विशेषज्ञ
दक्ष हॉस्पिटल, अलवर

रजि. नं. 5423/16262

14/04/2023 10:22:20 AM

Doctor

Printed by : DAKSH

S/N107YOXH04 TECHNOLOGIST

All investigation have their own limitations regarding the sensitivity & specificity of individual assay procedures, isolated laboratory investigations never confirm the final diagnosis of the disease. They only help in arriving at a diagnosis in conjunction with clinical presentation and other related investigations. Report is not valid for medico-legal purpose subject to ALWAR jurisdiction only.

Date :-14/04/2023

Name :- MRS. PRACHI AGARWAL

Age & Sex :- 35Yrs/ Female

Refd. :- Dr Mukesh Gupta M.D.

	TEST NAME	RESULT	REFERENCE RANGE
	ESR	15	00 -20 mm/hrs
	Blood Group & Rh Factor	A * POSITIVE	
	HbA1C	4.9	4 - 5.6%
	Blood Sugar (F)	89.2	< 70 - 100 mg/dl
	Blood Sugar (PP)	110.2	< 140 mg/dl
	Urine Sugar (F)	NIL	-
	Urine Sugar (PP)	NIL	-
LIVER	S.Bilirubin Total	0.90	0.30 - 1.20 mg/dl
	S.Bilirubin Direct	0.20	0.10 - 0.30 mg/dl
	S.Bilirubin Indirect	0.70	0.30 - 0.90 mg/dl
	S.G.O.T.	15	> 37 u/l
	S.G.P.T.	22	> 40 u/l
	S.Alk. Phosp.	179	80 - 306 u/l
	G.G.T.	17	5 -40 u/l
	Total Protein	6.8	6.5 - 8.5 gm/dl
	Albumin	3.7	3.8 - 5.4 gm/dl
	Globulin	3.1	2.3 - 3.5 gm/dl
	A/G Ratio	1.2	-
AST/ALT Ratio	0.7	-	
KIDNEY	Blood Urea	28.3	15 -45 mg/dl
	S.Creatinine	1.0	0.60 - 1.30 mg/dl
	BUN	16.0	6 -24 mg/dl
	S.Uric Acid	5.1	M 3.1 - 7.0, F 2.5 - 5.6 mg/dl
	BUN/Creatinine Ratio	16	-
LIPID PROFILE	Total Cholesterol	185.1	Up to 200 mg/dl
	S.HDL	43.1	30 - 70 mg/dl
	S.LDL	116.1	Up to 170 mg/dl
	S.VLDL	26.1	5.0 - 40 mg/dl
	S. Triglycerides	130.1	Up to 170 mg/dl
	LDL/HDL Ratio	2.6	-
	Total Cholesterol/ HDL Ratio	4.3	-
THYROID	T3	92.1	40 - 181 ng/dL
	T4	6.8	4.6 - 10.5 µg /dL
	TSH	4.5	0.30 - 5.0 mIU/L

URINE EXAMINATION

Microscopic Examination :

General/Chemical Examination:			RBC	Absent
	Colour	Pale Yellow	WBC	1 - 2
	Reaction	Acidic	Epithelial Cells	0- 1
	Specific Gravity	QNS	Cast	Absent
	Appearance	Clear	Crystal	Absent
	Albumin	Nil	Spermatozoa	Absent
	Sugar	Nil	Amorphous Sediments	Absent
			Other	Absent

X-RAY CHEST

NORMAL STUDY

STOOL EXAMINATION

Microscopic Examination :

General/ Chemical Examination:			RBC	-
	Colour	-	WBC	-
	Consistency	-	Ova & Parasites	-
	PH	-		
		Reducing Substances		

Doctor

TECHNOLOGIST

All investigation have their own limitations regarding the sensitivity & specificity of individual assay procedures, isolated laboratory investigations never confirm the final diagnosis of the disease. They only help in arriving at a diagnosis in conjunction with clinical presentation and other related investigations. Report is not valid for medico-legal purpose subject to ALWAR jurisdiction only.

DAKSH HOSPITAL

396 - 397, Gandhi Nagar, Scheme No. 8, ALWAR -301001

Ref. No.

Date.....

Date :- 14/04/2023

Name :- Mrs Prachi Agarawal

Age & Sex :- 35Yrs/ Female

Refd. :- Dr Mukesh Gupta MD

CYTO-PATHOLOGY**PAP SMEAR**

1. Specimen type	Received two conventional smears.
2. Specimen adequacy	Smears are satisfactory for evaluation.
3. Microscopic finding	Smears are moderately cellular comprises of predominantly intermediate with mature superficial squamous epithelial cells arranged in clusters & scattered singly.
4. Inflammation	Not seen
5. Bacilli	Not seen
6. Endocervical cells	Not seen
7. Koilocytic changes	Not seen
8. Trichomonas	Not seen
9. Dysplasia	Nil
10. Neoplasia	Nil
11. Endometrial cells	Nil

Impression:- Negative for intraepithelial lesion or malignancy


 डॉ० मुकेश गुप्ता
 M.D. F.C.C.S.
 फिजिशियन एवं मधुमेह रोग विशेषज्ञ
 दक्ष हॉस्पिटल, अलवर
 रजि. नं. 5423/16282



दक्ष हॉस्पिटल

396, गाँधी नगर स्कीम नं.8, अलवर (राज०) ☎ 0144-2703340

Sonography / 2D Echo Cardiography / Doppler Report

2D/ ECHO REPORT

Name: - Mrs Prachi

Age: - 35 Yrs

Date: - 14-Apr-23

Reg. No.: - Alw/2009/04
BOB health checkup

PROCEDURES:

M-MODE/2D/DOPPLER/COLOR/CONTRAST B.A.S. M²

MEASUREMENT:		DOPPLER:			
		NORMAL		NORMAL (cm/sec.)	
AOD	23	(20- 37mm)	MV 0.9	(0.8- 1.3)	MR No
LA	23	(19- 40mm)	AV 1.3	(1.2- 1.8)	AR No
AVO	18	(12- 25mm)	TV 0.6	(0.3- 0.8)	TR No
RVDd.	11	(03- 09mm)	PV 0.8	(0.7- 1.1)	PR No
LVDd	52	(37- 56mm)	MITRAL VALVE-		
LVDs	31	(22- 40mm)		AML	Normal
IVS d	7.9	(06- 12mm)		PML	Normal
IVS s	10		AORTIC VALVE		
PWd	5.8	(05- 10mm)			Normal
LV FUNCTION		TV & PV are normal.			
M- E- S Separation		<0.9cm			
Minor		24.42%			
LV Ejection Fraction	71%	65 +/- 12%			

LV WALL MOTION: NO RWMA
ALL CARDIAC CHAMBERS ARE NORMAL
ALL VALVES ARE NORMAL
NO CLOT, VEGETATION, PERICARDIAL EFFUSION

FINAL DIAGNOSIS: NORMAL STUDY

Adv: - Follow up/ review at higher center for confirmation

Note:- Please Correlate clinically. Due to technical limitations as well as inaccuracies inherent in the laboratory and statistical analysis of biological process. Diagnostic accuracy of ECHO is up to 95% only.
Report is not valid for medico-legal purpose.


DR. MUKESH GUPTA
Dr. Mukesh Kumar Gupta
PHYSICIAN
Physician & Sonologist
RM 5423/16262



"भ्रूण लिंग परीक्षण की शिकायत
104 टोल फ्री सेवा पर भी की
जा सकती है"
भ्रूण लिंग परीक्षण की शिकायत 104 टोल फ्री सेवा पर भी की जा सकती है।



दक्ष हॉस्पिटल

396, गाँधी नगर स्कीम नं.8, अलवर (राज०) ☎ 0144-2703340

Sonography / 2D Echo Cardiography / Doppler Report

NAME :- MRS Prachi/F/35 YRS

14-Apr-23

BOB HEALTH CHECKUP

U.S.G. OF ABDOMEN & PELVIS

LIVER

Liver is 15.2 cm at MCL with normal echo-texture. Intra hepatic biliary radicals are not dilated. No evidence of focal or diffuse lesion.

GALL BLADDER

Gall bladder **has sludge.**

PANCREAS

Pancreas is normal in size, shape & echo-texture. No evidence of focal or diffuse lesion. MPD not dilated.

SPLEEN

8.9 cm in size with normal shape & echo-texture. Spleen vein is normal. No evidence of focal or diffuse lesion.

KIDNEY

Both kidneys are normal.

URINARY BLADDER

UB is normal.

UTERUS:

Uterus is normal in size (8.8x3.4x4.7cm) with homogenous echo-texture. Endometrial 5 mm in thickness & echo genicity.

OVARIES:

Both ovaries are normal.

Advice- follow up/ hormonal study review at higher center for confirmation

Please correlate clinically. USG accuracy is 95 % due to technical limitations as well as inaccuracies inherent in the laboratory and statistical analysis biological process. This report is not valid for medico-legal cases.


DR. MUKESH GUPTA
Dr. Mukesh Kumar Gupta
Physician & Sonologist
RM 5423/16262



"भ्रूण लिंग परीक्षण की शिकायत
104 टोल फ्री सेवा पर भी की
जा सकती है"

भ्रूण लिंग परीक्षण की शिकायत 104 टोल फ्री सेवा पर भी की जा सकती है।

ID: 604

14-04-2023 12:18:26

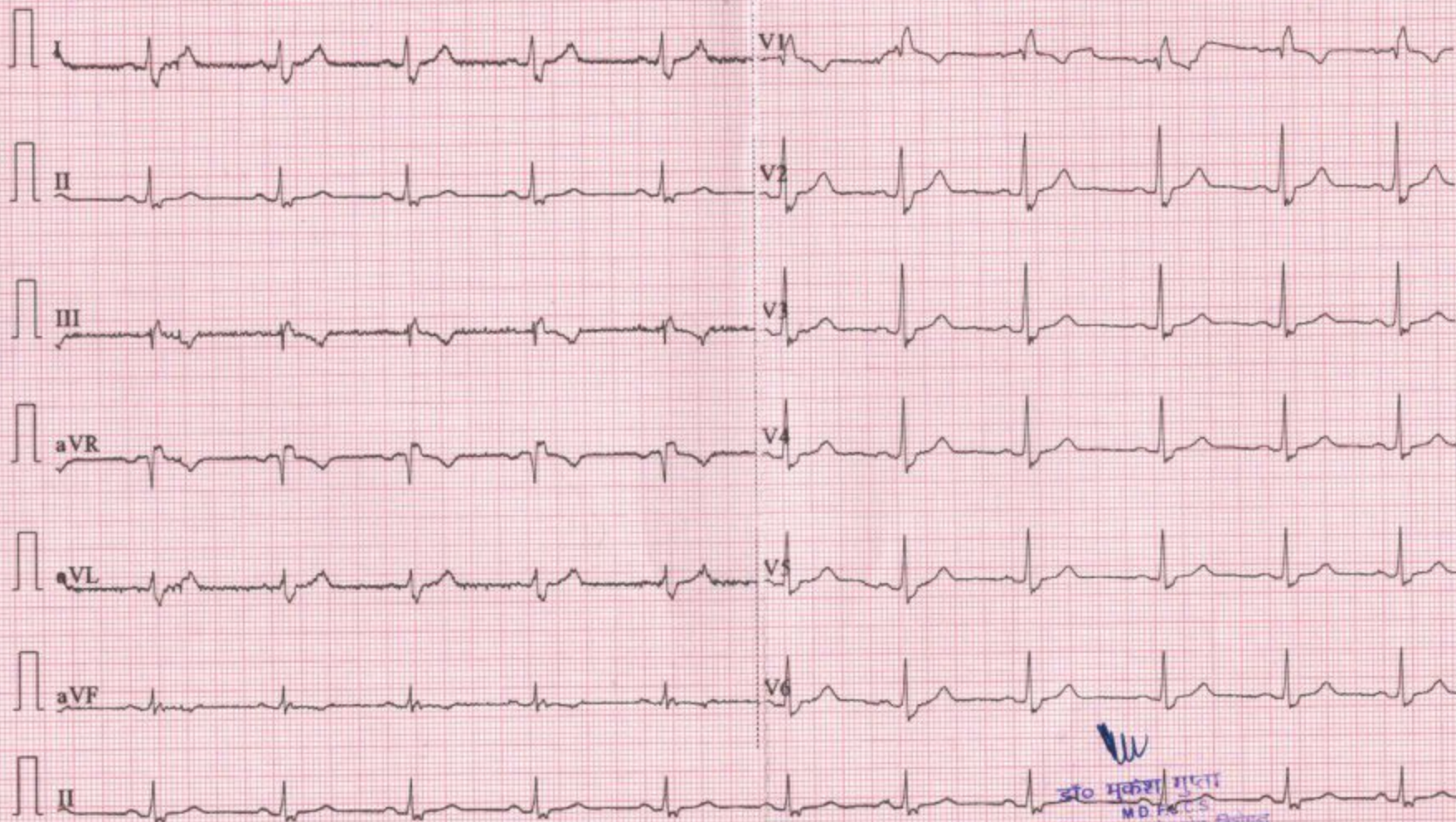
Female Years
Req. No. :


HR : 67 bpm
P : 116 ms
PR : 166 ms
QRS : 124 ms
QT/QTcBz : 414/437 ms
P:QRS/T : 51/59/-4 °
RV5/SV1 : 0.883/0.134 mV

Diagnosis Information:

Sinus rhythm
Right bundle branch block
Inferior T wave abnormality is nonspecific
Abnormal ECG

Report Confirmed by:




डॉ० मुकेश गुप्ता
 MB, BCh, FRCGS
 कर्जिसियन एंव मायने रोग विशेषज्ञ
 डॉ० सुविपुल अलवर
 राज. नं. 579 Hospital Alwar

PAT00421102 MRS PRACHI REFD BY DR MUKESH GUIPTA MD CHEST 14.04.2023
1535

R

VIJAY DIAGNOSTIC CENTRE 1/16 KALA KUAN .ALWAR

1535

