



Info Department <info@aakashhospital.com>


**Health Check up Booking Confirmed Request(bobE3123),Package Code-  
PKG10000248, Beneficiary Code-34082**

Mediwheel <noreply@mediwheel.in>

Wed, Sep 8, 2021 at 11:35 AM

To: "info@aakashhospital.com" <info@aakashhospital.com>, Mediwheel Admin <santosh@policywheel.com>

Cc: Mediwheel CC <wellness1@mediwheel.in>, Mediwheel CC <customercare@mediwheel.in>



**011-41195959**

Email:wellness@mediwheel.in

Hi **Aakash Hospital**,

Diagnostic/Hospital Location :**90/43 Malviya Nagar New Delhi**

We have received the confirmation for the following booking .

**Beneficiary Name** : PKG10000248

**Beneficiary Name** : MR. AGGARWAL NAVEEN

**Member Age** : 30

**Member Gender** : Male

**Member Relation** : Employee

**Package Name** : Mediwheel Metro BOB Full Body Health Checkup Male Below 40

**Location** : GULAB BAUG,Bihar-854326

**Contact Details** : 9728606010

**Booking Date** : 08-09-2021

**Appointment Date** : 10-09-2021

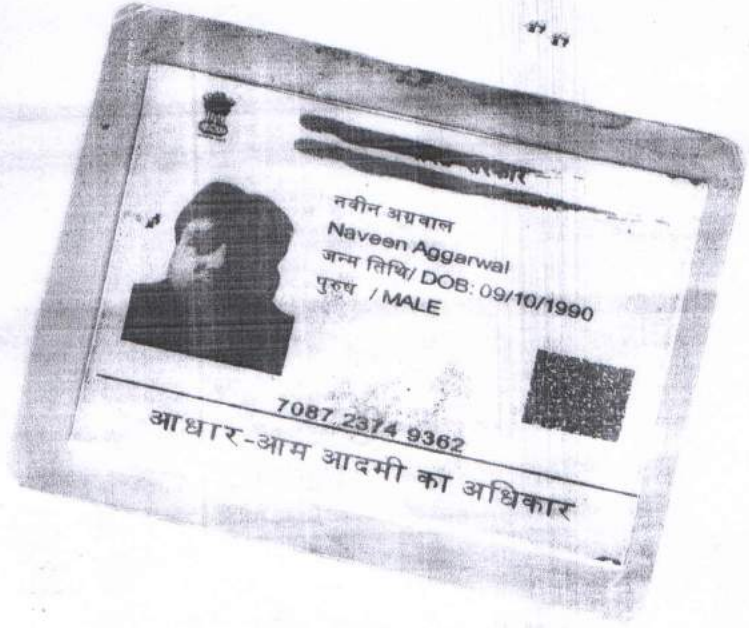**Instructions to undergo Health Check:**

1. Please ensure you are on complete fasting for 10-To-12-Hours prior to check.
2. During fasting time do not take any kind of medication, alcohol, cigarettes, tobacco or any other liquids (except Water) in the morning.
3. Bring urine sample in a container if possible (containers are available at the Health Check centre).
4. Please bring all your medical prescriptions and previous health medical records with you.
5. Kindly inform the health check reception in case if you have a history of diabetes and cardiac problems.

**For Women:**

1. Pregnant Women or those suspecting are advised not to undergo any X-Ray test.
2. It is advisable not to undergo any Health Check during menstrual cycle.

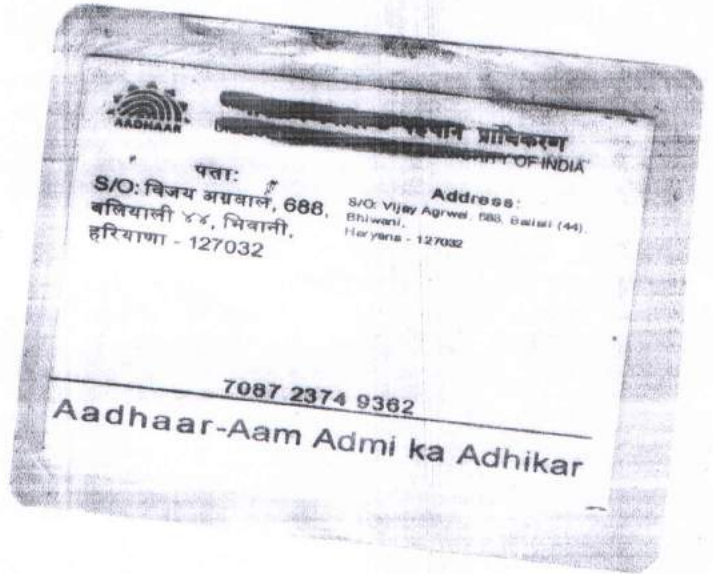We request you to facilitate the employee on priority.



*Naveen Aggarwal*

*31/12*

**DR. R. K. MEHRA**  
MBBS, DTCD (Delhi)  
MCI - 1476  
Aakash Hospital  
90/43, Malviya Nagar,  
New Delhi - 110017



**B** बैंक ऑफ बड़ौदा  
**Bank of Baroda**

SL: ROPURN0 408



नाम  
Name **NAVEEN AGGARWAL**

कर्मचारी कूट क.  
E.C. NO **126993**

*[Handwritten Signature]*  
जारीकर्ता प्राधिकारी  
Issuing Authority

*[Handwritten Signature]*  
धारक को हस्ताक्षर  
Signature of Holder

*[Handwritten Signature]*  
13/1/14

*Naveen Aggarwal*

**DR. R. K. MEHRA**  
MBBS, DTCD (Delhi)  
NICI - 1476  
Aakash Hospital  
90/43, Malviya Nagar,  
New Delhi -110017



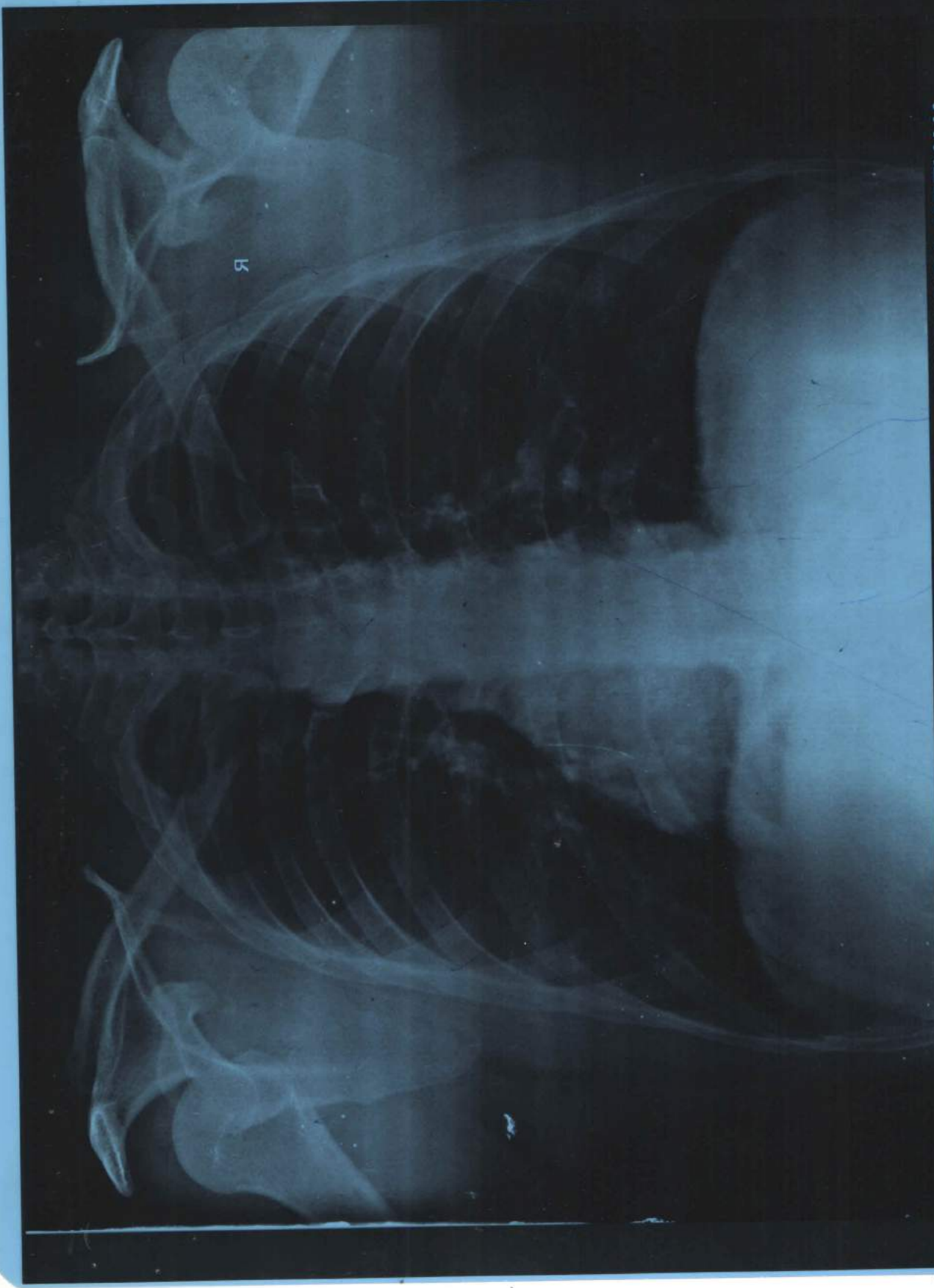
09/09/2021  
1:59PM

*M. Naveen Agrawal*

*12/12/21*

**DR. R. K. MEHRA**  
M.B.B.S, D.T.C.D (Delhi)  
- 1476  
Rash Hospital  
13, Malviya Nagar,  
Delhi - 110017

AKASH HOSPITAL 30143, MATIYA NAGAR, PH-40201000  
NAVEEN AGGARWAL 30YRS AKH 53435 M CHEST PA 5051-02-02





# Aakash Hospital<sup>TM</sup>

*Care with concern*

(A unit of Dr. Gaba & Associates Medicare Pvt. Ltd.)



CIN No. U85110DL2004PTC125538

90/43, Malviya Nagar, New Delhi-110017  
#+91-11-40501000 (100 Lines), 9871027922  
info@aakashhospital.com, www.aakashhospital.com

<b>NAME: MR NAVEEN AGGARWAL</b>	<b>AGE: 30 Y</b>	<b>SEX: MALE</b>
<b>REF.BY: MEDICAL</b>	<b>DATE: 09.09.21</b>	<b>X RAY NO: 23432</b>

## CHEST (PA VIEW)

The diaphragmatic domes have smooth contours, a normal arched shape and occupy a normal position.

The costophrenic angles are clear.

Both lungs are normally aerated and are applied to the chest wall on all sides.

The mediastinum is centered and of normal width.

The cardiac and vascular shadows show a normal configuration.

The thoracic skeleton is symmetrically shaped and the spine is unremarkable.

The soft tissue envelope of chest shows no abnormalities.

**IMP: NORMAL STUDY**

  
**DR. R. DUGGAL**  
**MD(RADIOLOGY)**  
**DMC-2595**

### AREA OF EXPERTISE

- Interventions (Vascular & Nonvascular)
- FNAC
- Biopsy
- Drainages
- Doppler Scans
- 3D & 4D Scans
- Varicose Vein Laser Treatment





90/43, Malviya Nagar, New Delhi-110017  
 #011 40501000 (100 Lines), 9871027922  
 info@aakashhospital.com, www.aakashhospital.com

<b>Name</b>	<b>Mr. NAVEEN AGGARWAL</b>	<b>Srl No. 55</b>	<b>Sample Coll. 09/09/202123:45:38</b>
<b>Ref. By</b>	<b>SELF</b>	<b>Age 30 Yrs. Male</b>	<b>Report printing 12/09/202116:52:46</b>
<b>UHID</b>	<b>02</b>	<b>Dep. OPD</b>	<b>Patient Id 2109090055</b>

Test Name	Result	Unit	Normal Value
<b><u>COMPLETE HAEMOGRAM</u></b>			
HAEMOGLOBIN (Hb)	14.4	gm/dl	13.5 - 18.0
TOTAL LEUCOCYTE COUNT (TLC)	8,000	/cumm	4000 - 11000
<b>DIFFERENTIAL LEUCOCYTE COUNT (DLC)</b>			
NEUTROPHIL	48	%	40 - 75
LYMPHOCYTE	43	%	20 - 45
EOSINOPHIL	06	%	01 - 06
MONOCYTE	03	%	02 - 10
BASOPHIL	00	%	0.0 - 1.0
ESR (WESTEGREN's METHOD)	20	mm/1st hr.	0 - 15
R B C COUNT	4.86	Millions/cmm	4.5 - 5.5
P.C.V / HAEMATOCRIT	43.7	%	40 - 54
M C V	89.8	fl.	80 - 100
M C H	29.6	Picogram	27.0 - 31.0
M C H C	30.0	gm/dl	33 - 37
PLATELET COUNT	2.14	Lakh/cmm	1.50 - 4.00
RDW	12.4	FL	11.6 - 14.0
<b><u>LIVER FUNCTION TEST (LFT)</u></b>			
BILIRUBIN TOTAL Diazo Method	0.3	mg/dl	0 - 1.0
CONJUGATED (D. Bilirubin) Diazo Method	0.1	mg/dl	0.00 - 0.25
UNCONJUGATED (I.D. Bilirubin)	0.2	mg/dl	0.00 - 0.70



90/43, Malviya Nagar, New Delhi-110017  
 #011 40501000 (100 Lines), 9871027922  
 info@aakashhospital.com, www.aakashhospital.com

<b>Name</b>	<b>Mr. NAVEEN AGGARWAL</b>	<b>Srl No. 55</b>	<b>Sample Coll.</b>	<b>09/09/202123:45:38</b>
<b>Ref. By</b>	<b>SELF</b>	<b>Age 30 Yrs. Male</b>	<b>Report printing</b>	<b>12/09/202116:52:49</b>
<b>UHID</b>	<b>02</b>	<b>Dep. OPD</b>	<b>Patient Id</b>	<b>2109090055</b>

Test Name	Result	Unit	Normal Value
TOTAL PROTEIN Biuret Method	7.9	gm/dl	6.6 - 8.3
ALBUMIN BCG Method	4.1	gm/dl	3.4 - 4.8
GLOBULIN	3.8	gm/dl	2.3 - 3.5
A/G RATIO	1.0		
SGOT IFCC Method	51	IU/L	0 - 40
SGPT IFCC Method	98	IU/L	0.0 - 41.0
ALKALINE PHOSPHATASE IFCC Method	132	U/L	40.0 - 130.0
GAMMA GT Glupa C Method	50	IU/L	8.0 - 71.0
<b>LFT INTERPRET</b>			
<b><u>KIDNEY FUNCTION TEST (RFT)</u></b>			
BLOOD UREA Urease GLDH Method	38.8	mg /dl	15.0 - 45.0
SERUM CREATININE ENZYMATIC Method	0.9	mg%	0.7 - 1.2
SERUM URIC ACID Uricase-POD Method	6.1	mg%	3.4 - 7.0
BLOOD UREA NITROGEN (BUN)	18.1	mg%	6.0 - 20.0
SODIUM	139	mmol/L	136.0 - 149.0
POTASSIUM	4.7	mmol/L	3.5 - 5.5
CHLORIDE	108	mmol/L	98.0 - 109.0





# Aakash Hospital™

Care with concern

(A unit of Dr. Gaba & Associates Medicare Pvt. Ltd.)



90/43, Malviya Nagar, New Delhi-110017  
#011 40501000 (100 Lines), 9871027922  
info@aakashhospital.com, www.aakashhospital.com

Name	Mr. NAVEEN AGGARWAL	Srl No.	55	Sample Coll.	09/09/202123:45:38
Ref. By	SELF	Age	30 Yrs. Male	Report printing	12/09/202116:52:52
UHID	02	Dep.	OPD	Patient Id	2109090055

Test Name	Result	Unit	Normal Value
<b>LIPID PROFILE</b>			
TRIGLYCERIDES GPO-Method	269	mg/dL	40.0 - 165.0
TOTAL CHOLESTEROL	224	mg/dL	123.0 - 199.0
H D L CHOLESTEROL DIRECT	48.3	mg/dL	40.0 - 79.4
V L D L	53.8	mg/dL	4.7 - 22.1
L D L CHOLESTEROL CALCULATED	121.9	mg/dL	63.0 - 129.0
TOTAL CHOLESTEROL/HDL RATIO	4.63		0.0 - 4.97
LDL / HDL CHOLESTEROL RATIO	2.52		0.00 - 3.55

#### INTERPRETATION

**TRIGLYCERIDE:-** Level > 250mg/dL is associated with an approximately 2-fold greater risk of coronary vascular disease. Elevation of triglycerides can be seen with obesity, medication, fast less than 12 hrs., alcohol intake, diabetes melitus, and pancreatitis.

**CHOLESTEROL:-** Its fractions and triglycerides are the important plasma lipids in defining cardiovascular risk factors and in the management of cardiovascular disease. Highest acceptable and optimum values of cholesterol values of cholesterol vary with age. Values above 220 mgm/dl are associated with increased risk of CHD regardless of HDL & LDL values.

**HDL-CHOLESTEROL:-** Level <35 mg/dL is associated with an increased risk of coronary vascular disease even in the face of desirable levels of cholesterol and LDL - cholesterol.

**LDL - CHOLESTEROL & TOTAL CHOLESTEROL:-** Levels can be strikingly altered by thyroid, renal and liver disease as well as hereditary factors. Based on total cholesterol, LDL- cholesterol, and total cholesterol/HDL - cholesterol ratio, patients may be divided into the three risk categories :-

<u>CHOLESTEROL</u>	<u>LDL-CHOLESTEROL</u>	<u>CHO/HDL RATIO</u>
--------------------	------------------------	----------------------

Acceptable/Low Risk	: < 200 mg/dL	: <130 mg/dL	: < 4.5
---------------------	---------------	--------------	---------



90/43, Malviya Nagar, New Delhi-110017  
 #011 40501000 (100 Lines), 9871027922  
 info@aakashhospital.com, www.aakashhospital.com

Name	Mr. NAVEEN AGGARWAL	Srl No.	55	Sample Coll.	09/09/202123:45:38
Ref. By	SELF	Age	30 Yrs. Male	Report printing	12/09/202116:52:53
UHID	02	Dep.	OPD	Patient Id	2109090055

Test Name	Result	Unit	Normal Value
Borderline High Risk	: 200-239 mg/dL	: 130-159 mg/dl	: 4.5 - 6.0
High Risk	: > 240 mg /dL	: > 160 mg/dL	: > 6.0

**APO A1 & APO B:-** Recent studies have shown that Apolipoproteins A1 & B might be the best indicators of Coronary Artery Disease risk in an individual. Patients who have normal lipid profile may have abnormal Apo A1 & Apo B values. Ratio of Apo B : Apo A1 is >1 in cases of increased CHD risk.

\*\*\*\* End Of Report \*\*\*\*



90/43, Malviya Nagar, New Delhi-110017  
 #011 40501000 (100 Lines), 9871027922  
 info@aakashhospital.com, www.aakashhospital.com

<b>Name</b>	<b>Mr. NAVEEN AGGARWAL</b>	<b>Srl No. 55</b>	<b>Sample Coll.</b>	<b>09/09/202123:45:38</b>
<b>Ref. By</b>	<b>SELF</b>	<b>Age 30 Yrs. Male</b>	<b>Report printing</b>	<b>12/09/202116:52:53</b>
<b>UHID</b>	<b>02</b>	<b>Dep. OPD</b>	<b>Patient Id</b>	<b>2109090055</b>

Test Name	Result	Unit	Normal Value
-----------	--------	------	--------------

### BIOCHEMISTRY

BLOOD SUGAR FASTING GOD-POD Method	105	mg/dl	70 - 110
BLOOD SUGAR PP GOD-POD Method	115	mg/dl	80 - 140
URINE SUGAR FASTING	NIL		NIL

\*\*\*\* End Of Report \*\*\*\*



90/43, Malviya Nagar, New Delhi-110017  
 #011 40501000 (100 Lines), 9871027922  
 info@aakashhospital.com, www.aakashhospital.com

Name	Mr. NAVEEN AGGARWAL	Srl No. 55	Sample Coll.	09/09/202123:45:38
Ref. By	SELF	Age 30 Yrs. Male	Report printing	12/09/202116:52:54
UHID	02	Dep. OPD	Patient Id	2109090055

Test Name	Result	Unit	Normal Value
-----------	--------	------	--------------

## HAEMATOLOGY

BLOOD GROUP ABO	"O"
RH TYPING	POSITIVE

## URINE EXAMINATION TEST

### PHYSICAL EXAMINATION

QUANTITY	15	ml.	
COLOUR	DEEP YELLOW		Pale yellow
TRANSPARENCY	SLIGHTLY TURBID		
SPECIFIC GRAVITY	1.020		1.005-1.030
PH	6.5		6.0-7.5

### CHEMICAL EXAMINATION

ALBUMIN	TRACE		Nil
REDUCING SUGAR	NIL		Nil
KETON	NIL		
LEUCOCYTE	NIL		
NITRITES	NEGATIVE		
BLOOD	NIL		

### MICROSCOPIC EXAMINATION

PUS CELLS	1-2	/HPF	0-5
RBC'S	NIL	/HPF	0-2



90/43, Malviya Nagar, New Delhi-110017  
 #011 40501000 (100 Lines), 9871027922  
 info@aakashhospital.com, www.aakashhospital.com

<b>Name</b>	Mr. NAVEEN AGGARWAL	<b>Srl No.</b>	55	<b>Sample Coll.</b>	09/09/202123:45:38
<b>Ref. By</b>	SELF	<b>Age</b>	30 Yrs. Male	<b>Report printing</b>	12/09/202116:52:57
<b>UHID</b>	02	<b>Dep.</b>	OPD	<b>Patient Id</b>	2109090055

Test Name	Result	Unit	Normal Value
CASTS	NIL		Occasional
CRYSTALS	AMORPHOUS URATES PRESENT		
EPITHELIAL CELLS	0-1	/HPF	0-3
BACTERIA	NIL		Nil

### STOOL EXAMINATION

#### STOOL ROUTINE & MICROSCOPY PHYSICAL EXAMINATION

COLOUR/ APPEARANCE	BROWNISH
CONSISTENCY	SEMI-FORMED
PUS	NIL
MUCUS	NIL
BLOOD	NIL

#### CHEMICAL REACTION

REACTION	6.0
----------	-----

#### MICROSCOPY EXAMINATION

PUS CELLS	2-3/HPF
EPITHELIAL CELLS	1-2 /HPF
RBC'S	NIL
OVA	NIL
CYST	NIL



# Aakash Hospital™

*Care with concern*

(A unit of Dr. Gaba & Associates Medicare Pvt. Ltd.)



90/43, Malviya Nagar, New Delhi-110017  
 #011 40501000 (100 Lines), 9871027922  
 info@akashhospital.com, www.aakashhospital.com

Name	Mr. NAVEEN AGGARWAL	Srl No.	55	Sample Coll.	09/09/202123:45:38
Ref. By	SELF	Age	30 Yrs. Male	Report printing	12/09/202116:52:57
UHID	02	Dep.	OPD	Patient Id	2109090055

VEG. MATTER	ABSENT
BACTERIA	NIL
OTHERS	NIL

\*\*\*\* End Of Report \*\*\*\*

Dr. MEENA METRE  
 MBBS, MD  
 CONSULTANT PATHOLOGIST



# Aakash Hospital™

Care with concern

(A unit of Dr. Gaba & Associates Medicare Pvt. Ltd.)



90/43, Malviya Nagar, New Delhi-110017  
#011 40501000 (100 Lines), 9871027922  
info@aakashhospital.com, www.aakashhospital.com

PATIENT NAME	: MR. NAVEEN AGGARWAL	AGE / SEX	: 30 Years / M
REG No	: 3428	REG.DATE/TIME	: 09/09/2021
UID No	: 101446011	PRINT DATE	: 12/09/2021
REF. BY Dr.	: SELF	AREA	: SAKET



## BIOCHEMISTRY

<u>Investigation</u>	<u>Result</u>	<u>Unit</u>	<u>Biological Reference Interval</u>
HbA1c WHOLE BLOOD ( HPLC)	6.90	%	4.8 - 5.9

### CLINICAL EVALUATION:

#### RECOMMENDED DCCT NGSP GUIDELINES FOR HbA1C LEVELS :

Normal                                    4.8 % - 5.9 %  
 Target for diabetics                : < 7 %  
 Therapeutic action required        > 8 %

.....END OF REPORT.....



*Shrey Khanna*



# Aakash Hospital™

Care with concern

(A unit of Dr. Gaba & Associates Medicare Pvt. Ltd.)



90/43, Malviya Nagar, New Delhi-110017  
#011 40501000 (100 Lines), 9871027922  
info@aakashhospital.com, www.aakashhospital.com

PATIENT NAME : MR. NAVEEN AGGARWAL  
REG No : 3428  
UID No : 101446011  
REF. BY Dr. : SELF

AGE / SEX : 30 Years / M  
REG.DATE/TIME : 09/09/2021  
PRINT DATE : 12/09/2021  
AREA : SAKET



## HORMONE

<u>Investigation</u>	<u>Result</u>	<u>Unit</u>	<u>Biological Reference Interval</u>
T3 SERUM (CLIA)	2.21	nmol/L	0.92 - 2.79
T4 SERUM (CLIA)	101.10	nmol/L	58.1 - 140.6
TSH SERUM(CLIA)	2.35	uIU/ml	0.35 - 5.5

REFERANCE RANGE FOR Children

1-4 days : 1.00-39.00  
5 days-5 months : 1.7 - 9.1  
5 months - 20 years : 0.70 - 6.40

Remarks :

(1) 4.2 to 15  $\mu$ IU/mL - Correlate clinically as physiological and other factors may falsely elevate TSH level. (2) TSH Values may be transiently altered because of non thyroidal illness. (3) Some drugs may decrease TSH values, e.g., L-dopa, Glucocorticoids. (4) Some drugs may increase TSH values, e.g., Iodine, Lithium, Amiodarone. Abbreviations.

.....END OF REPORT.....



*Shrey Khanna*





# Aakash Hospital<sup>TM</sup>

Care with concern

(A unit of Dr. Gaba & Associates Medicare Pvt. Ltd.)



CIN No. U85110DL2004PTC125538

90/43, Malviya Nagar, New Delhi-110017  
#+91-11-40501000 (100 Lines), 9871027922  
info@aakashhospital.com, www.aakashhospital.com

## ECHOCARDIOGRAM REPORT

NAME : MR NAVEEN AGGARWAL  
AGE/SEX : 30/M  
DATE : 09.09.21

## ECHOCARDIOGRAPHY & COLOR DOPPLER REPORT

MEASUREMENT	VALUE	NORMAL RANGE
AORTIC ROOT DIAMETER	26	20 – 37 mm
AORTIC VALVE OPENING	16	15 – 26 mm
LEFT ATRIAL DIMENSION	30	19 - 40 mm
RV DIMENSION	N	07 – 26 mm
RV THICKNESS	N	03 -09 mm
LV ED DIMENSION	37	37 – 56 mm
LV ES DIMENSION	23	22 - 40 mm
IVS THICKNESS	ED – 07 ES – 12	06 – 12 mm
LVPW THICKNESS	ED – 06 ES – 09	05 – 11 mm
IVS/LVPW RATION	N	
MITRAL VALVE	DE-N EF – N	
INDICES OF LV FUNCTION		
LVEF	60%	60 +/-5 %
FS	32%	24 -42 %

### AREA OF EXPERTISE

- Interventions  
(Vascular & Nonvascular)
- FNAC

- Biopsy
- Drainages
- Doppler Scans

- 3D & 4D Scans
- Varicose Vein  
Laser Treatment





# Aakash Hospital<sup>TM</sup>

*Care with concern*

(A unit of Dr. Gaba & Associates Medicare Pvt. Ltd.)



CIN No. U85110DL2004PTC125538

90/43, Malviya Nagar, New Delhi-110017  
#+91-11-40501000 (100 Lines), 9871027922  
info@aakashhospital.com, www.aakashhospital.com

## IMAGING

- ❖ LV normal size. Good contractility. RWMA absent. No thrombus.
- ❖ LA normal in size. No clot.
- ❖ RV & RA normal size. RV contractility.
- ❖ Mitral valve leaflets normal. PML motion normal. No annular calcification present.
- ❖ Normal tricuspid & pulmonic valves.
- ❖ Aortic valve- tricuspid.
- ❖ Pericardium normal.

**RWMA: ABSENT**


### **DOPPLER:-**

MV	E 0.77 m/sec	A 0.51 m/sec	MR	0/4
TV	0.40 m/sec		TR	0/4
AV	1.10 m/sec		AR	0/4
PV	0.85 m/sec		PR	0/4

**COLOUR FLOW MAPPING: NORMAL.**

### **FINAL IMPRESSION:-**

- ❖ Normal LV wall motion and systolic function.
- ❖ Normal flow across valves.
- ❖ No LV clot, Vegetation, pericardial effusion.

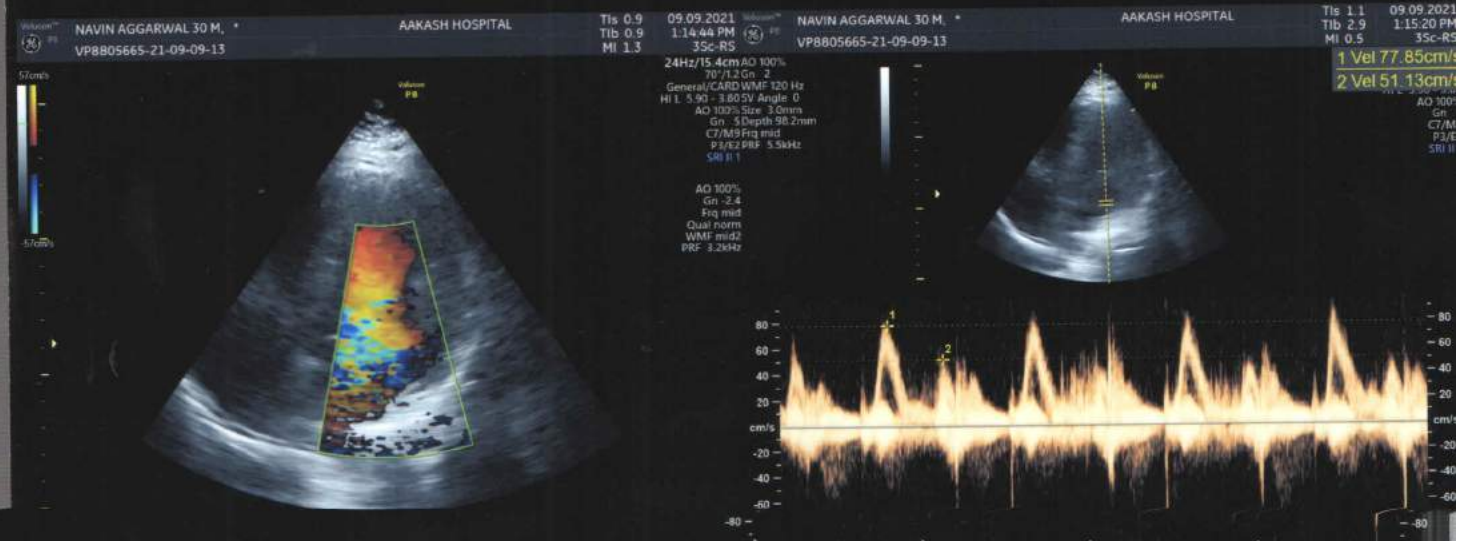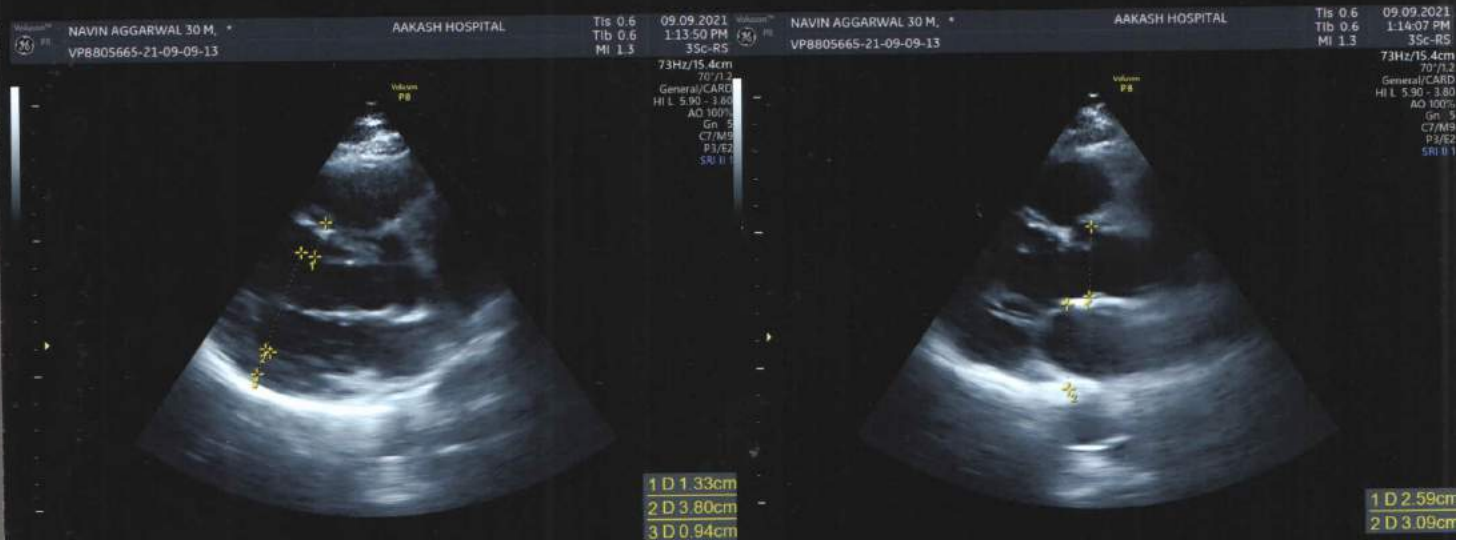
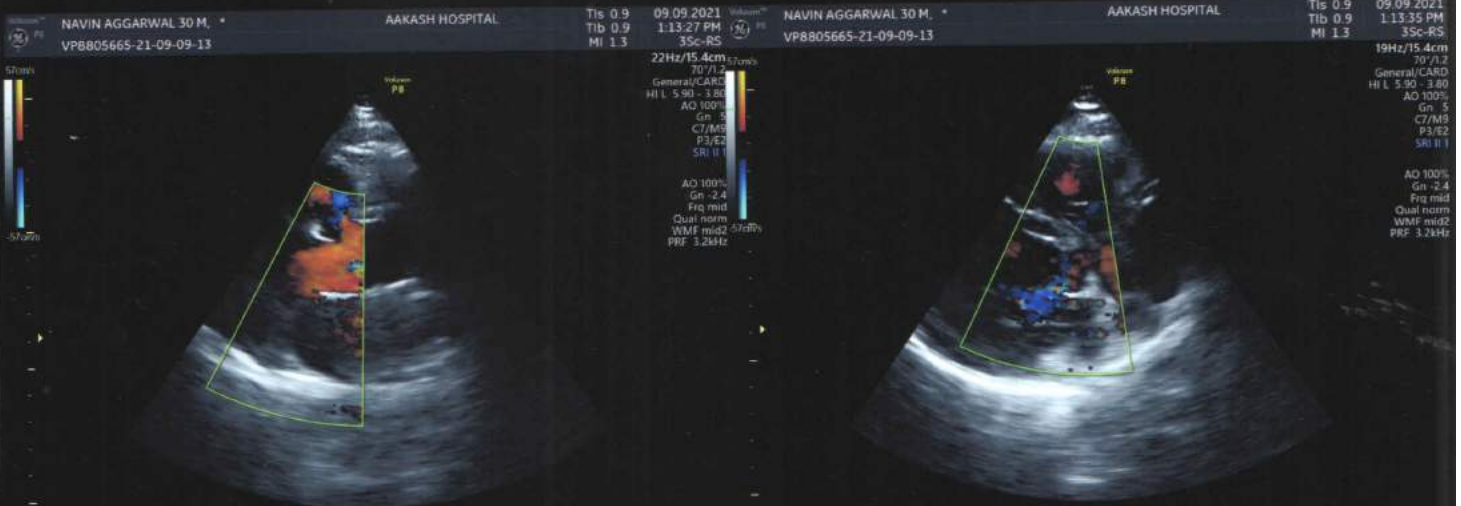
  
**DR. Rahul Trehan**  
MD, Medicine  
Consultant Physician & Cardiologist

### **AREA OF EXPERTISE**

- Interventions (Vascular & Nonvascular)
- FNAC
- Biopsy
- Drainages
- Doppler Scans
- 3D & 4D Scans
- Varicose Vein Laser Treatment



# AAKASH HOSPITAL, MALVIYA NAGAR



90/43, MALVIYA NAGAR, NEW DELHI-110017 #011-40501000



# Aakash Hospital™

Care with concern

(A unit of Dr. Gaba & Associates Medicare Pvt. Ltd.)



CIN No. U85110DL2004PTC125538

90/43, Malviya Nagar, New Delhi-110017  
#+91-11-40501000 (100 Lines), 9871027922  
info@aakashhospital.com, www.aakashhospital.com

<b>NAME: MR NAVEEN AGGARWAL</b>	<b>AGE: 36 YRS</b>	<b>SEX: MALE</b>
<b>REF.BY: DR NADEEM AHMED</b>	<b>DATE: 09.09.21</b>	

## ULTRASOUND WHOLE ABDOMEN

**LIVER:** - Normal sized, **with homogeneously increased echotexture**. No focal lesion seen. Intra hepatic biliary system not dilated. Intra hepatic veins radicles are normal.

**GALL BLADDER:** - Normal distension. Walls are normal. Calculus seen within the lumen measuring approx. 8.4 mm. Extra hepatic biliary system is not dilated. CBD - 5.2 mm.

**PANCREAS:** - Normal size and echotexture. No focal lesion seen. Pancreatic duct not dilated.

**SPLEEN:** - Normal size and echotexture. No focal lesion seen. Spleno-portal axis is normal.

**KIDNEYS:** - Both kidneys normally identified in the respective renal fossae. They demonstrate normal size and cortical echotexture. Corticomedullary differentiation well made out with a normal renal parenchymal thickness. No evidence of calculus or hydronephrosis seen on both side.

Right kidney measures approx. 10.0 cm in the long axis.  
Left kidney measures approx. 10.0 cm in the long axis.

**URINARY BLADDER:** - Moderately distended. No calculus or diverticulum is seen. Walls are normal. Both UV Junctions are normal.

**SEMINAL VESICLES:** - Shows normal sonographic appearances.

**PROSTATE:-** Is normal in size (9.2 cc). Echotexture is normal with no focal lesion. Outline is distinct with no contour bulge.

Retroperitoneum does not show any abnormally enlarged lymph nodes. No free peritoneal fluid or pleural effusion seen. Bowel loops are unremarkable. Both iliac fossae are normal. *Colon is fecal loaded.*

### IMPRESSION:

- **Grade II Fatty infiltration of Liver. Advice LFT correlation.**
- **Cholelithiasis. No E/O wall edema. CBD is not dilated.**

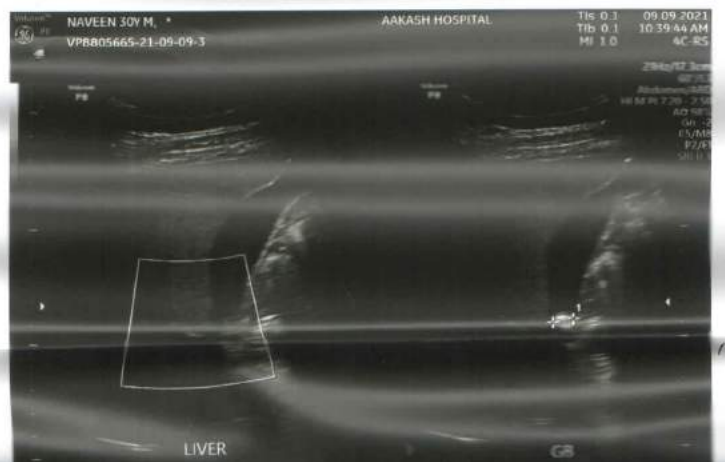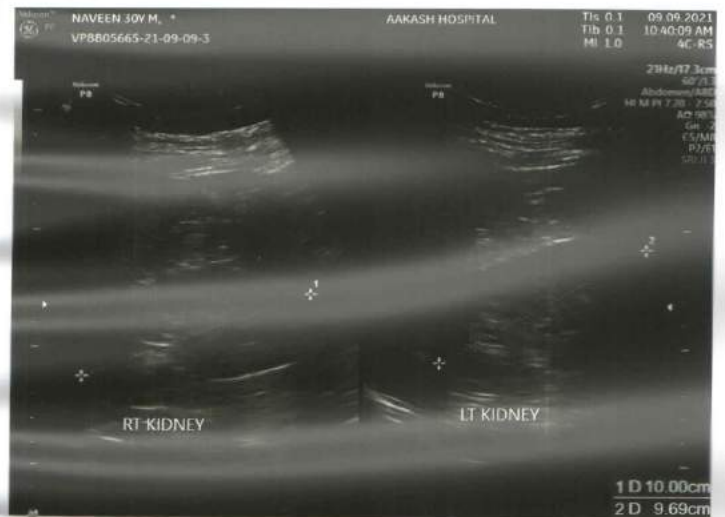
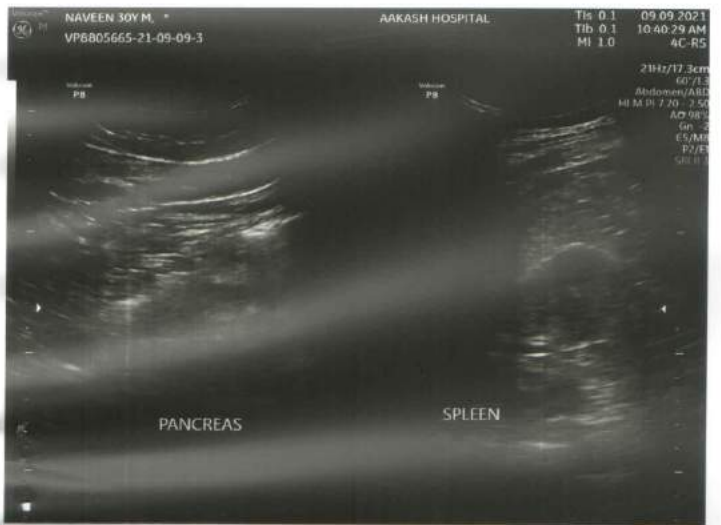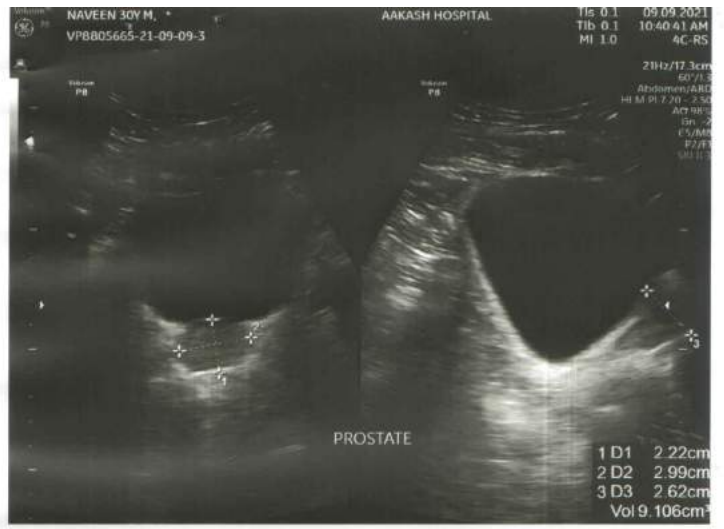
*Kindly correlate clinically.*

**DR.SALSABEEL.S**  
**DMRD.DNB(RADIOLOGY)**  
**DMC-35954**

### AREA OF EXPERTISE

- Interventions (Vascular & Nonvascular)
- FNAC
- Biopsy
- Drainages
- Doppler Scans
- 3D & 4D Scans
- Varicose Vein Laser Treatment







# Aakash Hospital™

Care with Concern

(A unit of Dr. Gaba & Associates Medicare Pvt. Ltd.)



90/43, Malviya Nagar, New Delhi-110017 #011 40501000 (100 Lines), 9871027922  
info@aakashhospital.com, www.aakashhospital.com

Name of patient : <i>Mr. Navneen Agrawal</i>	Age : 30	M/F : F
Address :		
Consultant : <i>Dr. Seema Gupta</i>	Speciality : <i>Ophthalmol</i>	Date : <i>9/9/21</i>

Investigations :	Presenting Complaints:	Provisional Diagnosis																								
<p>Systemic Examination :</p> <ul style="list-style-type: none"> <li>• Followup/Next visit</li> <li>• Diet / Nutrition Explained</li> <li>• Preventive Steps Explained</li> <li>• Prognosis Explained</li> </ul>	<p>Present History :</p> <p>Past History :</p> <p>Family History :</p> <p>H/o any Allergy :</p> <p>Vitals :</p> <p>BP :</p> <p>Pulse :</p> <p>Temp :</p> <p>Pain Scale (0-10)</p> <p>Wt/Ht (if required)</p> <p>Immunization</p>	<p><b>Rx</b></p> <p><i>for medical Examination</i></p> <table> <tr> <td></td> <td>RE</td> <td>LE</td> </tr> <tr> <td>vision</td> <td>6/60</td> <td>6/60</td> </tr> <tr> <td>distance</td> <td></td> <td></td> </tr> <tr> <td>with glasses -</td> <td>6/6</td> <td>6/6</td> </tr> <tr> <td>Ref.</td> <td>-4.0 Dm</td> <td>-3.25 Dm</td> </tr> <tr> <td>near.</td> <td>NB</td> <td>NB</td> </tr> <tr> <td>colour vision</td> <td>WNL</td> <td>WNL</td> </tr> <tr> <td>fundus - (undil)</td> <td>WNL</td> <td>WNL</td> </tr> </table> <p>Signature : <i>Seema Gupta</i></p> <p>Dr. Seema Gupta MBBS, DOMS Ophthalmic Eye Surgeon Dmc Reg. No. - 45002 981-9818293877</p> <p>Date/Time :</p>		RE	LE	vision	6/60	6/60	distance			with glasses -	6/6	6/6	Ref.	-4.0 Dm	-3.25 Dm	near.	NB	NB	colour vision	WNL	WNL	fundus - (undil)	WNL	WNL
	RE	LE																								
vision	6/60	6/60																								
distance																										
with glasses -	6/6	6/6																								
Ref.	-4.0 Dm	-3.25 Dm																								
near.	NB	NB																								
colour vision	WNL	WNL																								
fundus - (undil)	WNL	WNL																								

In case of emergency contact Duty Doctor,  
Aakash Hospital Ph. : 40501000, #9818166605

If you want HOME VISIT for Doctor/Nurse/Injection/Dressing/  
Blood Sample Collection , Please call : 011 40501000, 9910086605



# Aakash Hospital™

Care with Concern

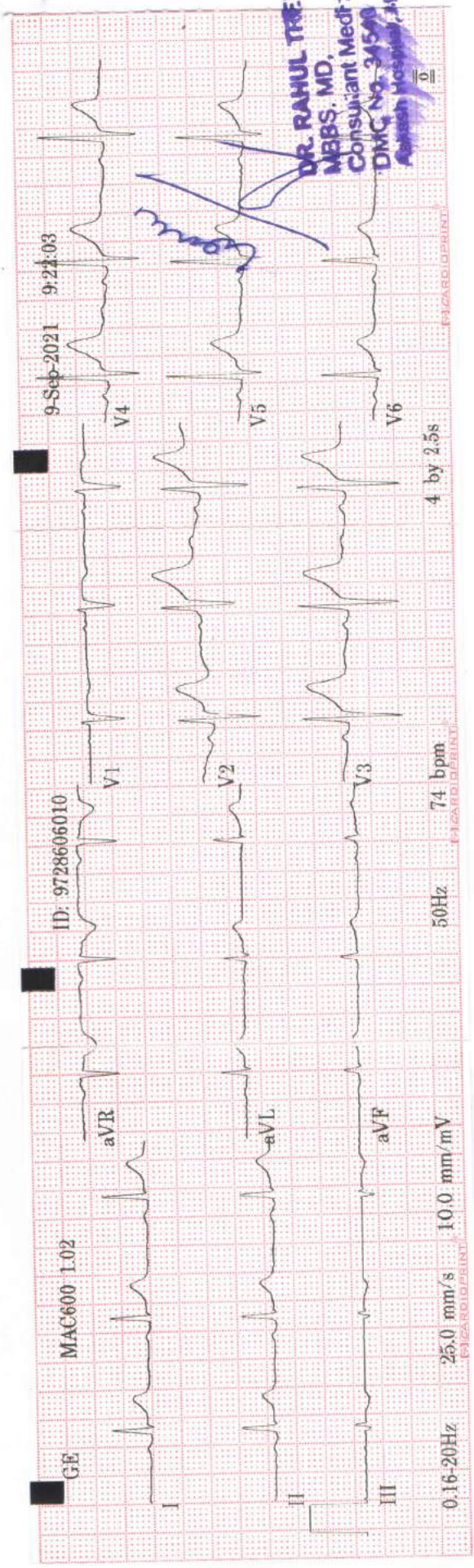
(A unit of Dr. Gaba & Associates Medicare Pvt. Ltd.)



90/43, Malviya Nagar, New Delhi-110017 #011 40501000 (100 Lines), 9871027922  
info@aakashhospital.com, www.aakashhospital.com

Name of patient : <i>Naveen Aggarwal</i>	Age : <i>30</i>	M/F : <i>M</i>
Address :		
Consultant : <i>Dr. Mala Bhattacharya</i>	Speciality : <i>ENT</i>	Date : <i>9/9/21</i>

Investigations :	Presenting Complaints:	Provisional Diagnosis
<p>Systemic Examination :</p> <p><i>CPH - Nose blocked</i> <i>D&amp;T.</i> <i>Ears - dgn'</i> <i>throat</i> <i>Chest clear</i></p> <ul style="list-style-type: none"> <li>• Followup/Next visit</li> <li>• Diet / Nutrition Explained</li> <li>• Preventive Steps Explained</li> <li>• Prognosis Explained</li> </ul>	<p><i>Itchy nose</i></p> <p><i>Dgn'</i></p> <p>Present History :</p> <p>Past History :</p> <p>Family History :</p> <p>H/o any Allergy :</p> <p>Vitals :</p> <p>BP :</p> <p>Pulse :</p> <p>Temp :</p> <p>Pain Scale (0-10)</p> <p>Wt/Ht (if required)</p> <p>Immunization</p>	<p><b>Rx</b></p> <p><i>6</i></p> <p><i>①</i> <i>SULFA 2 - 5W CAPSUL</i></p> <hr/> <p><i>Dn'</i></p> <p><i>NCCT PNE</i></p> <p><i>Crossed ear</i></p> <p><i>Serum IgE level</i></p> <p><i>Mishra</i></p> <p><i>09/09/21</i></p> <p><b>Dr. Mala Bhattacharjee</b> MBBS, M.S. (ENT) Sr. Consultant (ENT &amp; Head Neck Surgeon) DMC - 16234</p>
		Signature : _____ Date/Time : _____



DR. RAHUL TREHAN  
MBBS, MD.  
Consultant Medicine  
DMC No. 34540  
Aakash Hospital, Ambala

MAC600 1.02 12SL™ v239

ID: 9728606010	Male	Vent. rate	74 bpm
30 years		QRS duration	78 ms
		QT/QTc	362/401 ms
		PR interval	132 ms
		P duration	86 ms
		RR interval	810 ms
		P-R-T axes	38 30 17