



Swaminarayan Nagar, Off Mumbai-Agra Highway,
Panchvati, Nashik - 422 003.

+91- 253 - 2510250 / 350 / 450 / 550 / 750

apollonashik@apollohospitals.com

www.askapollo.com

QFAHN/BILL/003/V1



Apollo
HOSPITALS
NASHIK

Name : Mr. PRASAD B KALE (35 /M)

Date : 08/11/2022

Address : NASHIK, NASHIK, NASHIK, MAHARASHTRA, INDIA

Examined by:

UHID : MHN1.0000127856

Package : MediWheel Full Body Health Checkup Male Below 40
Package

AHC No : NSKAH28205



CHIEF COMPLAINTS

For corporate health checkup
No specific complaints

PRESENT KNOWN ILLNESS

Present known illness

No history of : - Diabetes mellitus, Hypertension, Thyroid disorder, Heart disease, Stroke, Asthma, COPD, Cancer



DRUG ALLERGY

NO KNOWN ALLERGY

:08/11/2022



SYSTEMIC REVIEW

Cardiovascular system

- Nil Significant



Past medical history

Do you have any allergies? - No

Do you have any drug allergies? - No

Past medical history - nil significant

Covid 19 - Yes

- January-2021

Post detection (3 - No

Weeks)

Hospitalization for - No

Covid 19

Oxygen support - No



Surgical history

Surgical history - Nil

Immunization history

- Covid Dose1, Covid Dose2



Personal history

Marital status - Married

No. of children - 02

Diet - Vegetarian

Alcohol - does not consume alcohol

Smoking - No

Chews tobacco - No

Physical activity - Active

- level ground walking



Family history

Diabetes - father

Hypertension - father, mother

Coronary artery - none

disease

Cancer - None

Thyroid/other - sister

endocrine disorder

PHYSICAL EXAMINATION



General

General appearance - normal

Build - normal



H Swaminarayan Nagar, Off Mumbai-Agra Highway,
Panchvati, Nashik - 422 003.

+91- 253 - 2510250 / 350 / 450 / 550 / 750

apollonashik@apollohospitals.com

www.askapollo.com

QFAHN/BILL/003/V1



Name : Mr. PRASAD B KALE (35 /M)

UHID : MHN1.0000127856

Date : 08/11/2022

Package : MediWheel Full Body Health Checkup Male Below 40 Package

AHC No : NSKAH28205

Height - 171
Weight - 82.8
BMI - 28.32
Pallor - No
Oedema - no
Temperature - 97.4
SpO2 - 98

Cardiovascular system


Heart rate (Per minute) - 59
Rhythm - Regular
B.P. Supine -
Systolic(mm of Hg) - 120
Diastolic(mm of Hg) - 70
Heart sounds - S1S2+

Respiratory system

Breath sounds - Normal vesicular breath sounds

Abdomen

Organomegaly - No
Tenderness - No





H Swaminarayan Nagar, Off Mumbai-Agra Highway,
Panchvati, Nashik - 422 003.

+91- 253 - 2510250 / 350 / 450 / 550 / 750

apollonashik@apollohospitals.com

www.askapollo.com

QFAHN/BILL/003/V1



Apollo
HOSPITALS
NASHIK

Name : Mr. PRASAD B KALE (35 /M)

UHID : MHN1.0000127856

Date : 08/11/2022

Package : MediWheel Full Body Health Checkup Male Below 40 Package

AHC No : NSKAH28205

C B C WITH ESR (AUTOMATION + STANDARD METHOD)

Test Name	Result	Unit	Level	Range
Hemoglobin	14.9	g/dl	●	13.0-18.0
Haematocrit	46.5	%	●	39.0-54.0
RBC COUNT	5.8	Million/ ul	●	4.2-6.5
MCV	80.7	fl	●	75.0-95.0
MCH	25.9 *	pg	●	26.0-32.0
MCHC	32.1	g/dl	●	31.0-36.0
WBC	16	%	●	11-16
Platelet Count(Optical/Impedance)	240	10 ³ /m ³	●	140-440
TLC Count	8.7	10 ³ /m ³	●	4.0-11.0
Neutrophils	58	%	●	45-75
Lymphocytes	35	%	●	20-45
Eosinophils	02	%	●	1-6
Monocytes	05	%	●	1-10
ERYTHROCYTE SEDIMENTATION RATE (ESR)	6.8	mm/1st hr	●	0-10

ALKALINE PHOSPHATASE - SERUM/PLASMA	61	U/L	●	0-100
AST (SGOT) - SERUM	22	U/L	●	15-37
BILIRUBIN, TOTAL - SERUM	0.5	mg/dL	●	0.0-1.0

LIPID PROFILE TEST (PACKAGE)

Test Name	Result	Unit	Level	Range
Total Cholesterol	179	mg/dL	●	0-200

CREATININE - SERUM / PLASMA

Test Name	Result	Unit	Level	Range
CREATININE - SERUM / PLASMA	0.8	mg/dL	●	0.8-1.3

LIVER FUNCTION TEST (PACKAGE)

Test Name	Result	Unit	Level	Range
GGTP: GAMMA GLUTAMYL TRANSPEPTIDASE - SERUM	22	U/L	●	0-50

GLUCOSE - SERUM / PLASMA (FASTING)

Test Name	Result	Unit	Level	Range
Glucose - Plasma (Fasting)	89	mg/dL	●	70-100
URINE GLUCOSE(FASTING): (Strip Method)	Nil			

BLOOD GROUPING AND TYPING (ABO and Rh)

Test Name	Result	Unit	Level	Range
Group:	O			
Rh (D) Type:	POSITIVE			

LIVER FUNCTION TEST (PACKAGE)

Test Name	Result	Unit	Level	Range
ALT(SGPT) - SERUM / PLASMA	25 *	U/L	●	30-65
ALBUMIN - SERUM	4.1	g/dL	●	3.5-5
GLOBULIN - SERUM: (Calculated)	3.5	g/dL	●	1.8-3.6
ALBUMIN:GLOBULIN - SERUM(RATIO) (Calculated)	1.2		●	1.1-1.8

GLUCOSE - SERUM / PLASMA (POST PRANDIAL)

Test Name	Result	Unit	Level	Range
Glucose - Plasma (POST PRANDIAL)	95	mg/dL	●	70-140
URINE GLUCOSE(POST PRANDIAL):(Strip Method)	Nil			

● Within Normal Range ● Borderline High/Low ● Out of Range



H Swaminarayan Nagar, Off Mumbai-Agra Highway,
Panchvati, Nashik - 422 003.

+91- 253 - 2510250 / 350 / 450 / 550 / 750

apollonashik@apollohospitals.com

www.askapollo.com

QFAHN/BILL/003/V1



Name : Mr. PRASAD B KALE (35 /M)

UHID : MHN1.0000127856

Date : 08/11/2022

Package : MediWheel Full Body Health Checkup Male Below 40 Package

AHC No : NSKAH28205

LIPID PROFILE TEST (PACKAGE)

Test Name	Result	Unit	Level	Range
HDL CHOLESTEROL - SERUM / PLASMA	54	mg/dL	●	40-60
TOTAL CHOLESTEROL/HDL CHOLESTEROL RATIO(Calculated)	3.3		●	0.0-4.5

LDL Cholesterol (Direct LDL) 127 mg/dL

Test Name	Result	Unit	Level	Range
BILIRUBIN CONJUGATED (DIRECT) - SERUM	0.1	mg/dL	●	0.0-0.3
BILIRUBIN UNCONJUGATED - SERUM(Calculated)	0.4	mg/dL	●	0.0-0.7

CARDIAC STRESS TEST - (TMT)

ECG

ULTRASOUND - WHOLE ABDOMEN

No significant abnormality is detected.
No urolithiasis.

X-RAY CHEST PA

No significant abnormality is detected.

INVESTIGATIONS NOT DONE / NOT YET REPORTED / NOT PART OF PACKAGE(LAB,RADIOLOGY & CARDIOLOGY)

LIVER FUNCTION TEST (PACKAGE)

Test Name	Result	Unit	Level	Range
PROTEIN, TOTAL - SERUM / PLASMA	7.6	g/dL	●	6.4-8.2
PROTEIN, TOTAL - SERUM / PLASMA	7.6	g/dL	●	6.4-8.2

Haematology

STOOL ROUTINE

THYROID PROFILE - I(T3,T4 AND TSH)

Test Name	Result	Unit	Level	Range
TOTAL T3: TRI IODOTHYRONINE - SERUM	121	ng/dL	●	Healthy Adults: 69 - 215
TOTAL T4: THYROXINE - SERUM	9.7	µg/dL	●	Healthy Adults:5.2-12.7

LIPID PROFILE TEST (PACKAGE)

Test Name	Result	Unit	Level	Range
Triglycerides - Serum	75	mg/dL	●	0-150

THYROID PROFILE - I(T3,T4 AND TSH)

Test Name	Result	Unit	Level	Range
TSH: THYROID STIMULATING HORMONE - SERUM	2.1	uIU/mL	●	Euthyroid: 0.3 - 4.5 Hypothyroid: 7.1 - >75

URIC ACID - SERUM

Test Name	Result	Unit	Level	Range
URIC ACID - SERUM	7.3 *	mg/dL	●	3.5-7.2

LIVER FUNCTION TEST (PACKAGE)

● Within Normal Range ● Borderline High/Low ● Out of Range



H Swaminarayan Nagar, Off Mumbai-Agra Highway,
Panchvati, Nashik - 422 003.

+91- 253 - 2510250 / 350 / 450 / 550 / 750

apollonashik@apollohospitals.com

www.askapollo.com

QFAHN/BILL/003/V1



Name : Mr. PRASAD B KALE (35 /M)

UHID : MHN1.0000127856

Date : 08/11/2022

Package : MediWheel Full Body Health Checkup Male Below 40 Package

AHC No : NSKAH28205

Printed By :

AHC Physician / Consultant Internal Medicine



Note :- The Health Check-up examinations and routine investigations have certain limitations and may not be able to detect all the diseases. Any new or persisting symptoms should be brought to the attention of the Consulting Physician. Additional tests, consultations and follow up may be required in some cases.



H Swaminarayan Nagar, Off Mumbai-Agra Highway,
Panchvati, Nashik - 422 003.
+91- 253 - 2510250 / 350 / 450 / 550 / 750
apollonashik@apollohospitals.com
www.askapollo.com

QFAHN/BILL/003/V1



Screening Echocardiography Report


Name: - Mr. PRASAD B KALE
UHID No: - MHN1.0000127856
Referred by: -Dr. Nirmal Kolte
Echo window: - Good

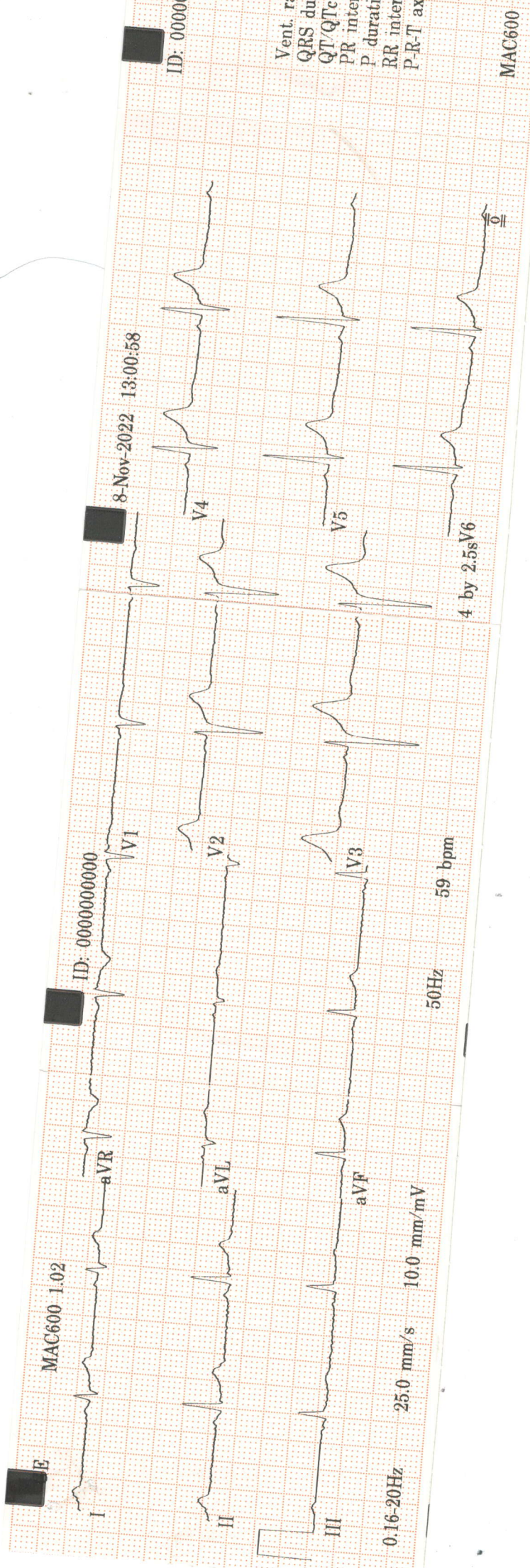
Age/Sex: 35/M
DATE: 08/11/2022
Echo No: -31093

Normal all rest of valves and chambers.
Normal LV systolic function. No RWMA at rest.
AO/LA= 29 mm/ 37 mm, LVIDd/LVIDs= 49 mm/ 31 mm, IVS/PW= 10 mm/ 10 mm.
No PAH.
No Clot/ Vegetation/Pericardial effusion.
No Coarctation.

Impression: -

Normal all rest of valves and chambers.
Normal LV systolic function. No RWMA at rest.
No PAH.
No clot/ vegetation/pericardial effusion.
No Coarctation.


DR.Nirmal Kolte.



ID: 000000

Vent. ra
QRS dur
QT/QTc
PR inter
p duratio
RR inter
P-R-T axe

MAC600 1

MAC600 1.02

ID: 0000000000

8-Nov-2022 13:00:58

0.16-20Hz 25.0 mm/s 10.0 mm/mV

50Hz 59 bpm

4 by 2.5s V6



Swaminarayan Nagar, Off Mumbai-Agra Highway,
Panchvati, Nashik - 422 003.

+91- 253 - 2510250 / 350 / 450 / 550 / 750

apollonashik@apollohospitals.com

www.askapollo.com

QFAHN/BILL/003/V1



MD (Radiology)

Patient Details : Mr. PRASAD B KALE | Male | 35Yr 0Mth 0Days

UHID : MHN1.0000127856 **Patient Location:** AHC

Patient Identifier: NSKAH28205



DRN : 222026945 **Completed on :** 08-NOV-2022 12:20

Ref Doctor : Dr. Rajashri Dhongade

ULTRASOUND - WHOLE ABDOMEN

LIVER : Normal in size. Echotexture is uniform and normal.
No I.H.B.D./ focal lesions.

PORTAL VEIN: Normal in size.

GALL BLADDER: Well distended with normal walls and lumen.
No calculi/pericholecystic fluid.

COMMON BILE DUCT: Normal in size.

PANCREAS : Visualized portion of head and body of pancreas appears normal in size and echotexture. Rest of the pancreas is obscured due to bowel gases.

AORTA, IVC and para aortic areas are normal.

SPLEEN : Normal in size and echotexture.

KIDNEYS: Both kidneys are normal in site, size and echotexture.

No evidence of calculi/ hydronephrosis.

Right kidney measures: 10.5 x 4.4 cm.

Left kidney measures : 11.9 x 5.5 cm.

URINARY BLADDER: Well distended with normal walls.

No evidence of calculi/ growth/ diverticula .

PROSTATE : Normal in size with homogenous echogenicity. No evidence of calcification within.

Prostate measures : 14.4gms.



H Swaminarayan Nagar, Off Mumbai-Agra Highway,
Panchvati, Nashik - 422 003.

+91- 253 - 2510250 / 350 / 450 / 550 / 750

apollonashik@apollohospitals.com

www.askapollo.com

QFAHN/BILL/003/V1



Apollo
HOSPITALS
NASHIK

Mr. PRASAD B KALE

MHN1.0000127856

NSKAH28205

ULTRASOUND - WHOLE ABDOMEN

Seminal vesicles are normal.

Visualized bowel loops appear grossly normal.

No evidence of any free fluid in the peritoneal cavity.

Impression

No significant abnormality is detected.

No urolithiasis.

--- END OF THE REPORT ---

Kunal Kalyanrao Patil

Consultant - MD (Radiodiagnosis)

Apollo
HOSPITALS
NASHIK



H Swaminarayan Nagar, Off Mumbai-Agra Highway,
Panchvati, Nashik - 422 003.

+91- 253 - 2510250 / 350 / 450 / 550 / 750

apollonashik@apollohospitals.com

www.askapollo.com

QFAHN/BILL/003/V1



MD (Radiology)

Patient Details : Mr. PRASAD B KALE | Male | 35Yr 0Mth 0Days

UHID : MHN1.0000127856 Patient Location: AHC

Patient Identifier: NSKAH28205



DRN : 122043904 Completed on : 08-NOV-2022 11:39

Ref Doctor : Dr. Rajashri Dhongade

X-RAY CHEST PA

Both lung fields are clear.

Both hila are normal in size and position.

Costophrenic and cardiophrenic angles are clear.

Cardiac size and contour are within normal limits.

Rib cage is normal.

Soft tissues are normal.

Impression

No significant abnormality is detected.

--- END OF THE REPORT ---

Kunal Kalyanrao Patil

Consultant - MD (Radiodiagnosis)



H Swaminarayan Nagar, Off Mumbai-Agra Highway,
Panchvati, Nashik - 422 003.

+91- 253 - 2510250 / 350 / 450 / 550 / 750

apollonashik@apollohospitals.com

www.askapollo.com

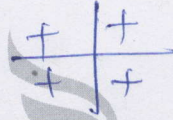
QFAHN/BJLL/003/V1



8/11/22

For,
Prasad Kale

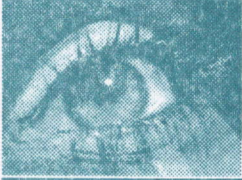Stains



Adv. scaling.



Sanj



OPHTHALMOLOGY



Name : Mr. Prasad Kale
 Occupation : _____
 Age : 35 Sex : Male Female S/M/W/D
 Address : Nsk
 Tel. No. _____

Date 8/11/22 UNIT _____
 Room No. _____ Out Patient
 Ref. Physician : _____
 Copies to : _____

REPORT ON OPHTHALMIC EXAMINATION

HISTORY : —

PRESENT COMPLAINT : —

PAST HISTORY : DM / HTN / ALLERGY

ON EXAMINATION

VISION :

RE 6/6 LE 6/12

	RIGHT				LEFT			
PGP	SPH	CYL	AXIS	VA	SPH	CYL	AXIS	VA
DIST	—————				—————			
NEAR	—————				—————			

AR / Retinoscopy :

RIGHT			LEFT		
SPH	CYL	AXIS	SPH	CYL	AXIS
<u>+2</u>	<u>0.75</u>	<u>34</u>	<u>+1.5</u>	<u>0.5</u>	<u>180</u>


Refraction or Acceptance :

	RIGHT				LEFT			
	SPH	CYL	AXIS	VA	SPH	CYL	AXIS	VA
DIST	<u>R</u>	<u>-</u>	<u>-</u>	<u>6/6</u>	<u>0.75</u>	<u>-</u>	<u>-</u>	<u>6/6</u>
NEAR	—————				—————			


Handwritten signature/initials

CONSULTANT OPTOMETRIST

Anterior Segment :



Fundus :



Diagnosis :

① Astigmatism

Advise / Rx:

Tcan dops etc

②

CONSULTANT OPHTHALMOLOGIST