



भारत सरकार
GOVERNMENT OF INDIA



रंजीत पवार
Ranjit Pawar
जन्म तिथि/DOB: 12/02/1978
पुरुष/ MALE
Mobile No: 9289618971

5064 9217 5482
VID . 9155 4425 2982 6701

मेरा आधार, मेरी पहचान

Downloaded on: 11/05/2019

पता: C/O राज प्रकाश पवार, ए-8/30, थर्ड फ्लोर, रोहिणी सेक्टर-8, उत्तर दिल्ली, 110089

Address: C/O Raj Prakash Pawar, A-8/30, Third Floor, A-Block, Pocket-8, Rohini Sector 15, North West Delhi, Delhi - 110089

5064 9217 5482

www.help@uidai.gov.in www.uidai.gov.in P.O. Box No. 1947, Bengaluru-560 001

Generation Date: 28/04/2019

भारतीय पहचान प्रमाणिका

भारत सरकार


Dr. NITIN AGARWAL
MBBS, MD
Regn. No. DMC-R-1436

ONEPLUS ULTRASOUND LAB
47, Harsh Vihar, Pitam Pura,
Delhi-110034
Ph. 011-42480101, 9599913051
E-mail: oneplusul@gmail.com



Dr. NITIN AGARWAL
MBBS, MD
Regn. No. DMC-R-1436

ONEPLUS ULTRASOUND LAB
47, Harsh Vihar, Pitam Pura,
Delhi-110034
Ph. 011-42480101, 9599913051
E-mail: oneplusul@gmail.com



ONEPLUS ULTRASOUND LAB

47, HARSH VIHAR, PITAMPURA, DELHI- 110034

Mr. RANJIT PAWAR
 ID : 1921
 Age : 44M
 Ref. by : MEDIVHEEL
 Indication1 :
 Indication2 :
 Indication3 :
 COMMENTS : Normal ECG.

Recorded : 24-3-2022 11:16
 HWM : 159/75
 Medication1 :
 Medication2 :
 Medication3 :

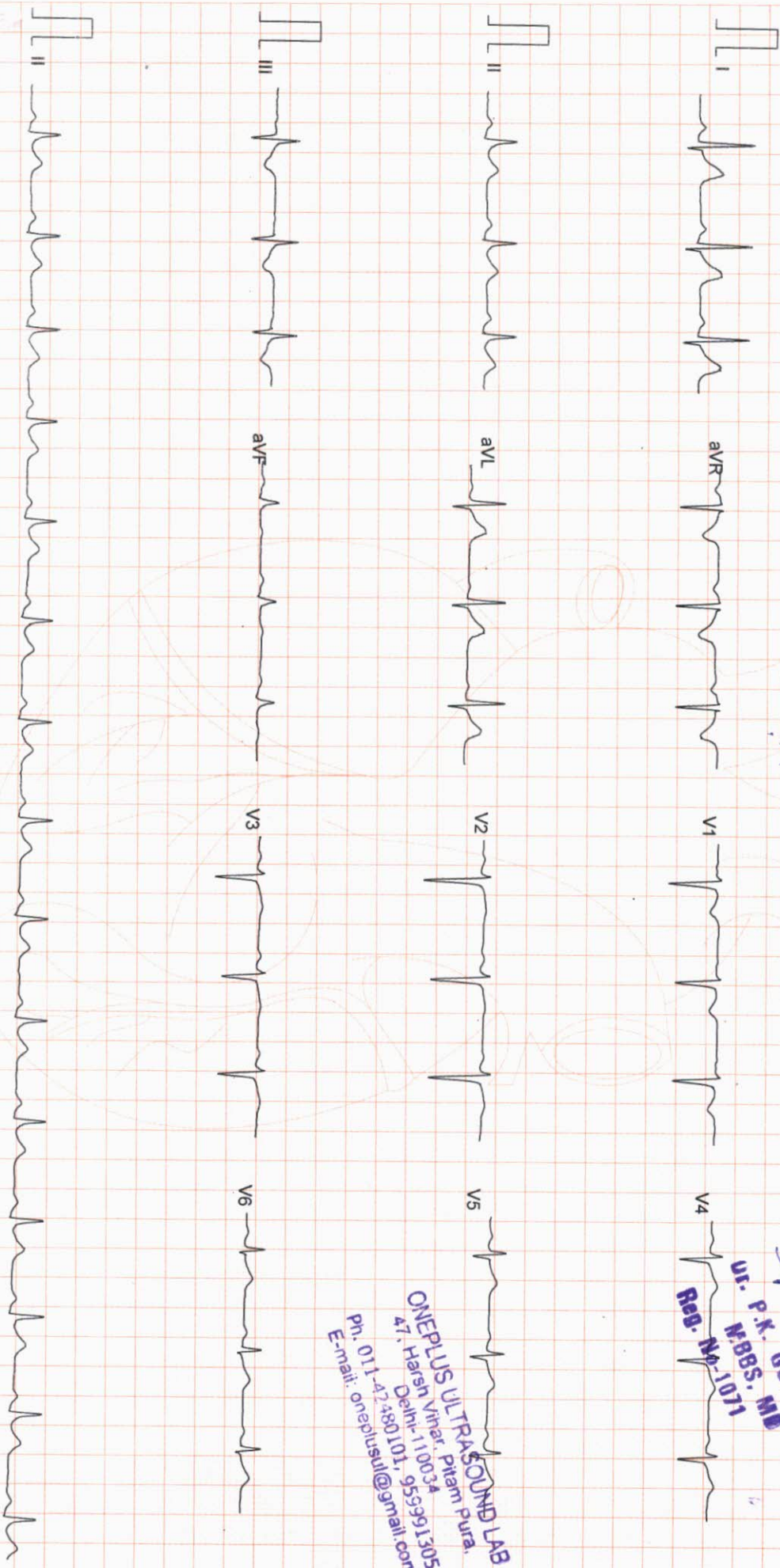
BPM : 90
 BP : 130/88
 P Axis : 34 deg
 QRS Axis : 21 deg
 T Axis : 2 deg

P duration : 83 msec
 PR duration : 140 msec
 QRS duration : 93 msec
 QT interval : 270 msec
 QTc interval : 322 msec
 Raw E.C.G. (Seq)

[Signature]

Unconfirmed Report Reviewed By:
 Cardiologist

[Signature]
Dr. P.K. GUPTA
M.BBS. MD
Reg. No-1071



ONEPLUS ULTRASOUND LAB
 Pitampura,
 47, Harsh Vihar, Pitampura,
 Delhi-110034
 Ph: 011-42480101, 9539913051
 E-mail: onepusul@gmail.com

ONEPLUS ULTRASOUND LAB

47, HARSH VIHAR PITAMPURA DELHI 110034

ID : 990
 HtWt : 159/75
 Recorded : 24-3-2022 11:18

TREADMILL TEST SUMMARY REPORT
 Protocol: BRUCE

Mr. RANJIT PAWAR
 Age/Sex : 44/M
 Ref. by : MEDWHEEL
 Indication1 :
 Indication2 :
 Indication3 :

History:
 Medication1 :
 Medication2 :
 Medication3 :

| PHASE | PHASE TIME | STAGE TIME | SPEED (Km./Hr.) | GRADE (%) | H.R. (BPM) | B.P. (mmHg) | RPP X100 | II | ST LEVEL (mm) V2 | V5 | METS |
|-----------|------------|------------|-----------------|-----------|------------|-------------|----------|-----|------------------|-----|-------|
| SUPINE | | | | | 92 | 130/88 | 119 | 1.0 | 0.7 | 0.8 | |
| STANDING | | | | | 90 | 130/88 | 117 | 1.1 | 0.7 | 0.8 | |
| STAGE 1 | 2:59 | 2:59 | 2.70 | 10.00 | 112 | 140/90 | 156 | 1.0 | 2.0 | 1.4 | 4.80 |
| STAGE 2 | 5:59 | 2:59 | 4.00 | 12.00 | 130 | 150/92 | 195 | 1.0 | 2.1 | 1.4 | 7.10 |
| STAGE 3 | 8:59 | 2:59 | 5.40 | 14.00 | 152 | 160/94 | 243 | 1.0 | 2.6 | 1.7 | 10.00 |
| PEAK EXER | 8:59 | 2:59 | | | 152 | 160/94 | 243 | 1.0 | 2.6 | 1.7 | |
| RECOVERY | 2:59 | 2:59 | 0.00 | 0.00 | 108 | 132/88 | 142 | 0.9 | 0.6 | 0.4 | 10.00 |

RESULTS

Exercise Duration 8:59 Minutes
 Max Heart Rate 152 bpm 86 % of target heart rate 176 bpm
 Max Blood Pressure 160/94 mmHg
 Max Work Load 10.00 METS
 Reason of Termination

IMPRESSIONS

Negative for ischaemic ECG


P.K. GUPTA
 Cardiologist, MBBS, MD
 Reg. No-1071



ONEPLUS ULTRASOUND LAB
 47, Harsh Vihar, Pitam Pura,
 Delhi-110034
 Ph. 011-42480101, 9599513051
 E-mail: oneplusul@gmail.com

ONEPLUS ULTRASOUND LAB

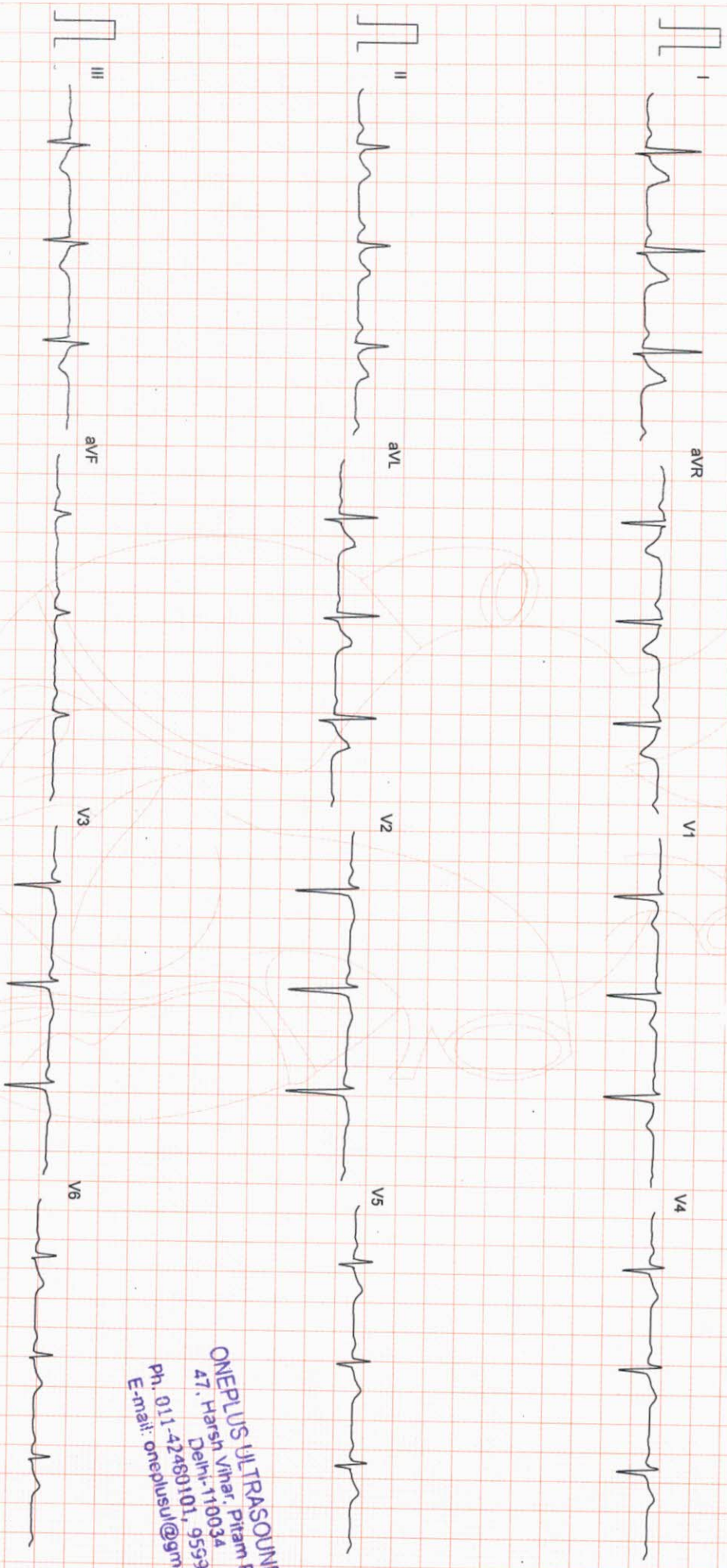
SUPINE
PRETEST

ST @ 10mm/mV
80ms PostJ

Mr. RANJIT PAWAR
I.D. : 990
AGE/SEX : 44/M
RECORDED : 24-3-2022 11:18

RATE : 92 BPM
B.P. : 130/88 mmHg

RAW E.C.G.



ONEPLUS ULTRASOUND LAB
47, Harsh Vihar, Pitam Pura,
Delhi-110034
Ph. 011-42460101, 9559913051
E-mail: oneplusul@gmail.com

Filtered

25mm/sec 10mm/mV

ARROW

CardiCom, INDIA Ph.:091-731-2620740, TeleFax:091-731-2431214

ONEPLUS ULTRASOUND LAB

STANDING
PRETEST

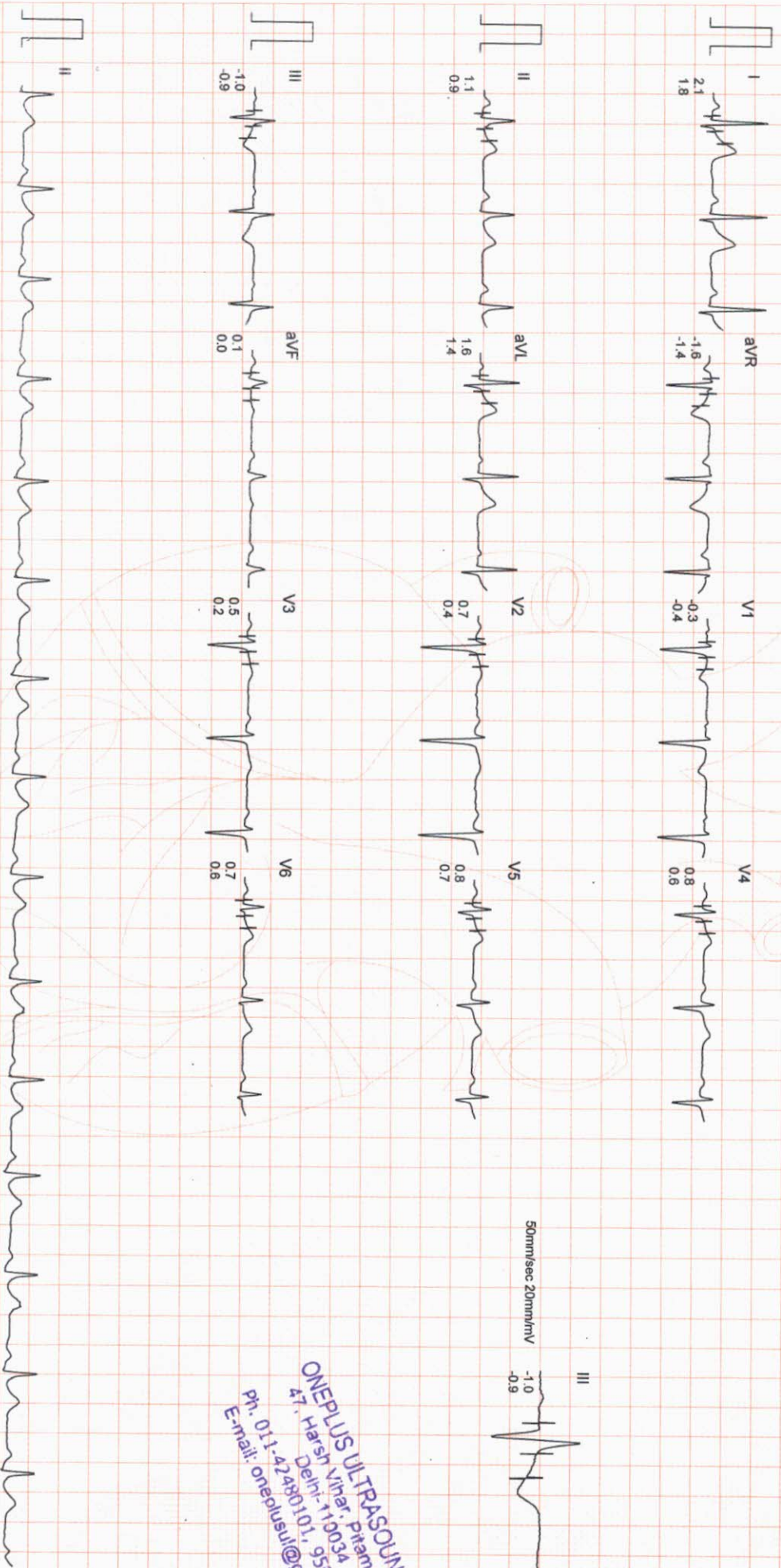
ST @ 10mm/mV
80ms PostJ

Mr. RANJIT PAWAR
I.D. : 990
AGE/SEX : 44/M

RATE : 90 BPM
B.P. : 130/88 mmHg

RECORDED : 24-3-2022 11:18

LINKED MEDIAN



ONEPLUS ULTRASOUND LAB
47, Harsh Vihar, Pitam Pura,
Delhi-110034
Ph. 011-42480101, 9559913051
E-mail: oneplusul@gmail.com

ONEPLUS ULTRASOUND LAB

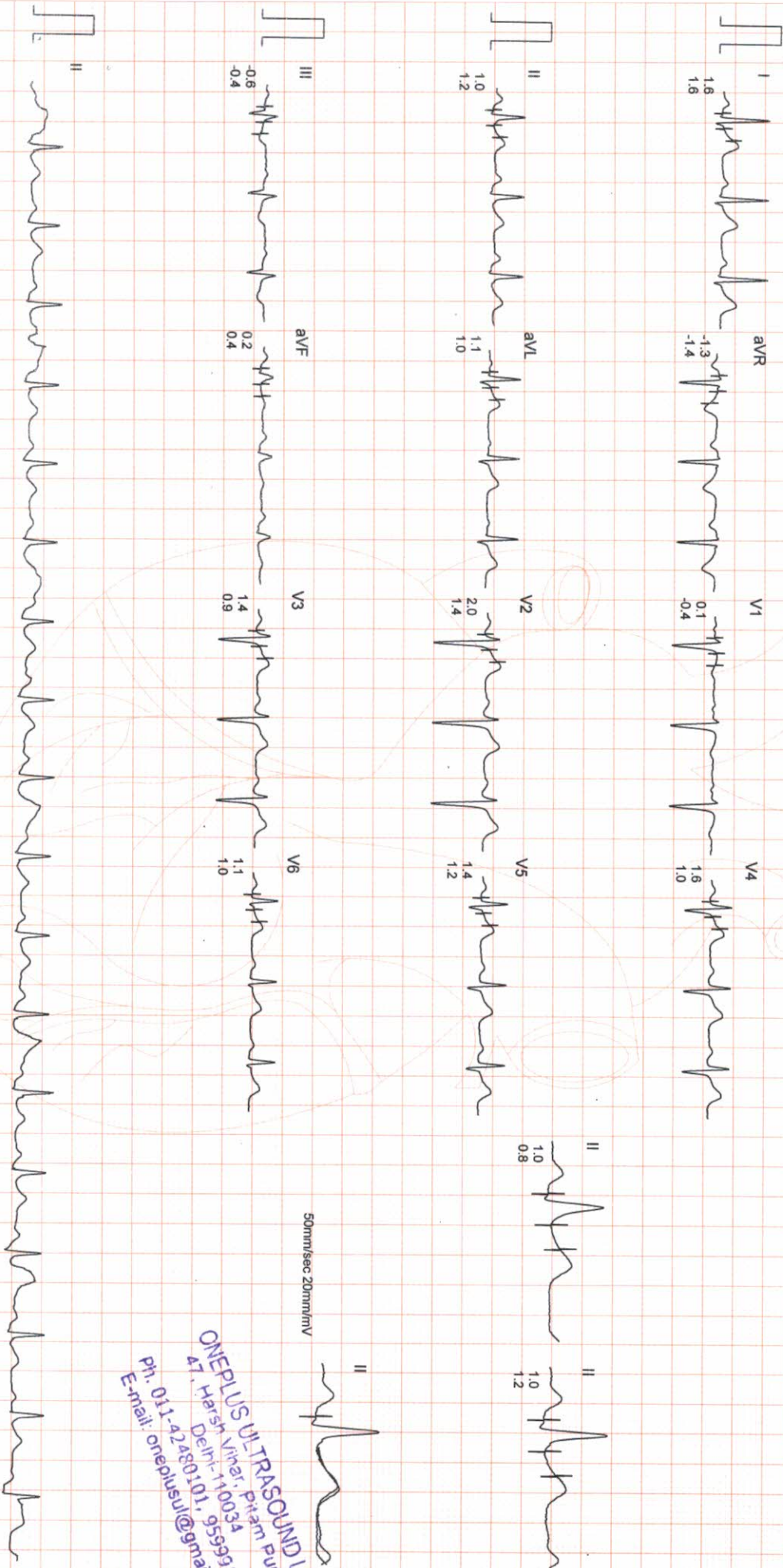
Mr. RANJIT PAWAR
I.D. : 990
AGE/SEX : 44/M
RECORDED : 24-3-2022 11:18

RATE : 112 BPM
B.P. : 140/90 mmHg

BRUCE
EXERCISE 1
PHASE TIME : 2:59
STAGE TIME : 2:59

ST @ 10mm/mV
80ms PostJ
SPEED : 2.7 Km./Hr.
GRADE : 10.0 %

LINKED MEDIAN



ONEPLUS ULTRASOUND LAB
47, Harsh Vihar, Pitam Pura,
Delhi-110034
Ph: 011-42280101, 9559913051
E-mail: oneplusul@gmail.com

ONEPLUS ULTRASOUND LAB

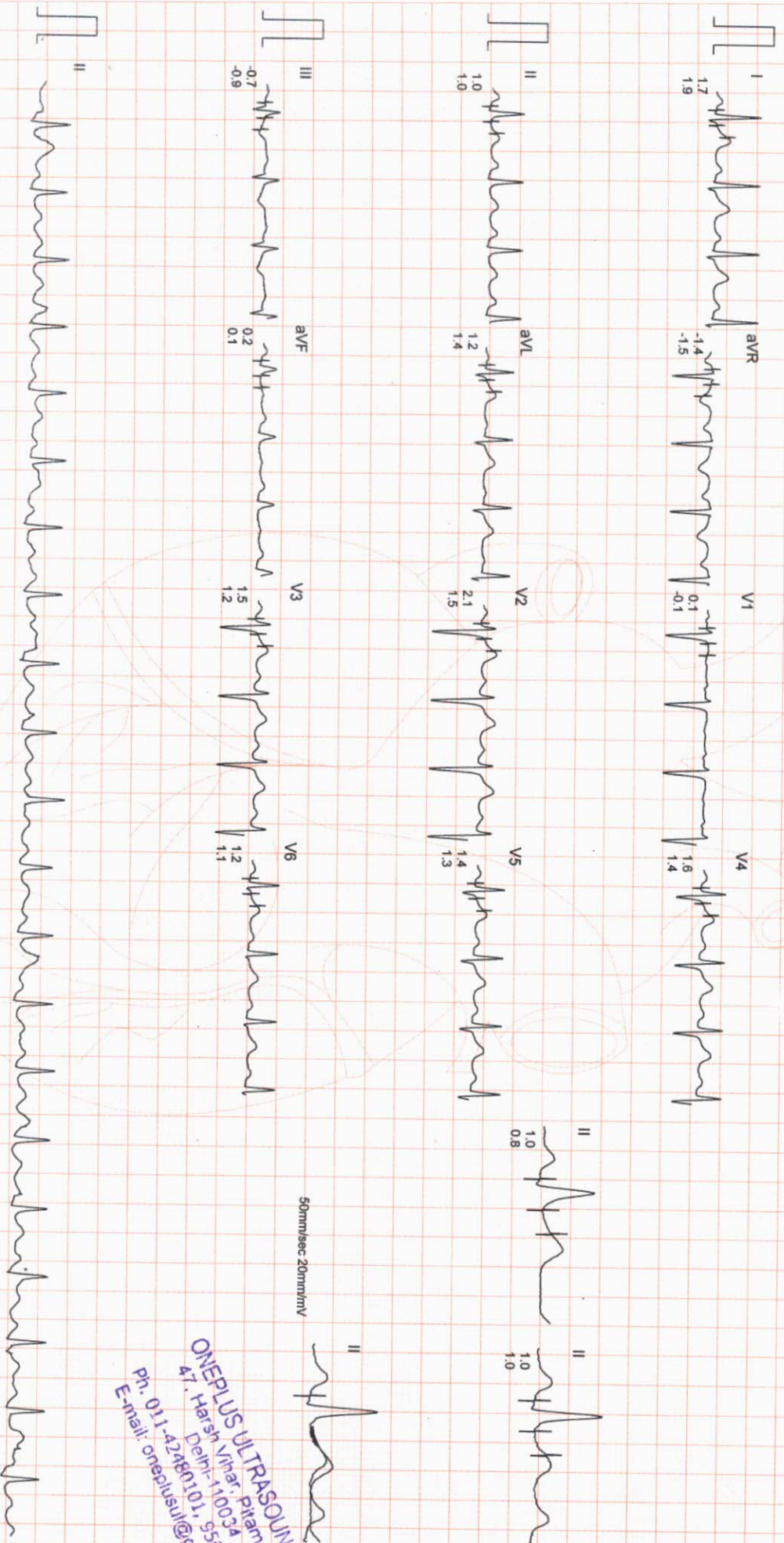
Mr. RANJIT PAWAR
I.D. : 990
AGE/SEX : 44/M
RECORDED : 24-3-2022 11:18

RATE : 130 BPM
B.P. : 150/92 mmHg

BRUCE
EXERCISE 2
PHASE TIME : 5:59
STAGE TIME : 2:59

ST @ 10mm/mV
80ms PostJ
SPEED : 4.0 Km./Hr.
GRADE : 12.0 %

LINKED MEDIAN



Filtered

Computer Corrected Baseline

25mm/sec 10mm/mV

50mm/sec 20mm/mV

ONEPLUS ULTRASOUND LAB
47, Harsh Vihar, Pitam Pura,
Delhi-110034
Ph. 011-42480101, 9599913051
E-mail: oneplusul@gmail.com

ONEPLUS ULTRASOUND LAB

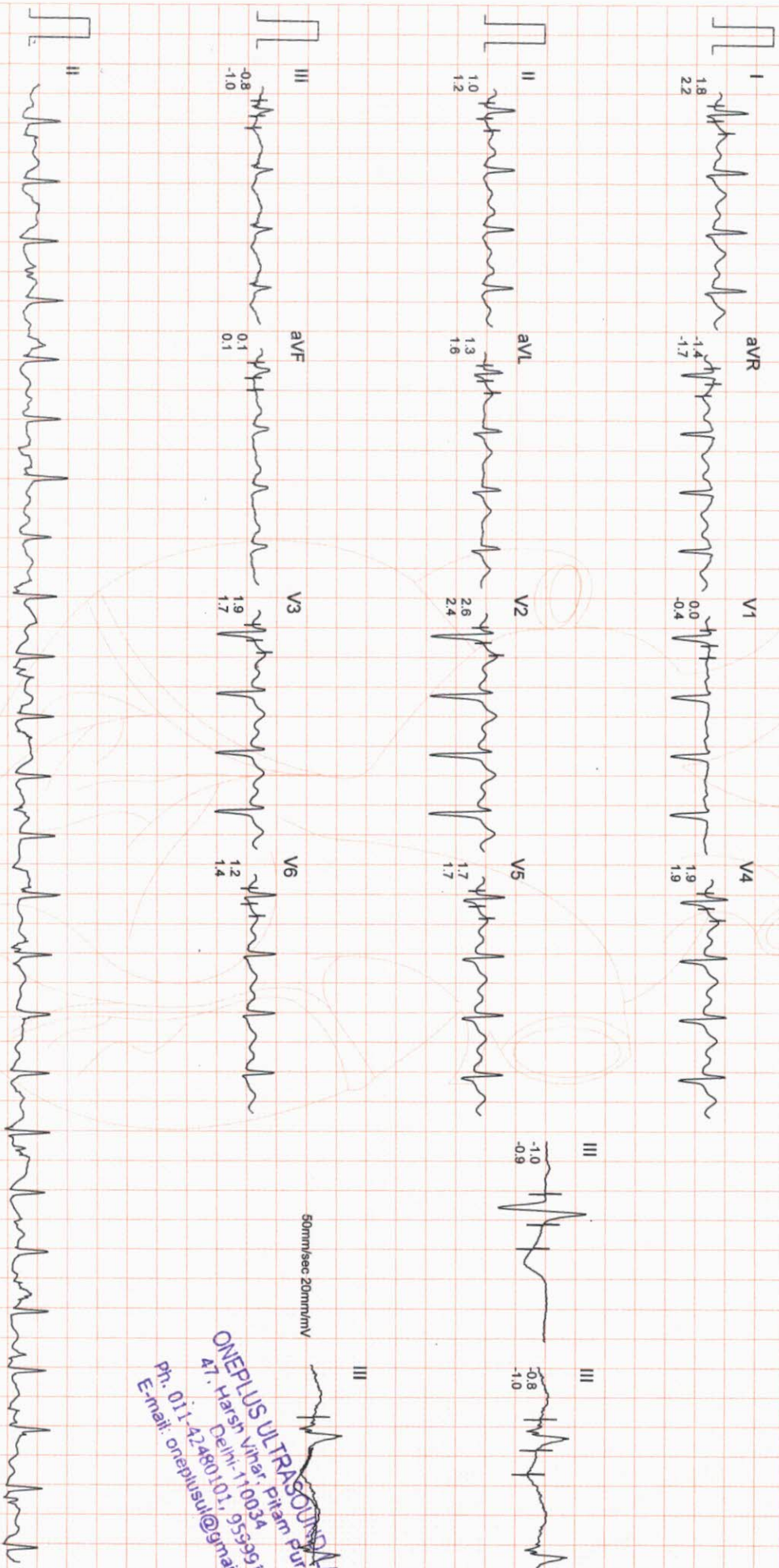
Mr. RANJIT PAWAR
 I.D. : 990
 AGE/SEX : 44/M
 RECORDED : 24-3-2022 11:18

RATE : 152 BPM
 B.P. : 160/94 mmHg

BRUCE
 EXERCISE 3
 PHASE TIME : 8:59
 STAGE TIME : 2:59

ST @ 10mm/mV
 80ms PostJ
 SPEED : 5.4 Km./Hr.
 GRADE : 14.0 %

LINKED MEDIAN



50mm/sec 20mm/mV

ONEPLUS ULTRASOUND LAB
 47, Harsh Vihar, Pitam Pura,
 Delhi-110034
 Ph. 011-42480101, 9559913051
 E-mail: oneplusul@gmail.com

ONEPLUS ULTRASOUND LAB

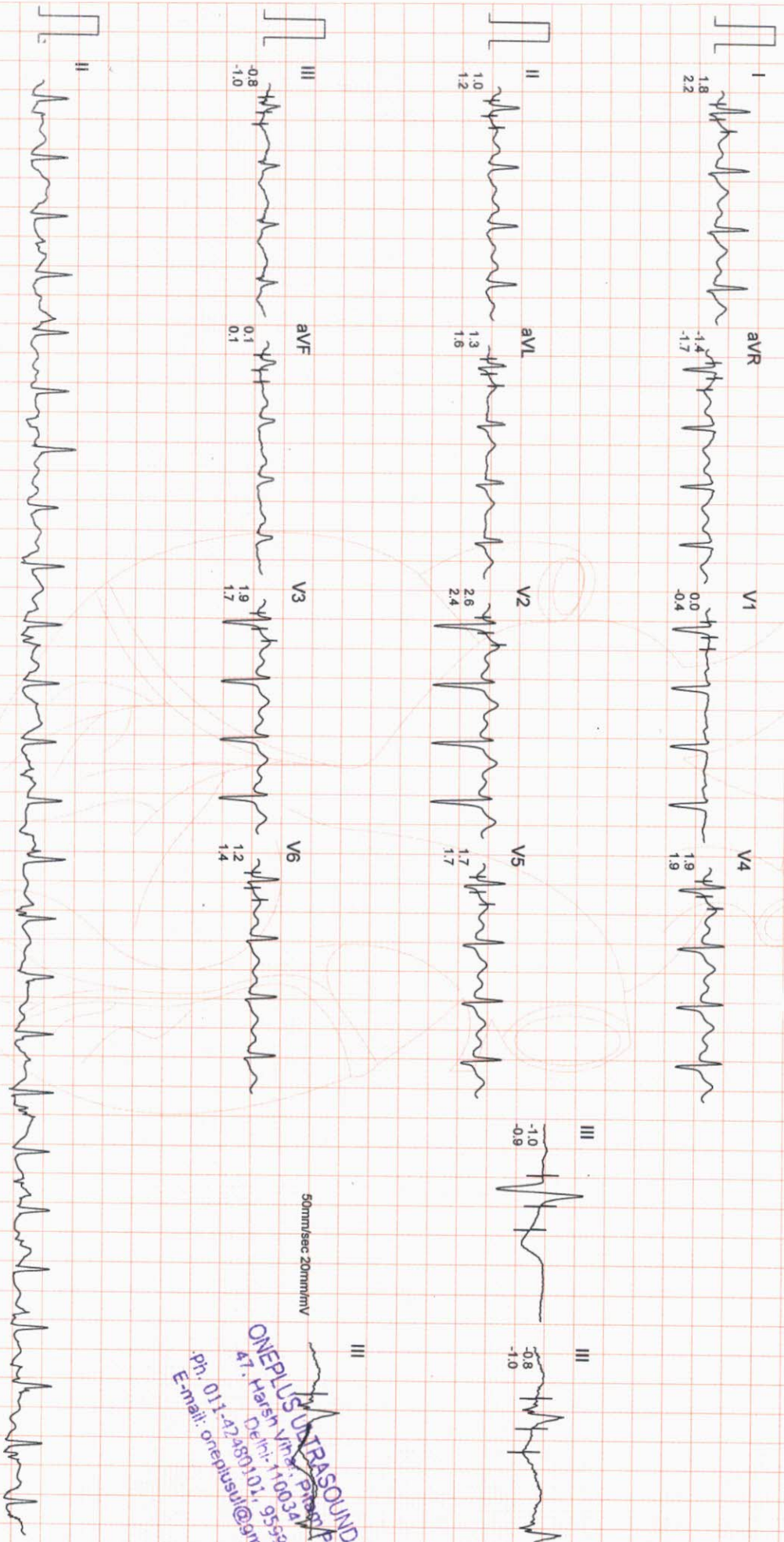
Mr. RANJIT PAWAR
 I.D. : 990
 AGE/SEX : 44/M
 RECORDED : 24-3-2022 11:18

RATE : 152 BPM
 B.P. : 160/94 mmHg

BRUCE
 PEAK EXERCISE
 PHASE TIME : 8:59
 STAGE TIME : 2:59

ST @ 10mm/mV
 80ms PostJ
 SPEED : 5.4 Km./Hr.
 GRADE : 14.0 %

LINKED MEDIAN



Filtered Computer Corrected Baseline 25mm/sec 10mm/mV

ONEPLUS ULTRASOUND LAB
 Dr. Harsh V. N. Bhat
 47, Harsh V. N. Bhat Pura,
 Delhi-110034
 Ph: 011-42468101, 9555912051
 E-mail: oneplusul@gmail.com

ONEPLUS ULTRASOUND LAB

BRUCE

RECOVERY

PHASE TIME : 2:59

ST @ 10mm/mV

80ms PostJ

SPEED : 0.0 Km./Hr.

GRADE : 0.0 %

M: RANJIT PAWAR

ID : 990

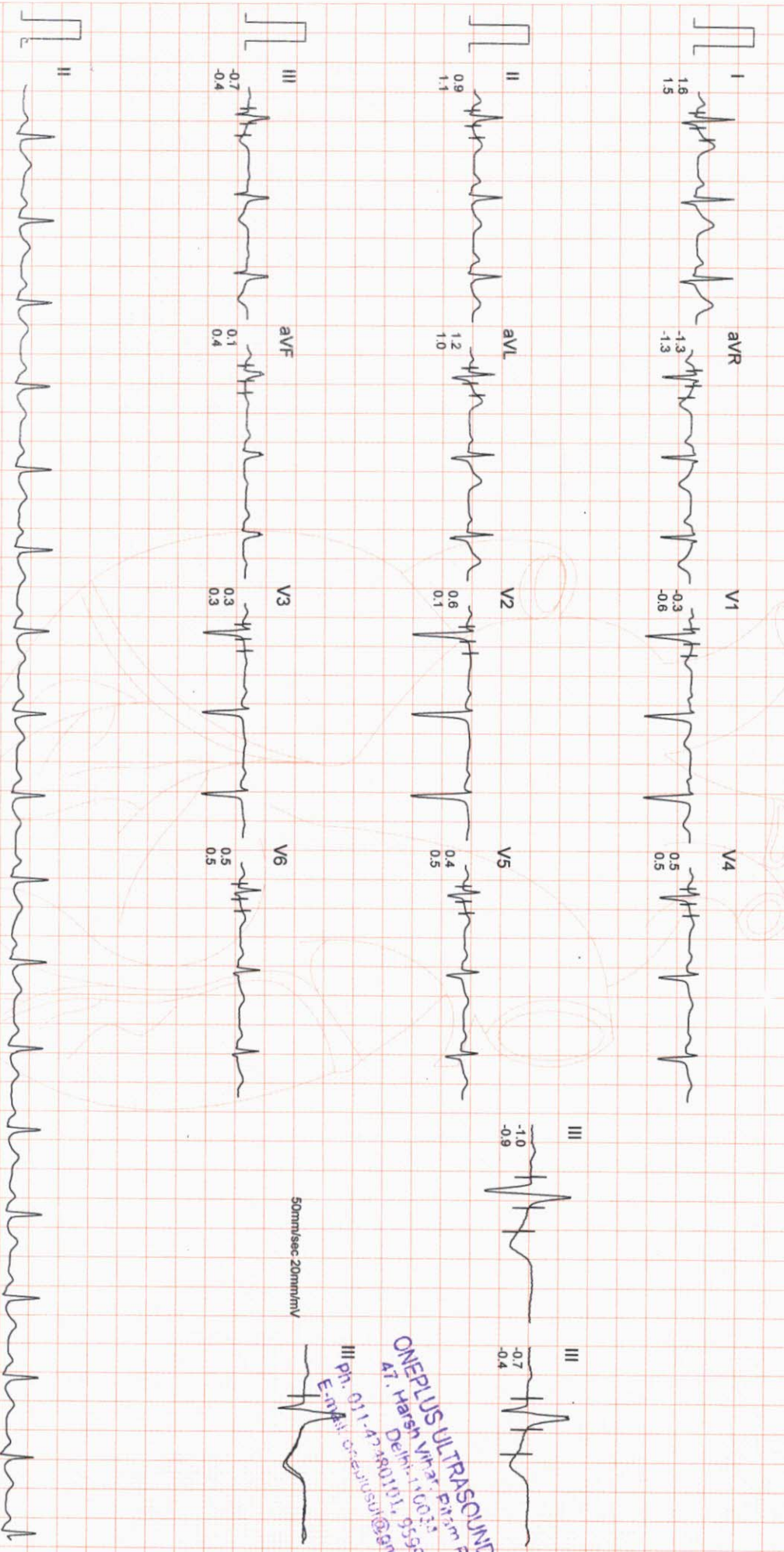
AGE/SEX : 44/M

RECORDED : 24-3-2022 11:18

RATE : 108 BPM

B.P. : 132/88 mmHg

LINKED MEDIAN



ONEPLUS ULTRASOUND LAB
Delhi: +91 11 47340101, 9559913051
47, I. Harsh Vihar, Pitam Pura.
E-mail: dr.ranjitpawar@gmail.com
Dr. Ranjit Pawar

50mm/sec 20mm/mV








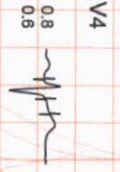











ONEPLUS ULTRASOUND LAB
 47, Harsh Vihar, Pitam Pura,
 Delhi-110034
 Ph. 011-42480101, 9559913051
 E-mail: oneplusul@gmail.com

STANDING
 0.0kmph
 0.0%
 90 bpm
 B.P. : 130/88
 80ms PostJ

PEAK EXERCISE
 8:59
 2:59
 5.4kmph
 14.0%
 152 bpm
 B.P. : 160/94
 80ms PostJ

STANDING
 0.0kmph
 0.0%
 90 bpm
 B.P. : 130/88
 80ms PostJ

PEAK EXERCISE
 8:59
 2:59
 5.4kmph
 14.0%
 152 bpm
 B.P. : 160/94
 80ms PostJ



ONEPLUS ULTRASOUND LAB
 #7, Harsh Vihar, Pitam Pura,
 Delhi-110034
 Ph. 011-42460101, 9539913051
 E-mail: oneplusul@gmail.com



OnePLUS
Ultrasound Lab

— QUALITY FIRST... ALWAYS! —

Dr. Nitin Agarwal

Pathologist & Director
Ex. Sr. Res. MAMC
& Lok Nayak Hospital
Ex. Chief of Lab Dr. Lal Path Labs.

Dr. Pooja (Garg) Agarwal

Radiologist & Director
MAMC & Lok Nayak Hospital

| | | | |
|----------------|--------------------|-------------------|----------------|
| Name | : Mr. RANJIT PAWAR | Age/Sex | : 44 YRS/Male |
| Ref. By | : Dr. MEDIWHEEL | Lab No | : 012203240023 |
| Date | : 24-Mar-2022 | Patient ID | : LSHHI93046 |

ULTRASOUND EXAMINATION---WHOLE ABDOMEN

Liver is normal in size (13.6 cm) and normal in outline with normal echopattern. Intrahepatic biliary radicles are not dilated. No abscess or mass lesion seen. Hepatic veins, portal vein, IVC and aorta are normal. CBD is normal in caliber.

Gall bladder is well distended with anechoic lumen. Wall thickness is normal.

Both kidneys are normal in size, shape, position, outline and echopattern. Corticomedullary differentiation is maintained. No pelvicalyceal dilation or mass lesion is seen.

Spleen is normal in size and echotexture. No mass lesion seen.

Pancreas is normal in size, outline and echotexture.

Urinary bladder is normal in shape and position. No evidence of intravesical stone or mass seen.

Prostate is normal in size, shape and echopattern.

Prostate measures 2.9 x 3.0 x 2.9 cm. **Weight of prostate is 13 grams.**

No abnormal bowel wall thickening seen in right iliac fossa.
No free fluid seen anywhere in abdomen.

IMPRESSION:

- Normal study.

DR. POOJA GARG
RADIOLOGIST
REG NO- DMC/R/03398

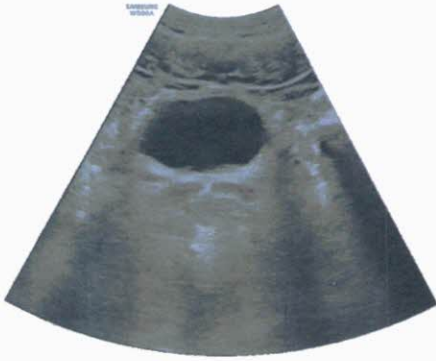Dr. POOJA GARG
M.B.B.S., D.M.R.D
Reg No. DMC/R/03398
Radiologist

Type By : DARSHITA

47, Harsh Vihar, Pitampura, New Delhi-110034 | Ph.: 011-42480101, 9599913051
E-mail: oneplusul@gmail.com | Web.: www.oneplusul.in

WSD0A MR RANJIT 44/M OnePlus Ultrasound Lab MI 1.5 24-03-2022
CA1-7A / Abdomen / FR 23Hz Tib0.1 11:49:09 AM

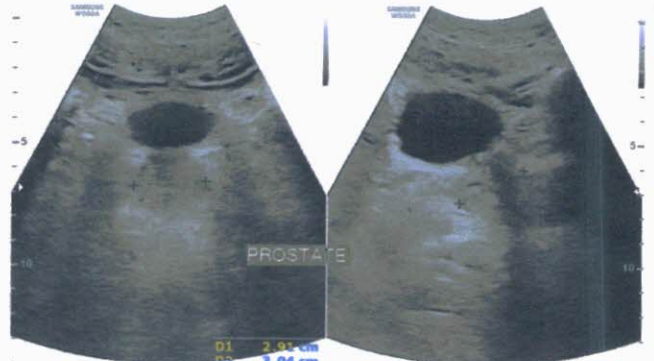20 G51-DR130-FA11 P100-Frq Pen. 14.0cm



WSD0A MR RANJIT 44/M OnePlus Ultrasound Lab MI 1.5 24-03-2022
CA1-7A / Abdomen / FR 23Hz Tib0.1 11:49:27 AM

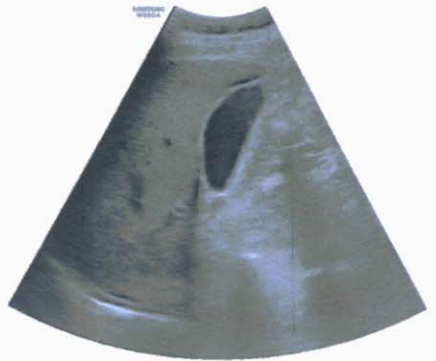20 G51-DR130-FA11 P100-Frq Pen. 14.0cm

20 G51-DR130-FA11 P100-Frq Pen. 14.0cm



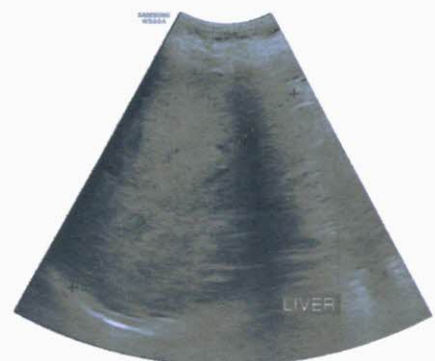WSD0A MR RANJIT 44/M OnePlus Ultrasound Lab MI 1.5 24-03-2022
CA1-7A / Abdomen / FR 23Hz Tib0.2 11:49:45 AM

20 G64-DR130-FA11 P100-Frq Pen. 17.0cm



WSD0A MR RANJIT 44/M OnePlus Ultrasound Lab MI 1.5 24-03-2022
CA1-7A / Abdomen / FR 23Hz Tib0.2 11:49:53 AM

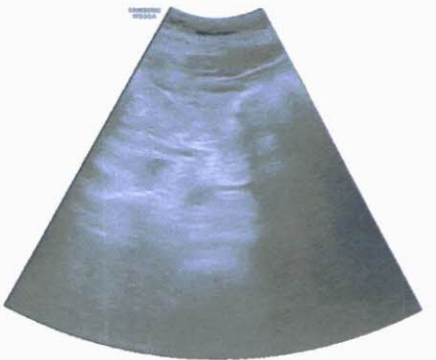20 G64-DR130-FA11 P100-Frq Pen. 17.0cm



D1 14.60 cm

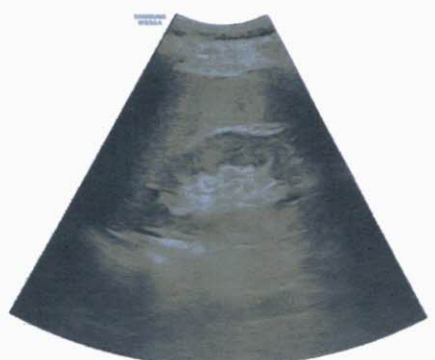WSD0A MR RANJIT 44/M OnePlus Ultrasound Lab MI 1.5 24-03-2022
CA1-7A / Abdomen / FR 23Hz Tib0.2 11:50:06 AM

20 G67-DR130-FA11 P100-Frq Pen. 17.0cm



WSD0A MR RANJIT 44/M OnePlus Ultrasound Lab MI 1.5 24-03-2022
CA1-7A / Abdomen / FR 23Hz Tib0.2 11:50:27 AM

20 G66-DR130-FA11 P100-Frq Pen. 17.0cm



WSD0A MR RANJIT 44/M OnePlus Ultrasound Lab MI 1.5 24-03-2022
CA1-7A / Abdomen / FR 23Hz Tib0.2 11:50:46 AM

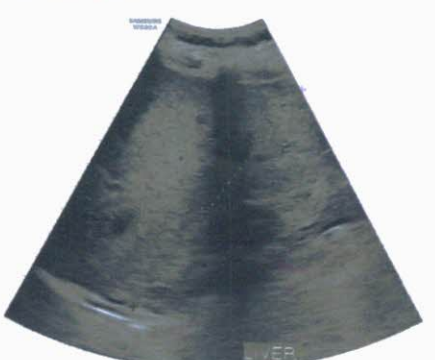20 G52-DR130-FA11 P100-Frq Pen. 17.0cm

20 G52-DR130-FA11 P100-Frq Pen. 17.0cm



WSD0A MR RANJIT 44/M OnePlus Ultrasound Lab MI 1.5 24-03-2022
CA1-7A / Abdomen / FR 23Hz Tib0.2 11:51:35 AM

20 G46-DR130-FA11 P100-Frq Pen. 17.0cm



D1 13.61 cm




Figure 1. Micrographs of the central region of the specimen.



Figure 2. Micrograph of the central region of the specimen.



Figure 3. Micrograph of the central region of the specimen.



Figure 4. Micrograph of the central region of the specimen.



Figure 5. Micrograph of the central region of the specimen.



Figure 6. Micrograph of the central region of the specimen.



Figure 7. Micrograph of the central region of the specimen.



Figure 8. Micrographs of the central region of the specimen.



OnePLUS
Ultrasound Lab

— QUALITY FIRST... ALWAYS! —

Dr. Nitin Agarwal

Pathologist & Director
Ex. Sr. Res. MAMC
& Lok Nayak Hospital
Ex. Chief of Lab Dr. Lal Path Labs.

Dr. Pooja (Garg) Agarwal


Radiologist & Director
MAMC & Lok Nayak Hospital

| | | | |
|----------------|--------------------|-------------------|----------------|
| Name | : Mr. RANJIT PAWAR | Age/Sex | : 44 YRS/Male |
| Ref. By | : Dr. MEDIWHEEL | Lab No | : 012203240023 |
| Date | : 24-Mar-2022 | Patient ID | : LSHHI93046 |

X-ray-Chest PA view

Bony cage and soft tissues are normal.
Cardiothoracic ratio is normal.
Mediastinum is normal.
Both hila are normal.
Both costophrenic angles are clear.
Both domes of diaphragm are normal.
Lung fields are clear. No parenchymal lesion seen.

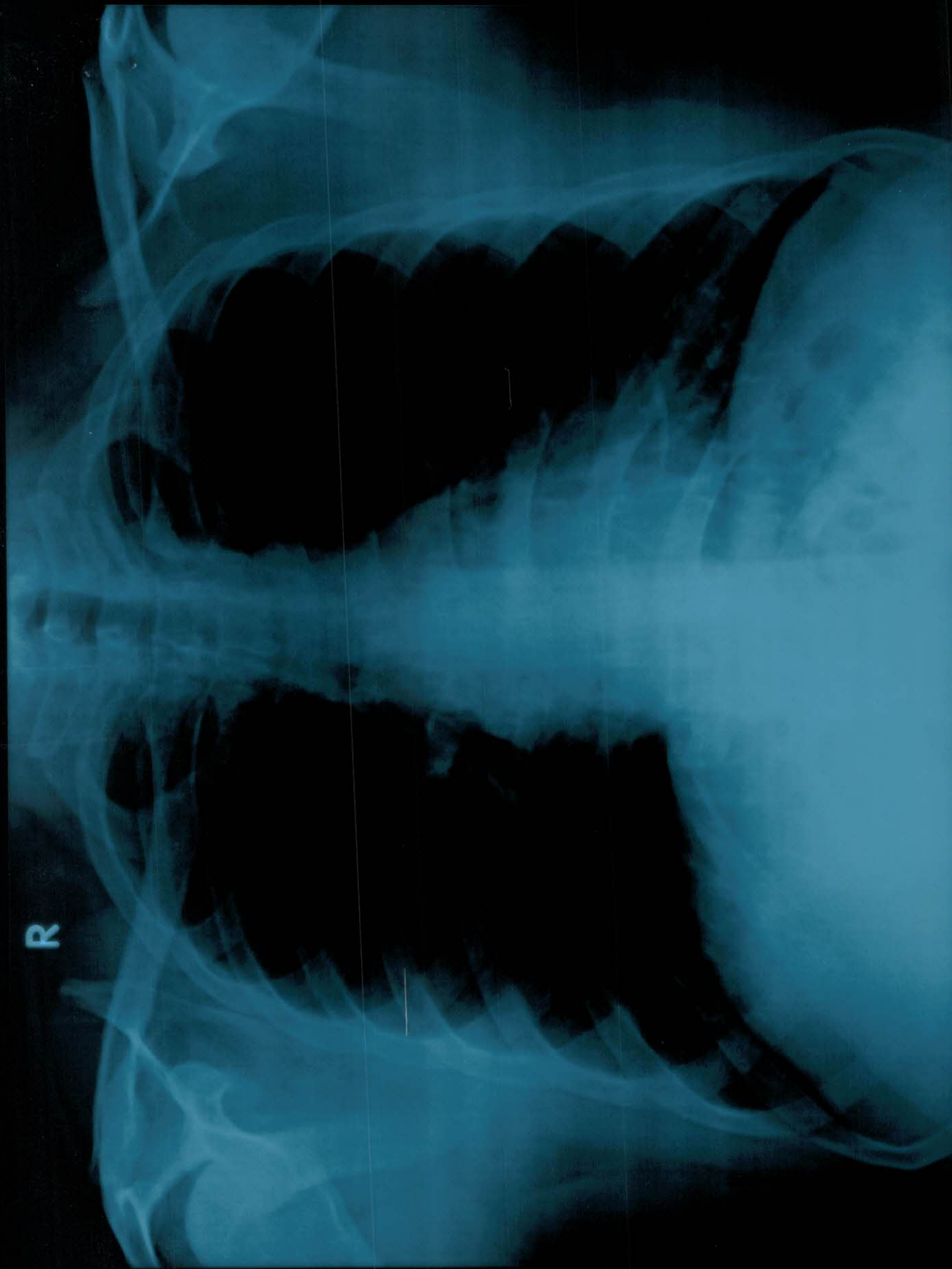
IMPRESSION: Normal Study.


DR. POOJA GARG
RADIOLOGIST
REG NO- DMC/R/03398
Dr. POOJA GARG
M.B.B.S., D.M.R.D
Reg No. DMC/R/03398
Radiologist

Type By : pooja

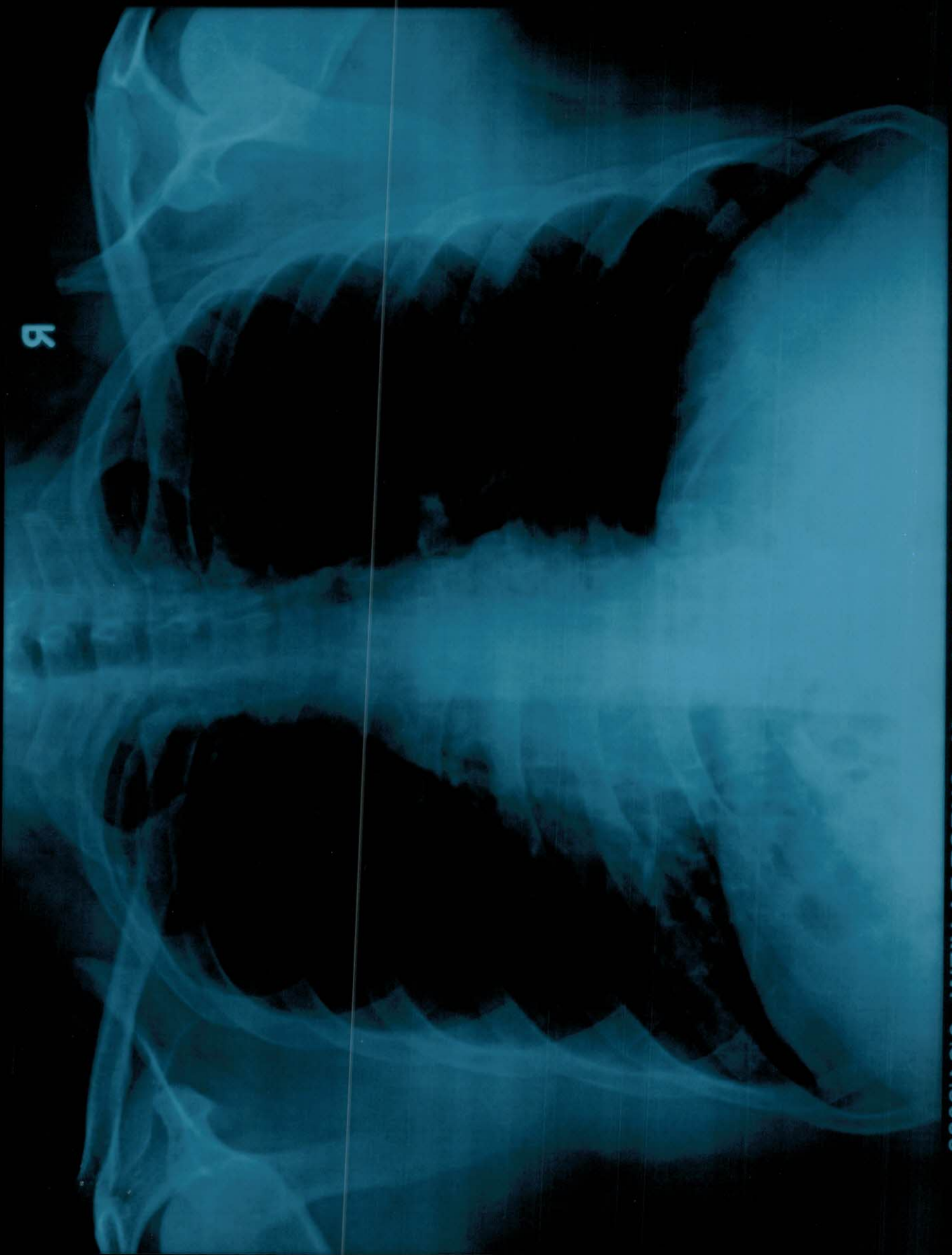
47, Harsh Vihar, Pitampura, New Delhi-110034 | Ph.: 011-42480101, 9599913051
E-mail: oneplusul@gmail.com | Web.: www.oneplusul.in

R



MR RANJIT PAWAR AGE 44 YRS 24-3-2022 M CHEST PA VIEW 3/24/2022
ONEPLUS ULTRASOUND LAB, 47-HARSH VIHAR, PITAMPURA

ONEPLUS ULTRASOUND LAB, 41-HARSH NIHAR PITAMPURA
MR RANJIT PAWAR AGE 44 YRS 54-3-5055 M CHEST PA VIEW 31/5/15055



R



OnePLUS Ultrasound Lab

QUALITY FIRST... ALWAYS!

Dr. Nitin Agarwal
Pathologist & Director
Ex. Sr. Res. MAMC
& Lok Nayak Hospital
Ex. Chief of Lab Dr. Lal Path Labs.

Dr. Pooja (Garg) Agarwal
Radiologist & Director
MAMC & Lok Nayak Hospital



ITDOSE INFOSYSTEMS PVT. LTD.

| | | | |
|-------------|-------------------------|-------------------|----------------------|
| NAME | :Mr. RANJIT PAWAR | Barcode No | :10115923 |
| AGE/GENDER | :44 YRS/Male | SPECIMEN DATE | :24/Mar/2022 10:19AM |
| PATIENT ID | :93046 | SPECIMEN RECEIVED | :24/Mar/2022 12:24PM |
| REFERRED BY | :Dr. MEDIWHEEL | REPORT DATE | :24/Mar/2022 03:19PM |
| CENTRE NAME | :ONEPLUS ULTRASOUND LAB | LAB NO. | :012203240023 |

| Test Name | Result | Unit | Ref. Range |
|-----------|--------|------|------------|
|-----------|--------|------|------------|

HAEMATOLOGY

Health checkup 2 Male

Glycosylated Hemoglobin (HbA1c) 5.3 % Non Diabetic adults <5.7
Prediabetic (at risk) 5.7-6.4
Diabetes >6.4

Estimated average blood glucose (eag) 105

Reference range (mg/dl):

90 - 120:Excellent control, 121 - 150:Good Control, 151 - 180:Average Control, 181 - 210:Action Suggested

>211:Panic value

BLOOD GROUP (ABO) B
Rh typing POSITIVE

NOTE :

- * Apart from major A,B,H antigens which are used for ABO grouping and Rh typing, many minor blood group antigens exist. Agglutination may also vary according to titre of antigen and antibody.
- * So before transfusion, reconfirmation of blood group as well as cross-matching is needed.
- * Presence of maternal antibodies in newborns, may interfere with blood grouping.
- * Auto agglutination (due to cold antibody, falciparum malaria, sepsis, internal malignancy etc.) may also cause erroneous result.

CBC

| | | | |
|-------------------------------------|-------|--------------|------------|
| Haemoglobin | 12.6 | g/dl | 13.0-17.0 |
| Total Leucocyte Count | 8500 | /cumm | 4000-10000 |
| Differential leucocyte count | | | |
| Neutrophils | 61.3 | % | 40-80 |
| Lymphocyte | 30.20 | % | 20-40 |
| Monocytes | 6.10 | % | 2-10 |
| Eosinophils | 1.9 | % | 1-6 |
| Basophils | 0.5 | % | 0-2 |
| RBC Count | 4.99 | million/cumm | 4.5 - 5.5 |

Checked By.

DR. NITIN AGARWAL
MBBS, MD (PATHOLOGIST)

Dr. Nitin Agarwal
MBBS, MD (Path)
011-42480101/01436

47, Harsh Vihar, Pitampura, New Delhi-110034 | Ph.: 011-42480101, 9599913051

E-mail: oneplusul@gmail.com | Web.: www.oneplusul.in

Page 1 of 6



OnePLUS Ultrasound Lab

QUALITY FIRST... ALWAYS!

Dr. Nitin Agarwal
Pathologist & Director
Ex. Sr. Res. MAMC
& Lok Nayak Hospital
Ex. Chief of Lab Dr. Lal Path Labs.

Dr. Pooja (Garg) Agarwal
Radiologist & Director
MAMC & Lok Nayak Hospital



| | | | |
|-------------|-------------------------|-------------------|----------------------|
| NAME | :Mr. RANJIT PAWAR | Barcode No | :10115923 |
| AGE/GENDER | :44 YRS/Male | SPECIMEN DATE | :24/Mar/2022 10:19AM |
| PATIENT ID | :93046 | SPECIMEN RECEIVED | :24/Mar/2022 12:24PM |
| REFERRED BY | :Dr. MEDIWHEEL | REPORT DATE | :24/Mar/2022 03:19PM |
| CENTRE NAME | :ONEPLUS ULTRASOUND LAB | LAB NO. | :012203240023 |

| Test Name | Result | Unit | Ref. Range |
|------------------------|--------|--------------|---------------|
| PCV(Hematocrit) | 40 | % | 40-50 |
| MCV | 80 | fL | 83-101 |
| MCH | 25.3 | Pg | 27-32 |
| MCHC | 31.6 | G/dL | 32-35 |
| Platelet count | 275000 | /cumm | 150000-450000 |
| RDW-CV | 15.4 | % | 11.4-14.0 |
| ESR(WESTEGRENs METHOD) | 14 | mm in 1st hr | 0-20 |

BIOCHEMISTRY

| | | | |
|-----------------------------------|-------|-------|------------|
| <u>Blood sugar fasting</u> | 94 | mg/dL | 70-110 |
| <u>Blood sugar pp</u> | 99 | mg/dL | 70.0-140.0 |
| <u>Bun (blood urea nitrogen)</u> | 14.60 | mg/dl | 8.9-21.6 |
| <u>Uric acid, serum</u> | 4.3 | mg/dl | 3.4-7.0 |
| <u>Creatinine, serum</u> | 1 | mg/dl | 0.60-1.1 |

LFT(LIVER FUNCTION TEST)

| | | | |
|-------------------------------|------|-------|-------------|
| Bilirubin Total | 0.65 | mg/dl | 0.1-1.2 |
| Bilirubin Conjugated | 0.24 | mg/dl | 0-0.4 |
| Bilirubin Unconjugated | 0.41 | mg/dl | up to 0.7 |
| SGOT (AST) | 19 | U/L | 0-35 |
| SGPT (ALT) | 24 | U/L | <45.0 |
| Alkaline phosphatase | 85 | U/L | 40-129 |
| Gamma glutamyl transpeptidase | 26 | U/L | <66 |
| Total Protein | 6.9 | gm/dl | 6.60 - 8.70 |
| Albumin | 3.8 | g/dL | 3.8-5.1 |
| Globulin | 3.10 | gm/dl | 1.8-3.4 |
| Albumin/Globulin Ratio | 1.23 | | 1.10 - 2.50 |

LIPID PROFILE

| | | | |
|---------------|-----|-------|--------|
| Cholesterol | 178 | mg/dl | 50-200 |
| Triglycerides | 170 | mg/dL | 25-150 |

Checked By.

DR. NITIN AGARWAL
MBBS, MD (PATHOLOGIST)
DMC/R/01436

47, Harsh Vihar, Pitampura, New Delhi-110034 | Ph.: 011-42480101, 9599913051

E-mail: oneplusul@gmail.com | Web.: www.oneplusul.in

Page 2 of 6



OnePLUS Ultrasound Lab

QUALITY FIRST... ALWAYS!

Dr. Nitin Agarwal
Pathologist & Director
Ex. Sr. Res. MAMC
& Lok Nayak Hospital
Ex. Chief of Lab Dr. Lal Path Labs.

Dr. Pooja (Garg) Agarwal
Radiologist & Director
MAMC & Lok Nayak Hospital



| | | | |
|-------------|-------------------------|-------------------|----------------------|
| NAME | :Mr. RANJIT PAWAR | Barcode No | :10115923 |
| AGE/GENDER | :44 YRS/Male | SPECIMEN DATE | :24/Mar/2022 10:19AM |
| PATIENT ID | :93046 | SPECIMEN RECEIVED | :24/Mar/2022 12:24PM |
| REFERRED BY | :Dr. MEDIWHEEL | REPORT DATE | :24/Mar/2022 03:19PM |
| CENTRE NAME | :ONEPLUS ULTRASOUND LAB | LAB NO. | :012203240023 |

| Test Name | Result | Unit | Ref. Range |
|-----------------------|--------|-------|--|
| HDL Cholesterol | 48 | mg/dL | 30-70 |
| LDL cholesterol | 96 | mg/dL | <130 |
| VLDL cholesterol | 34.0 | mg/dL | 5-40 |
| Cholesterol/HDL Ratio | 3.7 | | Low Risk 3.3-4.97 Average Risk 4.4-7.1 Moderate Risk 7.1-11.0 High Risk >11.0 |
| LDL/HDL Ratio | 2.0 | | 0 - 3.55 |

According to ATP III and NCEP guidelines

| Parameter | Normal | Desirable | Borderline | High |
|-------------------|--------------------------------------|-----------|------------|------|
| Total cholesterol | <200 | 200-239 | | 240 |
| Triglycerides | <150 | 150-199 | 200-499 | 500 |
| LDL | Optimal <100 Near Optimal 100-129 | 130-159 | 160-180 | 190 |
| HDL | <40 : LOW 60 : HIGH | | | |

ENDOCRINOLOGY

PSA TOTAL

Prostatic specific antigen, Total 1.00 ng/ml <4.0

| | |
|------------|--------------------|
| < 40 years | 0.21 to 1.72 ng/ml |
| 40 - 49 | 0.27 to 2.19 ng/ml |
| 50 - 59 | 0.27 to 3.42 ng/ml |
| 60 - 69 | 0.22 to 6.16 ng/ml |
| > 69 | 0.21 to 6.77 ng/ml |

Notes:

PSA is principally produced by the glandular epithelium of the prostate, and is secreted in the seminal fluid. PSA is also present in

Checked By.

DR. NITIN AGARWAL
MBBS,MD(PATHOLOGIST)

DR. NITIN AGARWAL
MBBS, MD (Path)
DMC(R/01436
Page 3 of 6

47, Harsh Vihar, Pitampura, New Delhi-110034 | Ph.: 011-42480101, 9599913051
E-mail: oneplusul@gmail.com | Web.: www.oneplusul.in



OnePLUS
Ultrasound Lab

— QUALITY FIRST... ALWAYS! —

Dr. Nitin Agarwal
Pathologist & Director
Ex. Sr. Res. MAMC
& Lok Nayak Hospital
Ex. Chief of Lab Dr. Lal Path Labs.

Dr. Pooja (Garg) Agarwal
Radiologist & Director
MAMC & Lok Nayak Hospital



| | | | |
|-------------|-------------------------|-------------------|----------------------|
| NAME | :Mr. RANJIT PAWAR | Barcode No | :10115923 |
| AGE/GENDER | :44 YRS/Male | SPECIMEN DATE | :24/Mar/2022 10:19AM |
| PATIENT ID | :93046 | SPECIMEN RECEIVED | :24/Mar/2022 12:24PM |
| REFERRED BY | :Dr. MEDIWHEEL | REPORT DATE | :24/Mar/2022 03:19PM |
| CENTRE NAME | :ONEPLUS ULTRASOUND LAB | LAB NO. | :012203240023 |

| Test Name | Result | Unit | Ref. Range |
|---|--------|------|------------|
| urine and blood. PSA acts on seminal fluid to fluidify and increase sperm mobility. PSA levels rise in prostatic pathologies such as benign prostatic hyperplasia (BPH) or prostate cancer. | | | |

THYROID PROFILE(T3,T4,TSH)

| | | | |
|-----------------------------------|------|--------|------------|
| Triiodothyronine total [t3] | 0.95 | ng/dl | 0.52-1.9 |
| Thyroxine total [t4] | 6.40 | µg/dl | 4.4 - 10.8 |
| TSH (Thyroid Stimulating Hormone) | 3.10 | µIU/ml | 0.25-5.0 |

AGE WISE VARIATION IN TSH

| AGE | TSH(µIU/ml) | AGE | TSH(µIU/ml) |
|-----------|-------------|-----------------------------|-------------|
| 1-4 weeks | 1.00 - 19.0 | 16-20 yrs | 0.25 - 5.0 |
| 1-12 mths | 1.70 - 9.1 | 21 - 80 yrs | 0.25 - 5.0 |
| 1-5 yrs | 0.80 - 8.2 | I st trimester | 0.25 - 5.0 |
| 6-10 yrs | 0.25 - 5.0 | II nd trimester | 0.50 - 5.0 |
| 11-15 yrs | 0.25 - 5.0 | III rd trimester | 0.4 - 6.0 |

Reference ranges - Interpretation of Diagnostic tests - (Jacques Wallach)

1. Primary hypothyroidism is accompanied by depressed serum T3 and T4 values and elevated serum TSH level.
2. Primary hyperthyroidism is accompanied by elevated serum T3 and T4 levels along with depressed TSH values.
3. Slightly elevated T3 levels may be found in pregnancy and estrogen therapy, while depressed levels may be encountered in severe illness, renal failure and during therapy with drugs like propranolol and propyl thiouracil.
4. Although elevated TSH levels are nearly always indicative of primary hypothyroidism, and may be seen in secondary thyrotoxicosis

CLINICAL PATHOLOGY

URINE ROUTINE

Physical examination

| | | |
|--------------|-------------|-------------|
| Quantity | 20 | ML |
| Colour | PALE YELLOW | |
| Transparency | CLEAR | CLEAR |
| Sp.gravity | 1.015 | 1.010-1.030 |
| pH | 6.00 | |
| Reaction | ACIDIC | ACIDIC |

Checked By.

DR. NITIN AGARWAL
MBBS, MD (PATHOLOGIST)
DR. NITIN AGARWAL
MBBS, MD (Path)
DMC/R/01436

47, Harsh Vihar, Pitampura, New Delhi-110034 | Ph.: 011-42480101, 9599913051

E-mail: oneplusul@gmail.com | Web.: www.oneplusul.in

Page 4 of 6



OnePLUS

Ultrasound Lab

QUALITY FIRST... ALWAYS!

Dr. Nitin Agarwal
Pathologist & Director
Ex. Sr. Res. MAMC
& Lok Nayak Hospital
Ex. Chief of Lab Dr. Lal Path Labs.

Dr. Pooja (Garg) Agarwal
Radiologist & Director
MAMC & Lok Nayak Hospital



| | | | |
|-------------|-------------------------|-------------------|----------------------|
| NAME | :Mr. RANJIT PAWAR | Barcode No | :10115923 |
| AGE/GENDER | :44 YRS/Male | SPECIMEN DATE | :24/Mar/2022 10:19AM |
| PATIENT ID | :93046 | SPECIMEN RECEIVED | :24/Mar/2022 12:24PM |
| REFERRED BY | :Dr. MEDIWHEEL | REPORT DATE | :24/Mar/2022 03:19PM |
| CENTRE NAME | :ONEPLUS ULTRASOUND LAB | LAB NO. | :012203240023 |

| Test Name | Result | Unit | Ref. Range |
|-----------|--------|------|------------|
|-----------|--------|------|------------|

Chemical examination

| | | | |
|------------------|----------|--|----------|
| Urine protein | NIL | | NIL |
| Urine sugar | NIL | | NIL |
| Bilirubin, urine | NEGATIVE | | NEGATIVE |
| Urobilinogen | NORMAL | | NORMAL |
| Ketones | NEGATIVE | | NEGATIVE |

Microscopic examination

| | | | |
|-------------------|-----|------|-----|
| Pus cells. | 1-2 | /HPF | 0-2 |
| Epithelial cells | 1-2 | /HPF | NIL |
| R.B.C. | NIL | /HPF | NIL |
| Casts | NIL | /HPF | NIL |
| Crystals | NIL | /HPF | NIL |
| Bacteria | NIL | /HPF | NIL |
| Others. | NIL | NIL | NIL |

STOOL ROUTINE

Physical examination

| | | | |
|-------------|-------------|--|-------------|
| Colour | BROWNISH | | |
| Consistency | SEMI FORMED | | Semi Formed |
| Blood | ABSENT | | Absent |
| Mucus | ABSENT | | Absent |

Chemical examination, stool

| | |
|----|------|
| pH | 5.50 |
|----|------|

Microscopic examination

| | | | |
|-----------------|---------|------|-----|
| Pus cells | 0-1 | /HPF | |
| Red blood cells | NIL | /HPF | NIL |
| Ova | NIL | | NIL |
| Cysts | NIL | | NIL |
| Bacteria | PRESENT | /HPF | NIL |
| Others | NIL | | |

Checked By.

DR. NITIN AGARWAL
MBBS, MD (PATHOLOGIST)
BMC/R/01436

47, Harsh Vihar, Pitampura, New Delhi-110034 | Ph.: 011-42480101, 9599913051

E-mail: oneplusul@gmail.com | Web.: www.oneplusul.in

Page 5 of 6

Clinical correlation is essential for final diagnosis. • If test results are unsatisfactory please contact personally or on phone. • This report is for perusal of doctors only. • All disputes Subject to Delhi Jurisdiction only. • Not for medicolegal purposes. • All congenital anomalies in a foetus may not be diagnosed in routine obstetric ultrasound.



OnePLUS Ultrasound Lab

— QUALITY FIRST... ALWAYS! —

Dr. Nitin Agarwal

Pathologist & Director
Ex. Sr. Res. MAMC
& Lok Nayak Hospital
Ex. Chief of Lab Dr. Lal Path Labs.

Dr. Pooja (Garg) Agarwal

Radiologist & Director
MAMC & Lok Nayak Hospital




| | | | |
|-------------|-------------------------|-------------------|----------------------|
| NAME | :Mr. RANJIT PAWAR | Barcode No | :10115923 |
| AGE/GENDER | :44 YRS/Male | SPECIMEN DATE | :24/Mar/2022 10:19AM |
| PATIENT ID | :93046 | SPECIMEN RECEIVED | :24/Mar/2022 12:24PM |
| REFERRED BY | :Dr. MEDIWHEEL | REPORT DATE | :24/Mar/2022 03:19PM |
| CENTRE NAME | :ONEPLUS ULTRASOUND LAB | LAB NO. | :012203240023 |

| Test Name | Result | Unit | Ref. Range |
|-----------|--------|------|------------|
|-----------|--------|------|------------|

*** End Of Report ***

Checked By.


DR. NITIN AGARWAL
MBBS, MD (PATHOLOGIST)
MBBS, MD (Path)
1051/R/01436

47, Harsh Vihar, Pitampura, New Delhi-110034 | Ph.: 011-42480101, 9599913051
E-mail: oneplusul@gmail.com | Web.: www.oneplusul.in

Clinical correlation is essential for final diagnosis. • If test results are unsatisfactory please contact personally or on phone. • This report is for perusal of doctors only.
• All disputes Subject to Delhi Jurisdiction only. • Not for medicolegal purposes. • All congenital anomalies in a foetus may not be diagnosed in routine obstetric ultrasound.