

11.02.2023 11:57:06  
BERLIN DIAGNOSTIC & DAY CARE  
BARIATU  
RANCHI

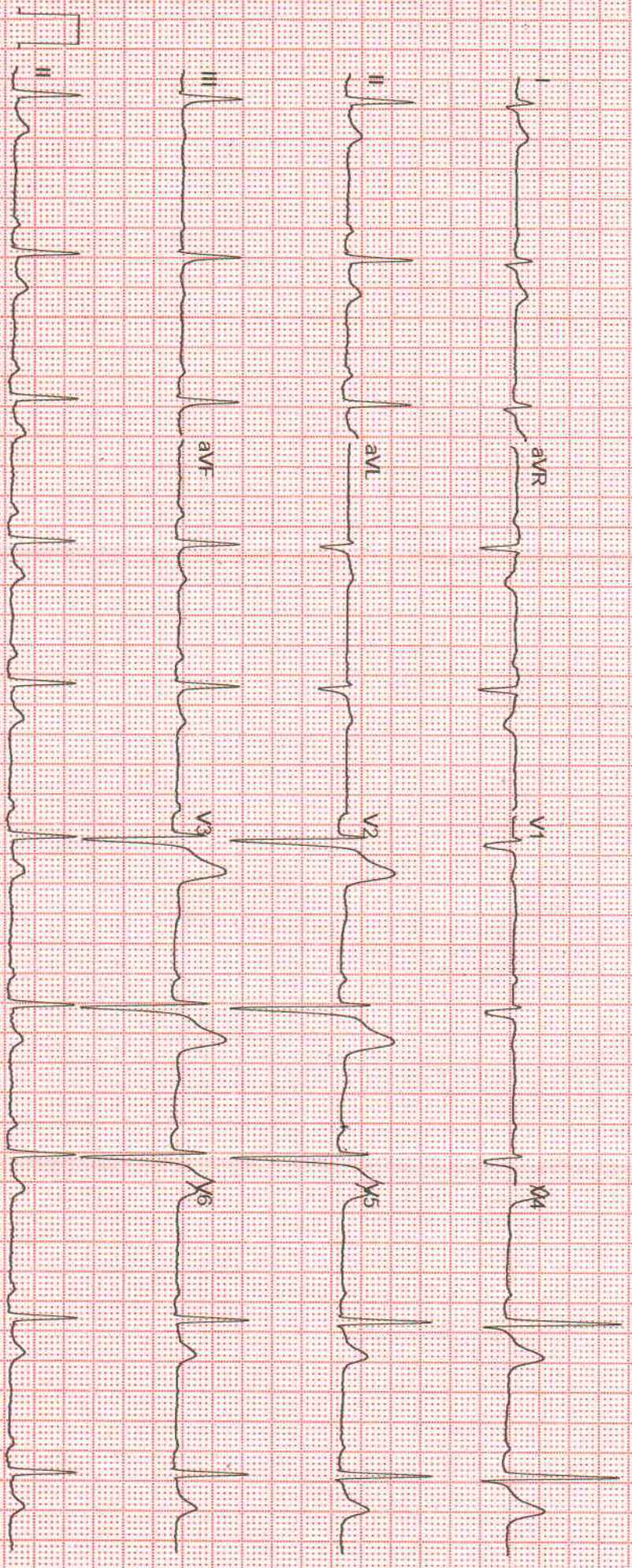
Location:  
Room:  
Order Number:  
Indication:  
Medication 1:  
Medication 2:  
Medication 3:

Technician:  
Ordering Ph:  
Referring Ph:  
Attending Ph:

QRS 98 ms  
QT/QTcBaz 378/371 ms  
PR 208 ms  
P 96 ms  
RR/PP 1030/1034 ms  
P/QRS/T 65/83/42 degrees

Sinus bradycardia  
Otherwise normal ECG

58 bpm  
-- / -- mmHg



MACC2000 1.1 12SL™ V241 25 mm/s 10 mm/mV ADS 0.56-20 Hz 50 Hz 4X2.5x3\_25\_R1 1/1

Unconfirmed



# BERLIN DIAGNOSTICS & DAY CARE

Name **MR. PANKAJ KUMAR**

Age **36**

Date **11/02/2023**

Patient Id **202313479.**

Sex **Male**

Ref.Physician

## Measurements

### 2D & M-Mode Measurements

IVSd	1.00 cm
LVIDd	5.17 cm
LVPWd	1.23 cm
IVSs	1.41 cm
LVIDs	3.68 cm
LVPWs	1.34 cm
EDV(Teich)	127.82 ml
ESV(Teich)	57.48 ml
EF(Teich)	55.03 %
%FS	28.78 %
SV(Teich)	70.34 ml
D-E Excursion	1.60 cm
E-F Slope	0.11 m/s

### PW-Measurements


MV E Vel	0.68 m/s
MV DecT	159.83 ms
MV Dec Slope	4.23 m/s <sup>2</sup>
MV A Vel	0.52 m/s
MV E/A Ratio	1.30
MV PHT	46.35 ms
MVA By PHT	4.75 cm <sup>2</sup>
AV Vmax	1.14 m/s
AV maxPG	5.19 mmHg

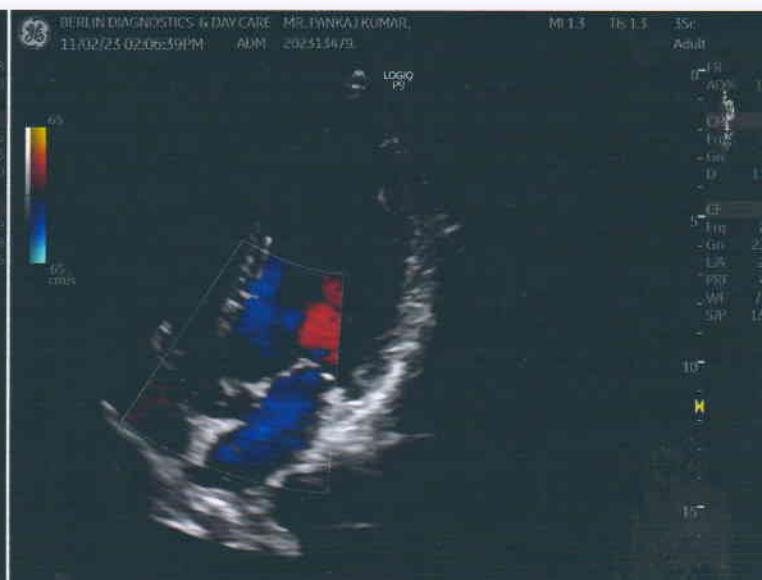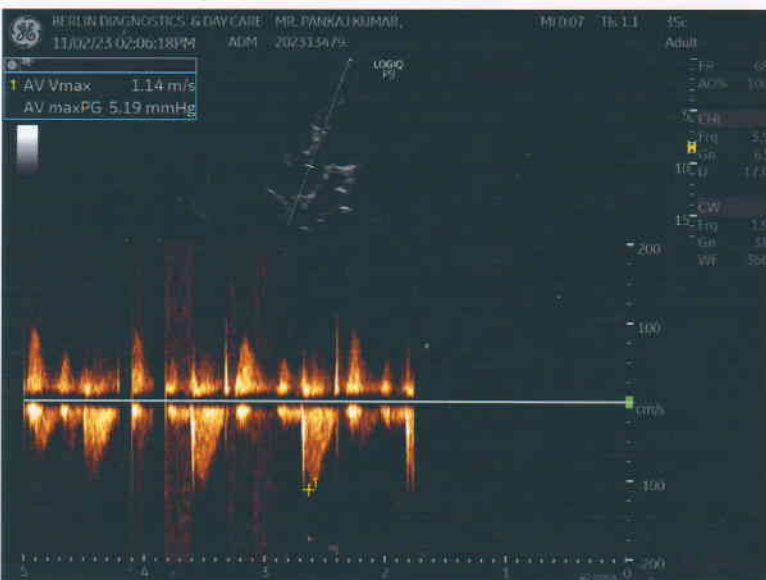
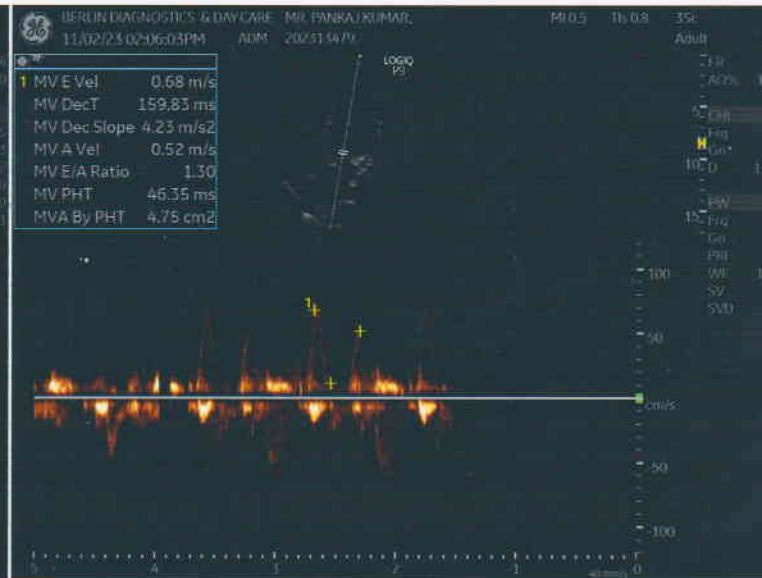
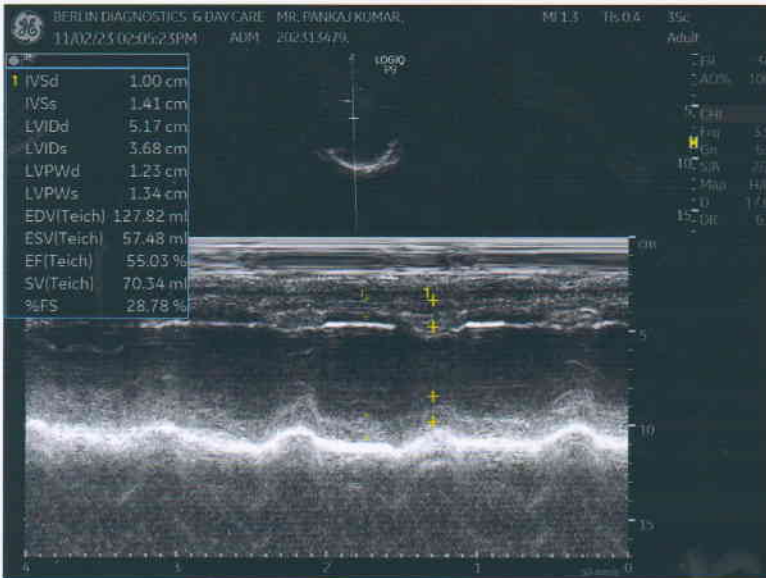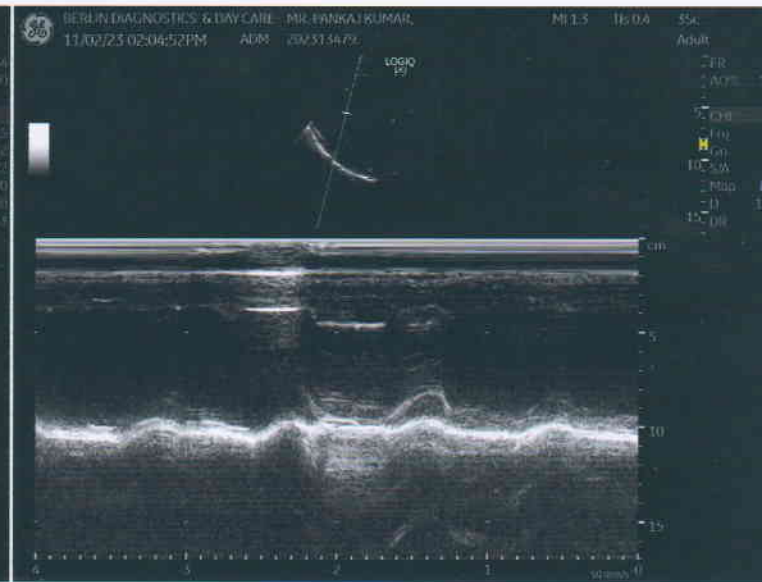
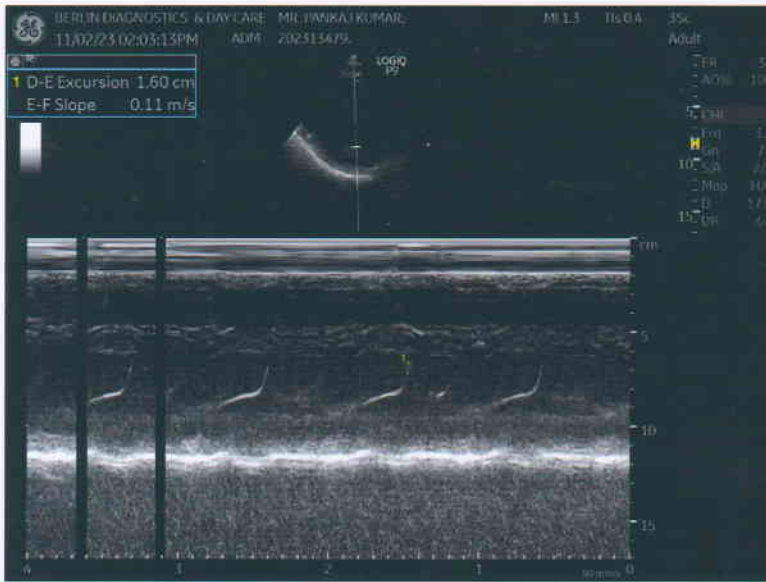
## Comments:

CONCENTRIC LVH, NORMAL LA RA AND RV SIZE, 2DEF=60%, NO RWMA, ALL VALVES AND PERICARDIUM NORMAL.

## Impression:

CONCENTRIC LVH, NORMAL LV SYSTOLIC AND RV FUNCTION IN NSR, NO PAH.

  
DR. AMAR KUMAR  
DIP CARD (P.G.D.C.C)  
CLINICAL CARDIOLOGIST





# BERLIN DIAGNOSTICS & DAY CARE

**Patient Name :** MR. PANKAJ KUMAR MANDAL 13479

**Age / Gender :** 36 years / Male

**Patient ID :** 4199

**Referral :** Dr. mediwheel

**Collection Time :** Feb 11, 2023, 10:06 a.m.

**Reporting Time :** Feb 11, 2023, 04:01 p.m.

**Sample ID :**



2302000146

Test Description	Value(s)	Reference Range
------------------	----------	-----------------

### BUN/CREATININE RATIO

BUN/ CREATININE	16.41	8:1 - 20:1	mg/dl
-----------------	-------	------------	-------

### LIPID PROFILE

S.Cholesterol	174	Desirable : < 200 Borderline high : 200 - 239 Undesirable : > 240	mg/dl
S.Triglycerides	138	Desirable : < 150 Borderline high : 150 - 199 High : 200 - 499 Very High : > 500	mg/dl
S. HDL	43	Undesirable : < 40 Borderline : 40 - 59 Desirable : > 60	mg/dl
S. LDL	103.4	Desirable : < 130 Borderline : 130-159 Undesirable : > 160	mg/dl
S. VLDL	27.6	5 - 51	mg/dl
LDLC/HDLC Ratio	2.4	0 - 3.6	
S.Cholesterol/HDLC Ratio	4.05	0-5.0	

NOTE

### GLYCOSYLATED HAEMOGLOBIN ( GHB / HBA1c )

Result	5.0	Normal : 4 - 6 Good Control : <7 Fair Control : 7 - 9 Poor Control : >9	%
Method	High Pressure Liquid Chromatography		

### ESR (ERYTHROCYTE SEDIMENTATION RATE)

ESR 1st Hour	10	0 - 15	Mm/hr
Method	Wintrobe's		

### BLOOD GLUCOSE LEVEL ( FASTING )

Scan to Validate



Address :- OPP. DAV NANDRAJ PUBLIC SCHOOL , BOOTY ROAD, BARIATU RANCHI-834009

CONTACT:18008913990/9341529301 TEL : 0651-2952017

EMAIL : info@berlindiagnosics.com



# BERLIN DIAGNOSTICS & DAY CARE

**Patient Name :** MR. PANKAJ KUMAR MANDAL 13479

**Age / Gender :** 36 years / Male

**Patient ID :** 4199

**Referral :** Dr. mediwheel

**Collection Time :** Feb 11, 2023, 10:06 a.m.

**Reporting Time :** Feb 11, 2023, 04:01 p.m.

**Sample ID :**



2302000146

Test Description	Value(s)	Reference Range	
Glucose Fasting	87	70 - 110	mg/dl
Method	GOD POD		
NOTE			

## STOOL ANALYSIS REPORT

### PHYSICAL EXAMINATION

Colour	Brownish Yellow
Consistency	Semisolid
Mucus	Absent

### CHEMICAL EXAMINATION

Occult Blood	Absent
Reducing Substance	Absent

### MICROSCOPIC EXAMINATION

RBC	Absent	/hpf
Pus Cells	Occasional	/hpf
Macrophages	Absent	
Ova	Absent	
Cyst	Absent	
Fat Globules	Absent	
Others	No seen	

### BLOOD GROUP

ABO Grouping	O
Rh Grouping	POSITIVE

### BLOOD GLUCOSE LEVEL - PP ( AFTER BREAKFAST )

Glucose PP (After Breakfast)	102	70 - 140	mg/dl
------------------------------	-----	----------	-------

### LIVER FUNCTION TEST with GGT( LFT )

Total Bilirubin	0.79	0.30 - 1.20	mg/dl
Direct Bilirubin	0.25	< 0.30	mg/dl
Indirect Bilirubin	0.54	< 1.10	mg/dl

Scan to Validate



Address :- OPP. DAV NANDRAJ PUBLIC SCHOOL , BOOTY ROAD, BARIATU RANCHI-834009

CONTACT:18008913990/9341529301 TEL : 0651-2952017

EMAIL : info@berlindiagnosics.com



# BERLIN DIAGNOSTICS & DAY CARE

**Patient Name :** MR. PANKAJ KUMAR MANDAL 13479

**Age / Gender :** 36 years / Male

**Patient ID :** 4199

**Referral :** Dr. mediwheel

**Collection Time :** Feb 11, 2023, 10:06 a.m.

**Reporting Time :** Feb 11, 2023, 04:01 p.m.

**Sample ID :**



2302000146

Test Description	Value(s)	Reference Range	
SGOT (Aspartate Amino Transferase - AST)	21	15 - 35	U/L
SGPT (Alanine Amino Transferase - ALT)	35	15 - 45	U/L
Alkaline Phosphatase	84	56 - 128	IU/L
Total Proteins	6.72	6.0 - 8.4	g/dl
Albumin	3.49	3.2 - 5.0	g/dl
Globulin	3.23	2.0 - 3.5	g/dl
Alb/Glo Ratio	1.08	-	
S. Gamma GT	12.81	0 - 36	U/L
NOTE			

## URINE ROUTINE EXAMINATION REPORT

### PHYSICAL EXAMINATION

Volume	20		ml
Colour	Pale Yellow		
Appearance	Slightly Turbid		
Specific Gravity	1.020	1.010 - 1.030	
Reaction (PH)	6.0	4.8 - 7.6	

### CHEMICAL EXAMINATION

Protein	Absent	Absent	
Glucose	Absent	Absent	
Ketones	Absent	Absent	
Nitrite	Negative	Negative	
Urobilinogen	Normal	Normal	

### MICROSCOPIC EXAMINATION

Pus Cells	2 - 3	0 - 5 - -	/hpf
RBC	Absent	0 - 1 - -	/hpf
Epithelial Cells	1 - 2	0 - 5 - -	/hpf
Casts	Absent	NIL - -	/LPF
Crystals	Absent	NIL - -	

## BLOOD UREA NITROGEN ( BUN )

Scan to Validate



Address :- OPP. DAV NANDRAJ PUBLIC SCHOOL , BOOTY ROAD, BARIATU RANCHI-834009

CONTACT:18008913990/9341529301 TEL : 0651-2952017

EMAIL : info@berlindiagnosics.com



# BERLIN DIAGNOSTICS & DAY CARE

**Patient Name :** MR. PANKAJ KUMAR MANDAL 13479

**Age / Gender :** 36 years / Male

**Patient ID :** 4199

**Referral :** Dr. mediwheel

**Collection Time :** Feb 11, 2023, 10:06 a.m.

**Reporting Time :** Feb 11, 2023, 04:01 p.m.

**Sample ID :**



2302000146

Test Description	Value(s)	Reference Range	
Result	12.82	6.0 - 20.0	mg/dl
Method	Spectrophotometry		

## CREATININE

Method	Spectrophotometry		
Creatinine	0.74	Male : 0.6-1.40 Female : 0.6-1.2	mg/dl

NOTE

## COMPLETE BLOOD COUNT (CBC)

Hb (Haemoglobin)	14.8	Male : 13.0-18.0 Female : 12-16.5 Infant : 13.5-19.5 Children : 12.0-14.5	gm/dl
RBC Count	4.61	4.5 - 6.5	millions/cumm
TLC (Total Leucocyte Count)	4700	4000 - 11000	/cumm

## DIFFERENTIAL COUNT

Neutrophils	65	40 - 65	%
Lymphocytes	28	20 - 45	%
Monocytes	03	1 - 10	%
Eosinophils	04	1 - 6	%
Basophils	0	0 - 1	%
Platelet Count	<b>1.35</b>	1.50 - 4.5	Lakhs/cumm
HCT (HAEMATOCRIT)	45.4	35 - 54	%
MCV (Mean Corpuscular Volume)	<b>98.48</b>	76 - 96	fl
MCH (Mean Corpuscular Haemoglobin)	<b>32.1</b>	27 - 32	pg
MCHC (Mean Corpuscular Hb Concentration)	32.6	32 - 35	gm/dl

NOTE

Comment

## URIC ACID Serum

Method	Spectrophotometry		
Result	3.48	Male : 3.4 - 7.0 Female : 2.5 - 6.0	mg/dl

Scan to Validate



Address :- OPP. DAV NANDRAJ PUBLIC SCHOOL , BOOTY ROAD, BARIATU RANCHI-834009

CONTACT:18008913990/9341529301 TEL : 0651-2952017

EMAIL : [info@berlindiagnosics.com](mailto:info@berlindiagnosics.com)



# BERLIN DIAGNOSTICS & DAY CARE

**Patient Name :** MR. PANKAJ KUMAR MANDAL 13479

**Age / Gender :** 36 years / Male

**Patient ID :** 4199

**Referral :** Dr. mediwheel

**Collection Time :** Feb 11, 2023, 10:06 a.m.

**Reporting Time :** Feb 11, 2023, 04:01 p.m.

**Sample ID :**



2302000146

Test Description	Value(s)	Reference Range
------------------	----------	-----------------

NOTE

**\*\*END OF REPORT\*\***

**Dr. Rajeev**  
MD Pathologist

Scan to Validate

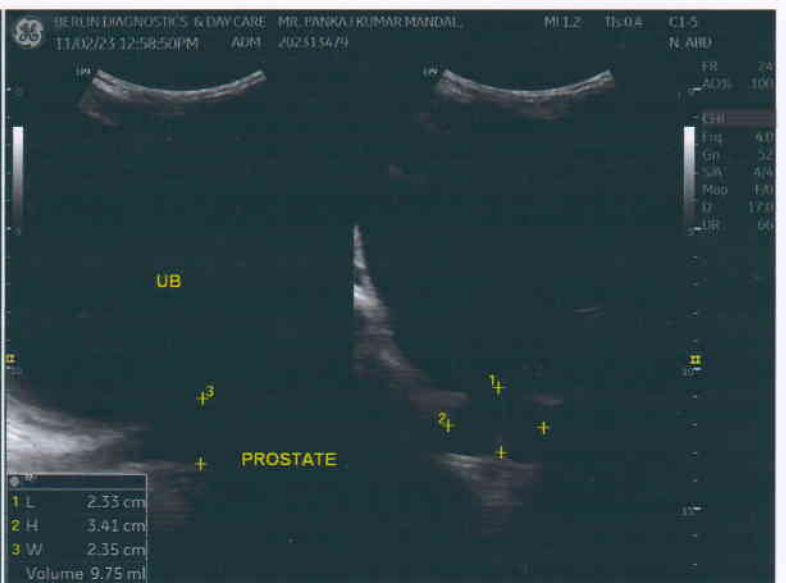
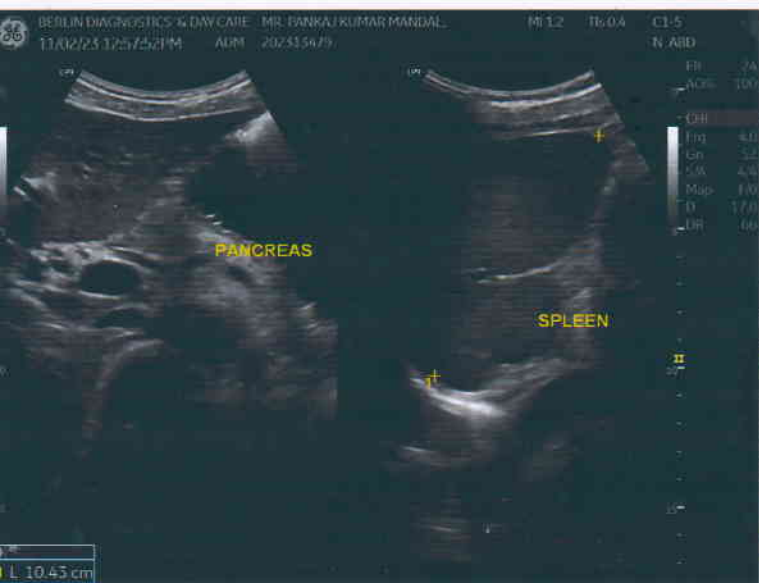
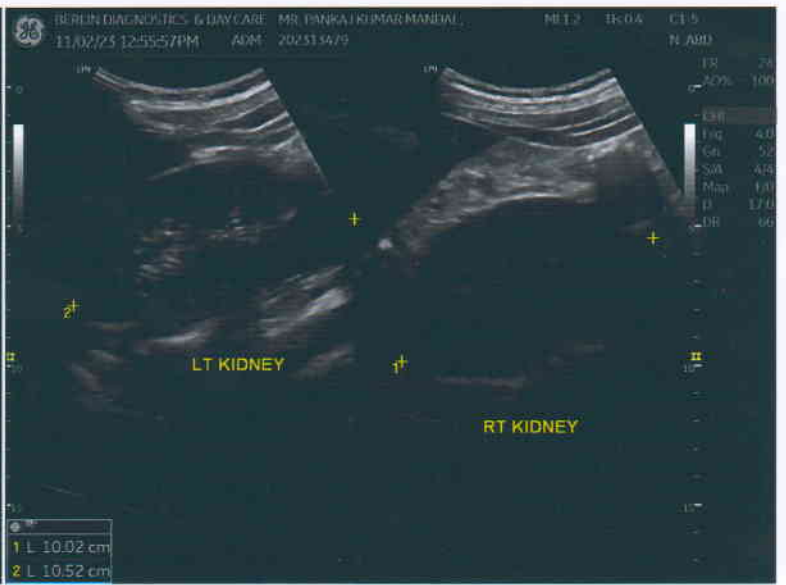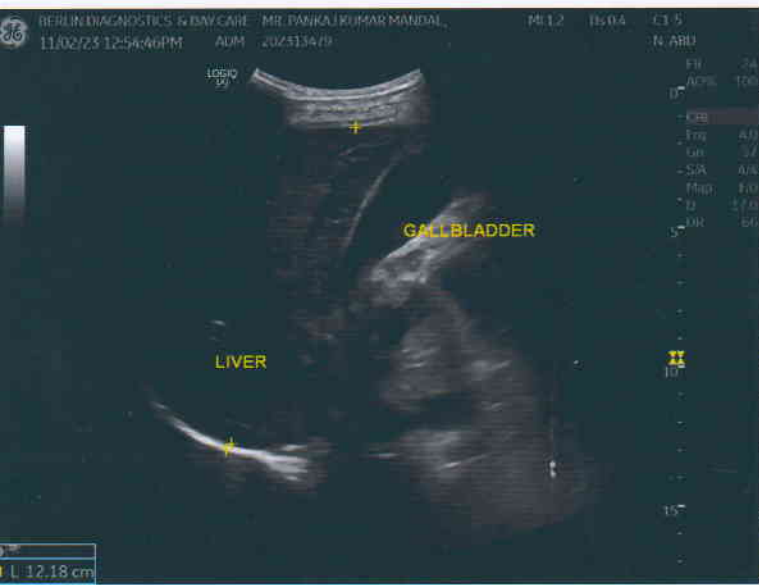Address :- OPP. DAV NANDRAJ PUBLIC SCHOOL , BOOTY ROAD, BARIATU RANCHI-834009

CONTACT:18008913990/9341529301 TEL : 0651-2952017

EMAIL : info@berlindiagnosics.com







# BERLIN DIAGNOSTICS & DAY CARE

<b>Patient Name</b>	MR. PANKAJ KUMAR MANDAL	<b>Requested By</b>	MEDIWHEEL
<b>MRN</b>	BER/202313479/OPD	<b>Procedure Date</b>	11.02.2023
<b>Age/Sex</b>	36 Y/MALE	<b>Hospital</b>	BERLIN DIAGNOSTICS & DAY CARE

## USG WHOLE ABDOMEN

**Liver** : The liver is normal in size (**12.2 cm**) and outline. It shows a uniform echopattern. No obvious focal or diffuse pathology is seen. The intra and extra hepatic biliary passage are not dilated. The portal vein is normal in calibre at the porta hepatis.

**Gall bladder** : The gall bladder is normal in size, has normal wall thickness with no evidence of calculi.

**CBD** : The CBD is of normal calibre.

**Pancreas** : The pancreas is normal in size and echogenicity with distinct outline. No obvious focal lesion is seen.

**Kidneys** : Both kidneys were normal in position:

**Right kidney** measures **10.0 cm**

**Left Kidney** measures **10.5 cm**

The renal cortical thickness and corticomedullary differentiation were adequate on both sides. No evidence of renal calculus or hydronephrosis seen on either sides.

**Spleen** : The spleen is normal in size (**10.4 cm**) and echogenicity.

**Urinary Bladder** : The urinary bladder is normal in size. Its walls show a smooth outline. There is no evidence of any intraluminal or perivesical abnormality.

**Prostate** : The prostate is normal in size, measures (**9.7 gm**) and shows normal parenchymal echogenicity.

No significant probe tenderness in RIF.

No evidence of ascites or lymphadenopathy seen.

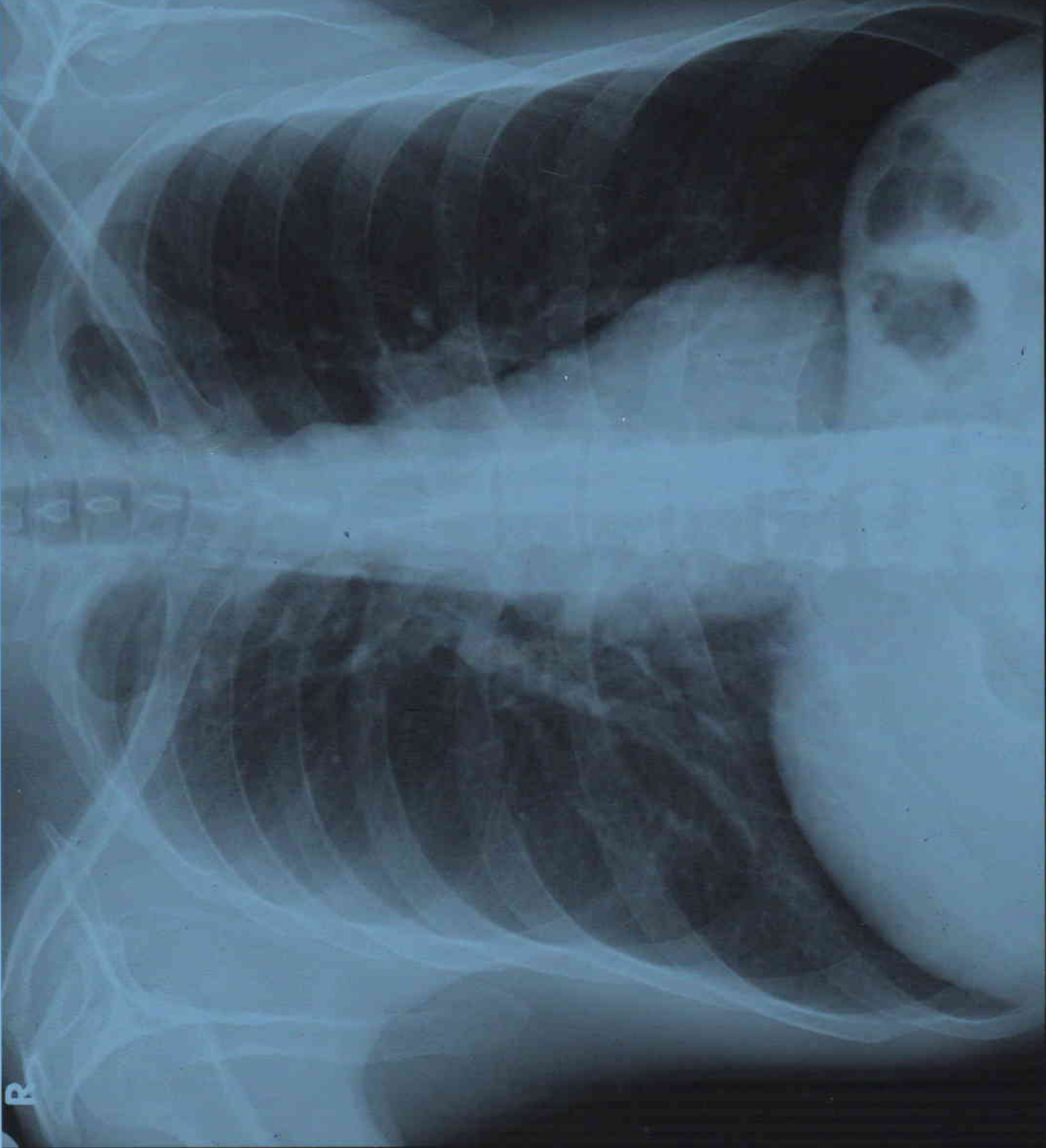
**IMPRESSION : NORMAL STUDY.**

**Please correlate clinically.**

**DR. RAVINDER KAUR**  
**SONOLOGIST**  
PC & PNDT Reg. No - 24648 (BMC)

We regret typographical errors if any. Please contact us for correction.

PA VIEW



R

PANKAJ KUMAR MANDAL AGE 36Y/M MEDIWHEEL BER/202313479 CHEST PA VIEW 11/02/2023  
BERLIN DIAGNOSTICS & DAY CARE, BARIATU ROAD, RANCHI.



PATIENT NAME	: MR. PANKAJ KUMAR MANDAL	PATIENT ID	: BER/202313479
AGE	: 36 Y	SEX	: MALE
REF. PHY.	: MEDIWHEEL	STUDY DATE	: 11-Feb-2023

## X - RAY CHEST PA VIEW

### FINDINGS:

Prominent broncho vascular markings are noted in both lung fields, this is indicative of mild bronchitis.

Both costophrenic angles appear normal.

The tracheal lucency is centrally placed.

The mediastinal and diaphragmatic outlines appear normal.

The heart shadow is normal.

The bony thoracic cage and soft tissues are normal.

### IMPRESSION:

Prominent broncho vascular markings are noted in both lung fields, this is indicative of mild bronchitis.

Dr Sandhya R  
Consultant Radiologist  
MBBS, MD  
Regn No: 117762

Dr Sandhya R  
11th Feb 2023