

**ECHO Report**

**Date: 25/02/2023**

**Patient Details**

**Patient ID –**

**Name** MRS NITAL HHOMBALKAR

**Age-** 32 YEARS

**Gender-** FEMALE

**Referral BY -** MEDIWHEEL

**Doctor Incharge** DR. MAHESH PADSALGE

**Clinical Status of Patient** -

**Finding description -**

1. Normal cardiac chambers dimensions .
2. Normal LV systolic function.
3. No RWMA.
4. All cardiac valves are structurally normal.
5. Trivial MR, Trivial PR, NO AR.
6. No PAH.
7. Normal RV systolic function.
8. No clot/vegetation/pericardial effusion.
9. No coarctation of aorta.

**Chamber Dimensions-M mode Findings**

LVID (Diastole) 35-56(mm) - 41.00  
 IVS (Diastole) 8-12(mm) - 08.00  
 LVPWT (Diastole) 6-11(mm) - 08.00  
 LVEF (%) - 68%

LVID (Systole) 24-42(mm) - 25.00  
 IVS (Systole) 14-42(mm) - 12.00  
 EPSS - 4.00  
 LVFS (%) - 38.00

LV Volume (Diastolic)(mm<sup>3</sup>)  
 Meridional Wall Stress in System

LV Volume (Systolic)(mm<sup>3</sup>)  
 Cubed LV Volume in Diastole (mm<sup>3</sup>)

Cubed LV+ myocardial volume (mm<sup>3</sup>)

Velocity of circumferential  
 Shortening (mm)

Aortic root 22-37(mm) - 26.00  
 Left Atrium Length (mm) - 26.00  
 Left Atrium Volume (mm<sup>3</sup>)  
 RV size Normal  
 Normal  
 RV volume (mm<sup>3</sup>)  
 Normal  
 Pericardium Normal  
 Effusion None  
 Resp Variation Present  
 Predicted RV Systolic Pressure

Left Atrium Width (mm)  
 Left Atrium Area (mm<sup>2</sup>)  
 RV Function

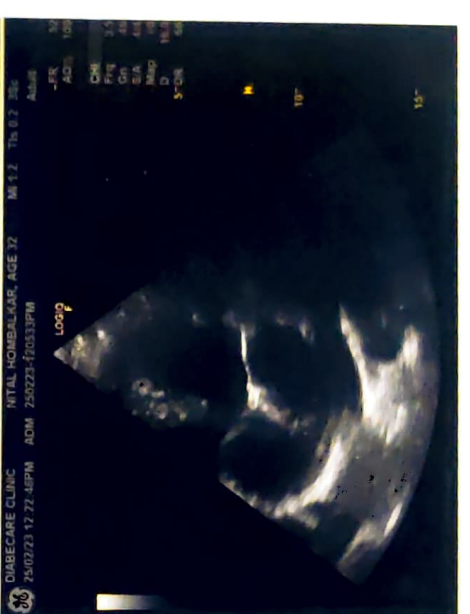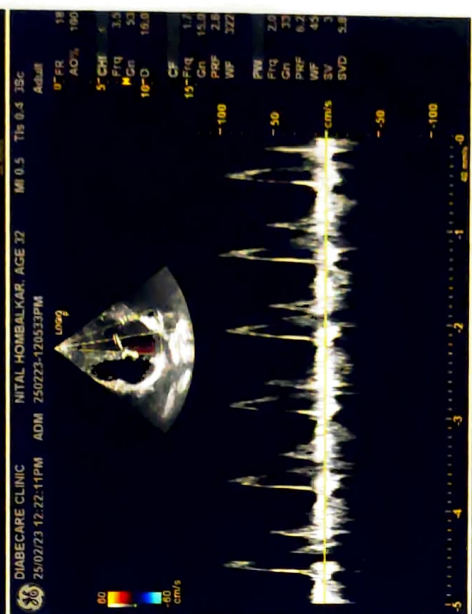
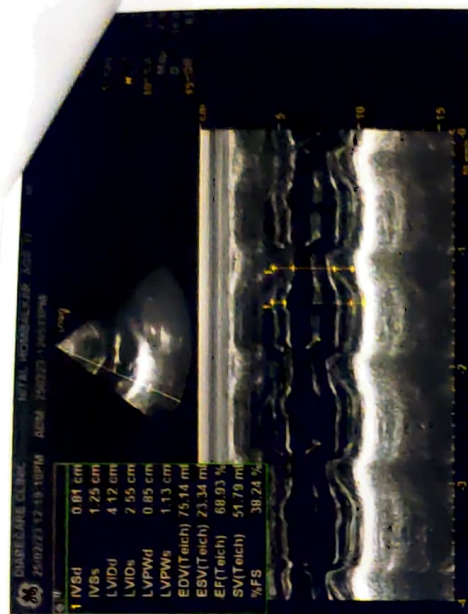
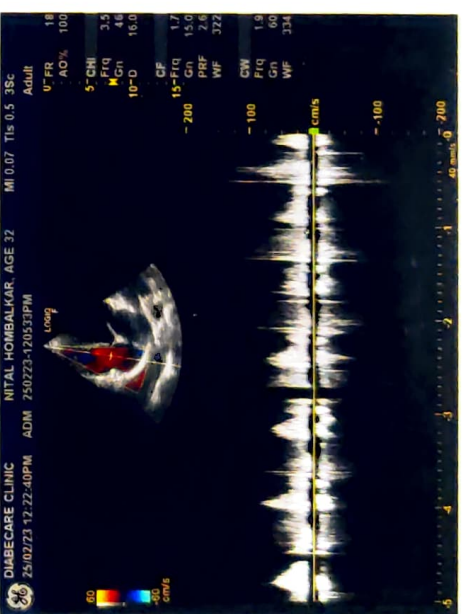
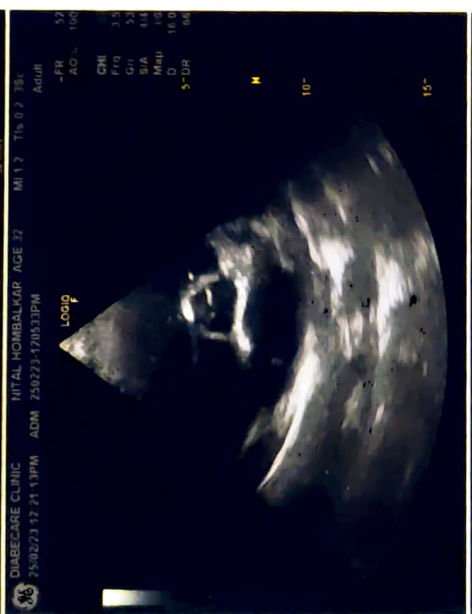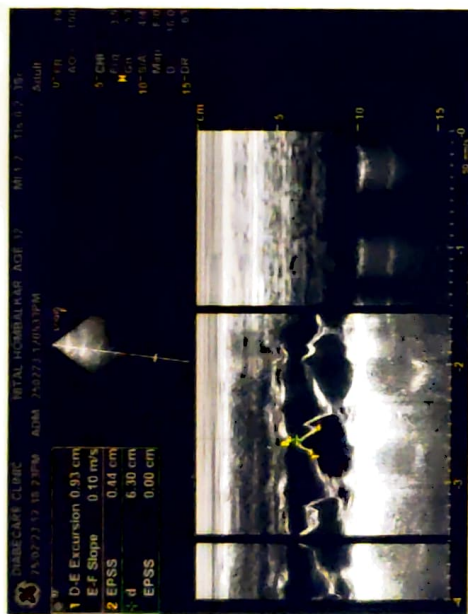
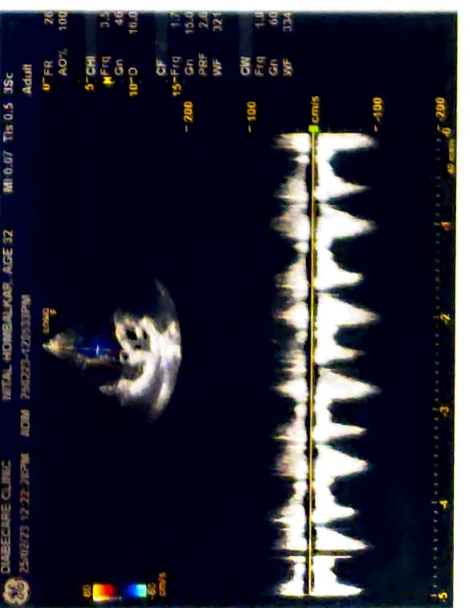
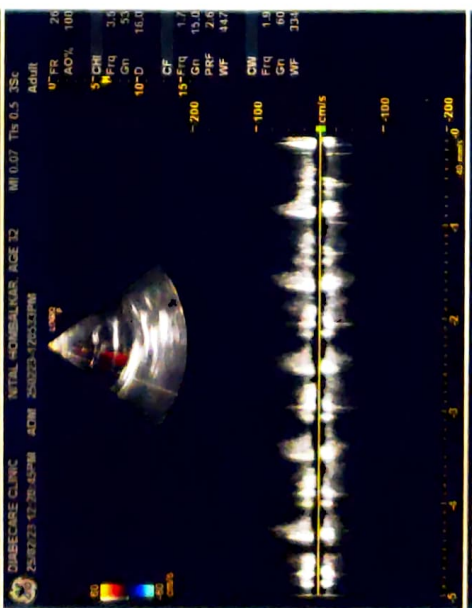
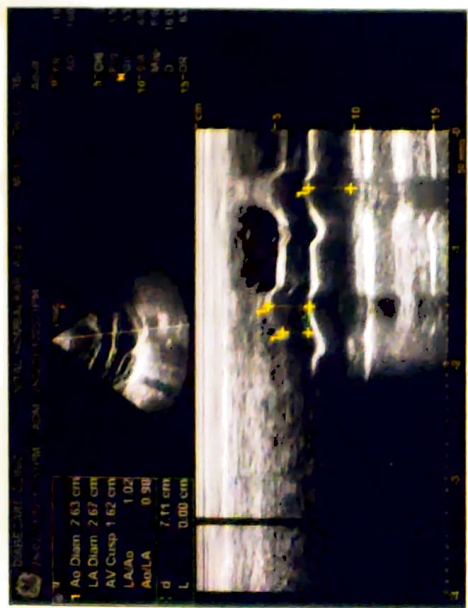
RA Size

IVC Size (mm) – 13mm Collapsible

**Doppler Findings- I**

  
**Dr. Mahesh Padsalge**

*Dr. Mahesh V. Padsalge*  
 MD. (Medicine)  
 Consultant Physician  
 Reg. No. 91424 (MMC)



Female

25.02.2023 11:49:23  
DIABEGARE-DIABETES & ENDOCRINE  
OPP. GRAND CENTRAL MALL  
SEAWOOD

69 bpm  
--/-- mmHg

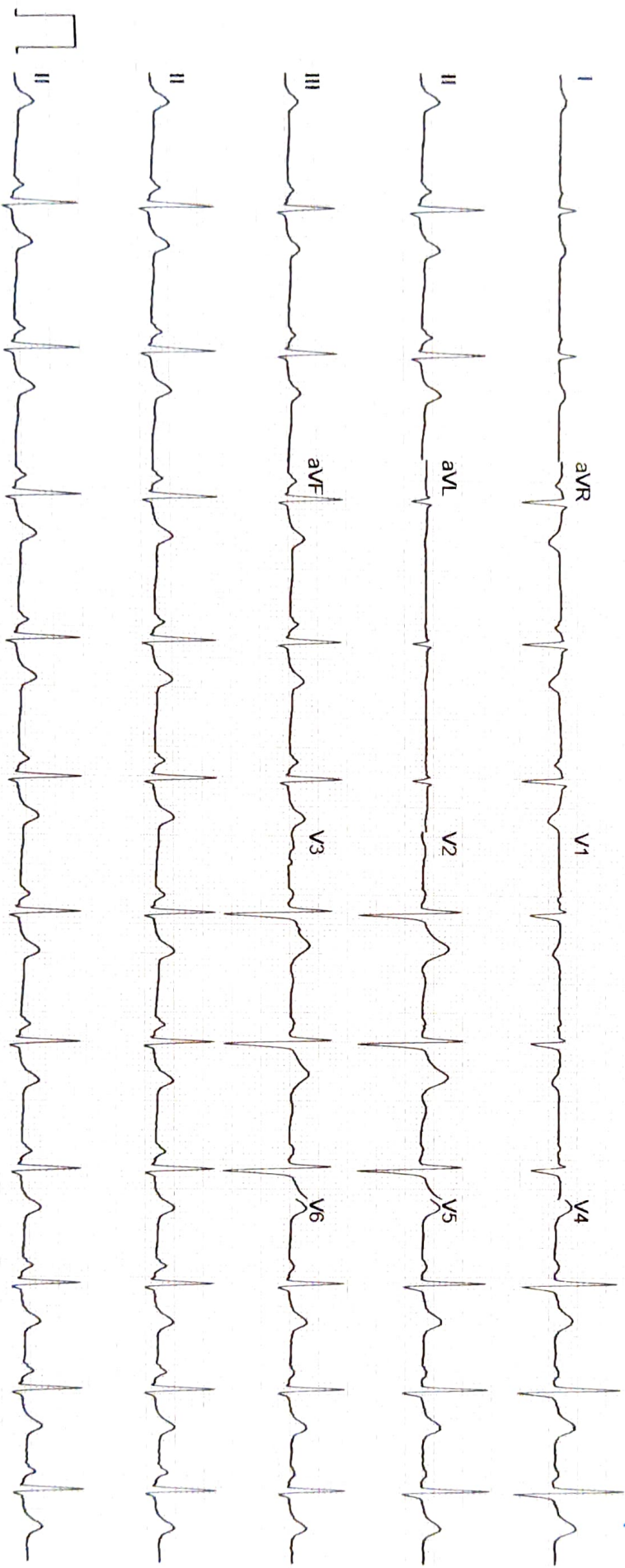
QRS	86 ms
QT / QTcBaz	388 / 415 ms
PR	132 ms
P	100 ms
RR / PP	862 / 869 ms
P / QRS / T	69 / 71 / 64 degrees

Normal sinus rhythm with sinus arrhythmia  
Normal ECG

*Handwritten:* Sinus arrhythmia

*Signature:* Dr. Mahesh V. Patsalga

Dr. Mahesh V. Patsalga  
MD. (Medicine)  
Consultant Physician  
Reg. No. 91424 (M.M.C)



Unconfirmed



Mrs. Nital Hombalkar  
33/F

25/2/23

opultra

(R)

(L)

VA

6/6

6/6

N6

N6

Color Vn

N

N

A/S

N

N

(F)

N

N


(B) wntz

ey

आयकर विभाग  
INCOME TAX DEPARTMENT  
NITAL NINAD HOMBALKAR  
GIRISH WAMAN GOSAVI  
19/07/1989  
Permanent Account Number  
AKWPH0693L  
Signature  
03/10/2013

भारत सरकार  
GOVT. OF INDIA



  
Dr. Mahesh V. Padsalge  
MD. (Medicine)  
Consultant Physician  
Reg. No. 91424 (MMC)

NAME- NITAL HOMBALKAR

DATE-25/2/2023

AGE- 33/F

**X-RAY CHEST PA**

The Soft Tissues And Bony Thorax Are Normal.

Both The Costophrenic And Cardiophrenic Angles Are Clear.

Cardiac Shape And Size Appears Normal.

The Lung Field Appears Normal.

Both The Hila Are Normal In Density And Position.

Both The Domes Of Diaphragm And Mediastinum Are Normal.

**Impression: - Normal Chest X-Ray.**

For, 

**DR.MRUDULA BABAR**  
**CONSULTANT RADIOLOGIST**

Dr. MRUDULA BABAR  
DMRE.CPS Mumbai 2009  
(RADIOLOGIST)  
Reg. No. 2005/03/2139