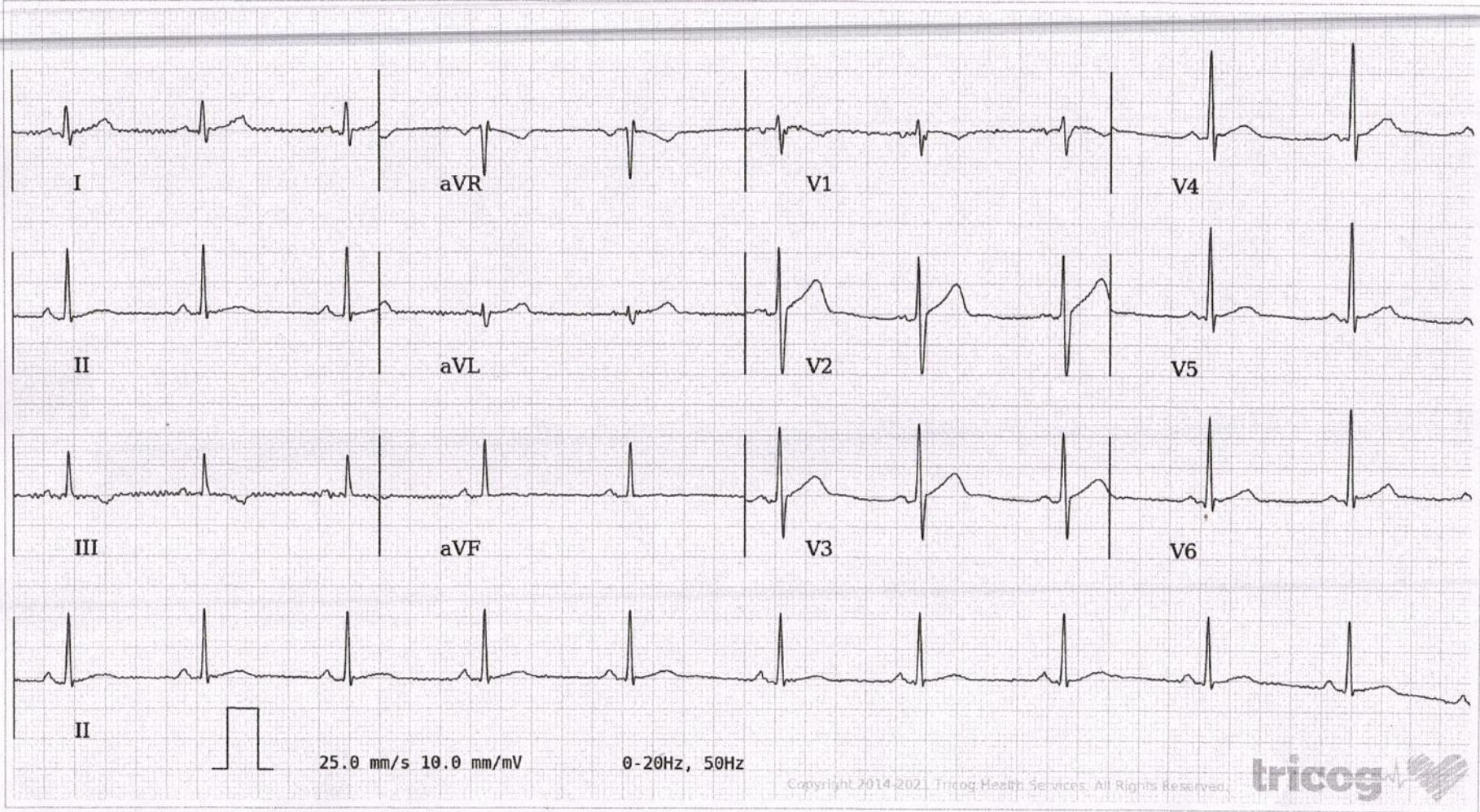




Age / Gender: 37/Male  
Patient ID: IDCD0352912122  
Patient Name: Mr.AMIT KUMAR

Date and Time: 28th Nov 21 10:47 AM



AR: 64 bpm VR: 64 bpm QRSD: 78 ms QT: 384 ms QTc: 396 ms PRI: 140 ms P-R-T: 61° 76° 11°

Sinus Rhythm, Normal Axis, Nonspecific ST Abnormality. Please correlate clinically.

AUTHORIZED BY

Dr. Charit  
MD, DM: Cardiology

63382

REPORTED BY

Dr Ponnambalam

47596