

✓ melliwhee

DR. HARI CHHABLANI  
M.B.B.S. FELLOWSHIP MEDICINE PGDHHM, PGDML  
FELLOW INTENSIVE CARE  
MMC REG. NO. - 91702

"DR. PLUS HEALTHCARE CENTRE"  
NATHANI HEIGHTS', B-WING,  
42, MUMBAI CENTRAL (EAST)

Handwritten initials/signature

33/M.

आयकर विभाग  
INCOME TAX DEPARTMENT

भारत सरकार  
GOVT. OF INDIA

SHONMIPAN KASOMWOSHI  
SOMI KASOMWOSHI  
07/01/1988

Permanent Account Number  
DZSPK6171G

Signature

Authority  
gadhar She  
danvan, Ma  
Opposite  
Mahakali  
Chakala Mldc,  
00093





# Dr-Plus Healthcare Centre

NATHANI HEIGHTS, B-Wing, Shop No. 42, Ground Floor, Opp. Mumbai Central Station (East), Mumbai - 400 008.

Patient Name	:	SHONMIPAN KASOMWOSHI	Sex:	MALE
Doctor's Name	:	DR. H. CHHABLANI	Age:	33 YEARS
Date	:	08/09/2021		

## ULTRASONOGRAPHY OF THE ABDOMEN AND THE PELVIS:

The relevant sonographic findings include the following:

### HEPATOBIILIARY APPARATUS

The liver is normal in size and echogenicity. No obvious focal parenchymal lesion is seen. Extrahepatic biliary radicals are not dilated. The portal vein and the common bile duct are normal.

### GALL BLADDER

The gall bladder is adequately distended. The wall thickness is normal. No echogenic contents are noted in its lumen. There is no pericholecystic collection noted.

### PANCREAS

The pancreas shows normal echogenicity and size. No focal or diffuse lesions are noted. No evidence of calcification is noted.

### SPLEEN

The spleen appears normal in size and echogenicity. No focal or diffuse lesions are noted. No evidence of calcification is noted.

### KIDNEYS

Right Kidney measure: 10.1 x 4.4 cm, Left kidney measure: 10.3 x 4.6cm  
Both the kidneys appear normal in size, shape and echogenicity. Both the pelvicalyceal system is normal and both corticomedullary differentiations are well maintained. There is no obvious focal or diffuse lesion noted. No evidence of any calculus seen in either kidney.


### PROSTATE

The Prostate appears normal and shows a normal echogenicity.

### URINARY BLADDER

The urinary bladder shows anechoic contents. Its wall thickness appears normal. No evidence of calcification is seen. There is no obvious evidence of abdominal or pelvic lymphadenopathy or ascites noted.

**IMPRESSION: No significant abnormality is detected.**

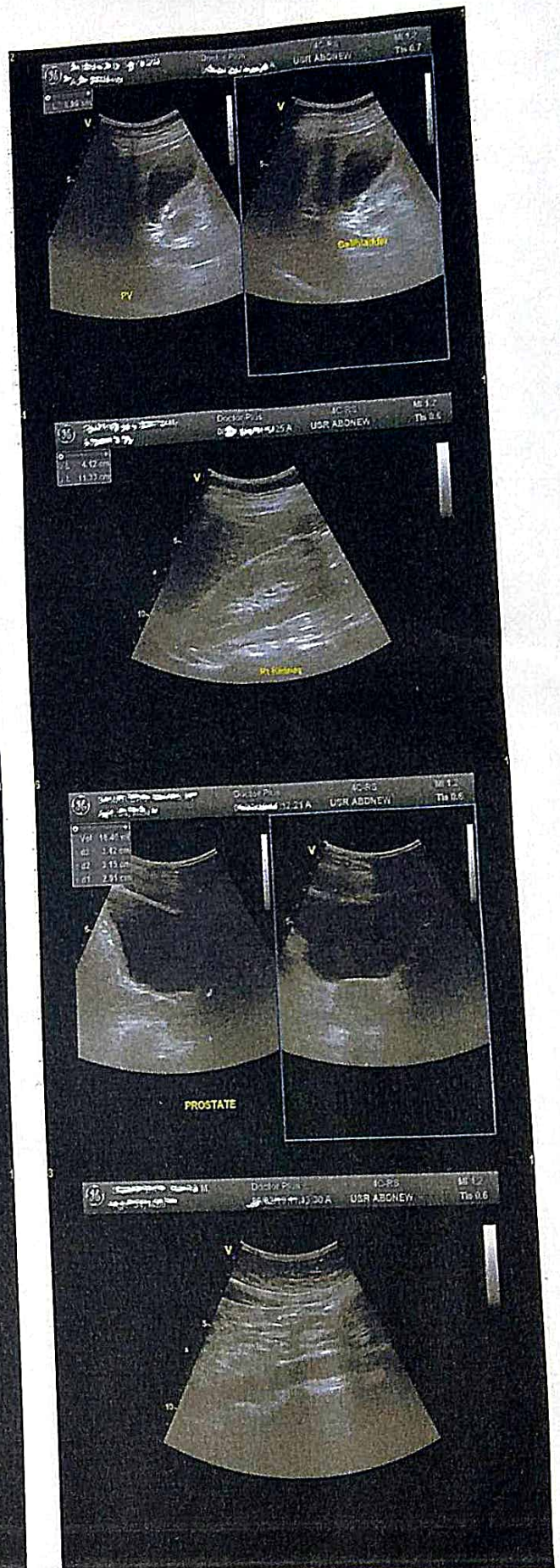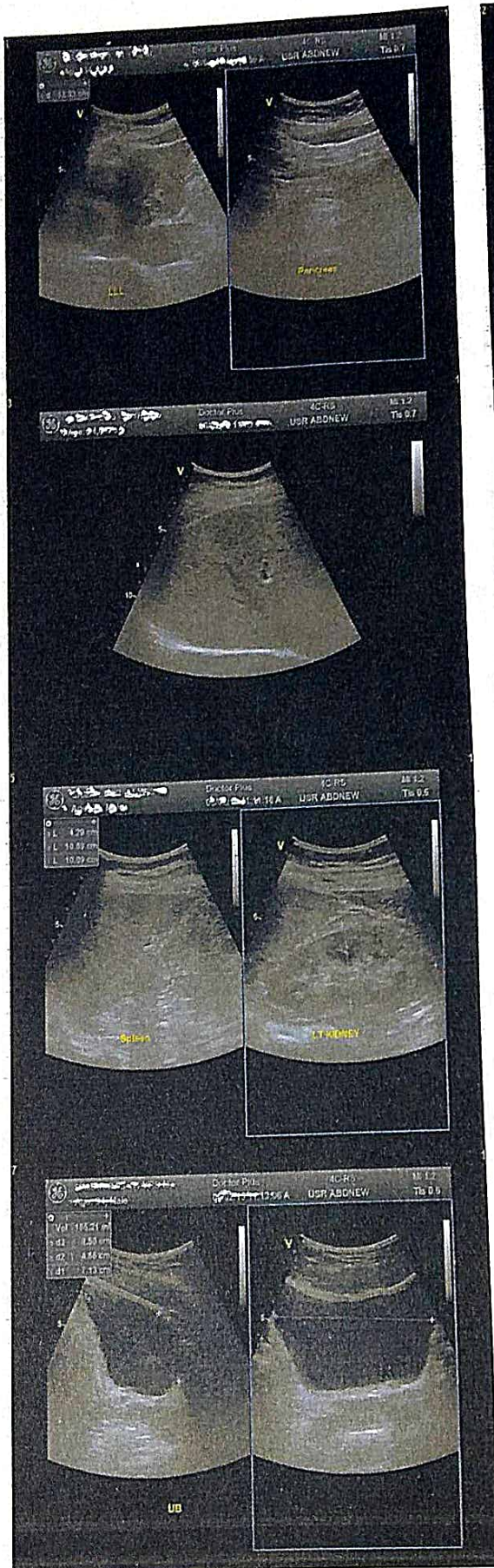
  
Dr. Parag Jha  
MBBS(BOM), DMRE(BOM)  
Radio-Sonologist

**'DR. PLUS HEALTHCARE CENTRE'  
NATHANI HEIGHTS', B-WING.  
42, MUMBAI CENTRAL (EAST)**

Name SHONMIPAN KASOMWOSHI

Sex Male

Age 33





# Dr-Plus Healthcare Centre

NATHANI HEIGHTS, B-Wing, Shop No. 42, Ground Floor, Opp. Mumbai Central Station (East), Mumbai - 400 008.

NAME : SHIONMIPAN KASOMWOSHI

33/M

DATE:08/09/2021

REF BY : DR. PURVI CHHABLANI

## 2D-ECHO. AND COLOR DOPPLER REPORT

- NORMAL CARDIAC VALVES WITH TRIVIAL TR.
- NORMAL CARDIAC CHAMBERS
- NO E/O REGIONAL WALL MOTION ABNORMALITY. WITH NORMAL LVEF OF 63 %.
- NO E/O PULMONARY HYPERTENSION. PASP 32 mmHg by TR jet.
- NO E/O LEFT VENTRICULAR HYPERTROPHY.
- NO E/O DIASTOLIC DYSFUNCTION.
- NO E/O PERICARDIAL EFFUSION.
- NO E/O INTRACARDIAC CLOT OR VEGETATIONS.
- INTACT IAS/IVS
- CONVENTIONL DOPPLER :

E TO A RATIO IS MORE THAN ONE IN LV INFLOW.


THERE IS NO GRADIENT ACROSS AV, LVOT OR RVOT.

PASP FROM TR JET IS .32 mm OF Hg.

- COLOUR DOPPLER:

TRIVIAL TR

EF Slope	114	mm/sec		
Opening Amplitude	17			
Posterior leaflet				
E.P.S.S	02	mm		
Mitral valve prolapse				
Vegetations				
TRICUSPID VALVE	OBSERVED	NORMAL VALUES		
PULMONARY VALVE	OBSERVED	NORMAL VALUES		
EF Slope				
'A' Wave				
Midsystolic notch				
Flutter				
Other Findings				
AORTIC VALVE	OBSERVED	NORMAL VALUES		
Cuspal opening	17	mm		
Closure line	Central			
Eccentricity index	1			
Other Findings				
DIMENSIONS	OBSERVED	NORMAL VALUES		
1. Lvd (Diastolic)	41	26-52		
2. Lvd (Systolic)	32	24-42mm		
3. RVD (Diastolic)	17	7-23mm		
4. IVST (Diastolic)	09	6-11mm		
5. IVST (Systolic)	15			
6. LVPWT (Diastolic)	09	6-11mm		
7. LVPWT (Systolic)	16			
8. Aortic root	30	22-37mm		
9. left Atrium	37	19-40mm		
	STRUCTURE	REGURG GRADING	VELOCITY m/sec	STENOSIS GRADIENT mm/Hg
			Max      mean	Peak mean
MITRAL VALVE	NORMAL	0/3	/	/
TRICUSPID VALVE	NORMAL	TRIVIAL	/	/
PULMONARY VALVE	NORMAL	0/4	/	/
AORTIC VALVE	NORMAL	0/4	/	/

  
**DR. P.H. CHHABLANI**  
 M.B.B.S, DNB. (MEDICINE)  
 CONSULTANT PHYSICIAN AND CARDIOLOGIST.

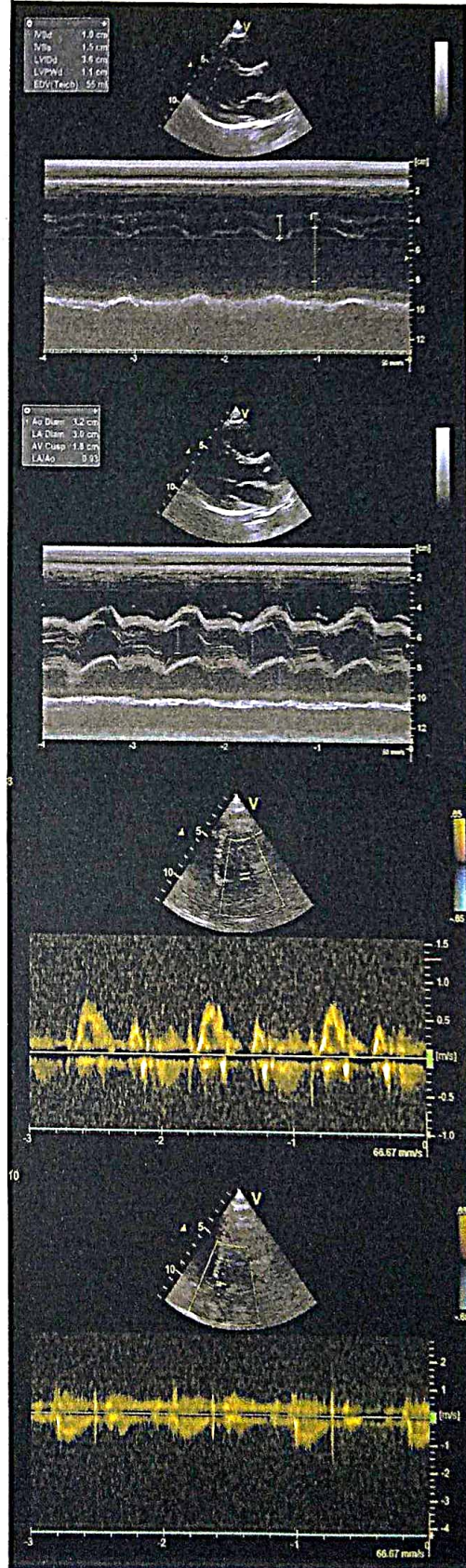
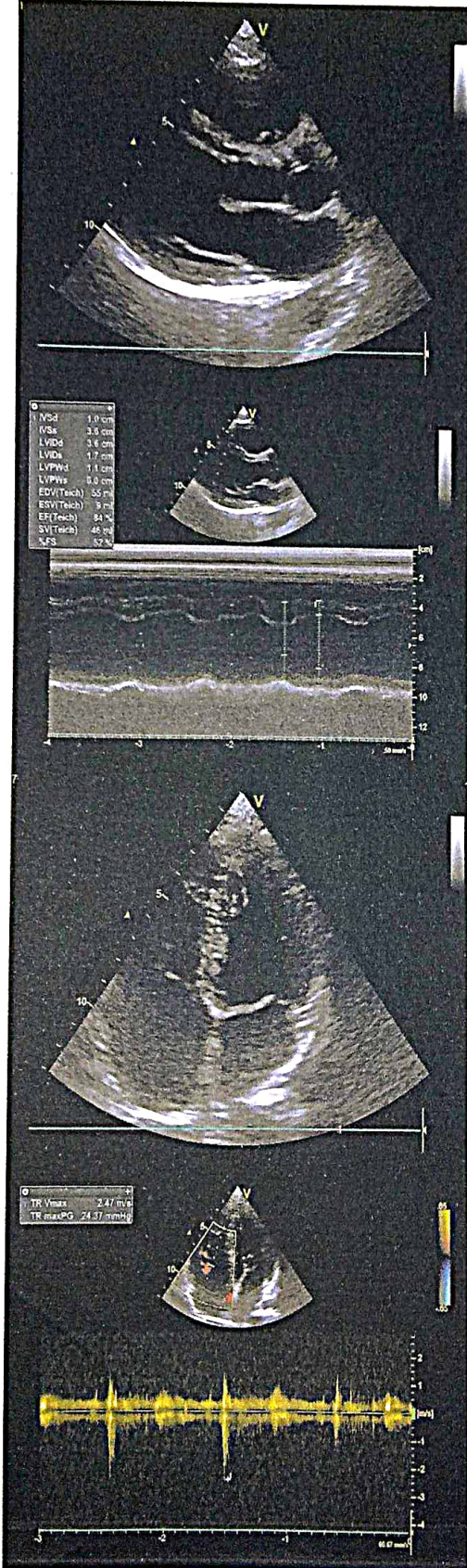
**DR. PURVI CHHABLANI**  
 MBBS DNB. (Medicine)  
 Consultant Physician And Intensivist  
 Reg No 7769F

Name SHONMIPAN KASOMWOSHI

Sex Male

Age 33

Date 08/09/2021





# Dr-Plus Healthcare Centre

NATHANI HEIGHTS, B-Wing, Shop No. 42, Ground Floor, Opp. Mumbai Central Station (East), Mumbai - 400 008.

Patient's Name : SHONMIPAN KASOMWOSHI

Report Date : 08/09/2021

Referred By : DR.HARI CHHABLANI

Age : 33 Years

Sex : MALE

## X- RAY CHEST

BOTH THE LUNG FIELDS ARE CLEAR .

THE HILAR SHADOWS APPEAR NORMAL.

THE COSTO -PHRENIC ANGLES ARE CLEAR.

THE CARDIAC SHADOWS APPEAR NORMAL.

THE TRACHIA IS CENTRAL IN POSITION.

THE BONY CAGE APPEARS NORMAL.

  
DR. A. J. MAZUMDAR

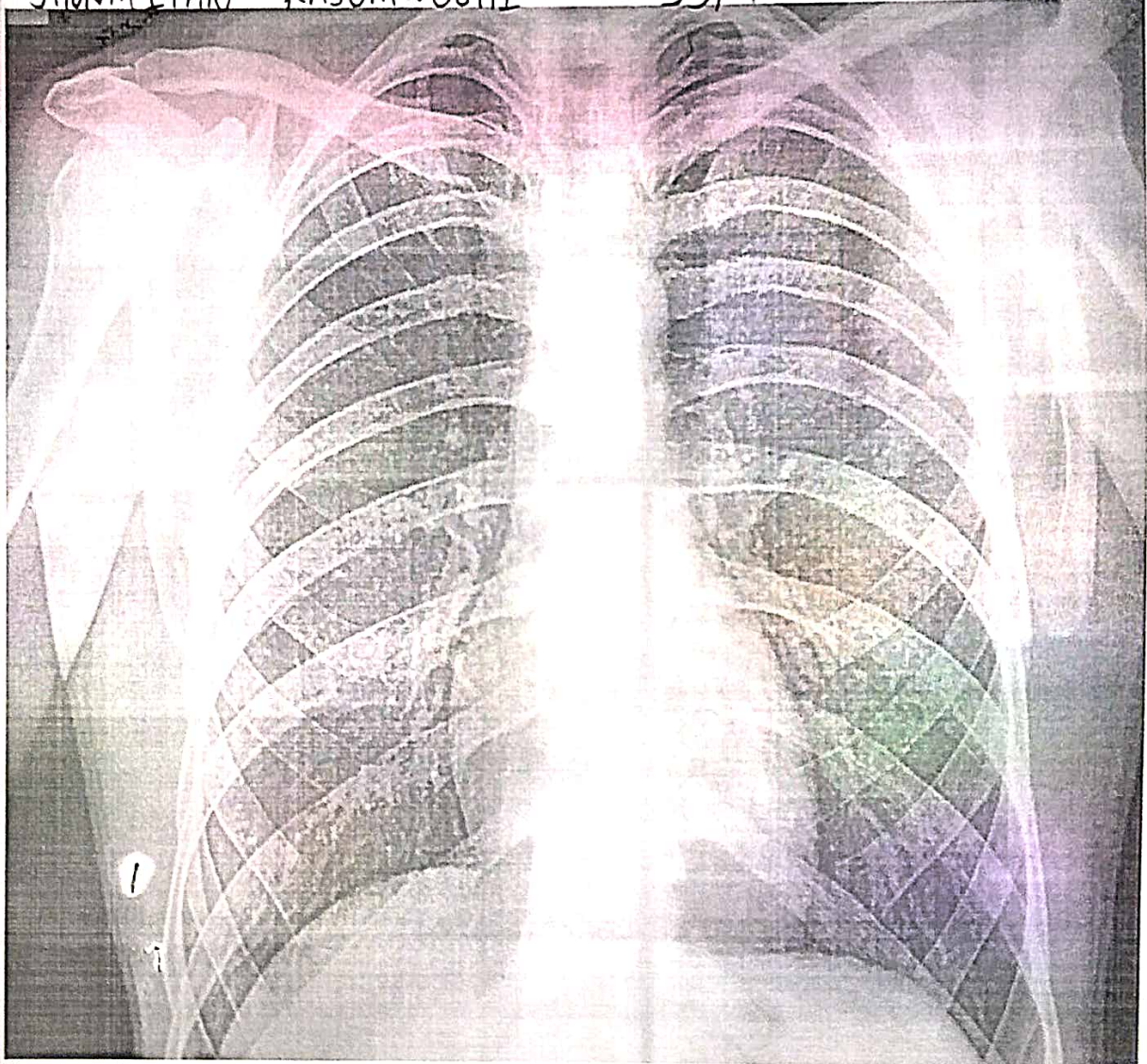
MD. DMRE, MDRD

**'DR. PLUS HEALTHCARE CENTRE'  
NATHANI HEIGHTS', B-WING,  
42, MUMBAI CENTRAL (EAST)**

SHONMIPAN KASOMWOSHI

33/M

08/09/2021







# Dr-Plus Healthcare Centre

NATHANI HEIGHTS, B-Wing, Shop No. 42, Ground Floor, Opp. Mumbai Central Station (East), Mumbai - 400 008.

Full Name of life to be assured:

SHONMIPAN KASOMWOSHI

33/M

DATE:08/09/2021

## HAEMOGRAM

### Normal Range

1.	Red Blood Cell Count	4.5	[M : 4.5 - 5.6 / F : 3.5 - 5.5/cu.mm]
2.	Hb%	15.2	[M: 14-18 / F : 11-16%]
3.	Hematocrit	48	[M : 40-53 / F : 30-47 %]
4.	Indices:		
(a)	MCV(Mean Corpuscular Volume)	88	[79-101 cu.mi.]
(b)	MCH(Mean Corpuscular Hb)	31	[27-32 pg]
(c)	MCHC(Mean Corpuscular Hb Concentration)	33	[32-38%]
5.	Morphology		
	Macrocytes :	--	Microcytes: -- Hypochromia: --
	Piokilocytosis:	--	Anisocytosis: --
6.	Target cells:	--	
	Spherocytes:	--	Elliptocytes: --
7.	<b>TOTALW.B.C.Count</b>	6,200	{4000-11000/cu.mm}
Differential Count0			
a)	Neutrophils :	58	[45 - 70%] c) Eosinophils: 04 [01 - 06%]
b)	Lymphocytes :	32	[20 - 45%] d) Monocytes: 06 [00 - 08%]
e)	Basophils :	01	[00 - 01%]
8.	Platelets : 2.92	1.5-4.5 Lacks/cu.mm	
9.	Erythrocyte Sedimentation Rate:12	20 mm at end of 1 hour	Method : Westergrens

## ROUTINE URINE EXAMINATION (RUA)

### 1. Physical Examination:

(i)	Colour:	PALE YELLOW	(ii)	Sediment:	CLEAR
(iii)	Transparency:	ABSENT	(iv)	Reaction:	ACIDIC
(v)	Specific gravity	1.005			

### 2. Chemical Examination:

(i)	Protein :	ABSENT	(ii)	Sugar:	ABSENT
(iii)	Bile salt:	ABSENT	(iv)	Bile pigment:	ABSENT

### 3. Microscopic Examination:

(i)	Red Blood Cells:	ABSENT	(ii)	Epithelial Cells:	ABSENT
(iii)	Crystals:	ABSENT	(iv)	Pus Cells:	02 TO 03/HPF
(v)	Casts:	ABSENT	(vi)	Deposits:	ABSENT
(vii)	Bacteria's :	ABSENT			

DR. PRAKESH PATKAR  
M.D., D.N.B. (Pathology)  
Reg. No. 2013/05/1660



# Dr-Plus Healthcare Centre

NATHANI HEIGHTS, B-Wing, Shop No. 42, Ground Floor, Opp. Mumbai Central Station (East), Mumbai - 400 008.

Full Name:

SHONMIPAN KASOMWOSHI

33/M

DATE:08/09/202

	Type of Test	Actual Reading	Normal Range
1	Fasting Blood Sugar	--	70-100 mg%
2	PPBS	130	110 TO 140 mg%
3	Total Cholesterol	185	120-200 mg%
4	VERY LOW DENSINTY LEVEL(VLDL)	20	10-30 mg/dl
5	High Density Lipid (HDL)	55	40-60 mg%
6	Low Density Lipid (LDL)	110	Upto 150
7	S. Triglycerides	130	50-150 mg%
8	CHOL/HDL	3.3	Upto 5
9	HDL/LDL	05	
10	S. Creatinine	0.9	0.5-1.2 mg%
11	Blood Urea Nitrogen (BUN)	14	7-21 mg%
12	BUN/CREAT RATIO	15.5	
13	S. Proteins	6.6	6.0-7.9 mg%
14	(a) Albumin	3.5	3.5-5.5 mg%
15	(b) Globulin	3.1	2.0-3.5 mg%
16	A/G RATIO	1.12	
17	S. Bilirubin	0.9	0.3-1.3mg%
18	(a) Direct	0.6	0.0-0.8 mg%
19	(b) Indirect	0.3	0.0-0.5 mg%
20	SGOT (AST)	25	05-34 IU
21	SGPT (ALT)	30	05-40 IU
22	GGTP (GGT)	41	05-50 IU
23	SGOT/SGPT	0.8	
24	HBA1C	5.5	UPTO 6.5
25	S. Alkaline Phosphatase	90	30-115 IU
26	T3	119	80-180ng/dl
27	T4	9.1	4.6-12 ug/dl
28	TSH	3.0	0.4-4.0 mIU/L
29	SERUM URIC ACID	5.2	2.5-7.2mg/dl
30	URINE SUGAR PP	ABSENT	
31	URINE SUGAR FASTING	--	
32	BLOOD GROUP	"A"POSITIVE"	

DR. RAKESH PATKAR  
M.D., D.N.B. (Pathology)  
Reg. No. 2013/05/1660



# Dr-Plus Healthcare Centre

NATHANI HEIGHTS, B-Wing, Shop No. 42, Ground Floor, Opp. Mumbai Central Station (East), Mumbai - 400 098.

Full Name:

SHONMIPAN KASOMWOSHI

33/M

DATE:09/09/202

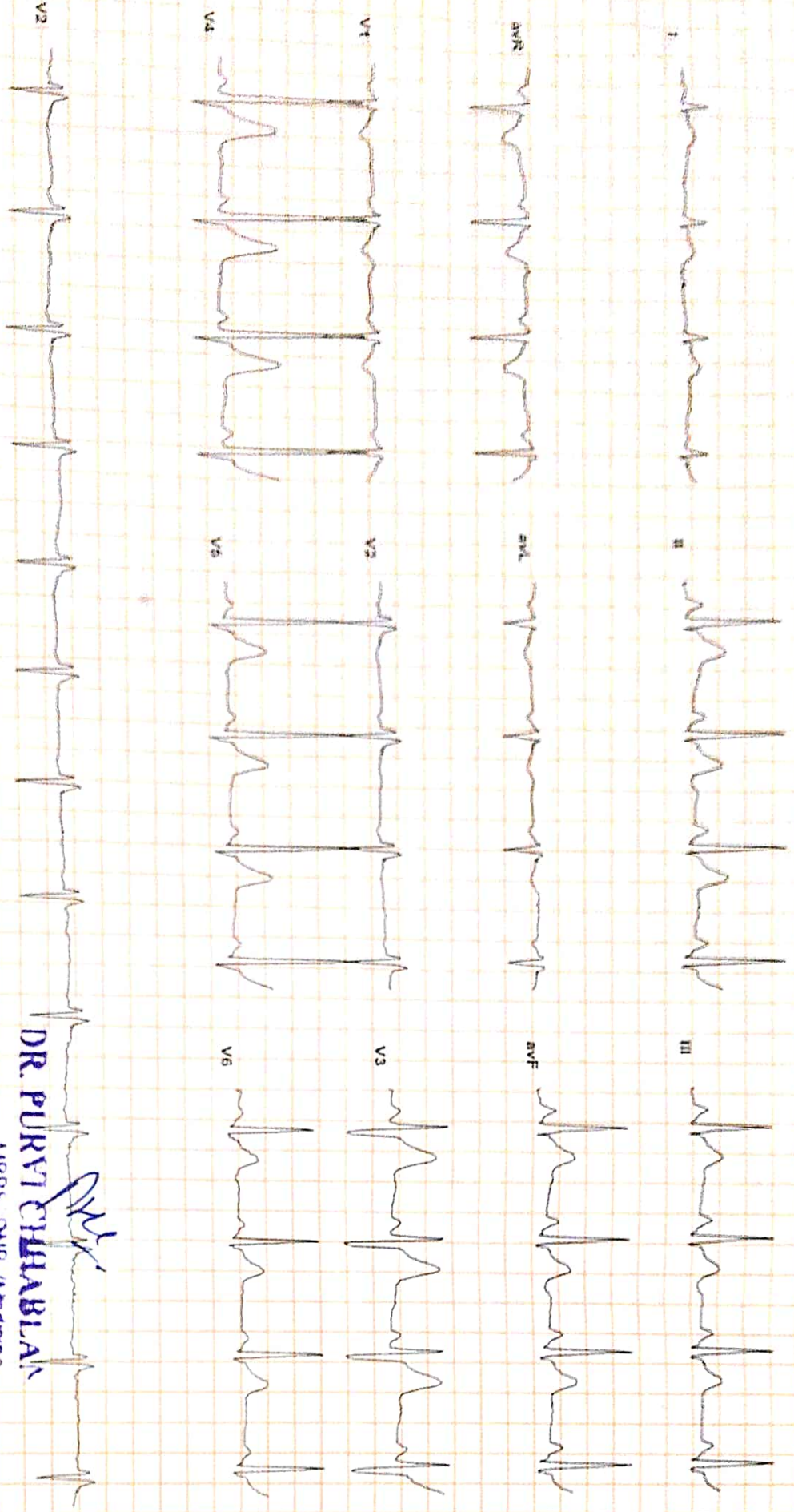
	Type of Test	Actual Reading	Normal Range
1	Fasting Blood Sugar	89	70-100 mg%
2	URINE SUGAR FASTING	ABSENT	

  
DR. RAKESH PATKAR  
M.D., D.N.B. (Pathology)  
Reg. No. 2013/05/1660

DR PLUS HEALTHCARE CENTRE - MUMBAI CENTRAL

1058 / SHONMIPAN KASOMWOSHI / 33 Yrs / M  
Heart Rate : 77 bpm / Tested On : 08-Sep-21 10:01:36 / HF 0.05 Hz - LF 100 Hz / Natch 50 Hz / SN 1.00 Cm/mV / Sw 25 mm/s  
/ Reled By : DR. HARI CHHABLANI

ECG



Consultant Physician And Intens.  
Reported By: DR. HARI CHHABLANI

DR. PURY CHHABLANI  
MBBS DNB (Medicine)

Wavelengths: ECG (Piscas)(PIS2162005339)

WNL



**Dr. Hari Chhablani**

Cardiometabolic Physician & Intensivist  
M.B.B.S., F.C.C.P (RESP. MED.), PGDHHM,  
PGDMLS, FELLOW INTENSIVE CARE MED.

ATTACHED TO: Wockhardt Hospital • Saifee Hospital • Apollo Spectra Hospital

NATHANI HEIGHTS, B-Wing, Shop No. 42, Ground Floor, Opp. Mumbai Central Station (East),  
Mumbai - 400 008. • Cell : 98206 46163 • E : drharichhablani@gmail.com

## PHYSICIAN REPORT

09/09/2021

NAME : SHONMIPAN KASOMWOSHI

AGE/SEX: 33/M

PRESENTING COMPLAINS: LUMBER DISC PROLAPSE ON PHYSIOTHERAPY SINCE 2014

PAST HISTORY: K/C/O ? HEPATITIS C

FAMILY HISTORY: NOT SIGNIFICANT

ADDICTION: NIL

P: 78/MIN

BP: 120/78

RS: CLEAR

CVS: S1,S2 REGULAR

PA: SOFT

CNS: CLINICALLY NAD

ECG: WNL

CXR: WNL

LABS: ATTACHED

EYE EXAMINATION B/E : NEAR VISION - BL N12 DISTANT VISION - 6/6 COLOUR VISION - NORMAL

ADVISED : MRI LUMBO - SACRAL SPINE , SONOGRAPHY ABDO - PELVIS

HBSAG , HCV , HIV

DR. HARI CHHABLANI

**DR. HARI CHHABLANI**  
M.B.B.S. & F.C.C.P. (RESP. MEDICINE) PGDHHM, PGDMLS  
FELLOW INTENSIVE CARE  
MMC REG. NO. - 91702

मुलींच्या पंढ्याची स्वागत करू  
मुलगी बाबका, दिव्य बाबका।

प्रसुतिपूर्व वििम तयारणी हातववा



- प्रसुति पूर्व वििम तयारणी करणे व  
उत्तर करणे वििम वििमन करण्यासाठी  
वििमन करणे, प्रसुति पूर्व वििमन करणे  
करणे
- वििम वििमन करणेचा वििमन  
वििमन करणे व वििमन करणेचा  
वििमन करणे व वििमन करणेचा  
वििमन करणे व वििमन करणेचा
- सर्व वििमन करणेचा वििमन  
वििमन करणेचा वििमन करणेचा  
वििमन करणेचा वििमन करणेचा  
वििमन करणेचा वििमन करणेचा

सर्व वििमन करणेचा वििमन करणेचा  
वििमन करणेचा वििमन करणेचा  
वििमन करणेचा वििमन करणेचा  
वििमन करणेचा वििमन करणेचा

www.mumbai.gov.in



Central  
SMART  
Google

**Mumbai, Maharashtra, India**  
Nathani Height Belasid Road, Shop Number 41, Jehangir Boman Behram Rd, Opposite Mumbai Central Station, Marzban Parsi Colony, Dalal Estate, Mumbai Central, Mumbai, Maharashtra 400008, India  
Lat 18.968765°  
Long 72.819972°  
08/09/21 09:16 AM

