

Facilities:
 All clinical Biomedical & Hematology Investigations
 including Bone Marrow Examination
 VPT, Podiascan & Complete Foot Care (First Time in Purvanchal)
 All Hormonal Investigation by Chemiluminescent Method
 Visceral Fat by (AB-140) Ambulatory BP Monitoring
 CGMS & Insulin Pump Available
 PFT, 2D-ECHO (Color Doppler), Holter, TMT, Cardiac-3 available
 VIA, VILI, Colposcopy available
 Special Endocrinological Investigation Protocols.

ISO 9001:2008 Certified
 Mobile: 9389994334, 9554572190, 9453837595



Panacea Pathology Clinical Reference Lab

Persistence, Preparedness and Precision
 EQAS (CMC Vellore Attached) & IQAS System
 पूर्वांचल की सर्वोत्तम गुणवत्ता वाली पैथोलॉजी

PATIENT NAME : VINAY PRAKASH MAURYA
 REFD BY DR. : ARCO FEMI HEALTHCARE LTD.
 SAMPLE : BLOOD & URINE

AGE/GENDER : 38YRS/MALE
 RECEIVED DATE : 30-03-2023 (10:00 AM)
 REPORT DATE : 01-04-2023 (07:00 PM)

PATHOLOGY REPORT

COMPLETE BLOOD COUNT (CBC)

TEST	LAB TEST VALUES	NORMAL RANGE
HEMOGRAM		
HEMOGLOBIN (FLOW CYTOMETRY)	15.9	13 – 16 gm/dl
TOTAL LEUCOCYTE COUNT (TLC)	5,600	4000 – 11000
RBC COUNT	5.02	3.5 – 5.5
PCV (HCT)	49.8	37 – 47
MCV	99.2	80 – 95
MCH	31.6	28 – 34
MCHC	31.9	30 – 36
PLATELET COUNT	1,80,000	1,50,000 – 4,00,000
E.S.R. (WINTROBE FIRST HOURS)	8.0	20 mm/1 st hr
DIFFERENTIAL LEUCOCYTE		
NEUTROPHILS	52	40 – 75%
LYMPHOCYTES	43	20 – 45%
EOSINOPHILS	02	1 – 6%
MONOCYTES	03	2 – 8%
BASOPHILS	00	< 2%

RANDOM/FASTING BLOOD SUGAR

TEST	LAB TEST VALUES	NORMAL RANGE
RBS/FBS		
RANDOM BLOOD SUGAR	229.0	125-140 mg/dl
FASTING BLOOD SUGAR	125.7	70-125 mg/dl

GLYCOSYLATED HEMOGLOBIN (HBA1C)

TEST	LAB TEST VALUES	NORMAL RANGE
HBA1C	7.9	Normal : <5.97 % Good Control : 5.97 – 6.81% Fair Control : 6.81 – 7.65% Poor Control : >7.65%

PAGE 1

Lab Technician

PANACEA HOSPITAL
 (A UNIT OF ARCO FEMI HEALTH CARE PVT. LTD.)
 REG. NO.: AL-1500
 B.36/44, B-4, KABIR NAGAR
 DURGAKUND, VARANASI

Timing : 8.00 a.m. to 9.00 p.m. (Sunday 8.00 a.m. to 3.00 p.m.)

This Report is not valid for medico legal purpose

Note: These tests have technical limitations. Clinico-pathological interpretation is necessary. In case of any disparity test may be repeated immediately.

Address : 36/44 FK Kabir Nagar, Durgakund, Varanasi – 221005

Email: dramishra@gmail.com, drpallaviojha@gmail.com Website: panaceahospital.org

Facilities:
 All clinical Biomedical & Hematology Investigations
 including Bone Marrow Examination
 VPT, Podiascan & Complete Foot Care (First Time in Purvanchal)
 All Hormonal Investigation by Chemiluminescent Method
 Visceral Fat by (AB-140) Ambulatory BP Monitoring
 CGMS & Insulin Pump Available
 PFT, 2D-ECHO (Color Doppler), Holter, TMT, Cardiac-3 available
 VIA, VILI, Colposcopy available
 Special Endocrinological Investigation Protocols.

ISO 9001:2008 Certified
 Mobile: 9389994334, 9554572190, 9453837595



Panacea Pathology

Clinical Reference Lab

Persistence, Preparedness and Precision
 EQAS (CMC Vellore Attached) & IQAS System
 पूर्वांचल की सर्वोत्तम गुणवत्ता वाली पैथोलॉजी

PATIENT NAME : VINAY PRAKASH MAURYA
 REFD BY DR. : ARCO FEMI HEALTHCARE LTD.
 SAMPLE : BLOOD & URINE

AGE/GENDER : 38YRS/MALE
 RECEIVED DATE : 30-03-2023 (10:00 AM)
 REPORT DATE : 01-04-2023 (07:00 PM)

PATHOLOGY REPORT

LIPID PROFILE, SERUM

TEST	LAB TEST VALUES	NORMAL RANGE
BLOOD CHEMISTRY		
TOTAL CHOLESTEROL (SERUM)	165.0	Desirable:- < 200 mg/dl Borderline:- 200 – 239 mg/dl High:- > 240 mg/dl
TRIGLYCERIDES (SERUM)	153.0	35 – 170 mg/dl
HDL CHOLESTEROL (SERUM)	45.0	35.30 – 79.50 mg/dl
LDL CHOLESTEROL (SERUM)	89.4	< 130 mg/dl
VLDL	30.6	< 40 mg/dl
CHOLESTROL/HDL RATIO	3.66	< 3.0 Low Risk Ratio 3.0 – 5.0 Avg Risk < 5.0 High Risk
LDL/HDL RATIO	1.98	< 3 Ratio

BLOOD GROUP

TEST	LAB TEST VALUES
BLOOD GROUP ABO & RH FACTOR	
BLOOD GROUP	"A"
RH FACTOR	POSITIVE

LIVER PROFILE TEST, SERUM

TEST	LAB TEST VALUES	NORMAL RANGE
BIO CHEMISTRY		
TOTAL BILIRUBIN	0.69	0.0 – 1.1 mg/dl
DIRECT BILIRUBIN	0.28	0.0 – 0.2 mg/dl
INDIRECT BILIRUBIN	0.41	< 0.90 mg/dl
SGOT (AST)	18.0	0 – 52 mg/dl
SGPT (ALT)	22.0	0 – 39 mg/dl
GGT (GYT)	18.5	< 55 U/L

THYROID PROFILE (T3, T4, TSH)

TEST	LAB TEST VALUES	NORMAL RANGE
THYROID FUNCTION TEST		
T3	0.91	0.60 – 1.81 ng/ml
T4	7.41	4.50 – 10.90 ug/dl
TSH	1.02	0.39 – 6.10 uIU/ml

PAGE 2

Lab Technician

PANACEA HOSPITAL
 (A UNIT OF AAROHA HEALTHCARE LTD.)
 REG. NO.: AL/179
 B.36/44 B-1, KABIR NAGAR
 DURGAKUND, VARANASI
 M.D., Pathology

Timing : 8.00 a.m. to 9.00 p.m. (Sunday 8.00 a.m. to 3.00 p.m.)

This Report is not valid for medico legal purpose

Note: These tests have technical limitations. Clinico-pathological interpretation is necessary. In case of any disparity test may be repeated immediately.

Address : 36/44 FK Kabir Nagar, Durgakund, Varanasi – 221005

Email: dramishra@gmail.com, drpallaviojha@gmail.com Website: panaceahospital.org

Facilities:
 All clinical Biomedical & Hematology Investigations
 including Bone Marrow Examination
 VPT, Podiascan & Complete Foot Care (First Time in Purvanchal)
 All Hormonal Investigation by Chemiluminescent Method
 Visceral Fat by (AB-140) Ambulatory BP Monitoring
 CGMS & Insulin Pump Available
 PFT, 2D-ECHO (Color Doppler), Holter, TMT, Cardiac-3 available
 VIA, VILI, Colposcopy available
 Special Endocrinological Investigation Protocols.

ISO 9001:2008 Certified
 Mobile: 9389994334, 9554572190, 9453837595



Panacea Pathology

Clinical Reference Lab

Persistence, Preparedness and Precision
 EQAS (CMC Vellore Attached) & IQAS System
 पूर्वांचल की सर्वोत्तम गुणवत्ता वाली पैथोलॉजी

PATIENT NAME : VINAY PRAKASH MAURYA	AGE/GENDER : 38YRS/MALE
REFD BY DR. : ARCO FEMI HEALTHCARE LTD.	RECEIVED DATE : 30-03-2023 (10:00 AM)
SAMPLE : BLOOD & URINE	REPORT DATE : 01-04-2023 (07:00 PM)

PATHOLOGY REPORT

RENAL & KIDNEY PROFILE, SERUM

TEST	LAB TEST VALUES	NORMAL RANGE
RENAL FUNCTION TESTS		
BLOOD UREA NITROGEN (BUN)	10.2	10 – 50 mg/dl
SERUM CREATININE	0.97	0.60 – 1.60 mg/dl
URIC ACID	3.56	3.60 – 7.70 mg/dl
ALKALINE PHOSPHATASE (ALP)	71.0	142 – 353 mg/dl
TOTAL PROTIENS	7.56	0 – 39 mg/dl
ALBUMIN	4.40	3.8 – 5.4 mg/dl
SERUM GLOBULIN	3.16	2.1 – 3.5 mg/dl
AG RATIO	1.39	-
CALCIUM	9.02	8.80 – 10.20
PHOSPHORUS	3.04	2.50 – 5.00
SERUM SODIUM NA+	137.6	135.00 – 155.00 mEq/Ltr
SERUM POTASIUM K+	4.32	3.60 – 5.50 mEq/Ltr
ICALCIUM	1.24	1.10 – 1.35 mmol/L
SERUM CHLORIDE CL+	105.9	98.00 – 110.00 mEq/Ltr

URINE ROUTINE EXAMINATION

TEST	LAB TEST VALUES	NORMAL RANGE
PHYSICAL EXAMINATION		
QUANTITY	25	ML
COLOUR	STRAW	PALE YELLOW
APPEARANCE	CLEAR	CLEAR
SPECIFIC GRAVITY	1.015	1.01 – 1.03
PH	6.0	4.7 – 7.5
CHEMICAL EXAMINATION		
GLUCOSE	Not Detected	Not Detected
PROTEIN	NIL	Not Detected
MICROSCOPIC EXAMINATION		
PUS CELLS	01-02	0-5
RBC	Not Detected	Not Detected
EPITHELIAL CELLS	01-05	0-5
CASTS	Not Detected	Not Detected
CRYSTALS	Not Detected	Not Detected
BACTERIA	Not Detected	Not Detected

----- End of Report -----

Lab Technician

PANACEA HOSPITAL
 (A UNIT OF AAROHA HEALTH CARE PVT. LT.)
 REG. NO.: AL-1500
 B.36/44B-1, KABIR NAGAR
 DURGAKUND, VARANASI

Timing : 8.00 a.m. to 9.00 p.m. (Sunday 8.00 a.m. to 3.00 p.m.)

This Report is not valid for medico legal purpose

Note: These tests have technical limitations. Clinico-pathological interpretation is necessary. In case of any disparity test may be repeated immediately.

Address : 36/44 FK Kabir Nagar, Durgakund, Varanasi – 221005

Email: dramishra@gmail.com, drpallaviojha@gmail.com Website: panaceahospital.org



PANACEA HOSPITAL

B 36/44 F.K KABIR NAGAR, DURGAKUND
TOLLFREE NO-18001233070.
Whatsapp No - 8795832852
www.piire.org



OP Slip

Print Date : 30-Mar-2023 10:33AM



UHID No :- UD-22230004218	OP No :- OP-22230015418	OP Date :- 30 Mar 2023 10:32AM
Patient Name :- Mr VINAY PRAKASH MOURYA BOB	Age/Sex :- 39 Y/Male	Mobile No :- 8600108474
Father :-	Department :- DIABETES, ENDOCRINOLOGY & METABOLIC PHYSICIAN	
Pay Type :- Cash	Consultant :- Dr ASHUTOSH MISHRA (MD(MEDICINE), IMS, BHU)	
Token No :- NOR. - 2	Paid/Bal :- 0.00 / 500.00 ✓	
Patient Type :- Normal		
Address :- BOB, varanasi		

BP :- 100/70 Rx
 height :- 170
 Weight (kg) :- 75.6
 BMI :-

SPO2 - 96

PR - 87

RBS - 136

WC - 90

NC - 34

PEFR - 220

700

Type DM.

Rx. Cap. Febenic-L 00

Tab. Diabemas-M. (500/10)

Es. Roumey (20) 00

Tab. FLY (180) 00

Rx. Adv. Airs PR (200)

0-10

Rx. 4 days

Printed By : Mr NITIN YADAV

Created By : Mr NITIN YADAV

2011.08.28

BPL

AUTO 10mm/mV

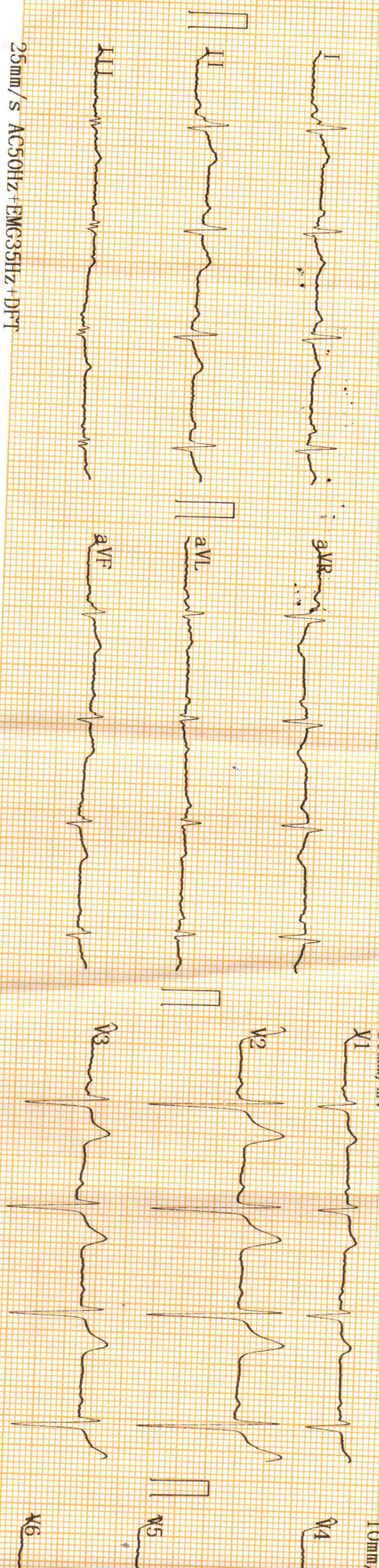
10mm/mV

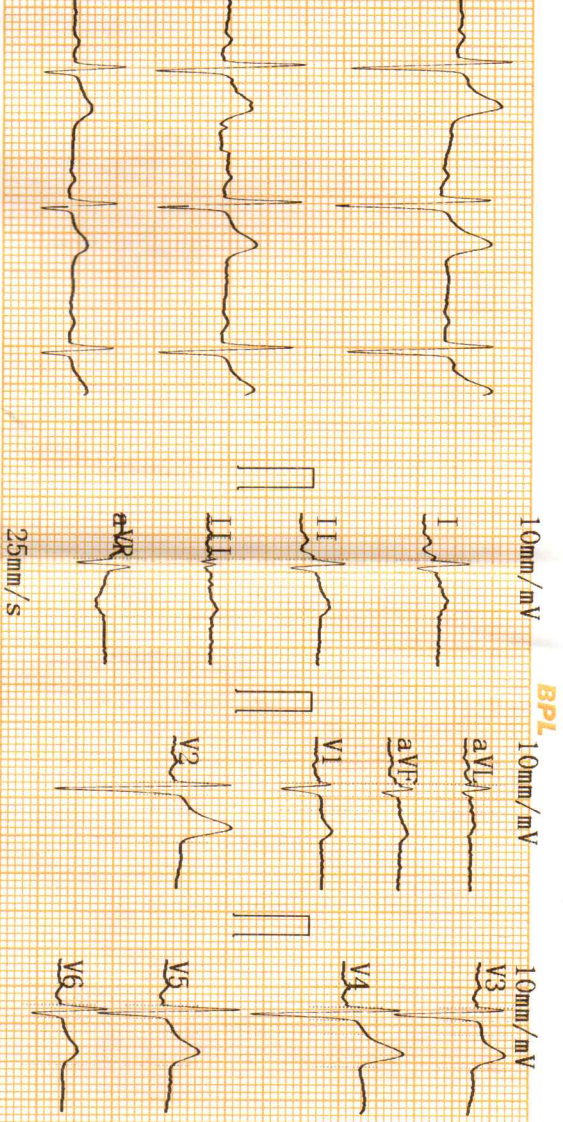
10mm/mV

10mm/mV

25mm/s AC50Hz+EMG35Hz+DFP

CARDIART





2022-03-30 10:28

<< Conclusions >>

ID :
 Name : **Vijay Prakash Mawry** Cardiac electric axis normal
 Sex : **M**
 Height : **39y** Age : **39y**
 SYS : Weight : **kg**
 DIA :
 Report need physician confirm

HR : 81 bpm
 PR Interval : 111 ms
 P Duration : 120 ms
 QRS Duration : 77 ms
 T Duration : 175 ms
 QT/QTc : 327/380 ms
 P/QRS/T Axis : 151.7/33.9/49.9 deg
 R(V5)/S(V1) : 1.01/0.49 mV
 R(V5)+S(V1) : 1.50 mV

Physician

DR. MILAVI MISHRA
 MBBS, MD (GENERAL MEDICINE)
 MCI Reg. No. 52033



Call Now - 1800-123-3070

PANACEA HOSPITAL

A shelter for many hearts A Home for many lives

(An ISO 9001:2008 Certified Organisation)

Lab Attached with CMC Vellore Under EQAS Scheme

PATIENT'S NAME : MR.VIJAY PRAKASH
REF. BY : Dr. ASHUTOSH MISHRA(MD)

AGE/SEX: 39 Y/M
Thursday, March 30, 2023

Echo - Cardiography

MITRAL VALVE Doppler	AML - normal morphology MV Flow - E - 0.6 A-0.4 E/A=1.39	PML - normal morphology MVA - 3.0 cm ² Mitral Regurgitation - No
TRICUSPID VALVE Doppler	Normal TV Flow -No	Tricuspid Regurgitation - No
PULMONARY VALVE Doppler	Normal PV Flow -No	Pulmonary Regurgitation - No
AORTIC VALVE Doppler	Trileaflet-No AV Flow - no	Aortic Regurgitation - no
MEASUREMENT	Aorta - 26.8 (20-38) mm IVS ed - 10.3 (6 -12) mm LVID ed -38.8 (35 - 55) mm LVPW ed - 28.6 (6 -12) mm OA - 7 (> 5) mm	LA - 28.0 (24-32) mm IVS es -13.7 (6 - 12) mm LVID es - 14.8 (24 - 40) mm LVPW es -12.0 (6 -12) mm EPSS - 4 (< 9) mm

CONCLUSION All cardiac chamber dimensions are WNL
No valvular abnormalities
Normal LV systolic function present Modified Simpson's method (4C, 2C) (LVEF=52%)
No diastolic dysfunction present (E/A = 1.39) by tissue Doppler (E/e'=6.2)
No RWMA
No pericardial effusion
Intact IAS / IV
No PAH
No intra cardiac mass /thrombus /vegetation

IMPRESSION **Normal Echocardiogram**

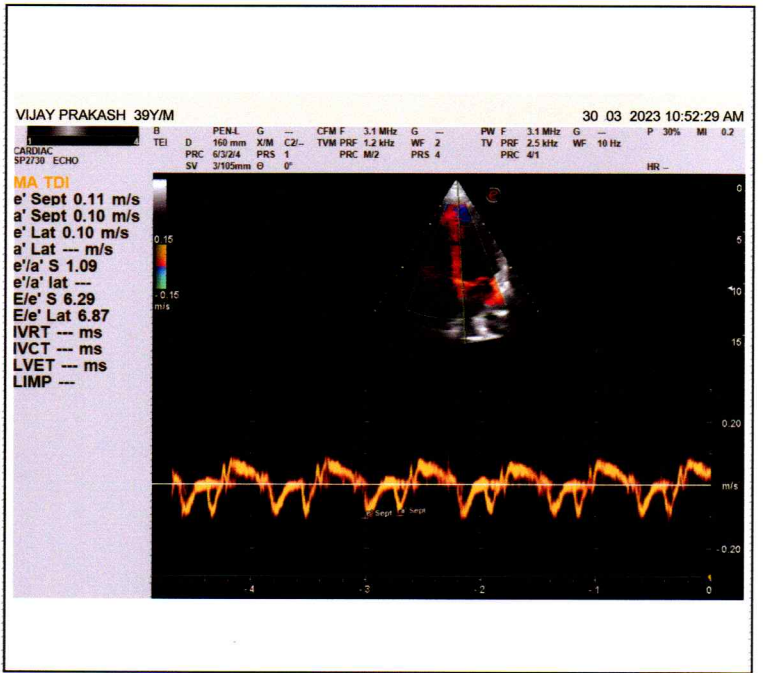
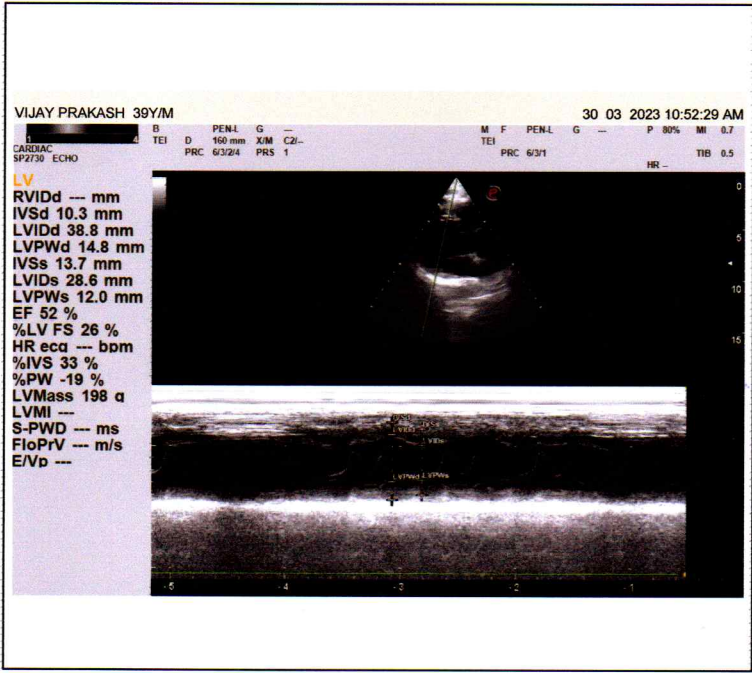
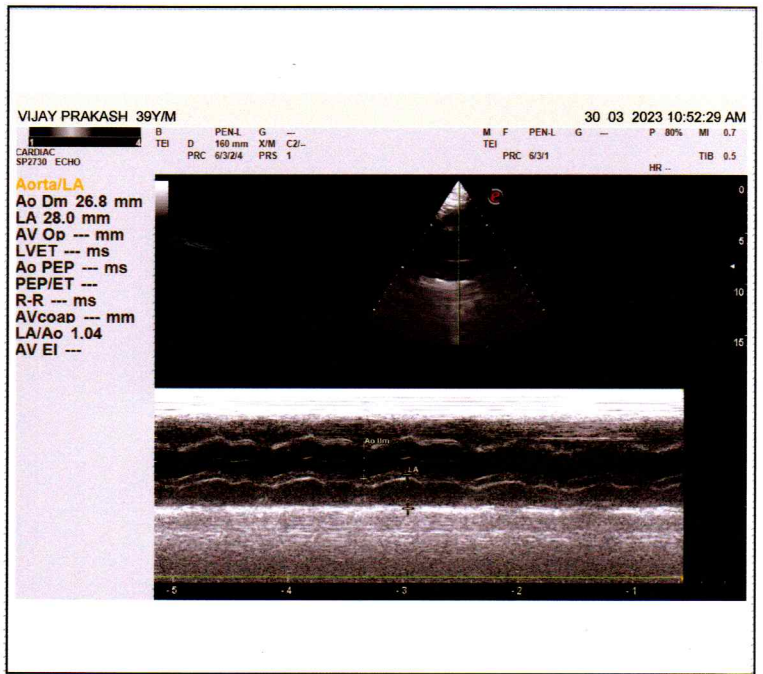
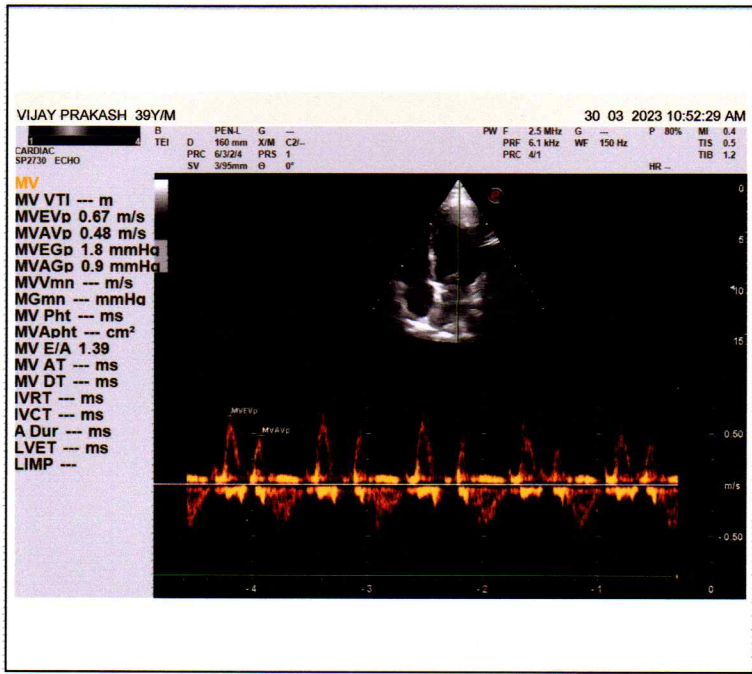
Niraj Mishra
Physician Assistant
(PIIRE)

Dr. Pallavi Mishra
MBBS, MD (MED) Lucknow
Echocardiography Specialist, MIAE
Non-invasive cardiologist
Women Cardiologist
Diabetocardiologist

Address : Kabir Nagar (Near Sanjay Shiksha Niketan), Durgakund, Varanasi

Mobile : 9554572190 / 9453837595 / Recpn. 9389994334

E-mail : dramishra@gmail.com, drpallaviojha@gmail.com, Website: www.piire.org





Call Now - 1800-123-3070

PANACEA HOSPITAL

A shelter for many hearts A Home for many lives

(An ISO 9001:2008 Certified Organisation)

Lab Attached with CMC Vellore Under EQAS Scheme

PATIENT'S NAME : VIJAY PRAKASH	AGE/SEX: 39 Y/M
REF. BY : Dr. ASHUTOSH MISHRA(MD)	Thursday, March 30, 2023

U/S. WHOLE ABDOMEN

- LIVER** : Liver is normal in size(11.7 cm), shape & echotexture. Intra hepatic biliary radicals are normal. Portal venous channels are normal.
- G. B.** : Gall bladder is normal in size, lumen is clear. Wall thickness normal.
- C.B.D.** : C.B.D. is normal in caliber.
- PANCREAS** : Pancreas is normal in size, shape and echotexture. No evidence of any inflammatory disease or mass.
- SPLEEN** : Spleen is normal in size(8.9 cm), shape and echotexture.
- Rt. KIDNEY** : Normal in size, shape and echotexture. Renal sinus is normal
Cortico medullary differentiation is normal. P. C. system is normal.
- Lt. KIDNEY** : Normal in size, shape and echotexture. Renal sinus is normal
Cortico medullary differentiation is normal. P. C. system is normal.
- URI. BLADDER** : Urinary bladder is normal in size, position. Wall thickness normal.
- PROSTATE** : Prostate is normal in size.
No ascites & retro peritoneal lymphadenopathy seen.
- IMPRESSION** : **NO OBVIOUS SONOLOGICAL ABNORMALITY SEEN.**

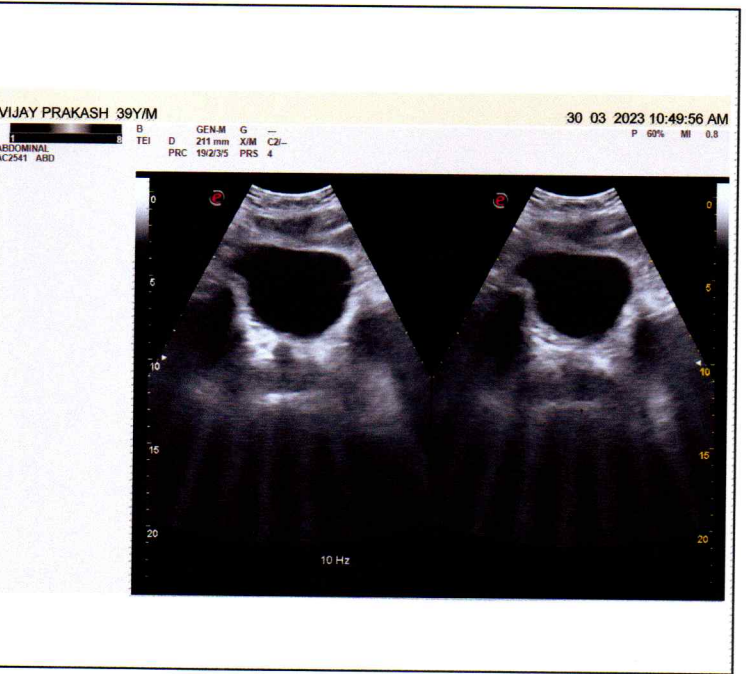
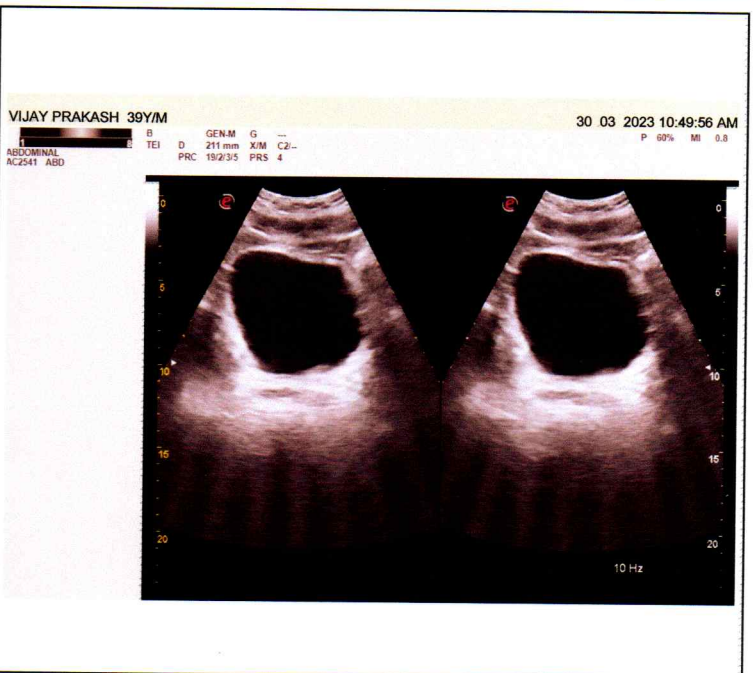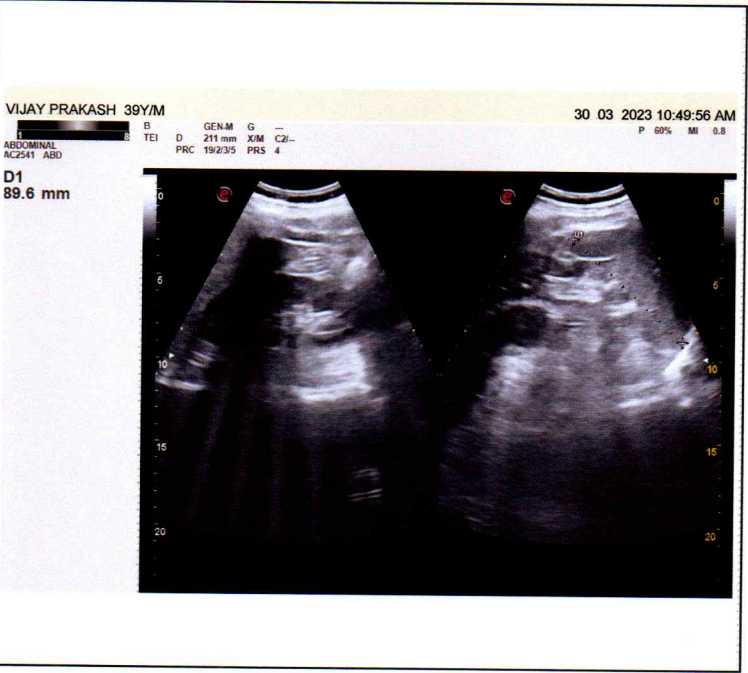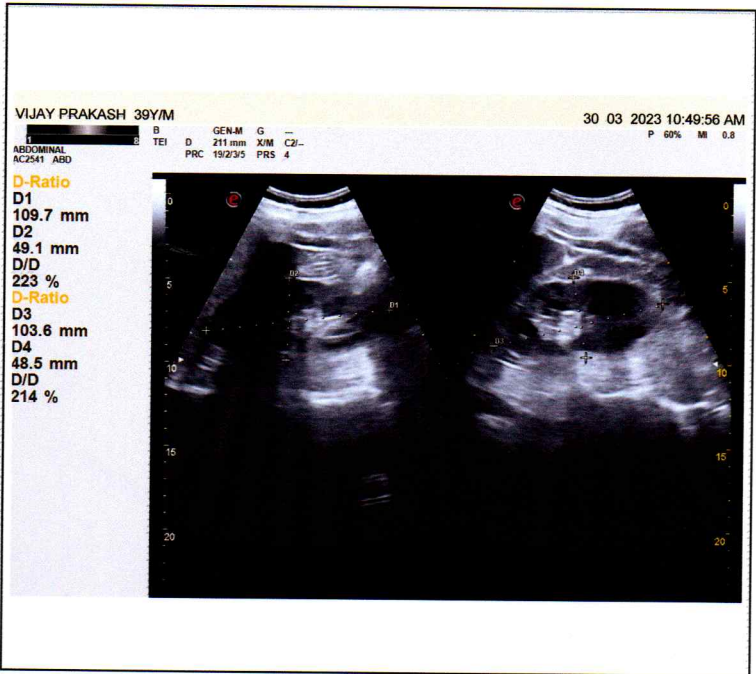
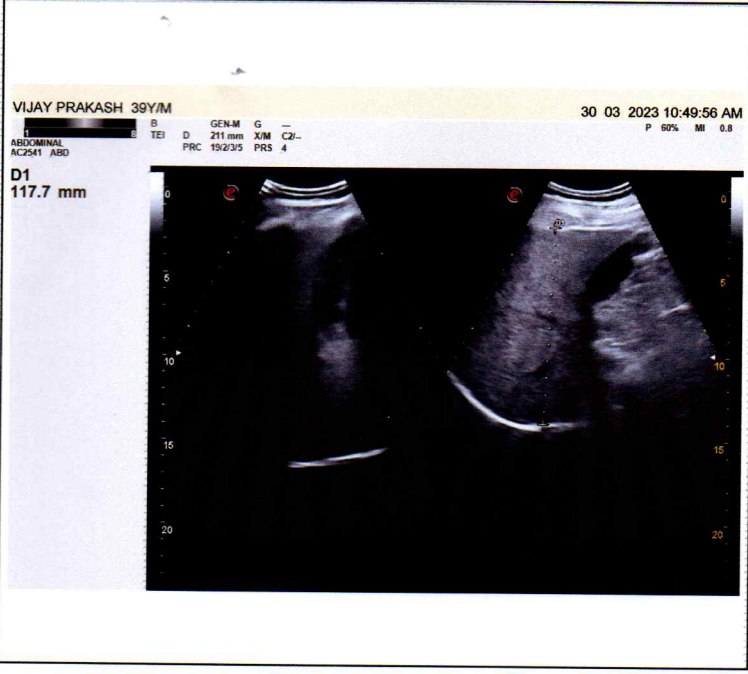
DR. R. TIWARI
(M.B.B.S, M.D.(KGMU, LKO)
(RADIODIAGNOSIS).

Thanks for reference.

Address : Kabir Nagar (Near Sanjay Shiksha Niketan), Durgakund, Varanasi

Mobile : 9554572190 / 9453837595 / Recpn. 9389994334

E-mail : dramishra@gmail.com, drpallaviojha@gmail.com, Website: www.piire.org



R
PA

VINAY PRAKASH MAURYA 39YIM O CHEST P.A. 30-Mar-23 10:03 AM

PANACEA HOSPITAL, KABIR NAGAR, DURGAKUND, VARANASI



Call Now - 1800-123-3070

PANACEA HOSPITAL

A shelter for many hearts A Home for many lives

(An ISO 9001:2008 Certified Organisation)

Lab Attached with CMC Vellore Under EQAS Scheme

PATIENT'S NAME : Mr.VINAY PRAKASH MAURYA AGE/SEX: 39 Y/M
REF. BY : Dr. ASHUTOSH MISHRA (M.D.) Friday, March 31, 2023

X-RAY CHEST (PA VIEW)

BOTH LUNG FIELDS AND PLEURAE:

Both lungs show normal bronchovascular pattern.

Right & left hila are normal

No focal mass or calcification is seen

There is no evidence of any fluid in the both the pleural cavities.

Both domes of diaphragms are normal in position.

MEDIASTINUM:


Trachea is central in position.

Cardiac silhouette is of normal size and configuration.

No evidence of pericardial effusion.

No significant lymphadenopathy is seen.

Visualized skeleton is normal.


DR. R. K. TIWARI
M.B.B.S, M.D.(KGMU, LKO)
(RADIODIAGNOSIS).

Thanks for reference.

Address : Kabir Nagar (Near Sanjay Shiksha Niketan), Durgakund, Varanasi

Mobile : 9554572190 / 9453837595 / Recpn. 9389994334

E-mail : dramishra@gmail.com, drpallaviojha@gmail.com, Website: www.piire.org