





बैंक ऑफ बर्सोदा
Bank of Baroda

नाम
Name
रामचंद्र एन. जाविर
Ramchandra N. Javir

कार्यकारी कूट क्र.
E.C. No.
158994

कार्यकारी प्राधिकारी
Issuing Authority

शेखर के इस्तेमाल
Signature of Holder

Javir

Rumita

DR. RUMITA SINGH
MBBS

Reg. No.: 67188

SUBURBAN DIAGNOSTICS (I) PVT. LTD.
Shop No 22, Ground Floor, Raikar Bhavan,
Sector-17, Vashi, Navi Mumbai - 400 703
Tel 27884547 / 27864548.

PHYSICAL EXAMINATION REPORT

Patient Name	Mr. Ramchandra Javir	Sex/Age	male / 58
Date	25/03/2022	CID	2208420538

History and Complaints

No complaints

EXAMINATION FINDINGS:

Height (cms):	164	Temp (0c):	Afebrile
Weight (kg):	64	Skin:	NAD
Blood Pressure	140/80 mmHg	Nails:	NAD
Pulse	72/min	Lymph Node:	NAD.
BMI			

Systems :

Cardiovascular:	S1 S2 (N)
Respiratory:	(N) Breath sounds
Genitourinary:	NAD
GI System:	NAD
CNS:	NAD

Impression:

Normal

Advice:

Brief Disclaimer: (1) Suburban Diagnostics ensures that the tests are conducted with utmost care and safety and are performed on sample received if unacceptable for the reasons stated.

CHIEF COMPLAINTS:

1)	Hypertension:	
2)	IHD	
3)	Arrhythmia	
4)	Diabetes Mellitus	
5)	Tuberculosis	
6)	Asthama	
7)	Pulmonary Disease	
8)	Thyroid/ Endocrine disorders	
9)	Nervous disorders	
10)	GI system	
11)	Genital urinary disorder	
12)	Rheumatic joint diseases or symptoms	
13)	Blood disease or disorder	
14)	Cancer/lump growth/cyst	
15)	Congenital disease	
16)	Surgeries	
17)	Musculoskeletal System	

NAD.

H/O cholecystectomy done May 2016.

PERSONAL HISTORY:

1)	Alcohol	once / twice a week.
2)	Smoking	NO
3)	Diet	vegn/non-veg
4)	Medication	no

Rumita
DR. RUMITA SINGH

MBBS

Reg. No.: 67188

SUBURBAN DIAGNOSTICS (I) PVT. LTD.
 Shop No 22, Ground Floor, Raikar Bhavan,
 Sector-17, Vashi, Navi Mumbai - 400 703
 Tel 27884547 / 27864548.

ADDRESS: 2nd Floor, Aston, Sundervan Complex, Above Mercedes Showroom, Andheri West - 400053

HEALTHLINE - MUMBAI: 022-6170-0000 | OTHER CITIES: 1800-266-4343

For Feedback - customerservice@suburbandiagnosics.com | www.suburbandiagnosics.com

Brief Disclaimer: (1)Suburban Diagnostic...

Date:- 25/03/2022

CID: 2208420538

Name:- Mr. Ramchandra Jaisr Sex / Age: m / 58

EYE CHECK UP

Chief complaints: —

Systemic Diseases: —

Past history:

H/O (BF) cat cataract done' 2018

Unaided Vision:

(RF) 6/6 N₂₄ (LE) 6/12 N₂₄

Aided Vision:

(RF) 6/6 N₆ (LE) 6/6 N₆.

Refraction:

(Right Eye)

(Left Eye)

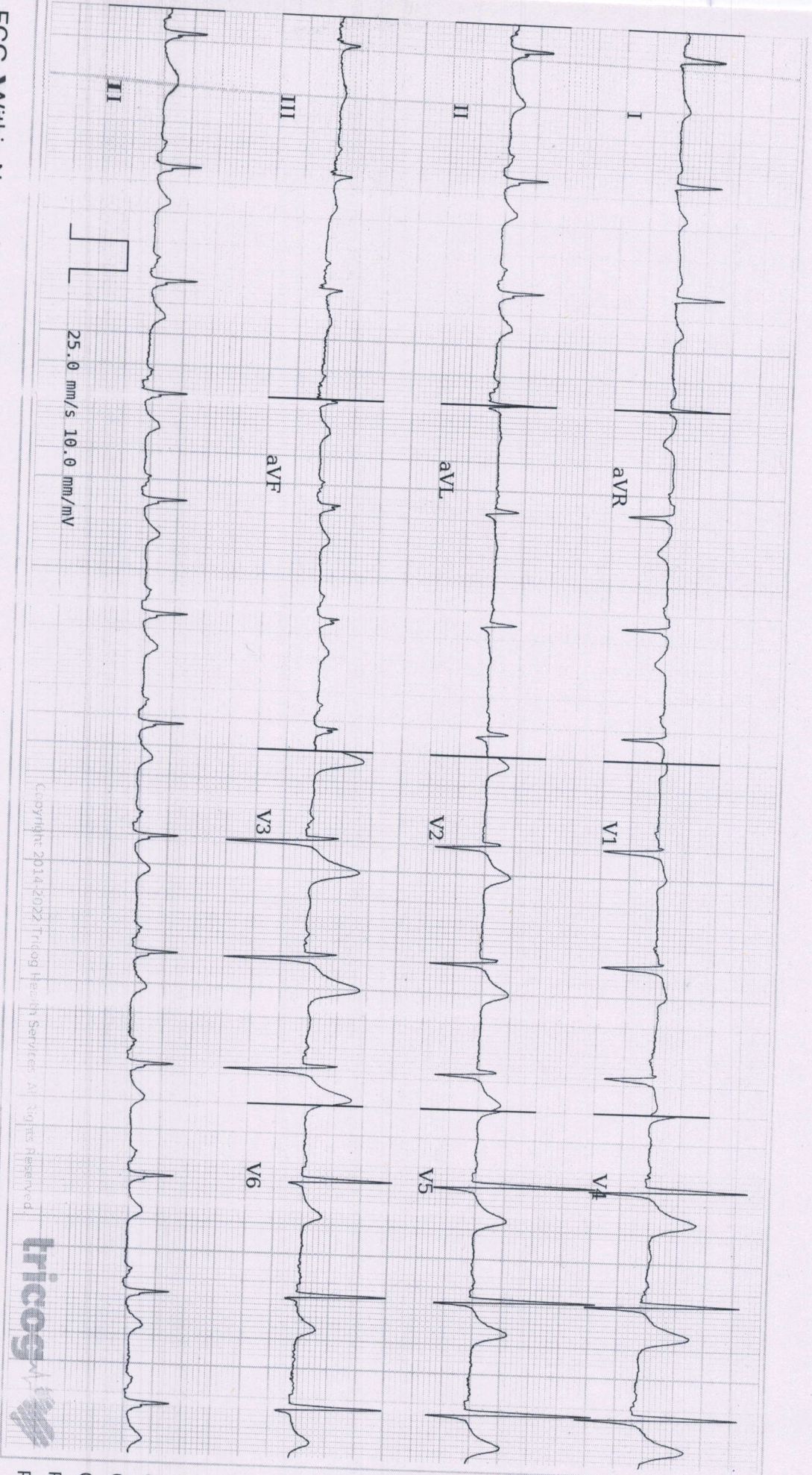
	Sph	Cyl	Axis	Vn	Sph	Cyl	Axis	Vn
Distance								
Near								

Colour Vision: Normal / Abnormal

Remark:

Rumita
DR. RUMITA SINGH
MBBS
Reg. No.: 67188

SUBURBAN DIAGNOSTICS (I) PVT. LTD.
Shop No 22, Ground Floor, Raikar Bhavan,
Sector-17, Vashi, Navi Mumbai - 400 703
Tel 27884547 / 27864548.



ECG Within Normal Limits: Sinus Rhythm, Normal Axis. Please correlate clinically.

Copyright 2014-2022 Tricog Health Services. All Rights Reserved



Age 58 3
years months

Gender Male

Heart Rate 79bpm

Patient Vitals

BP: 140/80 mm

Weight: 64 kg

Height: 164 cm

Pulse: NA

Spo2: NA

Resp: NA

Others:

Measurements

QSRD: 80ms

QT: 350ms

QTc: 401ms

PR: 166ms

P-R-T: 52° 41° 52°

REPORTED BY

Arum...

Dr. Anand N Motwani
M.D. (General Medicine)
Reg No 39329 M.M.C

Disclaimer: 1) Analysis in this report is based on ECG alone and should be used as an adjunct to clinical history, symptoms, and results of other invasive and non-invasive tests and must be interpreted by a qualified physician. 2) Patient vitals are as referred by the clinician and not derived from the ECG.

NAME :- Mr.RAMACHANDRA N JAVIR	AGE :- 58 YRS
SEX :- MALE	DATE :- 25/03/2022
CID NO :- 2208420538	

2D Echo and Colour doppler report

All cardiac chambers are normal in dimension
 No obvious resting regional wall motion abnormalities (RWMA)
 Interatrial and Interventricular septum – Appears Normal
 Valves – Structurally normal
 Trivial MR.
 Good biventricular function.
 IVC is normal.
 Pericardium is normal.
 Great vessels - Origin and visualized proximal part are normal.
 No coarctation of aorta.

Doppler study

Normal flow across all the valves.
 No pulmonary hypertension.
 Grade I diastolic dysfunction.

Measurements

Aorta annulus	17 mm
Left Atrium	30 mm
LVID(Systole)	18 mm
LVID(Diastole)	41 mm
IVS(Diastole)	10 mm
PW(Diastole)	9 mm
LV ejection fraction.	55-60%

Conclusion

- Good biventricular function
- No RWMA
- Valves – Structurally normal
- Trivial MR.
- Grade I diastolic dysfunction
- No PAH

Dasgupta Dr. Anirban Dasgupta
MBBS DNB

Reg. No. 2005/02/0920

Suburban Diagnostics (Vashi)

Performed by: Dr. Anirban Dasgupta

D.N.B. Internal Medicine, Diploma Cardiology (PGDCC-IGNOU).