



भारतीय विशिष्ट पहचान प्राधिकरण
UNIQUE IDENTIFICATION AUTHORITY OF INDIA

पता:

S/O मदनानंद झा, ११०, सब्जी
मंदी, पाँवर हाउस, नया टोला,
मजफ्फरपुर, मुजफ्फरपुर,
मुजफ्फरपुर, बिहार, 842001

Address:

S/O Madnanand Jha, 110,
Sabji Mandi, Power House,
Naya Tola, Mazaffarpur,
Muzaffarpur, Muzaffarpur,
Bihar, 842001



1947
1800 180 1947



help@uidai.gov.in

WWW

www.uidai.gov.in



P.O. Box No.1947,
Bengaluru-560 001



GPS Map Camera



Varanasi, Uttar Pradesh, India

44-B3, Durgakund, Bhelupur, Varanasi, Uttar
Pradesh 221001, India


Lat 25.289262°

Long 82.993308°


17/02/23 08:50 AM GMT +05:30



भारत सरकार
GOVERNMENT OF INDIA



शंकर कुमार झा
Shankar Kumar Jha
जन्म वर्ष / Year of Birth : 1992
पुरुष / Male



6014 3049 4608

आधार — आम आदमी का अधिकार



GPS Map Camera



Varanasi, Uttar Pradesh, India

44-B3, Durgakund, Bhelupur, Varanasi, Uttar Pradesh 221001, India

Lat 25.289262°

Long 82.993308°

17/02/23 08:49 AM GMT +05:30

Google

Facilities:

All clinical Biomedical & Hematology Investigations including Bone Marrow Examination
VPT, Podiascan & Complete Foot Care (First Time in Purvanchal)
All Hormonal Investigation by Chemiluminescent Method
Visceral Fat by (AB-140) Ambulatory BP Monitoring
CGMS & Insulin Pump Available
PFT, 2D-ECHO (Color Doppler), Holter, TMT, Cardiac-3 available
VIA, VILI, Colposcopy available
Special Endocrinological Investigation Protocols.

ISO 9001:2008 Certified
Mobile: 9389994334, 9554572190, 9453837595



Panacea Pathology

Clinical Reference Lab

Persistence, Preparedness and Precision
EQAS (CMC Vellore Attached) & IQAS System
पूर्वांचल की सर्वोत्तम गुणवत्ता वाली पैथोलॉजी

PATIENT NAME : SHANKAR KUMAR JHA	AGE/GENDER : 30YRS/MALE
REFD BY DR. : ARCO FEMI HEALTHCARE LTD.	RECEIVED DATE : 17-02-2023(09:00AM)
SAMPLE : BLOOD & URINE	REPORT DATE : 17-02-2023(07:00PM)

PATHOLOGY REPORT

COMPLETE BLOOD COUNT (CBC)

TEST	LAB TEST VALUES	NORMAL RANGE
HEMOGRAM		
HEMOGLOBIN (FLOW CYTOMETRY)	13.8	13 – 16 gm/dl
TOTAL LEUCOCYTE COUNT (TLC)	4,600	4000 – 11000
RBC COUNT	5.43	3.5 – 5.5
PCV (HCT)	44.1	37 – 47
MCV	81.3	80 – 95
MCH	25.4	28 – 34
MCHC	32.3	30 – 36
PLATELET COUNT	1,96,000	1,50,000 – 4,00,000
E.S.R. (WINTROBE FIRST HOURS)	10.0	20 mm/1 st hr
DIFFERENTIAL LEUCOCYTE		
NEUTROPHILS	52	40 – 75%
LYMPHOCYTES	42	20 – 45%
EOSINOPHILS	04	1 – 6%
MONOCYTES	02	2 – 8%
BASOPHILS	00	< 2%

RENAL & KIDNEY PROFILE, SERUM

TEST	LAB TEST VALUES	NORMAL RANGE
RENAL FUNCTION TESTS		
BLOOD UREA NITROGEN (BUN)	10.6	10 – 50 mg/dl
SERUM CREATININE	0.91	0.60 – 1.60 mg/dl
URIC ACID	3.91	3.60 – 7.70 mg/dl
ALKALINE PHOSPHATASE (ALP)	72.0	142 – 353 mg/dl
TOTAL PROTIENS	7.4	0 – 39 mg/dl
ALBUMIN	4.0	3.8 – 5.4 mg/dl
SERUM GLOBULIN	3.4	2.1 – 3.5 mg/dl
CALCIUM	8.0	8.80 – 10.20
PHOSPHORUS	3.14	2.50 – 5.00
SERUM SODIUM NA+	1.015	135.00 – 155.00 mEq/Ltr
SERUM POTASIUM K+	4.12	3.60 – 5.50 mEq/Ltr
ICALCIUM	1.22	1.10 – 1.35 mmol/L
SERUM CHLORIDE CL+	101.3	98.00 – 110.00 mEq/Ltr

PANACEA HOSPITAL
 UNIT OF AAROHA HEALTH CARE PVT. LTD.)
 REG. NO. AL-1500
 B.36/44 B/4, KABIR NAGAR
 DURGAKUND, VARANASI
 M.D., Pathology

PAGE 1

Lab Technician

Timing : 8.00 a.m. to 9.00 p.m. (Sunday 8.00 a.m. to 3.00 p.m.)

This Report is not valid for medico legal purpose

Note: These tests have technical limitations. Clinico-pathological interpretation is necessary. In case of any disparity test may be repeated immediately.

Address : 36/44 FK Kabir Nagar, Durgakund, Varanasi – 221005

Email: dramishra@gmail.com, drpallaviojha@gmail.com Website: panaceahospital.org

Facilities:

All clinical Biomedical & Hematology Investigations including Bone Marrow Examination VPT, Podiascan & Complete Foot Care (First Time in Purvanchal) All Hormonal Investigation by Chemiluminescent Method Visceral Fat by (AB-140) Ambulatory BP Monitoring CGMS & Insulin Pump Available PFT, 2D-ECHO (Color Doppler), Holter, TMT, Cardiac-3 available VIA, VILI, Colposcopy available Special Endocrinological Investigation Protocols.

ISO 9001:2008 Certified
Mobile: 9389994334, 9554572190, 9453837595



Panacea Pathology

Clinical Reference Lab

Persistence, Preparedness and Precision
EQAS (CMC Vellore Attached) & IQAS System
पूर्वांचल की सर्वोत्तम गुणवत्ता वाली पैथोलॉजी

PATIENT NAME : SHANKAR KUMAR JHA

AGE/GENDER : 30YRS/MALE

REFD BY DR. : ARCO FEMI HEALTHCARE LTD.

RECEIVED DATE : 17-02-2023(09:00AM)

SAMPLE : BLOOD & URINE

REPORT DATE : 17-02-2023(07:00PM)

PATHOLOGY REPORT

LIPID PROFILE, SERUM

TEST	LAB TEST VALUES	NORMAL RANGE
BLOOD CHEMISTRY		
TOTAL CHOLESTEROL (SERUM)	168.0	Desirable:- < 200 mg/dl Borderline:- 200 – 239 mg/dl High:- > 240 mg/dl
TRIGLYCERIDES (SERUM)	145.0	35 – 170 mg/dl
HDL CHOLESTEROL (SERUM)	41.0	35.30 – 79.50 mg/dl
LDL CHOLESTEROL (SERUM)	98.0	< 130 mg/dl
VLDL	29.0	< 40 mg/dl
CHOLESTROL/HDL RATIO	4.0	< 3.0 Low Risk Ratio 3.0 – 5.0 Avg Risk < 5.0 High Risk
LDL/HDL RATIO	2.3	< 3 Ratio

BLOOD GROUP

TEST	LAB TEST VALUES
BLOOD GROUP ABO & RH FACTOR	
BLOOD GROUP	"O"
RH FACTOR	POSITIVE

GLYCOSYLATED HEMOGLOBIN (HBA1C)

TEST	LAB TEST VALUES	NORMAL RANGE
HBA1C	5.8	Normal : <5.97 % Good Control : 5.97 – 6.81% Fair Control : 6.81 – 7.65% Poor Control : >7.65%

THYROID PROFILE (T3, T4, TSH)

TEST	LAB TEST VALUES	NORMAL RANGE
THYROID FUNCTION TEST		
T3	1.0	0.60 – 1.81 ng/ml
T4	8.12	4.50 – 10.90 ug/dl
TSH	2.28	0.39 – 6.10 uIU/mL

PAGE 2

Lab Technician

PANACEA HOSPITAL
(A UNIT OF ARCHA HEALTHCARE PVT. LTD.)
REG. NO. AL-1500
B.36/44, B-4, KABIR NAGAR
DURGAKUND, VARANASI
M.D., Pathology

Timing : 8.00 a.m. to 9.00 p.m. (Sunday 8.00 a.m. to 3.00 p.m.)

This Report is not valid for medico legal purpose

Note: These tests have technical limitations. Clinico-pathological interpretation is necessary. In case of any disparity test may be repeated immediately.

Address : 36/44 FK Kabir Nagar, Durgakund, Varanasi – 221005

Email: dramishra@gmail.com, drpallaviojha@gmail.com Website: panaceahospital.org

Facilities:

All clinical Biomedical & Hematology Investigations including Bone Marrow Examination VPT, Podiascan & Complete Foot Care (First Time in Purvanchal) All Hormonal Investigation by Chemiluminescent Method Visceral Fat by (AB-140) Ambulatory BP Monitoring CGMS & Insulin Pump Available PFT, 2D-ECHO (Color Doppler), Holter, TMT, Cardiac-3 available VIA, VILI, Colposcopy available Special Endocrinological Investigation Protocols.

ISO 9001:2008 Certified
Mobile: 9389994334, 9554572190, 9453837595



Panacea Pathology

Clinical Reference Lab

Persistence, Preparedness and Precision
EQAS (CMC Vellore Attached) & IQAS System
पूर्वांचल की सर्वोत्तम गुणवत्ता वाली पैथोलॉजी

PATIENT NAME : SHANKAR KUMAR JHA

AGE/GENDER : 30YRS/MALE

REFD BY DR. : ARCO FEMI HEALTHCARE LTD.

RECEIVED DATE : 17-02-2023(09:00AM)

SAMPLE : BLOOD & URINE

REPORT DATE : 17-02-2023(07:00PM)

PATHOLOGY REPORT

LIVER PROFILE TEST, SERUM

TEST	LAB TEST VALUES	NORMAL RANGE
BIO CHEMISTRY		
TOTAL BILIRUBIN	0.68	0.0 – 1.1 mg/dl
DIRECT BILIRUBIN	0.22	0.0 – 0.2 mg/dl
INDIRECT BILIRUBIN	0.46	< 0.90 mg/dl
SGOT (AST)	23.0	0 – 52 mg/dl
SGPT (ALT)	27.0	0 – 39 mg/dl
GGT (GYT)	20.5	< 55 U/L

URINE ROUTINE EXAMINATION

TEST	LAB TEST VALUES	NORMAL RANGE
PHYSICAL EXAMINATION		
QUANTITY	30	ML
COLOUR	STRAW	PALE YELLOW
APPEARANCE	CLEAR	CLEAR
SPECIFIC GRAVITY	1.015	1.01 – 1.03
PH	6.5	4.7 – 7.5
CHEMICAL EXAMINATION		
GLUCOSE	Not Detected	Not Detected
PROTEIN	NIL	Not Detected
MICROSCOPIC EXAMINATION		
PUS CELLS	1-2	0-5
RBC	Not Detected	Not Detected
EPITHELIAL CELLS	2-3	0-5
CASTS	Not Detected	Not Detected
CRYSTALS	Not Detected	Not Detected
BACTERIA	Not Detected	Not Detected

RANDOM/FASTING BLOOD SUGER

TEST	LAB TEST VALUES	NORMAL RANGE
RBS/FBS		
RANDOM BLOOD SUGAR	101.0	125-140 mg/dl
FASTING BLOOD SUGER	62.0	70-125 mg/dl

----- End of Report -----

Lab Technician

PANACEA HOSPITAL
(A UNIT OF AARCHA HEALTH CARE PVT. L.)
REG. NO.: 1500
B.36/44 FK KABIR NAGAR
M.D. Pathology
DURGAKUND, VARANASI

Timing : 8.00 a.m. to 9.00 p.m. (Sunday 8.00 a.m. to 3.00 p.m.)

This Report is not valid for medico legal purpose

Note: These tests have technical limitations. Clinico-pathological interpretation is necessary. In case of any disparity test may be repeated immediately.

Address : 36/44 FK Kabir Nagar, Durgakund, Varanasi – 221005

Email: dramishra@gmail.com, drpallaviojha@gmail.com **Website:** panaceahospital.org

BPL

AUTO 10mm/mV

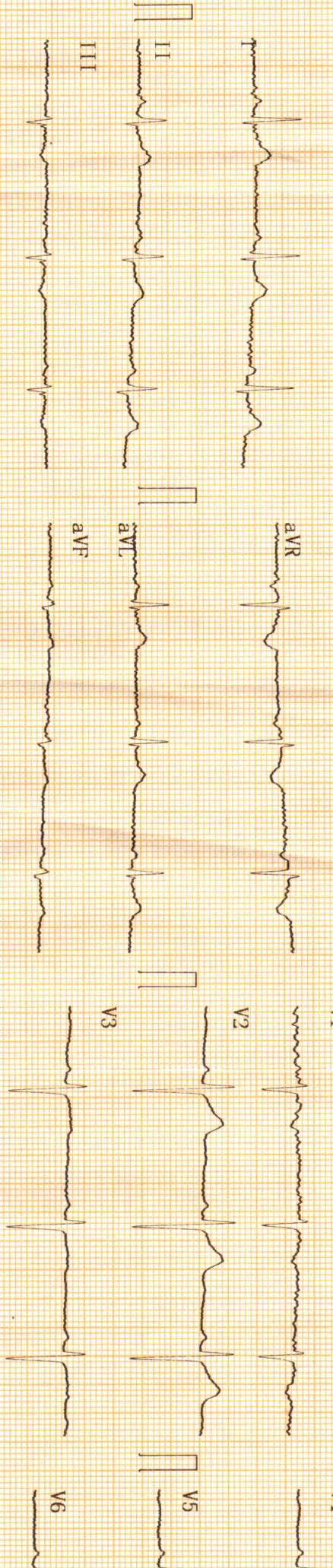10mm/mV

10mm/mV

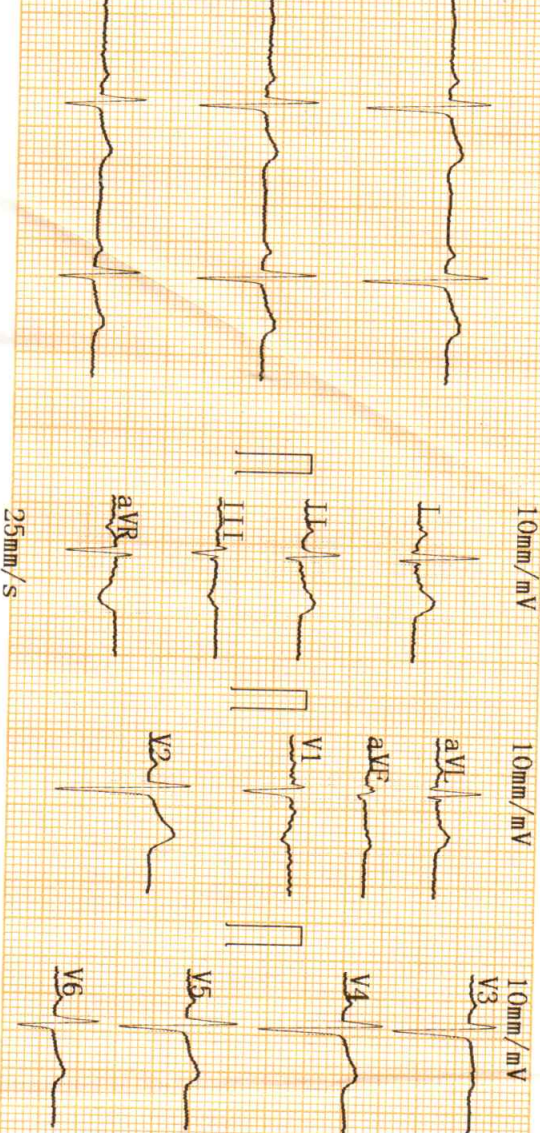
10mm/mV

25mm/s AC50Hz+EMC35Hz

CARDIART



BPL



2023-02-17 09:28

<< Conclusions >>

ID :
 Name :
 Sex :
 Height :
 SYS :
 DIA :

Age :
 Weight : kg**Report need physician confirm**

HR [bpm] : 64
 PR Interval [ms] : 157
 P Duration [ms] : 120
 QRS Duration [ms] : 77
 T Duration [ms] : 238
 QT/QTc [ms] : 365/377
 P/QRS/T Axis [deg] : 39.4 / -0.2 / 8.2
 R(V5)/S(V1) [mV] : 0.68 / 0.66
 R(V5)+S(V1) [mV] : 1.34

Physician

Kallan
PALLAVI MISHRA
 MBBS, M.D (GENERAL MEDICINE)
 MCI Reg. No. 52033



PANACEA HOSPITAL

A shelter for many hearts A Home for many lives

(An ISO 9001:2008 Certified Organisation)

Lab Attached with CMC Vellore Under EQAS Scheme

Name	MR.SHANKAR KUMAR JHA	Sex /Age	31/M	Date	17/02/2023
Ref. by	Dr.Pallavi Mishra(MD)	BSA - m ²		Echo window	fair

Echo - Cardiography

MITRAL VALVE Doppler	AML - normal morphology MV Flow - E - 0.9 A-0.4 E/A=1.94	PML - normal morphology MVA - 3.0 cm ² Mitral Regurgitation - No
TRICUSPID VALVE Doppler	Normal TV Flow -No	Tricuspid Regurgitation - No
PULMONARY VALVE Doppler	Normal PV Flow -No	Pulmonary Regurgitation - No
AORTIC VALVE Doppler	Trileaflet-No AV Flow - no	Aortic Regurgitation - no
MEASUREMENT	Aorta - 30.3 (20-38) mm IVS ed - 13.1 (6-12) mm LVID ed - 33.7 (35-55) mm LVPW ed - 14.3 (6-12) mm OA - 7 (> 5) mm	LA - 30.3 (24-32) mm IVS es -17.1 (6-12) mm LVID es - 22.3 (24-40) mm LVPW es - 17.1 (6-12) mm EPSS - 4 (< 9) mm

CONCLUSION

All cardiac chamber dimensions are WNL
 No valvular abnormalities
 Good LV systolic function present Modified Simpson's method (4C, 2C) (LVEF-64%)
 No diastolic dysfunction present (E/A = 1.94) by tissue Doppler (E/e'=6.2)
 No RWMA
 No pericardial effusion
 Intact IAS / IV
 No PAH
 No intra cardiac mass /thrombus /vegetation

IMPRESSION **Normal Echocardiogram**


 Niraj Mishra
 Physician Assistant
 (PIRE)

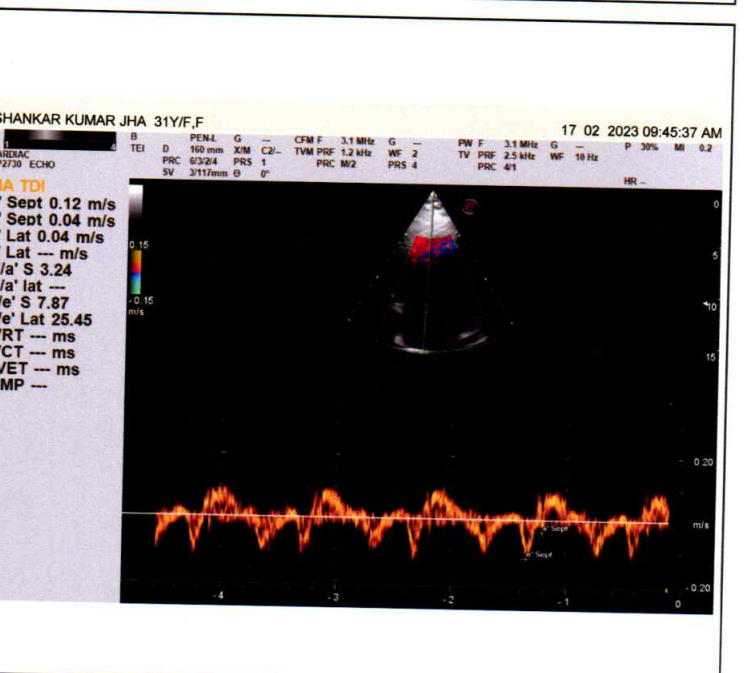
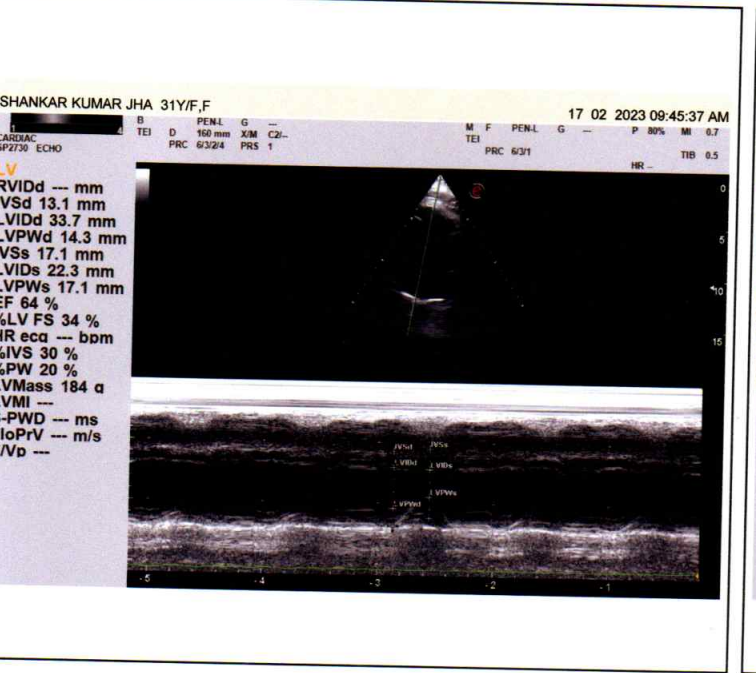
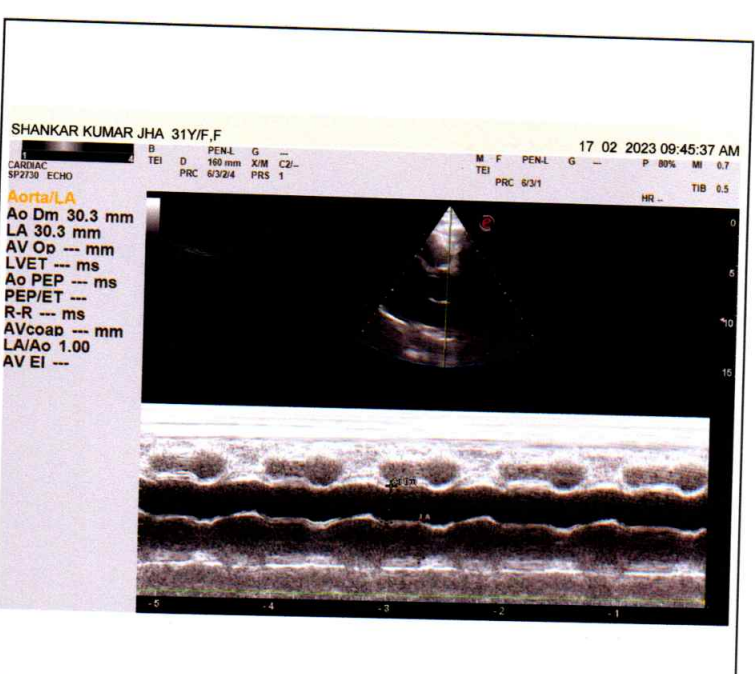
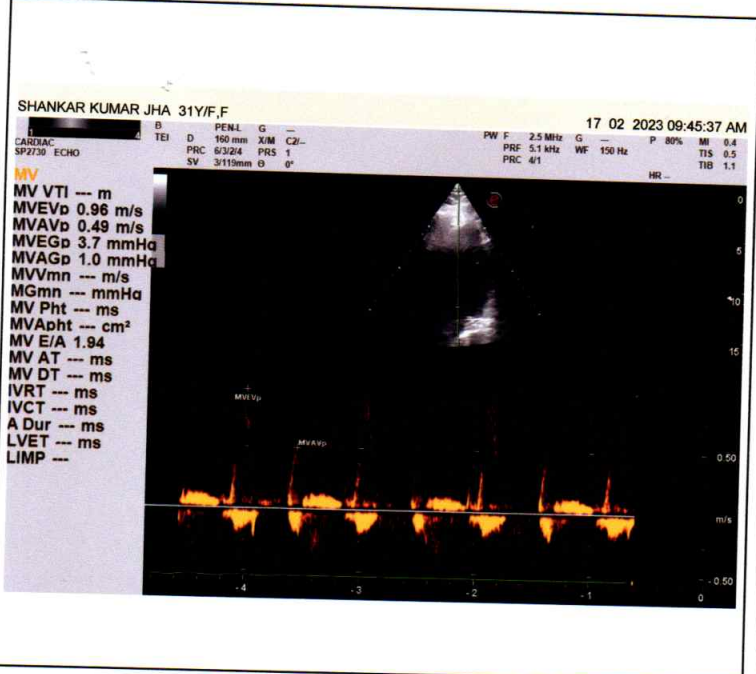
DR. PALLAVI MISHRA
 MBBS, MD (GENERAL MEDICINE)
 MCI Reg.No. 52033

Dr. Pallavi Mishra
 MBBS, MD (MED) Lucknow
 Echocardiography Specialist, MIAE
 Non-invasive cardiologist
 Women Cardiologist
 Diabetocardiologist

Address : Kabir Nagar (Near Sanjay Shiksha Niketan), Durgakund, Varanasi

Mobile : 9554572190 / 9453837595 / Recpn. 9389994334

E-mail : dramishra@gmail.com, drpallaviojha@gmail.com, Website: www.piire.org



54	TYPHOID
55	CA-125
56	BLOOD CULTURE
57	LACTIC ACID DEHYDROGENASE (LDH)
58	TORCH IGG IEM
59	ANTI PHOSPHOLIPID ANTIBODIES IGG IGM IGA (APLA)
60	SEMEN ANALYSIS
61	



GPS Map Camera



Varanasi, Uttar Pradesh, India
44-B3, Durgakund, Bhelupur, Varanasi, Uttar Pradesh 221001, India
Lat 25.289262°
Long 82.99331°
17/02/23 09:39 AM GMT +05:30

Panacea Hospital

Diabetes Care Organisation



ओ. पी. डी. पंजीकरण
O.P.D. REGISTRATION

IPD BILLING

GPS Map Camera



Varanasi, Uttar Pradesh, India
44-B3, Durgakund, Bhelupur, Varanasi, Uttar Pradesh 221001, India
Lat 25.289262°
Long 82.993308°
17/02/23 08:51 AM GMT +05:30

Google



Call Now - 1800-123-3070

PANACEA HOSPITAL

A shelter for many hearts A Home for many lives

(An ISO 9001:2008 Certified Organisation)

Lab Attached with CMC Vellore Under EQAS Scheme

NAME: MR.SHANKAR KUMAR JHA

AGE/SEX: 31 YRS / MALE

REF BY: DR. ASHUTOSH MISHRA (MD)

DATE: 17/02/2023

ULTRA SOUND WHOLE ABDOMEN REPORT

- Liver:** Normal in shape and size and shows smooth and regular margin.
- Gall bladder:** Normal distended with normal wall thickness and echo-free lumen.
- CBD** Visualized part normal in course & caliber.
- Pancreas:** Normal in size, shape & echogenicity. Margins are smooth & regular. No diffuse/ focal lesion seen.
- Spleen:** Normal in size shape & echogenicity. Margins are smooth & regular. No diffuse / focal lesion seen. Splenic vessels at hilum is normal.
- Kidney:** Right kidney: 9.8 X 5.3cm Left kidney: 10.1 X 5.0 cm Normal cortical echogenicity with well maintained Cortical-medullary differentiation., Pelvicalyceal system normal. No calculus/mass lesion seen. No hydronephrosis/ hydroureter seen.
- Urinary bladder:** Normally distended, wall thickness is normal. No echogenic foci lumen or diverticula seen. Both VUJ appears normal. No E.R. calculus / mass lesion seen
- Prostate:** Normal in size, shape, & echogenicity. No calcification or focal cystic lesion seen. Capsular margins are smooth and regular. Seminal vesicles appear normal in size, shape & echogenicity. No diffuse /focal lesion seen.
- Others:** No free fluid in peritoneal cavity. No free fluid in bilateral pleural cavity.

Impression:

- **NO SIGNIFICANT SONOLOGICAL ABNORMALITY DETECTED.**

Please correlate clinically and further investigations.

DR. PALLAVI MISHRA
MBBS, MD (GENERAL MEDICINE)
MCI Reg.No. 52033

DR. PALLAVI MISHRA
MBBS MD(MED) Lucknow
Echocardiography specialist, MIAE
Non invasive cardiologist
Women cardiologist

Radiologist

Dr. Tusharika Rai
MBBS MS

NIRAJ MISHRA
(Physician Assistant)
(PIIRE)

Address : Kabir Nagar (Near Sanjay Shiksha Niketan), Durgakund, Varanasi

Mobile : 9554572190 / 9453837595 / Recpn. 9389994334

E-mail : dramishra@gmail.com, drpallaviojha@gmail.com, Website: www.piire.org

SHANKAR KUMAR JHA 31Y/F,F

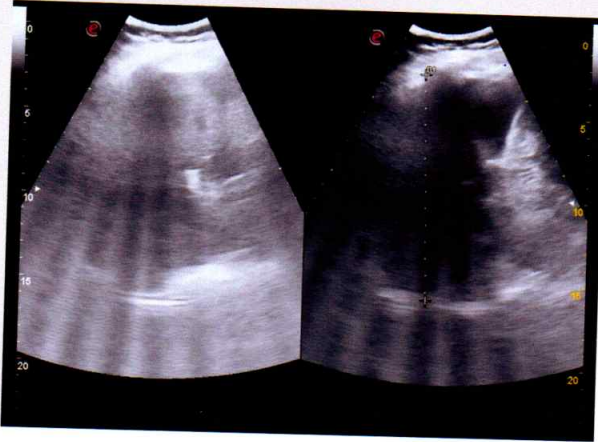
17 02 2023 09:42:55 AM

ABDOMINAL
AC2541 ABD

B PEN-H G
TEI D 211 mm X/M C2/-
PRC 19/2/3/5 PRS 4

P 60% MI 0.8

D1
134.9 mm



SHANKAR KUMAR JHA 31Y/F,F

17 02 2023 09:42:55 AM

ABDOMINAL
AC2541 ABD

B PEN-H G
TEI D 211 mm X/M C2/-
PRC 19/2/3/5 PRS 4

P 60% MI 0.8

D-Ratio

D1 98.7 mm

D2 53.2 mm

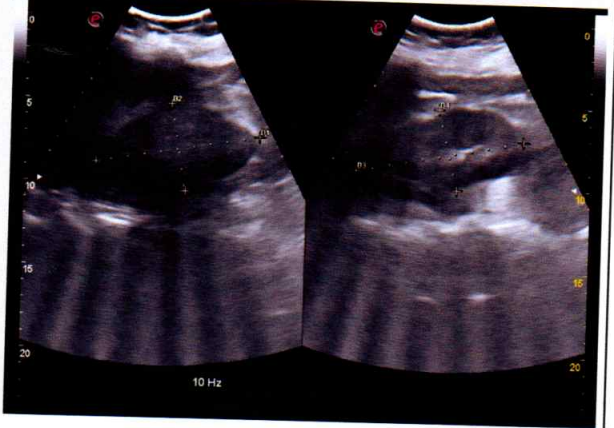D/D 186 %

D-Ratio

D3 101.2 mm

D4 50.0 mm

D/D 202 %



10 Hz

SHANKAR KUMAR JHA 31Y/F,F

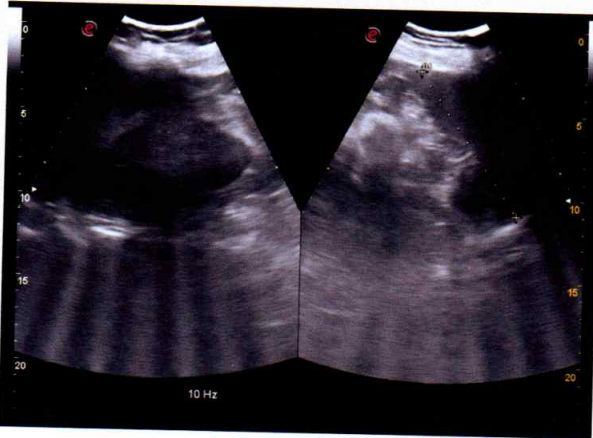
17 02 2023 09:42:55 AM

ABDOMINAL
AC2541 ABD

B PEN-H G
TEI D 211 mm X/M C2/-
PRC 19/2/3/5 PRS 4

P 60% MI 0.8

D1
103.3 mm



10 Hz

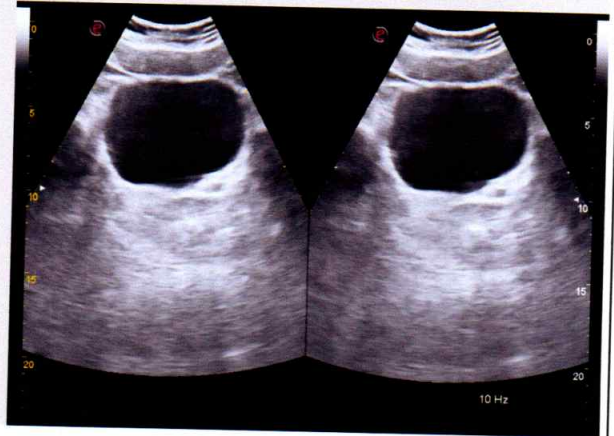
SHANKAR KUMAR JHA 31Y/F,F

17 02 2023 09:42:55 AM

ABDOMINAL
AC2541 ABD

B PEN-H G
TEI D 211 mm X/M C2/-
PRC 19/2/3/5 PRS 4

P 60% MI 0.8



10 Hz

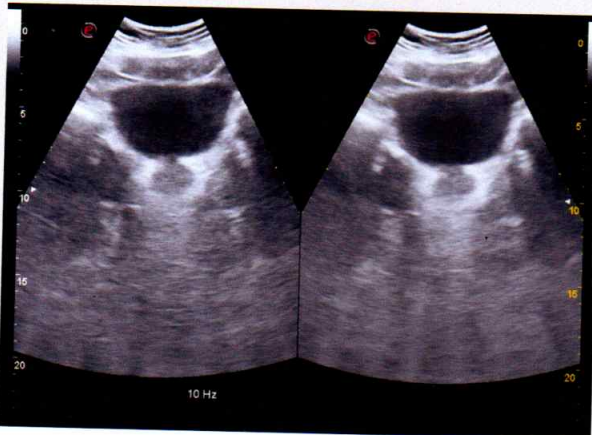
SHANKAR KUMAR JHA 31Y/F,F

17 02 2023 09:42:55 AM

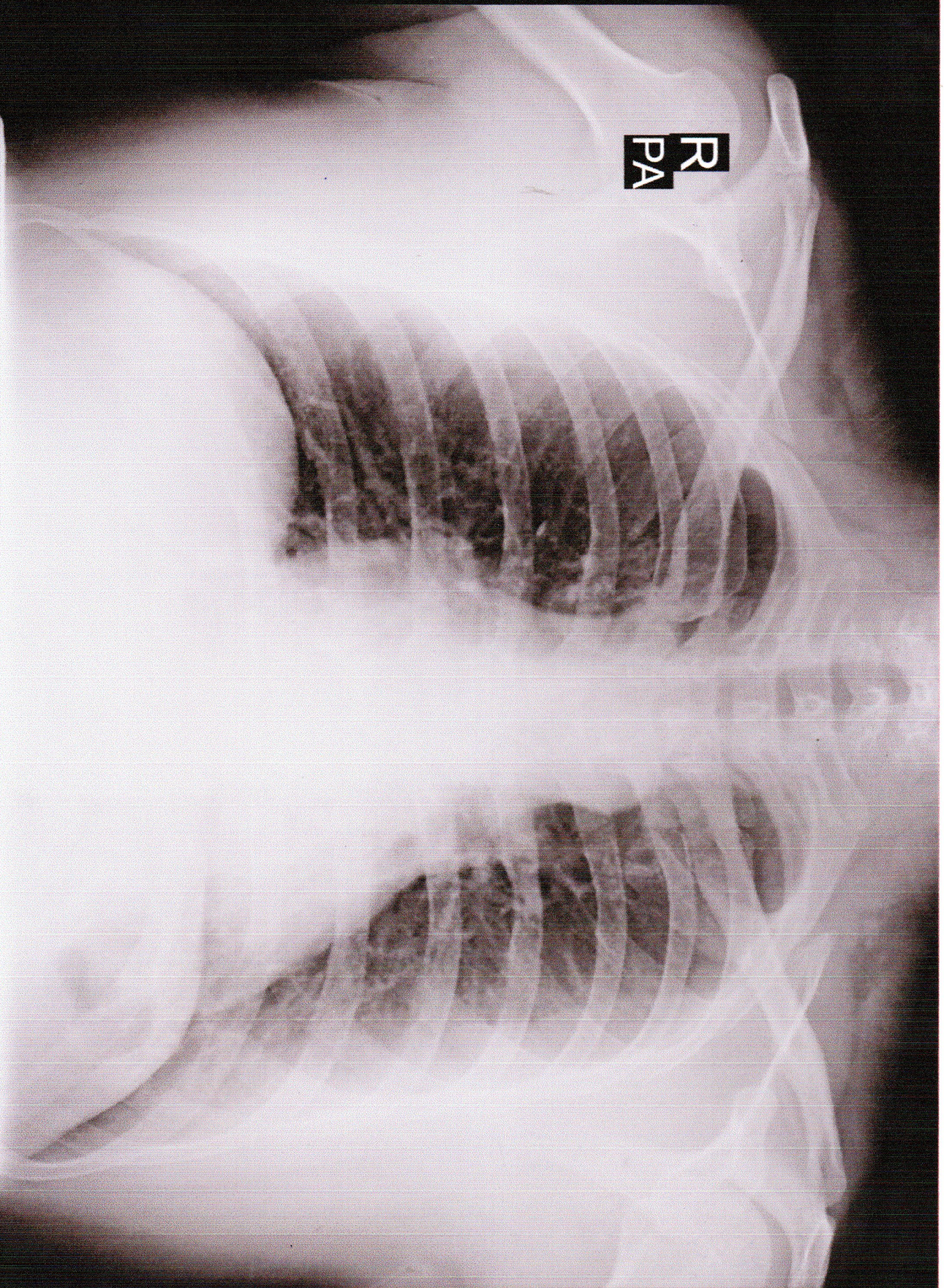
ABDOMINAL
AC2541 ABD

B PEN-H G
TEI D 211 mm X/M C2/-
PRC 19/2/3/5 PRS 4

P 60% MI 0.8



10 Hz



JHA SHANKAR KUMAR 31Y/M 3652 O CHEST P.A. 17-Feb-23 10:10 AM

PANACEA HOSPITAL, KABIR NAGAR, DURGAKUND, VARANASI



Call Now - 1800-123-3070

PANACEA HOSPITAL

A shelter for many hearts A Home for many lives

(An ISO 9001:2008 Certified Organisation)

Lab Attached with CMC Vellore Under EQAS Scheme

NAME: MR.SHANKAR KUMAR JHA
REF BY: DR. ASHUTOSH MISHRA (MD)

AGE/SEX: 31 YRS / MALE
DATE: 17/02/2023

X-RAY CHEST PA

BOTH LUNG FIELDS AND PLEURAE:

Both lungs show normal bronchovascular pattern.

Right & left hila are normal

No focal mass or calcification is seen

There is no evidence of any fluid in the both the pleural cavities.

Both domes of diaphragms are normal in position.

MEDIASTINUM:

Trachea is central in position.

Cardiac silhouette is of normal size and configuration.

No evidence of pericardial effusion.

No significant lymphadenopathy is seen.

Visualized skeleton is normal.

NO SIGNIFICANT RADIOGRAPHIC ABNORMALITY.

REPORTED BY
DR. Rahul Kumar Tiwari
MBBS, MD (Radio Diagnosis)
Reg.No. 57557

Address : Kabir Nagar (Near Sanjay Shiksha Niketan), Durgakund, Varanasi

Mobile : 9554572190 / 9453837595 / Recpn. 9389994334

E-mail : dramishra@gmail.com, drpallaviojha@gmail.com, Website: www.piire.org