

MEDICAL SUMMARY **Apollo Clinic** VASHI

NAME:	Mrs. Shiva Yadav	UHID:	
AGE:	27	DATE OF HEALTHCHECK:	26-1-2023
GENDER:	F		

HEIGHT:	159	MARITAL STATUS:	M
WEIGHT:	54	NO OF CHILDREN:	1
BMI:	21.4		

C/O: Fever (evening rise), weakness, epistaxis, vertigo.

K/C/O: PRESENT MEDICATION: Tab - Lorazepam, Tab - Ceftriaxone, Tab - Pantoprazole, Tab - Montelukast

P/M/H: → typhoid, lymphoma P/S/H: → No

ALLERGY: → No

PHYSICAL ACTIVITY: Active / Moderate / Sedentary ✓

H/A: SMOKING:)
ALCOHOL:)
TOBACCO/PAN:)

FAMILY HISTORY FATHER:)
MOTHER:)

O/E:
BP: 110/70 PULSE: → 72/min
TEMPERATURE: → 37.2 SCARS:

LYMPHADENOPATHY:)
PALLOR/ICTERUS/CYNOSIS/CLUBBING:)
OEDEMA:

S/E:
RS: 

P/A: 

CVS: S.I.R

Extremities & Spine: → Lower limb pain

CNS: Coma oriented

ENT:
Skin: → MAD

Vision:

	Without Glass		With Glass	
	Right Eye	Left Eye	Right Eye	Left Eye
FAR :				
NEAR :				
COLOUR VISION:				

• ANDHERI • COLABA • NASHIK • VASHI

OPHTHALMIC EVALUATION

UHID No.: _____

Date: 24/1/23

Name: Mr. Guina Yadav.

Age: 27

Gender: Male/Female Male

Without Correction :

Distance: Right Eye 6/6

Left Eye 6/6

Near : Right Eye N 6

Left Eye N 6

With Correction :

Distance: Right Eye _____

Left Eye _____

Near : Right Eye _____

Left Eye _____

	RIGHT					LEFT				
	SPH	CYL	AXIS	PRISM	VA	SPH	CYL	AXIS	PRISM	VA
Distance										
Near										

Colour Vision: (Normal)

Anterior Segment Examination: _____

Pupils: _____

Fundus: Normal

Intraocular Pressure: _____

Diagnosis: _____

Advice: _____

Re-Check on _____ (This Prescription needs verification every year)

DR. SHETH NIKET PRASHANT
M.B.B.S D.O.M.S
Regn.No 2008/10/3646

Dr. _____
(Consultant Ophthalmologist)

Name : _____ Age : _____ Sex : _____ UHID No. : _____ Date : _____

Mrs. Shiva Yendav / 26 yrs.

24 / 04 / 2023

married since 4 yrs

no gynae complaints

no bowel, bladder complaints

family history: no H/O malignancy in the family

Past history: no systemic illness

no H/O prev su

no H/O drug allergy.

gc: G fair

Afebrile

pallor

widened

no pedal edema

P - SA/min

P/A - soft, non-tender.

P/S - univ. xasnia healthy.

cervical ectropion

P/V - Papsmeas not taken i/v/omenas Dr. _____



→ cervical healthy, no pain, family's file

Apollo Clinic
VASHI

- Consultation
- Diagnostic
- Health Check-Ups
- Dentistry

Obs history: Para 1 A2 / FTNDI 4/4 / male A+W.

menstrual history

LMP: 20/01/2023

LMP: 29/12/2022

menstrual regular, mod flow, no dysmenorr.

Adv:

- Papsmeas at next visit

- USG Pelvis

- FU & reports

Dr. Aditi
21/3/2024

DENTAL CHECKUP

NAME: Mrs. Shina	MR NO:
AGE :	GENDER :
DATE: 24/1/23	

Medical history: Diabetes Hypertension

EXAMINATION	UPPER RIGHT	UPPER LEFT	LOWER LEFT	LOWER RIGHT
Calculus & Stains				
Mobility				
Caries (Cavities)				
a) Class 1 (Occlusal)				
b) Class 2 (Proximal)				
c) Class 5 (Cervical)				
Faulty Restoration				
Faulty Crown				
Fractured Tooth				
Root Pieces				
Impacted Tooth				
Missing Tooth				8
Existing Denture				

TREATMENT ADVISED:

TREATMENT	UPPER RIGHT	UPPER LEFT	LOWER LEFT	LOWER RIGHT
Restoration / Filling				
Root Canal Therapy				
Crown				
Extraction				8 if needed.

Oral Prophylaxis: Scaling & polishing
 Orthodontic Advice for Braces: Yes / No
 Prosthetic Advice to Replace Missing Teeth: Denture Bridge Implant
 Oral Habits: Tobacco Cigarette Others since ___ years
 Advice to quit any form of tobacco as it can cause cancer.
 Other Findings: NA

APOLLO CLINIC
 First Floor, Sec-12,
 Plot No. 195/B, Vashi,
 Navi Mumbai - 03.

SNEHA
 Dr. SNEHA

• ANDHERI • COLABA • NASHIK • VASHI

Name : Mrs. Shiva Yadav Gender : Female Age : 27 Years
UHID : FVAH 4598 Bill No : Lab No: V-3510-19
Ref. by : SELF Sample Col.Dt : 24/01/2023 09:20
Barcode No : 8676 Reported On : 24/01/2023 16:16

TEST RESULTS UNITS BIOLOGICAL REFERENCE INTERVAL

LFT(Liver Function Tests)-Serum

S.Total Protein (Biuret method)	7.29	g/dL	6.6 - 8.7
S.Albumin (BCG method)	4.50	g/dL	3.5 - 5.2
S.Globulin (Calculated)	2.79	g/dL	2 - 3.5
S.A/G Ratio:(Calculated)	1.61		0.9 - 2
S.Total Bilirubin (DPD):	0.32	mg/dL	0.1 - 1.2
S.Direct Bilirubin (DPD):	0.11	mg/dL	0.1 - 0.3
S.Indirect Bilirubin (Calculated)	0.21	mg/dL	0.1 - 1.0
S.AST (SGOT)(IFCC Kinetic with P5P): 18		U/L	5 - 36
S.ALT (SGPT) (IFCC Kinetic with P5P): 16		U/L	5 - 33
S.Alk Phosphatase(pNPP-AMP Kinetic): 134		U/L	35 - 105
S.GGT(IFCC Kinetic): 32		U/L	07 - 32

Sushant Gaikwad
Entered By

Ms Kaveri Gaonkar
Verified By



Dr.Milind Patwardhan
M.D(Pathologist)
Chief Pathologist

End of Report
Results are to be correlated clinically



Indira Health And Lifestyle Private Limited.
NABL Accredited Laboratory
The Emerald, 1st Floor, Plot No. 195, Sector-12,
Besides Neel Siddhi Tower, Vashi-Navi Mumbai-400703.
Tel.: (022) - 2788 1322 / 23 / 24 ☎ 8291490000
Email: apolloclinicvashi@gmail.com

Apollo Clinic
VASHI

Name : Mrs. Shiva Yadav
UHID : FVAH 4598
Ref. by : SELF
Barcode No : 8676


Gender : Female Age : 27 Years
Bill No : Lab No: V-3510-19
Sample Col.Dt : 24/01/2023 09:20
Reported On : 24/01/2023 16:16

TEST	RESULTS	BIOLOGICAL REFERENCE INTERVAL
	BIOCHEMISTRY	
S.Urea(Urease Method)	21.2 mg/dl	10.0 - 45.0
BUN (Calculated)	9.89 mg/dL	5 - 20
S.Creatinine(Jaffe's Method)	0.63 mg/dl	0.50 - 1.1
BUN / Creatinine Ratio	15.7	9:1 - 23:1
S.Uric Acid(Uricase Method)	4.3 mg/dl	2.4 - 5.7

Sushant Gaikwad
Entered By

Ms Kaveri Gaonkar
Verified By

End of Report
Results are to be correlated clinically


Dr. Milind Patwardhan
M.D(Pathologist)
Chief Pathologist

NORMAL ECG

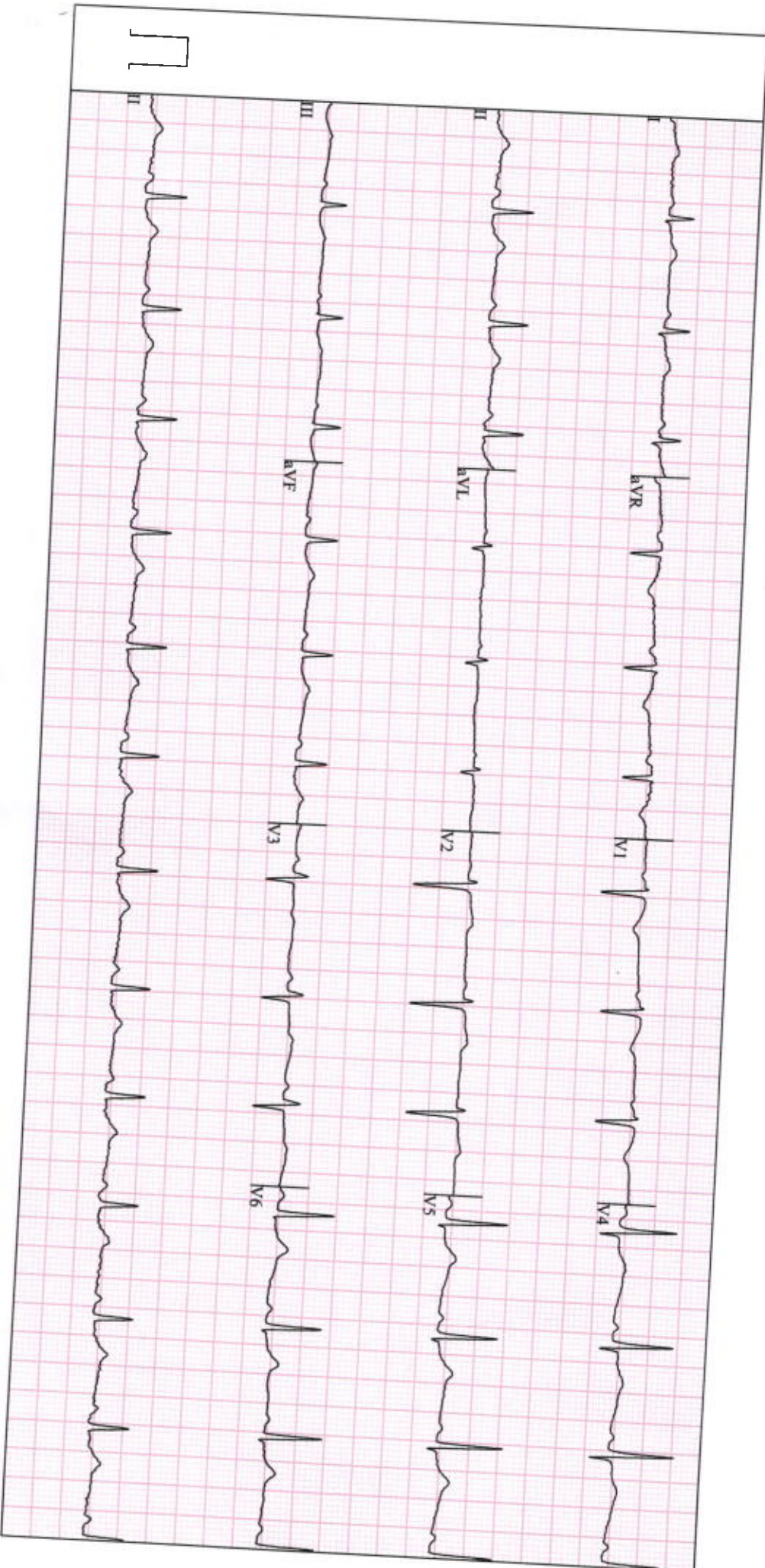
77 bpm
--/-- mmHg

QRS : 72 ms
QT/QTcBaz : 366/414 ms
PR : 114 ms
P : 74 ms
RR/PP : 774/779 ms
P/QRS/T : 39/65/56 degrees

Normal sinus rhythm
Normal ECG

WRC


DR. ANIRBAN DASGUPTA
M.B., B.S., D.N.B. Medicine
Diploma Cardiology
MMC-2005/02/10920



Apollo Clinic
The Emerald, Plot No-195/B, Sector-12,
Neel Siddhi Towers, Vashi-400703

Station
Telephone:

EXERCISE STRESS TEST REPORT

Patient Name: SHIVA, YADAV
Patient ID: 04598
Height:
Weight:

DOB: 02.02.1995
Age: 27yrs
Gender: Female
Race: Asian

Study Date: 24.01.2023
Test Type: Treadmill Stress Test
Protocol: BRUCE

Referring Physician: --
Attending Physician: DR. ANIRBAN DASGUPTA
Technician: Anita Gaikwad

Medications:
NIL

Medical History:
NIL

Reason for Exercise Test:
Screening for CAD

Exercise Test Summary

Phase Name	Stage Name	Time in Stage	Speed (mph)	Grade (%)	HR (bpm)	BP (mmHg)	Comment
PRETEST	SUPINE	00:08	0.00	0.00	83	110/70	
	STANDING	00:18	0.00	0.00	80		
	HYPERV.	00:15	0.00	0.00	83		
	WARM-UP	00:19	0.90	0.00	91		
EXERCISE	STAGE 1	03:00	1.70	10.00	134	120/80	
	STAGE 2	02:07	2.50	12.00	176	140/80	
RECOVERY		01:04	0.00	0.00	130	160/80	

The patient exercised according to the BRUCE for 5:06 min:s, achieving a work level of Max. METS: 7.00. The resting heart rate of 83 bpm rose to a maximal heart rate of 179 bpm. This value represents 92 % of the maximal, age-predicted heart rate. The resting blood pressure of 110/70 mmHg, rose to a maximum blood pressure of 160/80 mmHg. The exercise test was stopped due to Target heart rate achieved.

Interpretation

Summary: Resting ECG: normal.
Functional Capacity: normal.
HR Response to Exercise: appropriate.
BP Response to Exercise: normal resting BP - appropriate response.
Chest Pain: none.
Arrhythmias: none.
ST Changes: none.
Overall impression: Normal stress test.

Conclusions

TMT IS NEGATIVE FOR INDUCIBLE MYOCARDIAL ISCHAEMIA AT THE WORKLOAD ACHIEVED.

Physician-DR. ANIRBAN DASGUPTA

Dasgupta

Dr. ANIRBAN DASGUPTA
M.B.B.S., D.N.B. Medicine
Diploma Cardiology
MMC - 2005/02/0920

PATIENT'S NAME	SHIVA YADAV	AGE :- 27 y/M
UHID NO	4598	24 Jan 2023

X-RAY CHEST PA VEIW

OBSERVATION:

Bilateral lung fields are clear.
Both hila are normal.
Bilateral cardiophrenic and costophrenic angles are normal.
The trachea is central.
Aorta appears normal.
The mediastinal and cardiac silhouette are normal.
Soft tissues of the chest wall are normal.
Bony thorax is normal.

IMPRESSION:

➤ No significant abnormality seen.



DR. DISHA MINOCHA
DMRE (RADIOLOGIST)

PATIENT'S NAME	SHIVA YADAV	AGE :- 27Y/F
UHID	45498	24 Jan 2023

USG WHOLE ABDOMEN (TAS)

LIVER is normal in size, shape and echotexture. No evidence of any focal lesion. The portal vein appears normal & shows normal hepato-petal flow. No evidence of intra-hepatic biliary duct dilatation.

Gall Bladder appears well distended with normal wall thickness. There is no calculus or pericholecystic collection. CBD appears normal.

Visualised parts of head & body of PANCREAS appear normal.

SPLEEN is normal in size, and echotexture. No focal lesion seen. Splenic vein is normal.

Both kidneys are normal in size, shape and echotexture with normal parenchymal reflectivity and maintained cortico-medullary differentiation. No hydronephrosis or calculi or mass seen. RIGHT KIDNEY measures 9.6 x 3.6 cm. LEFT KIDNEY measures 8.8 x 4.1 cm.

URINARY BLADDER is well distended; no e/o wall thickening or mass or calculi seen.

UTERUS is anteverted and is normal in size, shape and echotexture; No focal lesion seen. It measures 6.8 x 5.0 x 4.0 cm; ET measures 7.4 mm.

Both ovaries are normal in size, shape and position.

RIGHT OVARY Vol: 2.6 x 1.7 cm, LEFT OVARY Vol: 2.8 x 1.9 cm.

Visualised BOWEL LOOPS appear normal. There is no free fluid seen.

IMPRESSION -

- No significant abnormality detected.

THIS REPORT IS NOT TO BE USED FOR MEDICOLEGAL PURPOSE. THE CONTENTS OF THIS REPORT REQUIRE CLINICAL CO-RELATION BEFORE ANY APPLICATION.



DR. CHHAYA S. SANGANI
CONSULTANT SONOLOGIST
Reg: No. 073826

• ANDHERI • COLABA • NASHIK • VASHI

Name: Mrs Shiva Yadav

Age: 27y

Date of Health check-up: 24/1/23

Findings and Recommendation:

Findings:-

— Abnormal phosphate - 134

Recommendation:-

- Balanced diet
- Low fat, fibre diet
- Fresh fruits, & Diet rich in omega 3 fatty acids.

— DR MAHESH NAIK
PHYSICIAN

Signature:

Consultant

Dr Mahesh Naik