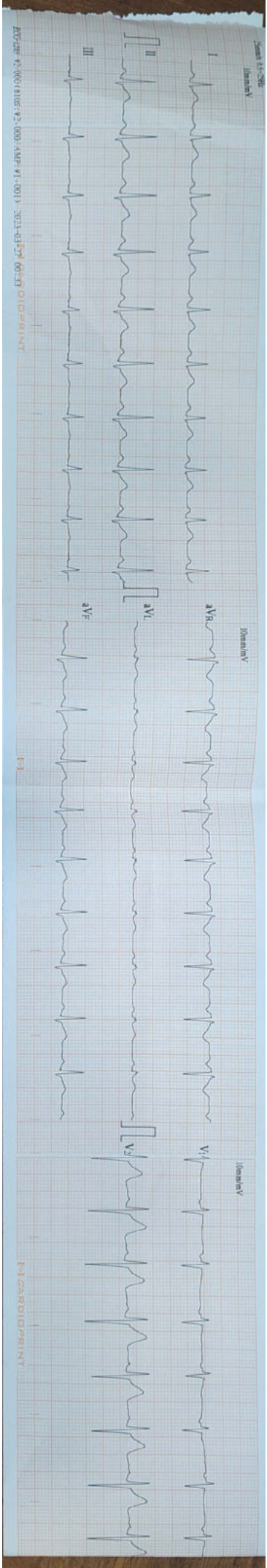


ID : 0141 HR : 97  
 Name: RASHEH RASHEH  
 Sex : M Age : 42  
 P/RRS/T : 34.4/74.2  
 RBS/SVL : 1.290/0.600 mV  
 RBS/SVL : 1.890 mV

Sinus brachycardia  
 Inspected/Printed ST-T Abnormality

Unconfirmed report verified by: \_\_\_\_\_





## ECHO REPORT

Name of the patient: MR. PANDEY RISHABH Age: 30 Sex:  Male  Female

UHID No: 23995 IPD No: \_\_\_\_\_ Date: 27/02/2022

Refer By Doctor: Dr. R. Arora

LVEF% 60

**2D ECHO**

> Mitral Value Normal Pulmonary Value N Pulm

> Artery N

> Aortic avive N Tricuspid valve N

**2D RWMA**

> NO RWMA (Regional wall motion abnormality) at rest

**COLD DOPPLER**

> NO Significant Vavular stenosis / Regurgiation

**COMMENTS AND SUMMARY**

> All cardiac chambers of N size and shape NO dilatation or hypertrophy.

> NO RWMA (Regional wall motion abnormality) at rest

> NO Cloth / Vegetation/ pericardial effusion

> LV 60% Systolic function

> NO Significant Vavular stenosis / Regurgiation

**Final Impression**

> EF at Rest 60%

**COMMENTS**

with  
2D ECHO & Color Doppler study with

Dr. Rakesh Kumar Arora  
MBBS, MD, DM (Cardiology)  
Reg. No. DMC - 16395  
Consultant - Cardiology  
Park Hospital, Faridkot



**Consultant Cardiology**

Doctor Name : Dr.  
Date :

Signature :  
Time :



12 Lead + Comparison

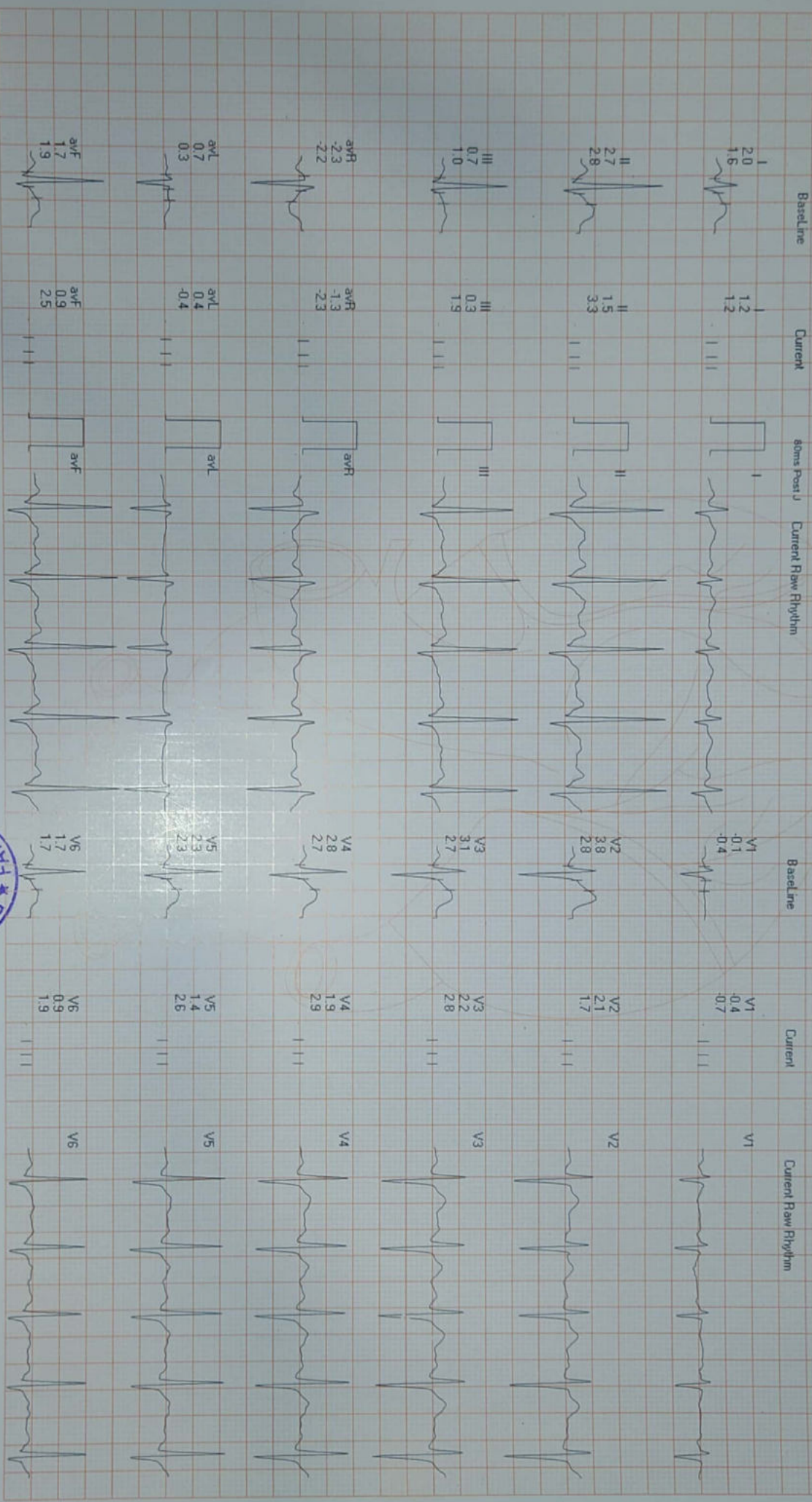

HR: 116 bpm  
METS: 1.0  
BP: 120/80

MPHR: 61% of 190  
Speed: 0.0 mpph  
Grade: 0.0%

Raw ECG  
BRUCE  
(0.05-100)/HZ

Ex Time 05:08  
BLC: On  
Notch: On

Recovery :  
10.0 mm/mV  
25 mm/Sec.





**DEPARTMENT OF RADIOLOGY**

Patient Name	Mr RISHABH PANDEY	Billed Date	: 27/03/2023	10.12 AM
Reg No	23995	Reported Date	: 27/03/2023	
Age/Sex	30 Years 8 Months 23Days / Male	Req. No.	: 23005815	
Type	OPD	Consultant Doctor	: Dr. CONSULTANT	

**X-RAY CHEST AP/PA**

Old united fracute of 5<sup>th</sup> rib seen.

Bilateral lungs appears normal.

No focal lung lesion seen.

Both hila are normal in size, have equal density and bear normal relationship.

The heart and trachea are central in position and no mediastinal abnormality is visible.

The cardiac size is normal for patient age and view.

The domes of the diaphragms are normal in position, and show smooth outline.

To be correlated clinically



DR BINOD KR CHAUDHARY  
MBBS, MD  
CONSULTANT RADIOLOGIST

(This is only professional opinion and not the diagnosis, Please correlate clinically)

J-Block, Sector-10, Near Court, Faridabad - 121004, Haryana  
Tel.: 0129-4200000 E-mail : parkfaridabad@gmail.com

**PARK GROUP OF HOSPITALS : West Delhi • South Delhi • Gurgaon • Karnal • Panipat • Hodal • Ambala • Behror**

the **health** care providers

the **health** care providers

Page No:1







**DEPARTMENT OF RADIOLOGY**

Patient Name	Mr RISHABH PANDEY	Billed Date	: 27/03/2023	10.12 AM
Reg No	23995	Reported Date	: 27/03/2023	
Age/Sex	30 Years 8 Months 23Days / Male	Req. No.	: 23005815	
Type	OPD	Consultant Doctor	: Dr. CONSULTANT	

**USG WHOLE ABDOMEN**

**LIVER** : The liver is normal in size, shape and echotexture.No evidence of any focal lesion. IHBR is NOT dilated. Portal vein is normal.

**GALL BLADDER** :The gall bladder is well distended.No evidence any calculus or mass seen.

GB wall thickness with in normal limits. No evidence of pericholecystic fluid is seen.

**BILE DUCT** :The common bile duct is normal in caliber.

**SPLEEN** :The spleen is normal in size and shape. Its echotexture is homogeneous.No evidence of focal lesion is noted. Splenic vein is normal.

**PANCREAS** :The pancreas is normal in size, shape, contours and echotexture.

**BILATERAL KIDNEYS** : The bilateral kidneys are normal in size and echotexture. Cortico-medullary differentiation is maintained. There is no evidence of obvious calculus or hydronephrosis seen.

**URINARY BLADDER** :The urinary bladder is well distended.Wall thickness within normal limits.No evidence of calculus is seen.No evidence of mass or diverticulum is noted.

**PROSTATE**: Prostate appears normal in size, shape and echotexture.

No free fluid is seen in peritoneal cavity.

No evidence of obvious retroperitoneal or mesentric lymphadenopathy is seen.

**IMPRESSION**: - **USG WHOLE ABDOMEN REVEALS NO OBVIOUS ABNORMALITY.**

**TO BE CORRELATED CLINICALLY.**

DR BINOD KR CHAUDHARY  
MBBS, MD  
CONSULTANT RADIOLOGIST



(This is only professional opinion and not the diagnosis, Please correlate clinically)

J-Block, Sector-10, Near Court, Faridabad - 121004, Haryana

Tel.: 0129-4200000 E-mail : parkfaridabad@gmail.com

**PARK GROUP OF HOSPITALS** : West Delhi • South Delhi • Gurgaon • Karnal • Panipat • Hodal • Ambala • Behror





**DEPARTMENT OF HAEMATOLOGY**

Patient Name : Mr. RISHABH PANDEY

MR No : 23995

Age/Sex : 30 Years 8 Months 23 Days / Male

Type : OPD

TPA/Corporate : MEDIWHEEL

Bill Date : 27/03/2023

Reporting Date : 28/03/2023

Sample ID : 4375

Bill/Req. No. : 23005815

Ref Doctor : Dr. CONSULTANT

Test	Result	Bio. Ref. Interval	Units
<b>GLYCOSYLATED HAEMOGLOBIN</b>			
GLYCOSYLATED HAEMOGLOBIN	5.6	0 - 6.5	%

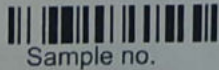Note : \*Done on DCA Vantage

\*Results of these tests should always be interpreted in conjunction with patients medical history, clinical presentation and other findings.

\*The results of HbA1c are not influenced by recent meals , physical activity or emotional stress.

\*\*\*\*\* END OF THE REPORT \*\*\*\*\*

OUT SOURCE  
PARK HOSPITAL  
GGN



Sample no.



Dr. VAISHALI YADAV  
PATHOLOGIST

Dr. PARDIP KUMAR  
MICROBIOLOGIST & ICO

S.C.GAUR  
LAB INCHARGE

USER NM SUNIL

(This is only professional opinion and not the diagnosis, Please correlate clinically)

J-Block, Sector-10, Near Court, Faridabad - 121004, Haryana

Tel.: 0129-4200000 E-mail : parkfaridabad@gmail.com

PARK GROUP OF HOSPITALS : West Delhi • South Delhi • Gurgaon • Karnal • Panipat • Hodal • Ambala • Behror







2



**DEPARTMENT OF IMMUNOLOGY**

**Patient Name** : Mr. RISHABH PANDEY  
**MR No** : 23995 **Bill Date** : 27/03/2023  
**Age/Sex** : 30 Years 8 Months 23 Days / Male **Reporting Date** : 30/03/2023  
**Type** : OPD **Sample ID** : 4375  
**TPA/Corporate** : MEDIWHEEL **Bill/Req. No.** : 23005815  
**Ref Doctor** : Dr.CONSULTANT

Test	Result	Bio. Ref. Interval	Units
<b>THYROID PROFILE</b>			
TRI-IODOTHYRONINE (T3)	1.57	0.60 - 1.81	ng/ml
THYROXINE (T4)	9.42	5.01 - 12.45	µg/dL
THYROID STIMULATING HORMONE	2.00	0.5-5.50 ,	µIU/ml

\*\*\*\*\* END OF THE REPORT \*\*\*\*\*



OUT SOURCE  
PARK HOSPITAL  
GGN



Sample no.

Dr. VAISHALI YADAV  
PATHOLOGIST

Dr. PARDIP KUMAR  
MICROBIOLOGIST & ICO

S.C.GAUR  
LAB INCHARGE

USER NM SAMAY

(This is only professional opinion and not the diagnosis, Please correlate clinically)

J-Block, Sector-10, Near Court, Faridabad - 121004, Haryana  
Tel.: 0129-4200000 E-mail : parkfaridabad@gmail.com

**PARK GROUP OF HOSPITALS** : West Delhi • South Delhi • Gurgaon • Karnal • Panipat • Hodal • Ambala • Behror

the **health** care providers

the **health** care providers







**DEPARTMENT OF PATHOLOGY**

Patient Name : Mr. RISHABH PANDEY

MR No : 23995

Age/Sex : 30 Years 8 Months 23 Days / Male

Type : OPD

TPA/Corporate : MEDIWHEEL

Bill Date : 27/03/2023

Reporting Date : 27/03/2023

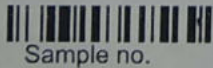Sample ID : 4375

Bill/Req. No. : 23005815

Ref Doctor : Dr. CONSULTANT

Test	Result	Bio. Ref. Interval	Units
<b>CBC</b>			
HAEMOGLOBIN	13.4	12 - 16	gm/dL
PACKED CELL VOLUME	40.8	35.0 - 50.0	%
RED BLOOD CELL COUNT	4.66	3.5 - 5.5	millions/ $\mu$ L
MEAN CORPUSCULAR VOLUME	87.6	83 - 101	fL
MEAN CORPUSCULAR HAEMOGLOBIN	28.8	27 - 31	pg
MEAN CORPUSCULAR HB CONC	<b>32.8</b> L	33 - 37	g/dl
RDW	13.7	11.6 - 14.5	%
TOTAL LEUCOCYTE COUNT	9150	4000-11000	/ $\mu$ L
<b>DIFFERENTIAL COUNT</b>			
NEUTROPHILS	70	40.0 - 80.0	%
LYMPHOCYTES	25	20 - 40	%
MONOCYTES	02	2.0 - 10.0	%
EOSINOPHILS	03	0.0 - 5.0	%
BASOPHILS	00	0.0 - 2.0	%
PLATELET COUNT	<b>1.41</b> L	1.50 - 4.50	lac/cumm

\*\*\*\*\* END OF THE REPORT \*\*\*\*\*



Sample no.

Dr. VAISHALI YADAV  
PATHOLOGIST

Dr. PARDIP KUMAR  
MICROBIOLOGIST & ICO



S.C. GAUR  
LAB INCHARGE

USER NM DEEPCHAND

(This is only professional opinion and not the diagnosis, Please correlate clinically)

J-Block, Sector-10, Near Court, Faridabad - 121004, Haryana

Tel.: 0129-4200000 E-mail : parkfaridabad@gmail.com

PARK GROUP OF HOSPITALS : West Delhi • South Delhi • Gurgaon • Karnal • Panipat • Hodal • Ambala • Behror

the health care providers

the health care providers





**DEPARTMENT OF HAEMATOLOGY**

**Patient Name** : Mr. RISHABH PANDEY  
**MR No** : 23995  
**Age/Sex** : 30 Years 8 Months 23 Days / Male  
**Type** : OPD  
**TPA/Corporate** : MEDIWHEEL

**Bill Date** : 27/03/2023  
**Reporting Date** : 27/03/2023  
**Sample ID** : 4375  
**Bill/Req. No.** : 23005815  
**Ref Doctor** : Dr. CONSULTANT

Test	Result	Bio. Ref. Interval	Units
<b>BLOOD GROUPING AND RH FACTOR</b>			
BLOOD GROUP	" O " RH POSITIVE		

\*\*\*\*\* END OF THE REPORT \*\*\*\*\*



Sample no.

Dr. VAISHALI YADAV  
PATHOLOGIST

Dr. PARDIP KUMAR  
MICROBIOLOGIST & ICO



S.C. GAUR  
LAB INCHARGE

USER NM SUNIL

(This is only professional opinion and not the diagnosis, Please correlate clinically)

J-Block, Sector-10, Near Court, Faridabad - 121004, Haryana  
Tel.: 0129-4200000 E-mail : parkfaridabad@gmail.com

PARK GROUP OF HOSPITALS : West Delhi • South Delhi • Gurgaon • Karnal • Panipat • Hodal • Ambala • Behror

the **health** care providers

the **health** care providers







**DEPARTMENT OF PATHOLOGY**

**Patient Name** : Mr. RISHABH PANDEY  
**MR No** : 23995  
**Age/Sex** : 30 Years 8 Months 23 Days / Male  
**Type** : OPD  
**TPA/Corporate** : MEDIWHEEL

**Bill Date** : 27/03/2023  
**Reporting Date** : 27/03/2023  
**Sample ID** : 4375  
**Bill/Req. No.** : 23005815  
**Ref Doctor** : Dr. CONSULTANT

Test	Result	Bio. Ref. Interval	Units
<b>LFT (LIVER FUNCTION TEST)</b>			
<b>LFT</b>			
TOTAL BILIRUBIN	0.7	0 - 1.2	mg/dL
DIRECT BILIRUBIN	0.3	0 - 0.4	mg/dL
INDIRECT BILIRUBIN	0.4	0.10 - 0.6	mg/dL
SGOT (AST)	27.7	0 - 45	U/L
SGPT (ALT)	35.5	0 - 45	U/L
ALKALINE PHOSPHATASE	139	30 - 170	IU/L
TOTAL PROTEIN	6.6	6.4 - 8.0	g/dL
ALBUMIN	4.0	3.3 - 5.5	g/dL
GLOBULIN	2.6	2.3 - 4.5	g/dL
A/G RATIO	1.54	1.1 - 2.2	

\*\*\*\*\* END OF THE REPORT \*\*\*\*\*




Sample no.

**Dr. VAISHALI YADAV**  
PATHOLOGIST

**Dr. PARDIP KUMAR**  
MICROBIOLOGIST & ICO



**S.C. GAUR**  
LAB INCHARGE

  
USER NM SUNIL

(This is only professional opinion and not the diagnosis, Please correlate clinically)

J-Block, Sector-10, Near Court, Faridabad - 121004, Haryana  
 Tel.: 0129-4200000 E-mail : parkfaridabad@gmail.com

**PARK GROUP OF HOSPITALS** : West Delhi • South Delhi • Gurgaon • Karnal • Panipat • Hodal • Ambala • Behror

the **health** care providers

the **health** care providers





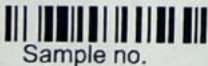**DEPARTMENT OF PATHOLOGY**

**Patient Name** : Mr. RISHABH PANDEY  
**MR No** : 23995  
**Age/Sex** : 30 Years 8 Months 23 Days / Male  
**Type** : OPD  
**TPA/Corporate** : MEDIWHEEL

**Bill Date** : 27/03/2023  
**Reporting Date** : 27/03/2023  
**Sample ID** : 4375  
**Bill/Req. No.** : 23005815  
**Ref Doctor** : Dr.CONSULTANT

Test	Result	Bio. Ref. Interval	Units
<b>KFT (RENAL PROFILE)</b>			
<b>KFT</b>			
SERUM UREA	29.6	10 - 45	mg/dL
SERUM CREATININE	1.01	0.4 - 1.4	mg/dL
SERUM URIC ACID	6.8	2.5 - 7.0	mg/dL
SERUM SODIUM	139	136 - 148	mmol/L
SERUM POTASSIUM	4.0	3.5 - 5.5	mmol/L
CHLORIDE	101	96 - 106	mmol/L

\*\*\*\*\* END OF THE REPORT \*\*\*\*\*



Sample no.

**Dr. VAISHALI YADAV**  
PATHOLOGIST

**Dr. PARDIP KUMAR**  
MICROBIOLOGIST & ICO

**S.C.GAUR**  
LAB INCHARGE

*(Signature)*  
**USER NM SUNIL**

(This is only professional opinion and not the diagnosis, Please correlate clinically)

J-Block, Sector-10, Near Court, Faridabad - 121004, Haryana  
Tel.: 0129-4200000 E-mail : parkfaridabad@gmail.com

**PARK GROUP OF HOSPITALS** : West Delhi • South Delhi • Gurgaon • Karnal • Panipat • Hodal • Ambala • Behror





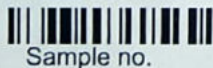**DEPARTMENT OF BIOCHEMISTRY**

**Patient Name** : Mr. RISHABH PANDEY  
**MR No** : 23995  
**Age/Sex** : 30 Years 8 Months 23 Days / Male  
**Type** : OPD  
**TPA/Corporate** : MEDIWHEEL

**Bill Date** : 27/03/2023  
**Reporting Date** : 27/03/2023  
**Sample ID** : 4375  
**Bill/Req. No.** : 23005815  
**Ref Doctor** : Dr.CONSULTANT

Test	Result		Bio. Ref. Interval	Units
<b>LIPID PROFILE</b>				
<b>LIPID PROFILE</b>				
TOTAL CHOLESTEROL	<b>145.08</b>	L	150 - 250	mg/dL
SERUM TRIGLYCERIDES	<b>183.82</b>	H	60 - 165	mg/dl
HDL-CHOLESTEROL	34.64		30 - 70	mg/dl
VLDL CHOLESTEROL	<b>36.76</b>	H	6 - 32	mg/dL
LDL	73.68		50 - 135	mg/dl
LDL CHOLESTEROL/HDL RATIO	2.13		1.0 - 3.0	mg/dL
TOTAL CHOLESTEROL/HDL RATIO	4.19		2.0 - 5.0	mg/dl

\*\*\*\*\* END OF THE REPORT \*\*\*\*\*




Sample no.



**Dr. VAISHALI YADAV**  
PATHOLOGIST

**Dr. PARDIP KUMAR**  
MICROBIOLOGIST & ICO

**S.C.GAUR**  
LAB INCHARGE

  
**USER NM SUNIL**

(This is only professional opinion and not the diagnosis, Please correlate clinically)

J-Block, Sector-10, Near Court, Faridabad - 121004, Haryana  
Tel.: 0129-4200000 E-mail : parkfaridabad@gmail.com

**PARK GROUP OF HOSPITALS : West Delhi • South Delhi • Gurgaon • Karnal • Panipat • Hodal • Ambala • Behror**





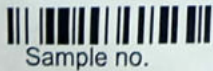**DEPARTMENT OF PATHOLOGY**

Patient Name : Mr. RISHABH PANDEY  
 MR No : 23995  
 Age/Sex : 30 Years 8 Months 23 Days / Male  
 Type : OPD  
 TPA/Corporate : MEDIWHEEL

Bill Date : 27/03/2023  
 Reporting Date : 27/03/2023  
 Sample ID : 4375  
 Bill/Req. No. : 23005815  
 Ref Doctor : Dr. CONSULTANT

Test	Result	Bio. Ref. Interval	Units
<b>BLOOD SUGAR FASTING</b>			
PLASMA GLUCOSE FASTING	89.00	60 - 110	mg/dl

\*\*\*\*\* END OF THE REPORT \*\*\*\*\*



Sample no.

Dr. VAISHALI YADAV  
PATHOLOGIST

Dr. PARDIP KUMAR  
MICROBIOLOGIST & ICO

S.C.GAUR  
LAB INCHARGE

USER NM SUNIL

(This is only professional opinion and not the diagnosis, Please correlate clinically)

J-Block, Sector-10, Near Court, Faridabad - 121004, Haryana  
 Tel.: 0129-4200000 E-mail : parkfaridabad@gmail.com

**PARK GROUP OF HOSPITALS : West Delhi • South Delhi • Gurgaon • Karnal • Panipat • Hodal • Ambala • Behror**







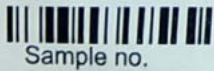**DEPARTMENT OF PATHOLOGY**

Patient Name : Mr. RISHABH PANDEY  
MR No : 23995  
Age/Sex : 30 Years 8 Months 23 Days / Male  
Type : OPD  
TPA/Corporate : MEDIWHEEL

Bill Date : 27/03/2023  
Reporting Date : 27/03/2023  
Sample ID : 4375  
Bill/Req. No. : 23005815  
Ref Doctor : Dr.CONSULTANT

Test	Result	Bio. Ref. Interval	Units
<b>URINE ROUTINE AND MICROSCOPY</b>			
<b>PHYSICAL CHARACTERSTICS</b>			
QUANTITY	40ml	5 - 100	ml
COLOUR	Pale Yellow		
TURBIDITY	Clear	clear	
SPECIFIC GRAVITY	1.015	1.000-1.030	
PH	Acidic	Acidic/Alkaline	
<b>CHEMICAL EXAMINATION-1</b>			
URINE PROTEIN	NIL	NIL	mg/dl
GLUCOSE	NIL	NIL	
<b>MICRO.EXAMINATION</b>			
PUS CELL	1-2 /hpf	0-5	/HPF
RED BLOOD CELLS	Nil	0-2	cells/hpf
EPITHELIAL CELLS	1-2/HPF	0-5	cells/hpf
CASTS	NIL	NIL	/HPF
CRYSTALS	NIL	NIL	/hpf
OTHER	NIL		

\*\*\*\*\* END OF THE REPORT \*\*\*\*\*



Dr. VAISHALI YADAV  
PATHOLOGIST

Dr. PARDIP KUMAR  
MICROBIOLOGIST & ICO

**PARK HOSPITAL**  
HRY.  
S.C.GAUR  
LAB INCHARGE

USER NM SUNIL

(This is only professional opinion and not the diagnosis, Please correlate clinically)

J-Block, Sector-10, Near Court, Faridabad - 121004, Haryana  
Tel.: 0129-4200000 E-mail : parkfaridabad@gmail.com

**PARK GROUP OF HOSPITALS : West Delhi • South Delhi • Gurgaon • Karnal • Panipat • Hodal • Ambala • Behror**