



DEPARTMENT OF RADIOLOGY

Patient Name	Mr ANMOL RATAN	Billed Date	: 11/11/2023	9.59 AM
Reg No	28577	Reported Date	: 11/11/2023	
Age/Sex	56 Years 10 Months 11Days / Male	Req. No.	: 23064947	
Type	OPD	Consultant Doctor	: Dr. CONSULTANT	

X-RAY CHEST ~~AP~~/PA

Bilateral lungs appears normal.

Both hila are normal in size, have equal density and bear normal relationship.

The heart and trachea are central in position and no mediastinal abnormality is visible.

The cardiac size is normal for patient age and view.

The domes of the diaphragms are normal in position, and show smooth outline.

To be correlated clinically

DR BINOD KR CHAUDHARY
MBBS, MD
CONSULTANT RADIOLOGIST

(This is only professional opinion and not the diagnosis, Please correlate clinically)

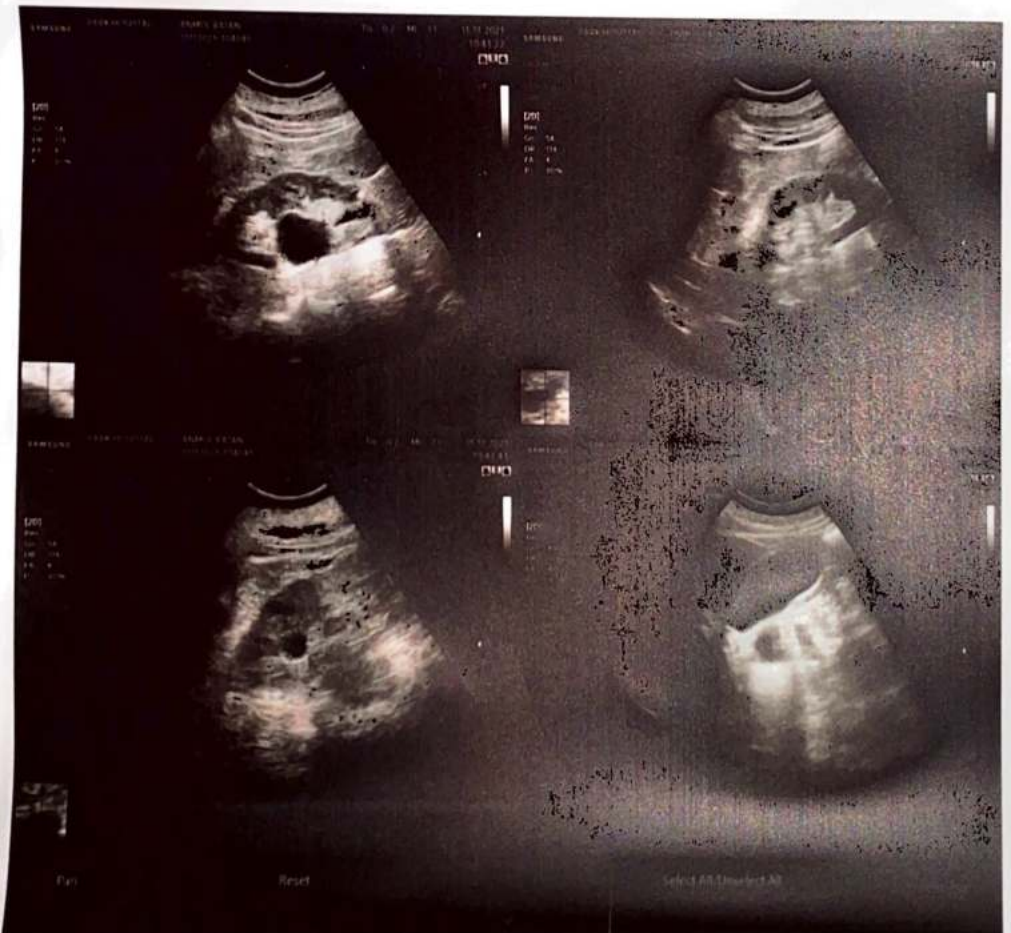
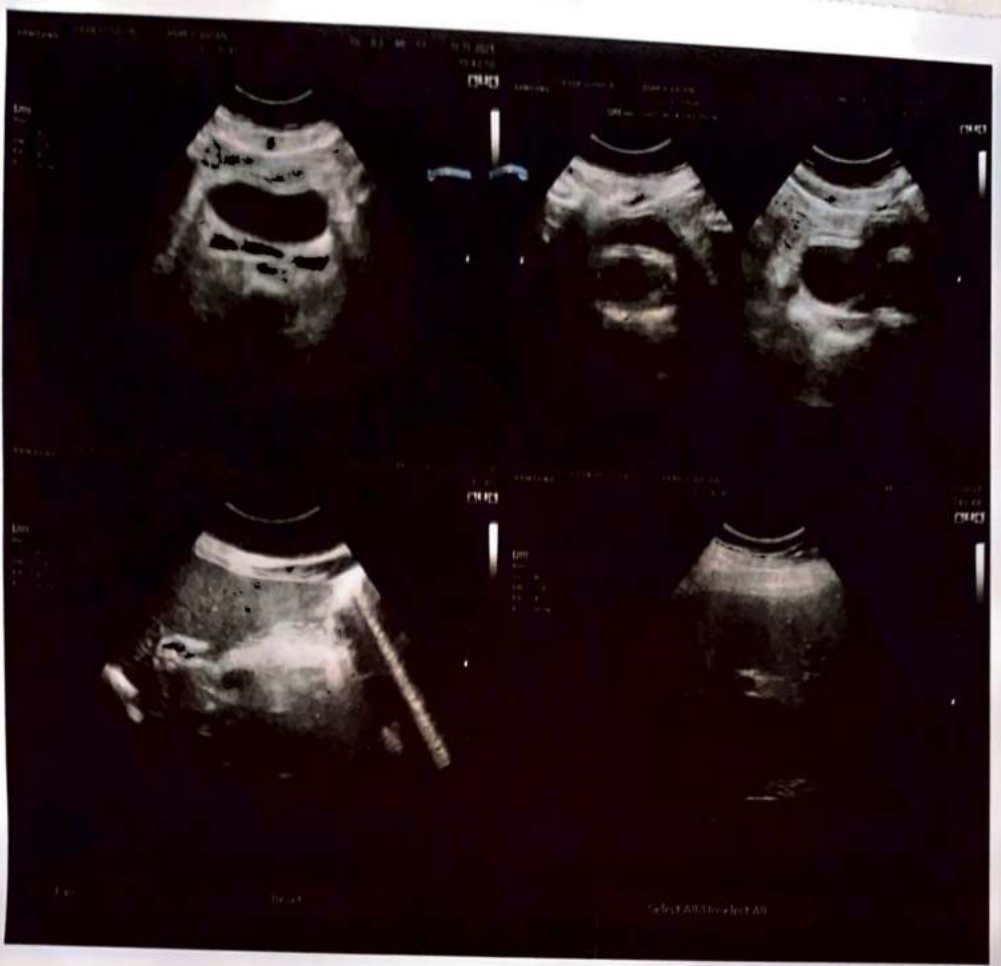J-Block, Sector-10, Near Court, Faridabad - 121004, Haryana

Tel.: 0129-4200000 E-mail : parkfaridabad@gmail.com

PARK GROUP OF HOSPITALS : West Delhi • South Delhi • Gurgaon • Karnal • Panipat • Hodal • Ambala • Behror

the **health** care providers

the **health** care providers





DEPARTMENT OF RADIOLOGY

Patient Name	Mr ANMOL RATAN	Billed Date	: 11/11/2023	9.59 AM
Reg No	28577	Reported Date	: 11/11/2023	
Age/Sex	56 Years 10 Months 11Days / Male	Req. No.	: 23064947	
Type	OPD	Consultant Doctor	: Dr. CONSULTANT	

USG WHOLE ABDOMEN

LIVER : The liver is normal in size, shape and shows increased echotexture. No evidence of any focal lesion. IHBR is NOT dilated. Portal vein is normal.

GALL BLADDER :The gall bladder is well distended. No evidence any calculus or mass seen. GB wall thickness with in normal limits. No evidence of pericholecystic fluid is seen. The common bile duct is normal.

SPLEEN :The spleen is normal in size and shape. Its echotexture is homogeneous. No evidence of focal lesion is noted. Splenic vein is normal.

PANCREAS :The pancreas is normal in size, shape, contours and echotexture.

BILATERAL KIDNEYS : The bilateral kidneys are normal in size and echotexture. Cortico-medullary differentiation is maintained. There is no evidence of obvious calculus or hydronephrosis seen. **Few cystic lesions are seen in both kidneys, largest measuring ~ 3.3x3.2cm in right kidney.**

URINARY BLADDER :The urinary bladder is well distended. Wall thickness within normal limits. No evidence of calculus is seen. No evidence of mass or diverticulum is noted.

PROSTATE : Prostate appears mildly enlarged in size (Vol : 25cc), normal in shape and echotexture.

No free fluid is seen in peritoneal cavity.

No evidence of obvious retroperitoneal or mesenteric lymphadenopathy is seen.

IMPRESSION: - USG WHOLE ABDOMEN REVEALS

Grade I fatty liver.

Bilateral renal cysts.

Prostatomegaly.

DR BINOD KR CHAUDHARY
MBBS,MD

CONSULTANT RADIOLOGIST

(This is only professional opinion and not the diagnosis, Please correlate clinically)

J-Block, Sector-10, Near Court, Faridabad - 121004, Haryana

Tel.: 0129-4200000 E-mail : parkfaridabad@gmail.com

PARK GROUP OF HOSPITALS : West Delhi • South Delhi • Gurgaon • Karnal • Panipat • Hodal • Ambala • Behror



ECHO REPORT

Name of the patient: MR ANMOL RATAN Age: 56 Sex: Male Female

UHID No: 28577 ~~IPD No:~~ 23064947 Date: 11/11/23

Refer By Doctor: DR. RAKESH ARORA

LVEF% 60%

2D ECHO

> Mitral Value Normal Pulmonary Value N Pulm
 > Artery N
 > Aortic avive N Tricuspid valve N

2D RWMA

> NO RWMA (Regional wall motion abnormality) at rest

COLD DOPPLER

> NO Significant Vavular stenosis / Regurgiation

COMMENTS AND SUMMARY

> All cardiac chambers of N size and shape NO dilatation or hypertrophy.
 > NO RWMA (Regional wall motion abnormality) at rest
 > NO Cloth / Vegetation/ pericardial effusion
 > LV 60% Systolic function
 > NO Significant Vavular stenosis / Regurgiation

Final Impression

> EF at Rest 60%

COMMENTS 2DECHO & Color Doppler study was

[Handwritten Signature]

Consultant Cardiology
 Doctor Name : Dr.
 Date :

Signature
 Time

Dr. Rakesh Kumar Arora
 MBBS, MD, DM (Cardiology)
 Reg. No. DMC - 16390
 Consultant - Cardiology
 Park Hospital, Faridkot



DEPARTMENT OF PATHOLOGY

Patient Name : Mr. ANMOL RATAN

MR No : 28577

Age/Sex : 56 Years 10 Months 11 Days / Male

Type : OPD

TPA/Corporate : MEDIWHEEL

Bill Date : 11/11/2023

Reporting Date : 11/11/2023

Sample ID : 4864

Bill/Req. No. : 23064947

Ref Doctor : Dr.CONULTANT

Test	Result	Bio. Ref. Interval	Units
CBC			
HAEMOGLOBIN	13.0	12 - 16	gm/dL
PACKED CELL VOLUME	42.9	35.0 - 50.0	%
RED BLOOD CELL COUNT	4.55	3.5 - 5.5	millions/ μ L
MEAN CORPUSCULAR VOLUME	94.3	83 - 101	fL
MEAN CORPUSCULAR HAEMOGLOBIN	28.6	27 - 31	pg
MEAN CORPUSCULAR HB CONC	30.3 L	33 - 37	g/dl
RDW	13.2	11.6 - 14.5	%
TOTAL LEUCOCYTE COUNT	6910	4000-11000	/ μ L
DIFFERENTIAL COUNT			
NEUTROPHILS	58	40.0 - 80.0	%
LYMPHOCYTES	33	20 - 40	%
MONOCYTES	07	2.0 - 10.0	%
EOSINOPHILS	02	0.0 - 5.0	%
BASOPHILS	00	0.0 - 2.0	%
PLATELET COUNT	1.17 L	1.50 - 4.50	lac/cumm

***** END OF THE REPORT *****



Sample no.

Dr. VAISHALI YADAV Dr.REETU JADHAV Dr. PARDIP KUMAR S.C.GAUR
CONS.PATHOLOGIST CONS.PATHOLOGIST MICROBIOLOGIST & ICO LAB INCHARGE USER NM DEEPCHAND

(This is only professional opinion and not the diagnosis, Please correlate clinically)

J-Block, Sector-10, Near Court, Faridabad - 121004, Haryana

Tel.: 0129-4200000 E-mail : parkfaridabad@gmail.com

PARK GROUP OF HOSPITALS : West Delhi • South Delhi • Gurgaon • Karnal • Panipat • Hodal • Ambala • Behror



DEPARTMENT OF PATHOLOGY

Patient Name : Mr. ANMOL RATAN
MR No : 28577
Age/Sex : 56 Years 10 Months 11 Days / Male
Type : OPD
TPA/Corporate : MEDIWHEEL
Bill Date : 11/11/2023
Reporting Date : 11/11/2023
Sample ID : 48640
Bill/Req. No. : 23064947
Ref Doctor : Dr.CONULTANT

Test	Result	Bio. Ref. Interval	Units
LFT (LIVER FUNCTION TEST)			
LFT			
TOTAL BILIRUBIN	0.6	0 - 1.2	mg/dL
DIRECT BILIRUBIN	0.2	0 - 0.4	mg/dL
INDIRECT BILIRUBIN	0.4	0.10 - 0.6	mg/dL
SGOT (AST)	41.3	0 - 45	U/L
SGPT (ALT)	38.1	0 - 45	U/L
ALKALINE PHOSPHATASE	78.7	30 - 170	IU/L
TOTAL PROTEIN	6.9	6.4 - 8.0	g/dL
ALBUMIN	4.3	3.3 - 5.5	g/dL
GLOBULIN	2.6	2.3 - 4.5	g/dL
A/G RATIO	1.65	1.1 - 2.2	

***** END OF THE REPORT *****



Sample no.

Dr. VAISHALI YADAV
 CONS.PATHOLOGIST
 Dr. REETU JADHAV
 CONS.PATHOLOGIST
 Dr. PARDIP KUMAR
 MICROBIOLOGIST & ICO
 S.C.GAUR
 LAB INCHARGE
 USER NM DEEPCHAND

(This is only professional opinion and not the diagnosis; Please correlate clinically)

J-Block, Sector-10, Near Court, Faridabad - 121004, Haryana
 Tel.: 0129-4200000 E-mail : parkfaridabad@gmail.com

PARK GROUP OF HOSPITALS : West Delhi • South Delhi • Gurgaon • Karnal • Panipat • Hodal • Ambala • Behror



DEPARTMENT OF PATHOLOGY

Patient Name : Mr. ANMOL RATAN
MR No : 28577
Age/Sex : 56 Years 10 Months 11 Days / Male
Type : OPD
TPA/Corporate : MEDIWHEEL
Bill Date : 11/11/2023
Reporting Date : 11/11/2023
Sample ID : 4864
Bill/Req. No. : 23064947
Ref Doctor : Dr.CONULTANT

Test	Result	Bio. Ref. Interval	Units
KFT (RENAL PROFILE)			
KFT			
SERUM UREA	27.0	10 - 45	mg/dL
SERUM CREATININE	1.0	0.4 - 1.4	mg/dL
SERUM URIC ACID	7.7 H H	2.5 - 7.0	mg/dL
SERUM SODIUM	146.2	136 - 148	mmol/L
SERUM POTASSIUM	4.8	3.5 - 5.5	mmol/L
CHLORIDE	108.0 H H	96 - 106	mmol/L

***** END OF THE REPORT *****



Sample no.

Dr. VAISHALI YADAV Dr. REETU JADHAV Dr. PARDIP KUMAR S.C. GAUR
 CONS. PATHOLOGIST CONS. PATHOLOGIST MICROBIOLOGIST & ICO LAB INCHARGE USER NM DEEPCHAND

(This is only professional opinion and not the diagnosis, Please correlate clinically)

J-Block, Sector-10, Near Court, Faridabad - 121004, Haryana

Tel.: 0129-4200000 E-mail : parkfaridabad@gmail.com

PARK GROUP OF HOSPITALS : West Delhi • South Delhi • Gurgaon • Karnal • Panipat • Hodal • Ambala • Behror



DEPARTMENT OF PATHOLOGY

Patient Name : Mr. ANMOL RATAN	Bill Date : 11/11/2023
MR No : 28577	Reporting Date : 11/11/2023
Age/Sex : 56 Years 10 Months 11 Days / Male	Sample ID : 48640
Type : OPD	Bill/Req. No. : 23064947
TPA/Corporate : MEDIWHEEL	Ref Doctor : Dr.CONULTANT

Test	Result	Bio. Ref. Interval	Units
BLOOD GROUPING AND rh FACTOR			
BLOOD GROUP	" B " Rh POSITIVE		

***** END OF THE REPORT *****



Sample no.

Dr. VAISHALI YADAV Dr. REETU JADHAV Dr. PARDIP KUMAR S.C. GAUR
CONS. PATHOLOGIST CONS. PATHOLOGIST MICROBIOLOGIST & ICO LAB INCHARGE USER NM DEEPCHAND

(This is only professional opinion and not the diagnosis, Please correlate clinically)

J-Block, Sector-10, Near Court, Faridabad - 121004, Haryana
Tel.: 0129-4200000 E-mail : parkfaridabad@gmail.com

PARK GROUP OF HOSPITALS : West Delhi • South Delhi • Gurgaon • Karnal • Panipat • Hodal • Ambala • Behror



DEPARTMENT OF PATHOLOGY

Patient Name : Mr. ANMOL RATAN	Bill Date : 11/11/2023
MR No : 28577	Reporting Date : 11/11/2023
Age/Sex : 56 Years 10 Months 11 Days / Male	Sample ID : 4864
Type : OPD	Bill/Req. No. : 23064947
TPA/Corporate : MEDIWHEEL	Ref Doctor : Dr.CONSULTANT

Test	Result	Bio. Ref. Interval	Units
BLOOD SUGAR FASTING			
PLASMA GLUCOSE FASTING	102.8	60 - 110	mg/dl

***** END OF THE REPORT *****



Sample no.

Dr. VAISHAL YADAV Dr.REETU JADHAV Dr. PARDIP KUMAR S.C.GAUR
CONS.PATHOLOGIST CONS.PATHOLOGIST MICROBIOLOGIST & ICO LAB INCHARGE USER NM DEEPCHAND

(This is only professional opinion and not the diagnosis, Please correlate clinically)

J-Block, Sector-10, Near Court, Faridabad - 121004, Haryana

Tel.: 0129-4200000 E-mail : parkfaridabad@gmail.com

PARK GROUP OF HOSPITALS : West Delhi • South Delhi • Gurgaon • Karnal • Panipat • Hodal • Ambala • Behror



DEPARTMENT OF PATHOLOGY

Patient Name : Mr. ANMOL RATAN
MR No : 28577
Age/Sex : 56 Years 10 Months 11 Days / Male
Type : OPD
TPA/Corporate : MEDIWHEEL

Bill Date : 11/11/2023
Reporting Date : 11/11/2023
Sample ID : 48640
Bill/Req. No. : 23064947
Ref Doctor : Dr.CONULTANT

Test	Result	Bio. Ref. Interval	Units
LIPID PROFILE			
LIPID PROFILE			
TOTAL CHOLESTEROL	139.18	120.0 - 200.0	mg/dL
SERUM TRIGLYCERIDES	79.61	40.0 - 160.0	mg/dl
HDL-CHOLESTEROL	41.25	30 - 70	mg/dl
VLDL CHOLESTEROL	15.92	6 - 32	mg/dL
LDL	82.01	50 - 135	mg/dl
LDL CHOLESTEROL/HDL RATIO	1.99	1.0 - 3.0	mg/dL
TOTAL CHOLESTEROL/HDL RATIO	3.37	2.0 - 5.0	mg/dl

***** END OF THE REPORT *****



Sample no.

Dr. VAISHALI YADAV Dr.REETU JADHAV Dr. PARDIP KUMAR S.C.GAUR
 CONS.PATHOLOGIST CONS.PATHOLOGIST MICROBIOLOGIST & ICO LAB INCHARGE USER NM DEEPCHAND

(This is only professional opinion and not the diagnosis, Please correlate clinically)

J-Block, Sector-10, Near Court, Faridabad - 121004, Haryana
 Tel.: 0129-4200000 E-mail : parkfaridabad@gmail.com

PARK GROUP OF HOSPITALS : West Delhi • South Delhi • Gurgaon • Karnal • Panipat • Hodal • Ambala • Behror



DEPARTMENT OF PATHOLOGY

Patient Name : Mr. ANMOL RATAN
MR No : 28577
Age/Sex : 56 Years 10 Months 11 Days / Male
Type : OPD
TPA/Corporate : MEDIWHEEL
Bill Date : 11/11/2023
Reporting Date : 11/11/2023
Sample ID : 48640
Bill/Req. No. : 23064947
Ref Doctor : Dr. CONSULTANT

Test	Result	Bio. Ref. Interval	Units
URINE ROUTINE AND MICROSCOPY			
PHYSICAL CHARACTERSTICS			
QUANTITY	30.0 ML	5 - 100	ML
COLOUR	Pale Yellow		
TURBIDITY	Clear	clear	
SPECIFIC GRAVITY	1.020	1.003 - 1.030	
PH	6.0	Acidic	
CHEMICAL EXAMINATION-1			
URINE PROTEIN	NIL	NIL	
GLUCOSE	NIL	NIL	
MICRO.EXAMINATION			
PUS CELL	2 - 3/HPF		CELLS/HPF
RED BLOOD CELLS	Nil	0-2	CELLS/HPF
EPITHELIAL CELLS	1-2/HPF	0-5	CELLS/HPF
CASTS	NIL	NIL	CELLS/HPF
CRYSTALS	NIL	NIL	CELLS/HPF
OTHER	NIL		

***** END OF THE REPORT *****



Sample no.

Dr. VAISHALI YADAV Dr. REETU JADHAV Dr. PARDIP KUMAR S.C. GAUR
 CONS. PATHOLOGIST CONS. PATHOLOGIST MICROBIOLOGIST & ICO LAB INCHARGE USER NM DEEPCHAND

(This is only professional opinion and not the diagnosis, Please correlate clinically)

J-Block, Sector-10, Near Court, Faridabad - 121004, Haryana

Tel.: 0129-4200000 E-mail : parkfaridabad@gmail.com

PARK GROUP OF HOSPITALS : West Delhi • South Delhi • Gurgaon • Karnal • Panipat • Hodal • Ambala • Behror



DEPARTMENT OF PATHOLOGY

Patient Name : Mr. ANMOL RATAN
 MR No : 28577
 Age/Sex : 56 Years 10 Months 11 Days / Male
 Type : OPD
 TPA/Corporate : MEDIWHEEL

Bill Date : 11/11/2023
 Reporting Date : 11/11/2023
 Sample ID : 48640
 Bill/Req. No. : 23064947
 Ref Doctor : Dr. CONSULTANT

Test	Result	Bio. Ref. Interval	Units
STOOL ROUTINE AND MICROSCOPY			
STOOL ROUTINE AND MICROSCOPY			
COLOUR	BROWNISH		
CONSISTENCY	Solid	Formed	
PH	ALKALINE	>= 5.5	
RBCS	NIL	NIL	
CYSTS	NIL	NIL	
OVA	NIL	NIL	
PUS CELLS	1-2/hpf	NIL	
MUCUS	NIL	NIL	

***** END OF THE REPORT *****



Sample no.

Dr. VAISHALI YADAV
 CONS.PATHOLOGIST

Dr. REETU JADHAV
 CONS.PATHOLOGIST

Dr. PARDIP KUMAR
 MICROBIOLOGIST & ICO

S.C.GAUR
 LAB INCHARGE

USER NM DEEPOCHAND

(This is only professional opinion and not the diagnosis, Please correlate clinically)

J-Block, Sector-10, Near Court, Faridabad - 121004, Haryana
 Tel.: 0129-4200000 E-mail : parkfaridabad@gmail.com

PARK GROUP OF HOSPITALS : West Delhi • South Delhi • Gurgaon • Karnal • Panipat • Hodal • Ambala • Behror



DEPARTMENT OF PATHOLOGY

Patient Name : Mr. ANMOL RATAN
 MR No : 28577
 Age/Sex : 56 Years 10 Months 11 Days / Male
 Type : OPD
 TPA/Corporate : MEDIWHEEL

Bill Date : 11/11/2023
 Reporting Date : 11/11/2023
 Sample ID : 48640
 Bill/Req. No. : 23064947
 Ref Doctor : Dr.CONSULTANT

Test	Result	Bio. Ref. Interval	Units
BLOOD SUGAR 2 HR. PP			
BLOOD SUGAR P.P.	170.0 H H	80 - 150	mg/dl

***** END OF THE REPORT *****



Sample no.

Dr. VAISHALI YADAV
 CONS.PATHOLOGIST
 Dr.REETU JADHAV
 CONS.PATHOLOGIST
 Dr. PARDIP KUMAR
 MICROBIOLOGIST & ICO
 S.C.GAUR
 LAB INCHARGE
 USER NM DEEPCHAND

(This is only professional opinion and not the diagnosis, Please correlate clinically)

J-Block, Sector-10, Near Court, Faridabad - 121004, Haryana
 Tel.: 0129-4200000 E-mail : parkfaridabad@gmail.com

PARK GROUP OF HOSPITALS : West Delhi • South Delhi • Gurgaon • Karnal • Panipat • Hodal • Ambala • Behror

DEPARTMENT OF PATHOLOGY

Patient Name : Mr. ANMOL RATAN

MR No : 28577

Age/Sex : 56 Years 10 Months 11 Days / Male

Type : OPD

TPA/Corporate : MEDIWHEEL

Bill Date : 11/11/2023

Reporting Date : 16/11/2023

Sample ID : 48640

Bill/Req. No. : 23064947

Ref Doctor : Dr. CONSULTANT

Test	Result	Bio. Ref. Interval	Units
PSA - TOTAL (PROSTATIC SPECIFIC ANTIGEN) - CANCER MARKER			
PROSTATE SPECIFIC ANTIGEN(PSA)	1.72	0.0 - 4.0	ng/ml
Method : chemiluminescent immunoassay			

Note : Clinical Use: -

An aid in the early detection of Prostate cancer in Male. Follow up and amazement of Prostate cancer patients. Detect metastatic or persistent disease in patients following surgical or medical treatment of Prostate cancer

Note: -

False negative / positive results are observed in patients receiving mouse monoclonal antibodies for diagnosis or therapy. PSA levels may appear consistently elevated / depressed due to the interference by heterophilic antibodies & non-specific protein binding. PSA values regardless of levels should not be interpreted as absolute evidence of the presence or absence of disease. All values should be correlated with clinical findings and results of other investigations.

***** END OF THE REPORT *****



Sample no.



Dr. VAISHALI YADAV Dr. REETU JADHAV Dr. PARDIP KUMAR S.C. GAUR
 CONS. PATHOLOGIST CONS. PATHOLOGIST MICROBIOLOGIST & ICO LAB INCHARGE USER NM PRIYANKA

(This is only professional opinion and not the diagnosis, Please correlate clinically)

J-Block, Sector-10, Near Court, Faridabad - 121004, Haryana

Tel.: 0129-4200000 E-mail : parkfaridabad@gmail.com

PARK GROUP OF HOSPITALS : West Delhi • South Delhi • Gurgaon • Karnal • Panipat • Hodal • Ambala • Behror



DEPARTMENT OF PATHOLOGY

Patient Name : Mr. ANMOL RATAN

MR No : 28577

Age/Sex : 56 Years 10 Months 11 Days / Male

Type : OPD

TPA/Corporate : MEDIWHEEL

Bill Date : 11/11/2023

Reporting Date : 11/11/2023

Sample ID : 48640

Bill/Req. No. : 23064947

Ref Doctor : Dr.CONSULTANT

Test	Result	Bio. Ref. Interval	Units
HB A1C GLYCOSYLATED HAEMOGLOBIN			
HBA1C	6.1		%

Note : Non-Diabetics 4.0 - 6.0 %

In Diabetics

Good Control 6.1 - 6.8 %

Fair Control 6.9 - 7.6 %

Poor Control > 7.6 %

***** END OF THE REPORT *****

OUT SOURCE
PARK HOSPITAL
CGN



Sample no

Dr. VAISHALI YADAV Dr.REETU JADHAV Dr. PARDIP KUMAR S.C.GAUR
CONS.PATHOLOGIST CONS.PATHOLOGIST MICROBIOLOGIST & ICO LAB INCHARGE USER NM SUNIL

(This is only professional opinion and not the diagnosis, Please correlate clinically)

J-Block, Sector-10, Near Court, Faridabad - 121004, Haryana

Tel.: 0129-4200000 E-mail : parkfaridabad@gmail.com

PARK GROUP OF HOSPITALS : West Delhi • South Delhi • Gurgaon • Karnal • Panipat • Hodal • Ambala • Behror



DEPARTMENT OF PATHOLOGY

Patient Name : Mr. ANMOL RATAN
MR No : 28577
Age/Sex : 56 Years 10 Months 11 Days / Male
Type : OPD
TPA/Corporate : MEDIWHEEL
Bill Date : 11/11/2023
Reporting Date : 13/11/2023
Sample ID : 48640
Bill/Req. No. : 23064947
Ref Doctor : Dr.CONSULTANT

Test	Result	Bio. Ref. Interval	Units
THYROID PROFILE			
TRI-IODOTHYRONINE (T3)	1.27	0.60 - 1.81	ng/ml
THYROXINE (T4)	7.4	5.01 - 12.45	µg/dL
THYROID STIMULATING HORMONE	1.84	0.5-5.50 ,	µIU/ml

***** END OF THE REPORT *****

OUT SOURCE
PARK HOSPITAL
GGN



Sample no.

Dr. VAISHALI YADAV Dr.REETU JADHAV Dr. PARDIP KUMAR S.C.GAUR
 CONS.PATHOLOGIST CONS.PATHOLOGIST MICROBIOLOGIST & ICO LAB INCHARGE USER NM DEEPCHAND

(This is only professional opinion and not the diagnosis, Please correlate clinically)

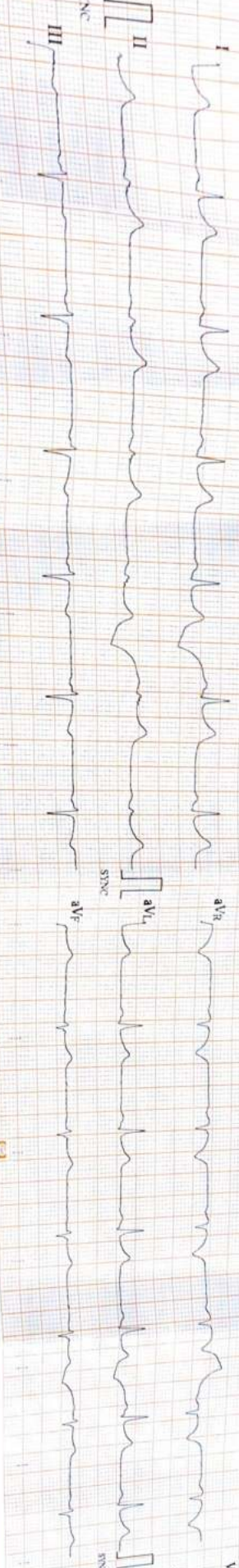
J-Block, Sector-10, Near Court, Faridabad - 121004, Haryana

Tel.: 0129-4200000 E-mail : parkfaridabad@gmail.com

PARK GROUP OF HOSPITALS : West Delhi • South Delhi • Gurgaon • Karnal • Panipat • Hodal • Ambala • Behror

25mm/s 50mm/mV

10mm/mV

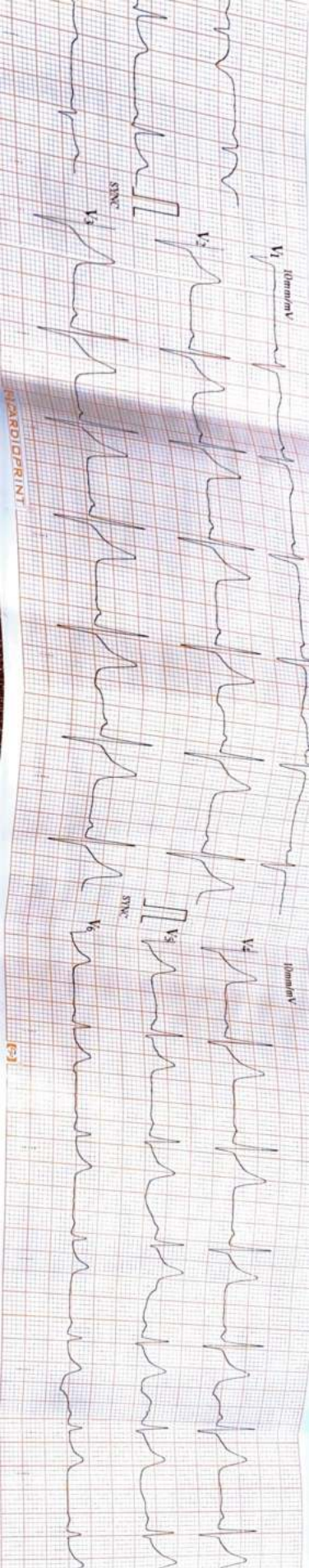


10mm/mV

10mm/mV

ECG CARDIOPRINT

2023-11-11 11:07



ID : 2953

HR : 51

P-R : 117.1

QRS : 0

QT/QTc : 0.0

P/QRS/T : 70.0

RV5/SV1 : 0.0

RV5+SV1 : 0

Age : 56y

Sex : Male

Name: Arvind Kishan

Unconfirmed report Verified by: [Signature]

ECG CARDIOPRINT