

Dharmendra Sarangi
M.

12/2/22

Eye check up

(R)

(L)

VA (A)

6/6

6/9

N6

N6

Dist Seg

NM

NM

color vis

(N)


(N)




Dr. Kedar Dighe
DNB(Oph), DOMS, MBBS
Consultant Eye Surgeon
Reg. No. 72882



भारत सरकार
Government of India



धर्मेन्द्र कुमार सारंगी
Dharmendra Kumar Sarangi
जन्म तिथि/DOB: 10/08/1978
पुरुष/ MALE



9401 5456 6334

VID : 9175 8332 0826 4350

मेरा आधार, मेरी पहचान


अनन्यता विविधता सहमान अधिकरण
Unique Identification Authority of India

पत्ता:
S/O गगन बिहारी सारंगी, फ्लॉट नं 304 ए विंग, प्लॉट नं 221, प्लाटीनम प्यलेसीओ 2, सेक्टर 23, उल्हे, उरान, रैडीगढ़, महाराष्ट्र - 410206

Address:
S/O Gagan Bihari Sarangi, Flat No 304 A Wing, Plot No 221, Platinum Palacio 2, Sector 23, Ulwe, Uran, Raigarh, Maharashtra - 410206



9401 5456 6334

VID : 9175 8332 0826 4350

© 2017
www.aui.gov.in

[Handwritten signature]



[Handwritten signature]

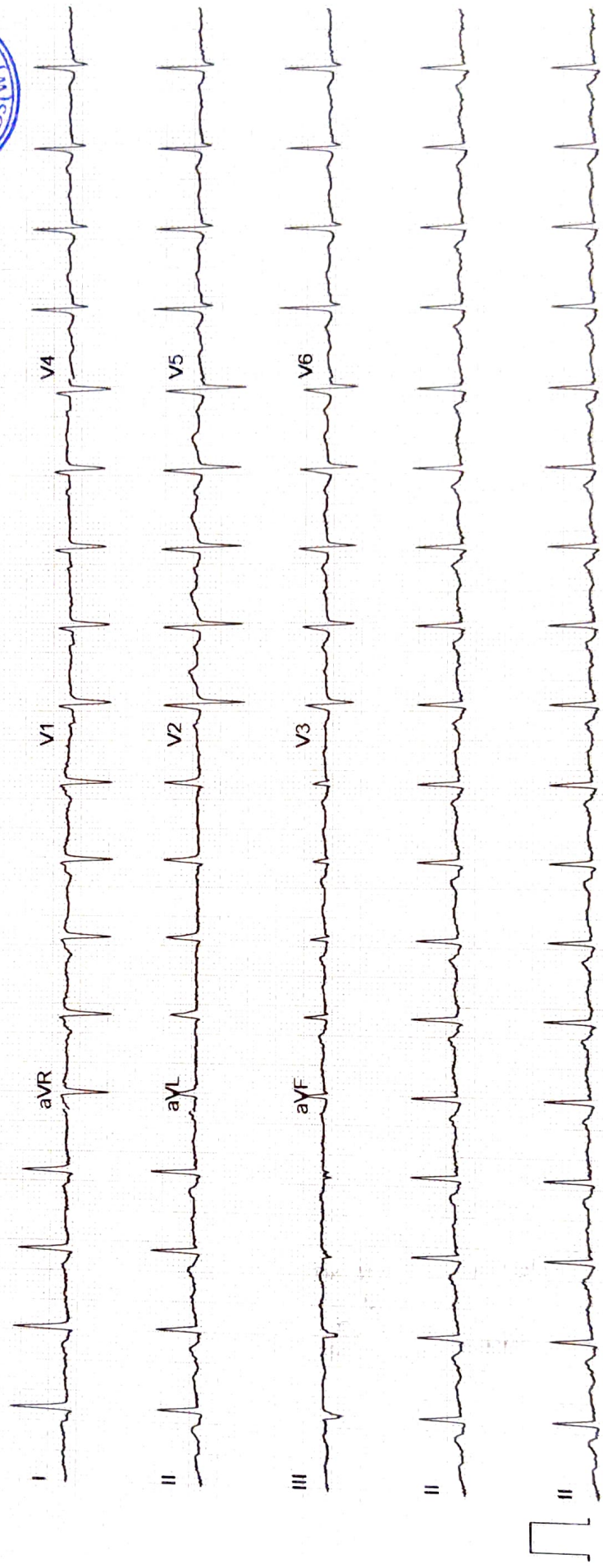
Dr. Mahesh V. Padsalge
MD. (Medicine)
Consultant Physician
Reg. No. 91424 (MMC)

Male

QRS : 74 ms
QT / QTcBaz : 306 / 417 ms
PR : 144 ms
P : 102 ms
RR / PP : 534 / 535 ms
P / QRS / T : 50 / 22 / 48 degrees

Sinus tachycardia
Nonspecific T wave abnormality
Abnormal ECG

Dr. Mahesh V. Padsalge
MD. (Medicine)
Consultant Physician
Reg. No. 91424 (MMC)



Dr. Mahesh V. Padsalge

Dr. Mahesh V. Padsalge

ECHO Report

Date:12/2/2022

Patient Details

Patient ID –
Name- MR. DHARMENDRA SARANGI
Age- 43 YEARS
Gender- MALE
Referral By - MEDIWHEEL
Doctor Incharge DR. MAHESH PADSALGE

Clinical Status of Patient -

Finding description -

- 1. Normal cardiac chambers dimensions.**
- 2. Normal LV systolic function.**
- 3. No RWMA.**
- 4. All cardiac valves are structurally normal.**
- 5. Trivial MR, Trivial PR, NO AR.**
- 6. No PAH.**
- 7. Normal RV systolic function.**
- 8. No clot/vegetation/pericardial effusion.**
- 9. No coarctation of aorta.**



Chamber Dimensions-M mode Findings

LVID (Diastole) 35-56(mm)	-	47.00	LVID (Systole) 24-42(mm)	-	30.00
IVS (Diastole) 8-12(mm)	-	10.00	IVS (Systole) 14-42(mm)	-	14.00
LVPWT (Diastole) 6-11(mm)	-	10.0	EPSS	-	5.00
LVEF (%)	-	65%	LVFS (%)	-	30.00

LV Volume (Diastolic)(mm³)
Meridional Wall Stress in System

LV Volume (Systolic)(mm³)
Cubed LV Volume in Diastole (mm³)

Cubed LV+ myocardial volume (mm³)

Velocity of circumferential
Shortening (mm)

Aortic root 22-37(mm)	-	23.00
Left Atrium Length (mm)	-	23.00
Left Atrium Volume (mm ³)		
RV size		Normal
RV volume (mm ³)		
Pericardium		Normal
Effusion		None
Resp Variation		Present
Predicted RV Systolic Pressure		

Left Atrium Width (mm)		
Left Atrium Area (mm ²)		
RV Function		Normal
RA Size		Normal

IVC Size (mm) – 13 mm Collapsible

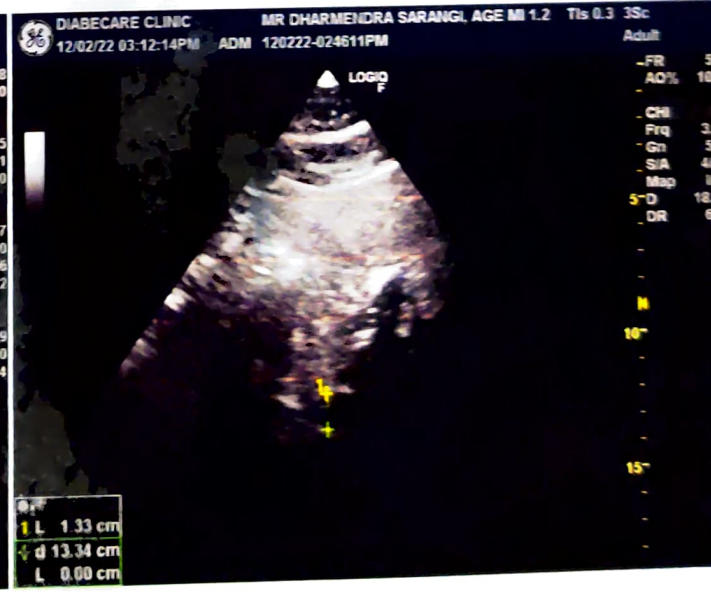
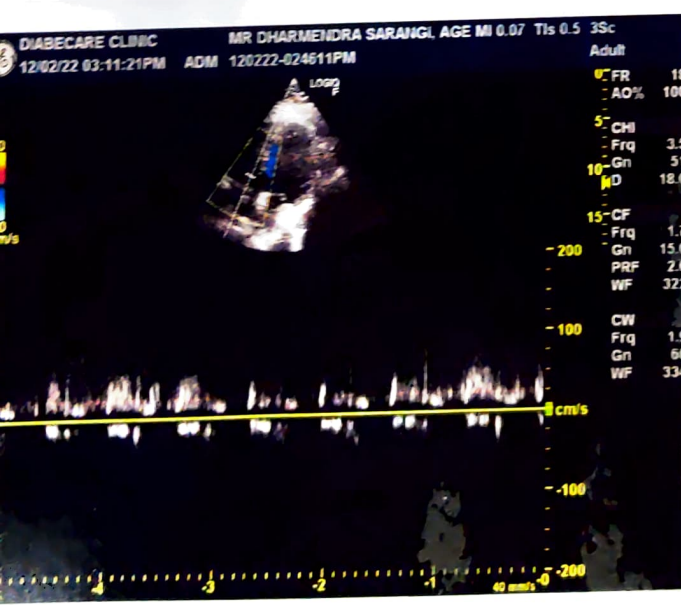
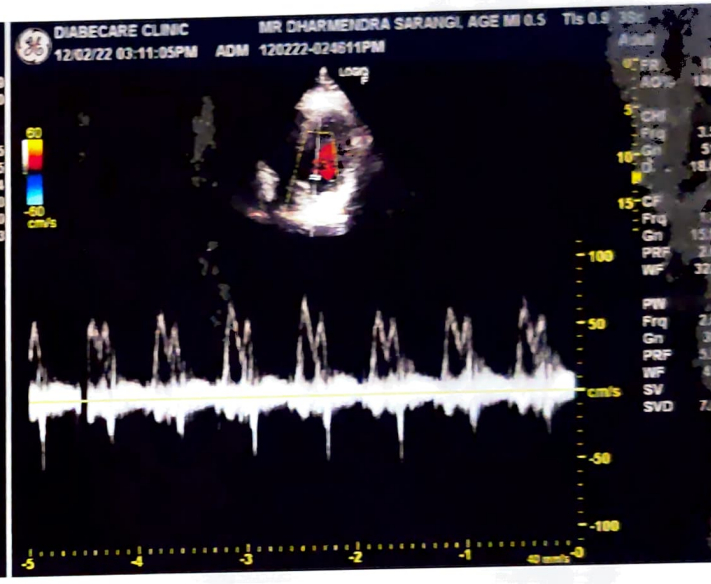
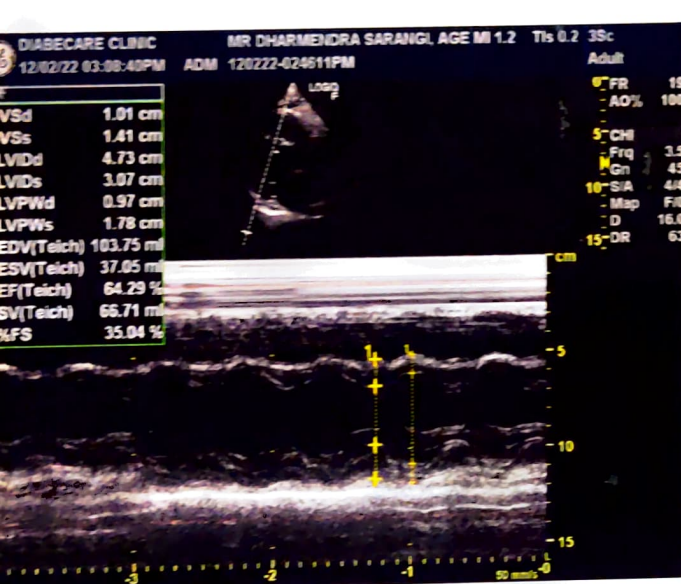
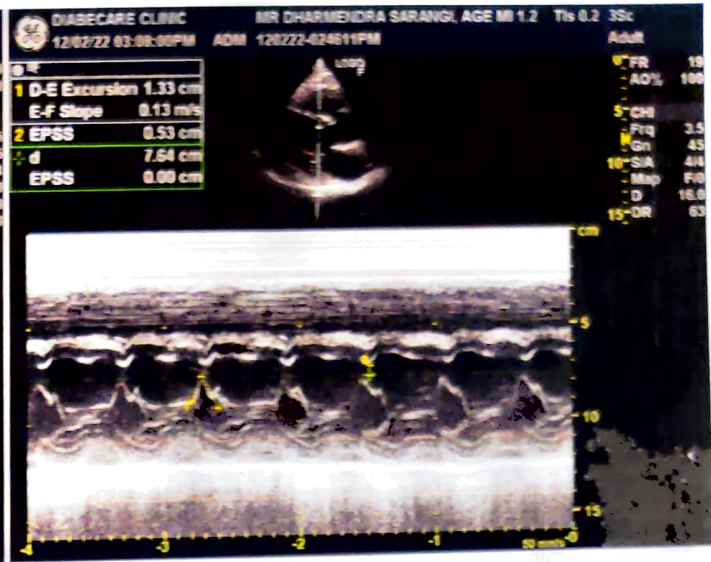
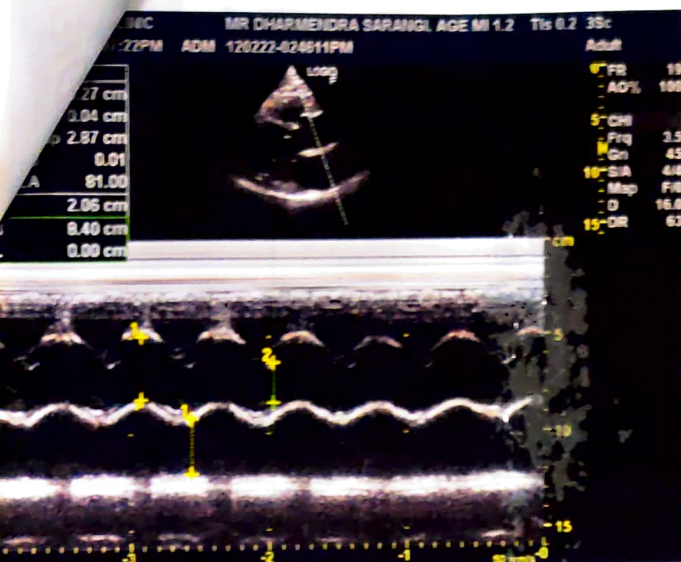
Doppler Findings- I



Dr. Mahesh Padsalge

Dr. Mahesh V. Padsalge
MD. (Medicine)
Consultant Physician
Reg. No. 91424 (MMC)





NAME - DHARMENDRA SARANGI**DATE- 12/2/2022****AGE-43/M****X-RAY CHEST PA**

THE SOFT TISSUES AND BONY THORAX ARE NORMAL.

BOTH THE COSTOPREHNIC AND CARDIOPHRENIC ANGLES ARE CLEAR.

THE LUNG FIELDS ARE NORMAL.

CARDIAC SHAPE AND SIZE APPEARS NORMAL.

BOTH THE HILA ARE NORMAL IN DENSITY AND POSITION.

BOTH THE DOMES OF DIAPHRAGM AND MEDIASTINUM ARE NORMAL.

IMPRESSION: NORMAL CHEST X-RAY.

For, 

**DR.SIDRAM JADHAV
RADIOLOGIST**

Dr. Sidram D. Jadhav
MBBS, DMRE (Radiologist)
Reg. No.: 2004 / 09 / 3526

Name : MR DHARMENDRA SARANGI	Age/sex: 43 Yrs. /MALE
Ref by: MEDIWHEEL	Date: 12/02/2022

ULTRASOUND EXAMINATION OF ABDOMEN & PELVIS

The Liver is enlarged in size(16.5cm) ,shape and grade-I increased echogenicity. No focal lesion is seen. The Hepatic veins appear normal. There is no IHBR dilatation. The portal vein appears normal.

The gall bladder is distended. The proximal C.B.D. is normal caliber

Visualized head of Pancreas appears normal in size and reflectivity. The pancreatic duct is not dilated. Rest of the pancreas and retro peritoneum is obscured by bowel gases

The spleen is normal in size, No focal lesion is seen. Splenic vein is normal at hilum.

Both kidneys are normal in position and size. They show normal cortical reflectivity and cortico-medullary differentiation. There is no evidence of renal calculus, hydronephrosis or mass.

Right kidney measures 11.1 x 4.4 cm

Left kidney measures 12.0 x 4.7cm

The Urinary bladder is well distended. No evidence of any intraluminal mass or calculi.

The visualized Prostate appears normal in size, shape and homogenous echotexture.

There is no free fluid is seen.

IMPRESSION :-

➤ **MILD HEPATOMEGALY WITH GRADE-I FATTY INFILTRATION.**

• **Adv : clinical correlation.**



Dr. SIDRAM JADHAV
CONSULTANT RADIOLOGIST

Dr. Sidram D. Jadhav
MBBS, DMRE (Radiologist)
Reg. No.: 2004 / 09 / 3526

