



भारत सरकार
GOVERNMENT OF INDIA

Download Date: 06/04/2019



प्रीति श्रीवास्तवा
Preeti Srivastava
जन्म तिथि / DOB : 07-04-1984
लिंग / GENDER : FEMALE
Mobile No. 9818720368
5340 9384 5778
VID : 9196 2657 4984 9882

Issue Date: 07/11/2019

मेरा आधार, मेरी पहचान

Preeti



भारतीय विशिष्ट पहचान प्राधिकरण
UNIQUE IDENTIFICATION AUTHORITY OF INDIA

आधार

पता:
D/O एस.के. श्रीवास्तवा, विजया बैंक के पीछे, मयूर
विहार, ईस्ट दिल्ली,
दिल्ली - 110091



Address
D/O S.K. Srivastava D-11 ACHARYA NIKETAN
GALAXY HOUSE BEHIND VIJAYA BANK
MAYUR VIHAR East Delhi Delhi - 110091

5340 9384 5778



1947
1800 300 1947

help@uidai.gov.in

www.uidai.gov.in

P.O. Box No.1947,
Bengaluru-560 001

Malik Radix Health Care Pvt. Ltd.
C-217, C-218, Nirman Vihar
Delhi-110092
Ph. : 011-22011190, 22011192
Road No. 007



MALIK RADIX HEALTH CARE

(UNIT OF MALIK RADIX HEALTHCARE PVT. LTD)

C-217, 218, Nirman Vihar, Vikas Marg, New Delhi - 110092

Tel.: 011-22011192, 22011196, 47060150 • Fax.: 22011208

E-mail : radixhealthcare@yahoo.co.in

Website : www.radixhealthcare.org



Safety at WEI now accredited by NABH

Name - Preeti Srivastava
Age - 38yr / F

8/11/22

6/10 eye
6/18 eye

As: Dry Eye

using
not brought

near L No
No

Ad

9 dry eye

(2)

Dr. Nidhi Gupta
MBBS, MS, DNB
Casualty/OPD Specialist
Malik Radix Healthcare Pvt. Ltd.
DMC No. 11111

Facilities Available :

MRHC / GEN / FR / 15

- ★ Multispeciality Hospital ★ 24 Hours Emergency ★ X-Ray/ ECG/ Ultrasound ★ Dental
- ★ Fully Equipped Operation Theatre ★ Fully Functional Lab ★ Casualty/ICU ★ Nursery
- ★ Labour Room ★ All Speciality OPD ★ Laparoscopic Surgery ★ ECHO ★ Plastic Surgery

Home Collection Facility Available Contact : 8587915647



CONSULTANTS ON PANEL

PAEDIATRICS

Dr. Ravi Malik (MBBS, MD)
Dr. Amit Kumar (MBBS, DCH, DNB)
Dr. Sikha Mangla (MBBS, MD)
Dr. S. K. Garg (MBBS, MD)

GYNAECOLOGY

Dr. Renu Malik (MBBS, MD)
Dr. Rupam Arora (MBBS, MD)
Dr. Meena Malhotra (MBBS, MD)
Dr. Santosh Sachdeva (MBBS, DGO)
Dr. Nupur Pagore (MBBS, MD)
Dr. Vaishali Saini (MBBS, DGO)

DENTAL

Dr. Shruti Malik (BDS, MDS)
Dr. Rachit Thakral (BDS, MDS)
Dr. Amrita (BDS)

MEDICINE

Dr. A. S. Talwar (MBBS, MD)
Dr. B. B. Sardana (MBBS, MD)

RESPIRATORY MEDICINE

Dr. Abhinav Bhanot (MBBS, DNB)

SURGERY

Dr. Ajay Jain (MBBS, MS)
Dr. Pradeep Saini (MBBS, MS)
Dr. G. S. Garg (MBBS, MS)
Dr. Yogesh Aggarwal (MBBS, MS)

ORTHOPAEDICS

Dr. Vikas Bhardwaj (MBBS, MS, Ortho, DNB)
Dr. Deepak Kumar Arora (MBBS, MS, Ortho)

EYE

Dr. Nidhi Gupta (MBBS, MS, DNB, PGDM)
Dr. Himanshu Singh (MBBS, MS)

ENT

Dr. A. K. Lahiri (MBBS, MS, DLO)
Dr. Anurag Jain (MBBS, MS, DLO)
Dr. Ashok Singh (MBBS, MS)
Dr. S. K. Gupta (MBBS, MS)

RADIOLOGY (Ultrasound)

Dr. K. K. Singh (MBBS, DMRD)
Dr. Shuchi Agarwal (MBBS, MS, Radio)

PATHOLOGY

Dr. Reema Dhayya (MBBS, MD, PATH)
Dr. Meenu Aggarwal (MBBS, MD, PATH)

ANAESTHESIA

Dr. R. Arora (MBBS, MD)
Dr. Rakesh Atrey (MBBS, MD)
Dr. Swaraj Garg (MBBS, MD)
Dr. Rajesh Dhall (MBBS, MD)
Dr. Rakesh Gupta (MBBS, MD)

DERMATOLOGY & COSMETIC SURGERY

Dr. Nitesh Singhal (MBBS, MD)
Dr. Jitendra Saran (MBBS, MD)

PLASTIC SURGERY

Dr. V. N. Dudani (MBBS, MS, M.Ch.)
Dr. Akhilesh Jangid (MBBS, MS, M.Ch.)
Dr. Mukesh (MBBS, MCh)

PAEDIATRIC SURGERY

Dr. Satish Aggarwal (MBBS, MS, M.Ch.)
Dr. Handa (MBBS, MS, M.Ch.)
Dr. Dharmendra Singh (MBBS, MS, M.Ch.)

PAED.ENDOCRINOLOGY

Dr. I. P. S. Kochhar (MBBS, MD, MAMS, MRCP)

PAEDIATRIC NEPHROLOGY

Dr. A. S. Vashudev (MBBS, MD, Dip. in Paed.)

NEPHROLOGY

Dr. S. R. Kabra (MBBS, MD, DM)

CARDIOLOGY

Dr. Sanjay (MBBS, DIP, Card.)
Dr. Partha Chaudhry (MBBS, MD, Cardio)

NEUROLOGY

Dr. Deepak Srivastava (MBBS, MD, DM)
Dr. Amit Batra (MBBS, MD)

GASTROENTEROLOGY

Dr. Nareesh Aggarwal (MBBS, MS, DM)
Dr. Deepak Lahoti (MBBS, MD, DM)

UROLOGY

Dr. Ajay Aggarwal (MBBS, MS, M.Ch.)
Dr. Shailesh Saha (MBBS, M.Ch.)
Dr. Nikhil Sharma (MBBS, MS, M.Ch.)

PSYCHIATRY

Dr. Sunil Awana (MBBS, Dip Psy. Med DNB, PSY.)
Dr. Sandeep Govil (MBBS)

GASTRO PHYSICIAN

Dr. Rohit Sharma

PHYSIOTHERAPY

Dr. Kirti Dixit (BPT, MPT)
Dr. Sunil Aggarwal

CLINICAL PSYCHOLOGIST

Dr. Sapna Paliwal
Dr. Yukti

DIETICIAN

Ms. Sakshi Rana (M.Sc./Home Science)

SPEECH THERAPY

Murli Singh Nehra

Dr. Shruti Malik

BDS, MDS (Endodontics)
☎ +91-9899561092

Name : Preeti Srivastava
Age/Sex : 38 y / F
Date : 8/11/22

Timings : 9:00 am. to 1:30 pm.
6:00 pm. to 8:30 pm.

For Appointment
☎ +91-9999254639

CLINICAL EXAMINATION:-

1. TMJ:-

Routine checkup

2. DENTAL STATUS:

7/E

- a. Caries Teeth :
- b. Fracture Teeth :
- c. Root Stumps :
- d. Gingivitis :
- e. Periodontitis :
- f. Impacted Teeth :
- g. Malaligned Teeth :

Calculus +++

Stains ++

Caries

+ 8

Adv.

- oral prophylaxis

3. ORAL LESIONS:-

- P-Kit

4. DIAGNOSIS:-

Gleetika

5. TREATMENT PLANNING:

6. FOLLOW UP:-

Referral To Other Consultant: Yes/ No

If Yes, please mention the Name:

Doctor's Signature

Facilities Available :

- ★ Multispeciality Hospital ★ 24 Hours Emergency ★ X-Ray/ ECG/ OPG Ultrasound ★ Dental
- ★ Fully Equipped Operation Theatre ★ Fully Functional Lab ★ Casualty/ICU ★ Nursery
- ★ Labour Room ★ All Speciality OPD ★ Laparoscopic Surgery ★ ECHO ★ Plastic Surgery

Echocardiogram Report

Patient Name	MRS. PREETI SRIVASTAVA
Date of Test	08/11/2022
Age	38YRS/ FEMALE
Ref. by	MEDI WHEEL

Dimensions	Result	Normal Range
AO (ed)	2.7 cm	(2.1 -3.7cm)
LA (es)	3.4 cm	(2.1 -3.7cm)
RVID (ed)	3.8 cm	(1.1-3.0cm)
LVID (ed)	4.1 cm	(3.6 – 5.5 cm)
LVID (es)	2.7 cm	(2.3-3.9cm)
IVS (ed)	0.9 cm	(0.6 – 1-2 cm)
LVPW (ed)	1.0 cm	(0.6 – 1-2 cm)
EF	62 %	
FS	33 %	(28 % - 42 %)

Impression

NO REGIONAL WALL MOTION ABNORMALITY SEEN.

LVEF= 62 %

DILATED RIGHT VENTRICLE & RIGHT ATRIUM.

MODERATE MITRAL REGURGITATION.

MILD AORTIC REGURGITATION.

NORMAL MIP .

MODERATE TRICUSPID REGURGITATION.

RVSP BY TR JET IS 27.0mmHg + RAP. s/o MODERATE PA HYPERTENSION.

NO INTRA CARDIAC CLOT/MASS/ VEGETATION/PERICARDIAL EFFUSION SEEN

Dr. Nishant Tyagi

(M.D. Medicine. DNB Cardiology)

(Senior Consultant, Cardiology)

Dr. Sheikh Nazir Ahmed

M.D. "Physician" PGDCC

(Consultant Non – Invasive Cardiologist)

Facilities Available :

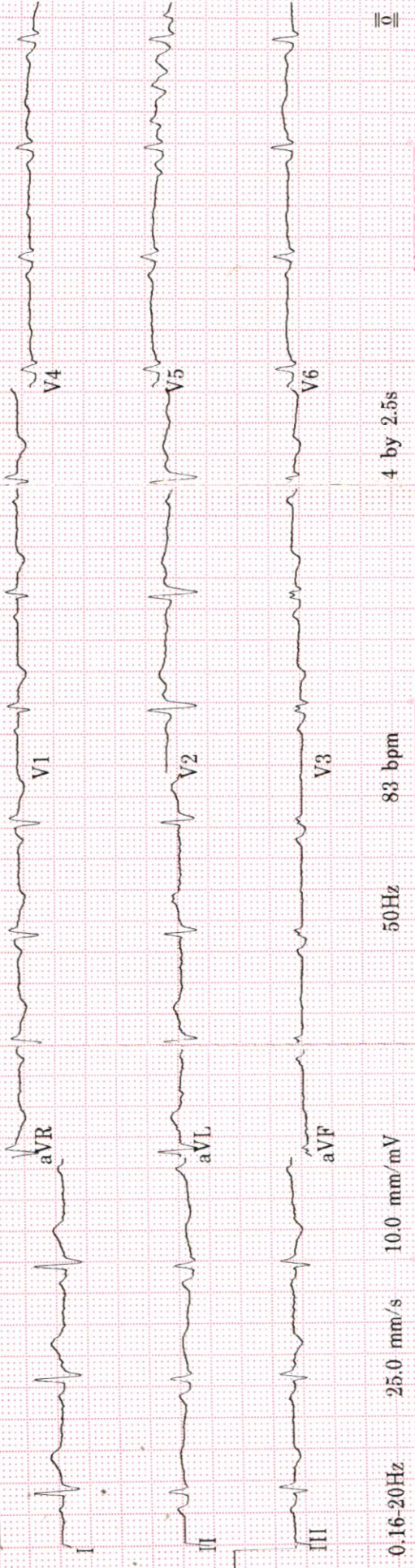
GE

MAC600 1.02

ID: 7355436578

8-Nov-2022 12:24:12

ID: 7355436578



38years Female

Vent. rate 83 bpm
 QRS duration 76 ms
 QT/QTc 356/418 ms
 PR interval 146 ms
 P duration 108 ms
 RR interval 722 ms
 P-R-T axes 57 35 26

Handwritten signature

0.16-20Hz

25.0 mm/s

10.0 mm/mV

50Hz

83 bpm

4 by 2.5s

MAC600 1.02

12SL™ v239

ECG

ECG

ECG

ECG

ECG

ECG

ECG

ECG

Malik Radix HealthCare.

ELECTROCARDIOGRAM

Name: MRS. PREETI SHRIVASTAVA

Age & Sex: 38YR/FEMALE

Ref By: MEDIWHEEL

Date: 08/11/2022

EKG FINDINGS:

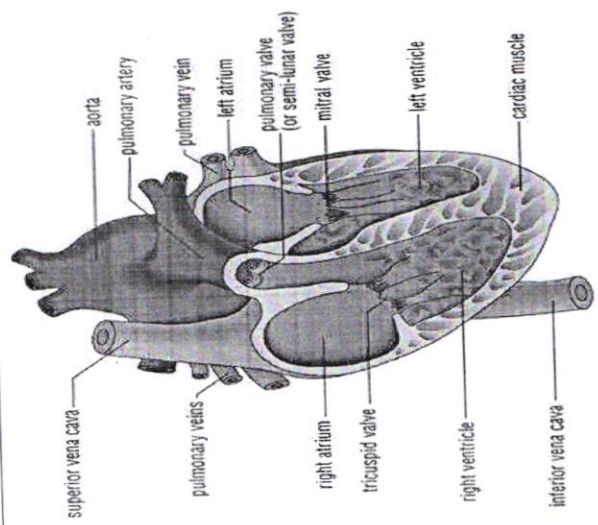
Rate 84bpm Rhythm Sinus Mechanism Normal

Axis Normal P Wave Normal PR Interval 0.14/Sec

QRS Complex Normal QT Interval Normal Q Wave Normal

ST Segment Normal T Wave Normal

Conclusion Sinus Rhythm, Normal Axis, Normal ECG.



Doctors Signature Dr. SHEKHAR AZIZ AHMED
M.D. Physician
PGDGT
DMC-46499



LAB REPORT

Reg. Date	08/11/2022	Patient Id	2211080002	DOB.	
Name	MRS. PREETI SHRIVASTAVA			Perm. ID	
Age	38 Yrs.	Gender	F	Reported	08/11/2022 17:17:12
Ref. By	MEDIWHEEL	Panel	MEDIWHEEL		

Test Name	Result	Units	Ref. Range
MEDIWHEEL F ABOVE 40			

HAEMATOLOGY

COMPLETE HAEMOGRAM

HAEMOGLOBIN (HB%)	13.2	gm/dl	12 - 15
TOTAL LEUCOCYTE COUNT (TLC)	5,600	/cumm	4000 - 11000

DIFFERENTIAL LEUCOCYTE COUNT (DLC)

NEUTROPHIL	51	%	40 - 80
LYMPHOCYTE	39	%	28 - 55
MONOCYTE	07	%	02 - 10
EOSINOPHIL	03	%	01 - 06
BASOPHIL	00	%	0 - 0
ESR (WESTEGREN'S METHOD)	16	mm/1st hr.	0 - 15
R B C COUNT	4.49	Millions/cmm	4.247 - 5.4
P.C.V / HAEMATOCRIT	40.5	%	35 - 45
M C V	90.2	fl.	80 - 100
M C H	29.4	Picogram	27.0 - 31.0
M C H C	32.6	gm/dl	33 - 37
PLATELET COUNT	1.71	Lakh/cu mm	1.50 - 4.50

Urine Routine Examination

PHYSICAL EXAMINATION

QUANTITY	20	ml.	
COLOUR	Pale Yellow		Pale Yellow
TRANSPARENCY	Clear		
SPECIFIC GRAVITY	1.015		
PH	6.5		

Checked by : _____
Page 1 Contd...2

If test results are alarming or unexpected, patient is advised to contact the laboratory immediately for possible remedial action.

Facilities Available

- Multispeciality Hospital - 24 Hours Emergency - X-Ray/ ECG/ Ultrasound/ CT Scan - Dental - Fully Equiped Operation Theatre - Fully Functional Lab - Casualty/ ICU-Nursery - Labour Room - All Speciality OPD - Laproscopic Surgery - ECHO - Plastic Surgery



LAB REPORT

Reg. Date	08/11/2022	Patient Id	2211080002	DOB.	
Name	MRS. PREETI SHRIVASTAVA	Gender	F	Perm. ID	
Age	38 Yrs.	Panel	MEDIWHEEL	Reported	08/11/2022 17:17:12
Ref. By	MEDIWHEEL				

Test Name	Result	Units	Ref. Range
CHEMICAL EXAMINATION			
ALBUMIN	Nil		
SUGAR	Nil		
MICROSCOPIC EXAMINATION			
PUS CELLS	0-1	/HPF	
RBC'S	Nil	/HPF	
CASTS	Nil		
CRYSTALS	NIL		
EPITHELIAL CELLS	0-1	/HPF	
BACTERIA	Nil		
OTHERS	Nil		
Stool Examination Report			
BLOOD GROUP ABO	" B "		
RH TYPING	Positive		
BLOOD SUGAR FASTING	73.46	mg/dl	70 - 100
BLOOD SUGAR PP	92.55	mg/dl	90 - 140
HBA1C	5.95	%	

Interpretation

Non Diabetic	: 4-6%
Good Diabetic Control	: 6-8%
Fair Control	: 8-10%

Checked by : _____
Page 2 Contd...3

If test results are alarming or unexpected, patient is advised to contact the laboratory immediately for possible remedial action.

Facilities Available

- Multispeciality Hospital - 24 Hours Emergency - X-Ray/ ECG/ Ultrasound/ CT Scan - Dental - Fully Equiped Operation Theatre
- Fully Functional Lab - Casualty/ ICU-Nursery - Labour Room - All Speciality OPD - Laproscopic Surgery - ECHO - Plastic Surgery



LAB REPORT

Reg. Date	08/11/2022	Patient Id	2211080002	DOB.	
Name	MRS. PREETI SHRIVASTAVA			Perm. ID	
Age	38 Yrs.	Gender	F	Reported	08/11/2022 17:17:12
Ref. By	MEDIWHEEL	Panel	MEDIWHEEL		

Test Name	Result	Units	Ref. Range
-----------	--------	-------	------------

Poor Control	: >10%		
--------------	--------	--	--

The Glycosylated haemoglobin assay has been validated as a reliable indicator Of mean blood glucose levels for a period of 8-12 week period. ADA recommended the testing twice a year in patients with stable blood glucose and quarterly. If treatment change, or if blood glucose levels are unstable.

TO BE CORRELATED CLINICALLY.

THYROID PROFILE

Free T3 ELFA	2.10	ng/ml	02 - 04
Free T4 ELFA	0.87	ug/dl	0.8 - 2.7
TSH Serum/ELFA	12.230	uIU/ml	0.25 - 5.50 uIU/ml

Interpretation

Clinical Use

- Diagnose Hypothyroidism and Hyperthyroidism
- Monitor T4 replacement or T4 suppressive Therapy
- Quantify TSH levels in the subnormal range

Increased Levels : Primary Hypothyroidism Subclinical Hypothyroidism, TSH dependent, Thyroid Hormone Resistance.

Decreased Levels : Grave's Disease, Autonomous Thyroid Hormone Secretion, TSH Deficiency

LIPID PROFILE

TOTAL CHOLESTEROL	157.00	mg/dL	130.0 - 200.0 (<200)
-------------------	--------	-------	----------------------

Checked by : _____
Page 3 Contd...4

If test results are alarming or unexpected, patient is advised to contact the laboratory immediately for possible remedial action.

Facilities Available

- Multispeciality Hospital - 24 Hours Emergency - X-Ray/ ECG/ Ultrasound/ CT Scan - Dental - Fully Equiped Operation Theatre - Fully Functional Lab - Casualty/ ICU-Nursery - Labour Room - All Speciality OPD - Laproscopic Surgery - ECHO - Plastic Surgery

**LAB REPORT**

Reg. Date	08/11/2022	Patient Id	2211080002	DOB.
Name	MRS. PREETI SHRIVASTAVA	Gender	F	Perm. ID
Age	38 Yrs.	Panel	MEDIWHEEL	Reported
Ref. By	MEDIWHEEL			08/11/2022 17:17:12

Test Name	Result	Units	Ref. Range
TRIGLYCERIDES	80.40	mg/dL	80.5 - 150.0 (<150)
H D L CHOLESTEROL DIRECT	33.03	mg/dL	42.0 - 60.0 (<40->59)
V L D L	16.1	mg/dL	4.0 - 30. (23-45)
L D L CHOLESTEROL	107.9	mg/dL	50.0 - 150.0 (50-150)
TOTAL CHOLESTEROL / HDL RATIO	4.8		3.3 - 5.1
LDL / HDL CHOLESTEROL RATIO	3.3		1.5 - 3.5
SERUM URIC ACID	5.17	mg/dl	2.4 - 6.0
BLOOD UREA NITROGEN (BUN)	11.20	mg/dl	6.0 - 21.0
SERUM CREATININE	1.20	mg/dl	0.6 - 1.2
BUN/CREAT RATIO	9.3	mg/dl	
<u>LIVER FUNCTION TEST (LFT)</u>			
BILIRUBIN TOTAL	0.73	mg/dl	0.2 - 1.2
CONJUGATED (D. BILIRUBIN)	0.26	mg/dl	0.00 - 0.3
UNCONJUGATED (I.D.BILIRUBIN)	0.47	mg/dl	0.2 - 0.9
SGOT / AST	18.54	IU/L	0 - 35
SGPT / ALT	22.55	IU/L	0 - 35
ALKALINE PHOSPHATASE	108.10	U/L	64 - 306
TOTAL PROTEIN	7.08	gm/dl	6.0 - 8.3
ALBUMIN	4.47	gm/dl	3.2 - 5.0
GLOBULIN	2.61	gm/dl	2.5 - 5.6
A/G RATIO	1.71		0.9 - 2.0
GAMMA GT	18.20	IU/L	0.0 - 35.0

10 - 20

Dr. REEMA DAHIYA

M.B.B.S, MD (Path.)

Malik Radix Healthcare Pvt. Ltd.

C-217, C-218, Nirman Vihar

Delhi-92

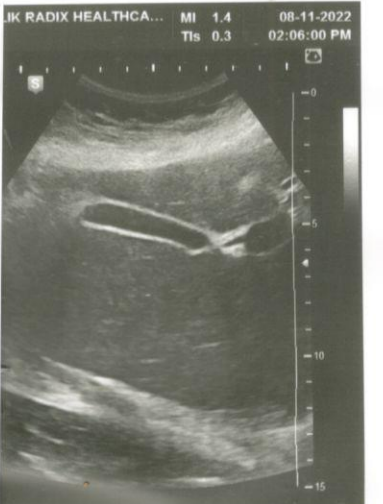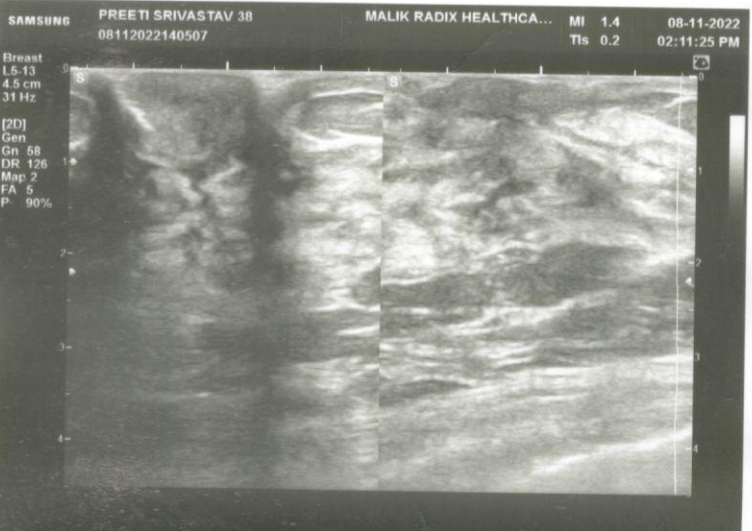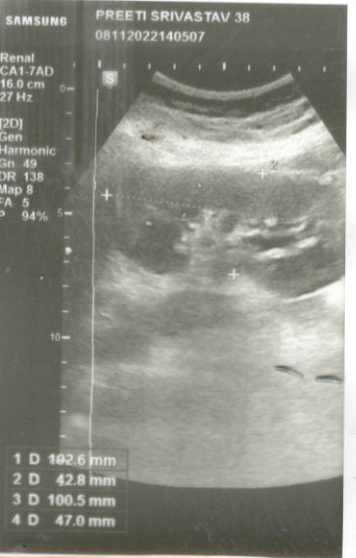
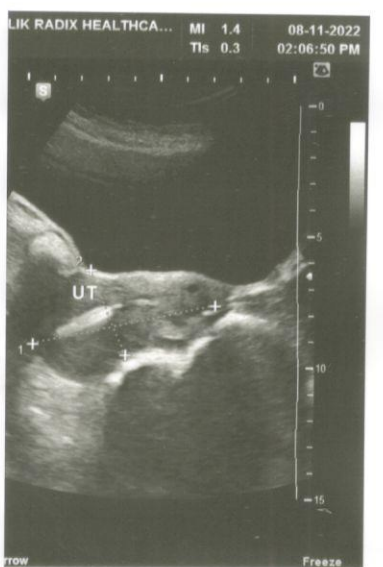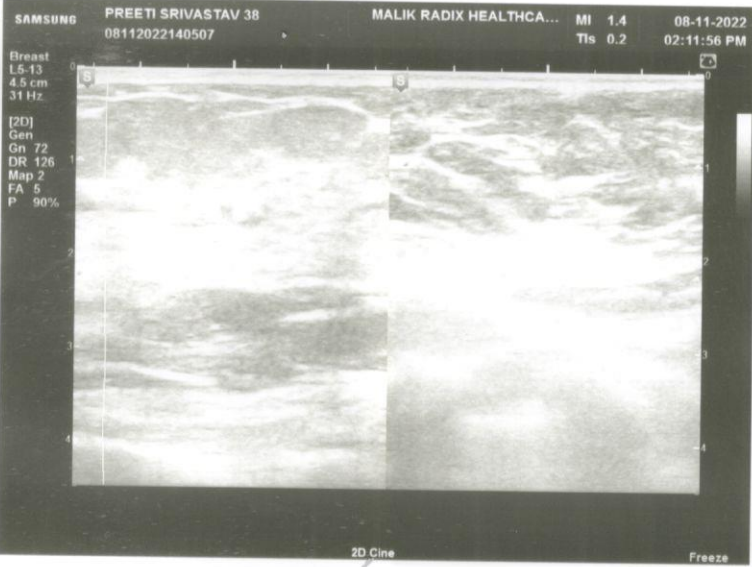
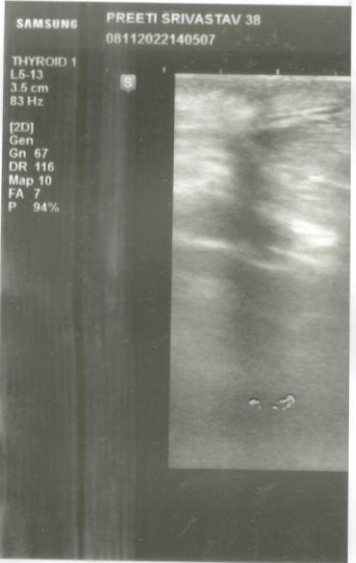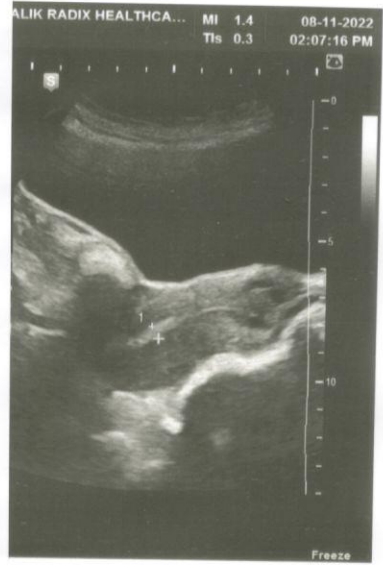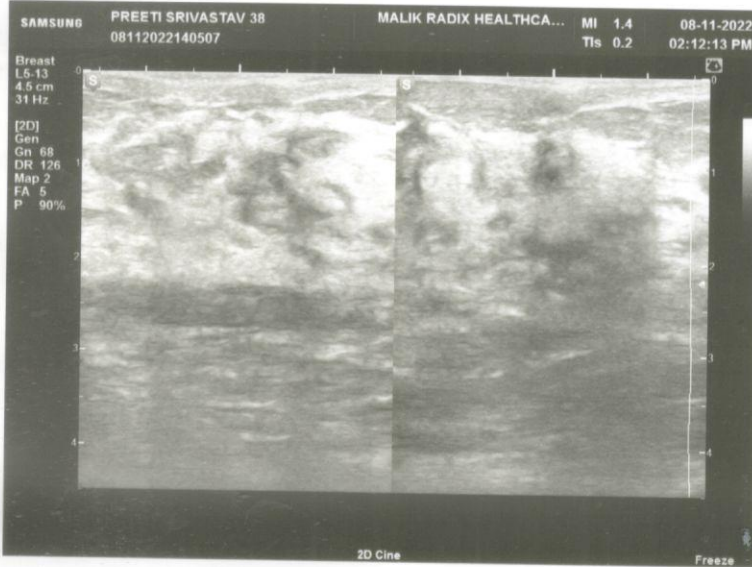
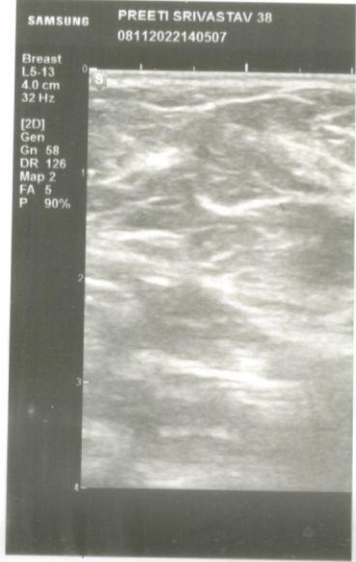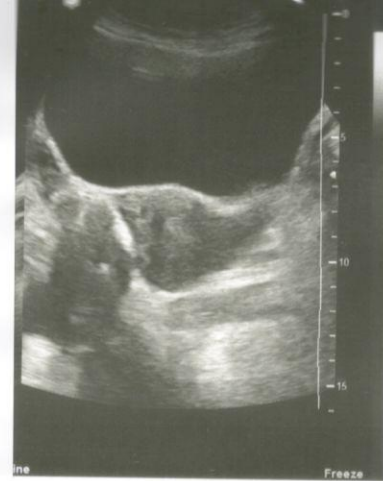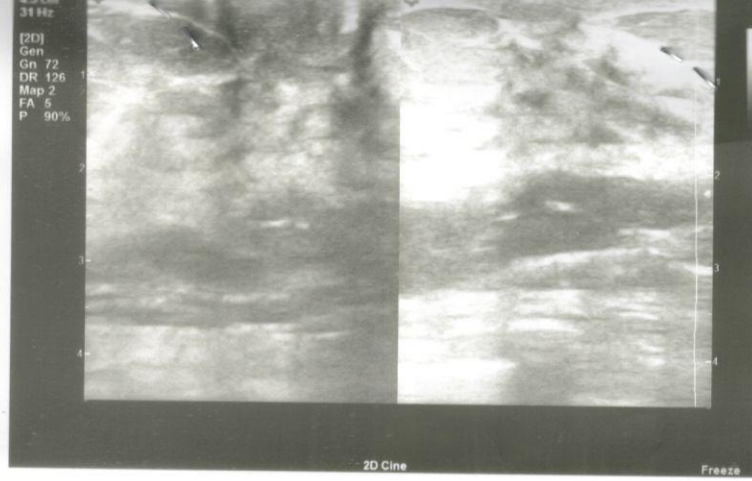
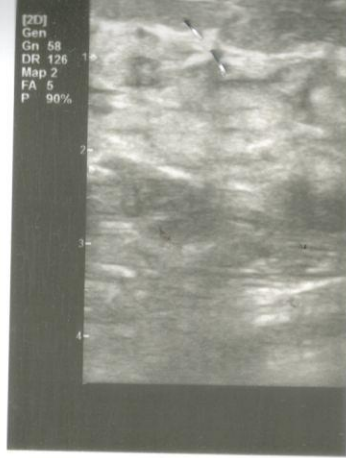DR. MEENU AGGARWAL

M.B.B.S, MD (Path.)

If test results are alarming or unexpected, patient is advised to contact the laboratory immediately for possible remedial action.

Facilities Available

- Multispeciality Hospital - 24 Hours Emergency - X-Ray/ ECG/ Ultrasound/ CT Scan - Dental - Fully Equiped Operation Theatre
- Fully Functional Lab - Casualty/ ICU-Nursery - Labour Room - All Speciality OPD - Laproscopic Surgery - ECHO - Plastic Surgery






MALIK RADIX HEALTH CARE

(UNIT OF MALIK RADIX HEALTHCARE PVT. LTD)
C-217, 218, Nirman Vihar, Vikas Marg, New Delhi - 110092
Tel.: 011-22011192, 22011196, 47060150 • Fax.: 22011208
E-mail : radixhealthcare@yahoo.co.in
Website : www.radixhealthcare.org



UHID	PT173961	LAB No.	ULC2205771
Name	Mrs. PREETI SRIVASTAVA	Regn. No.	GEN2227530
Age / Sex	38 Yrs / F	Receiving Dt/Time	08/Nov/2022 02:09
		Reporting Dt/Time	08/Nov/2022 02:10 PM



U/S BREAST (BOTH)

USG Breast was done with high frequency linear probe.

Both breast parenchyma shows normal echopattern .

No obvious solid or cystic lesion seen.


No calcification/shadowing seen.

No obvious duct dilatation seen.

Retromammary space appears normal.

No significant axillary lymph nodes seen.

IMP— No significant abnormality seen ultrasonographically .


DR. K.K. SINHA
M.B.B.S. D.M.R.D.
SENIOR CONSULTANT
Reg. No. 25437 (DMC)

DR. RAJESH MALHOTRA
MBBS, MD (RADIOLOGY)
CONSULTANT RADIOLOGY
Reg.No.DMC9299

DR. T. K VOHRA
MD (RADIODIAGNOSIS)
SENIOR CONSULTANT
Reg. No. 3272 (DMC)

DR. MUKESH KOSHAL
MBBS, MD (RADIOLOGY)
CONSULTANT RADIOLOGY
Reg.No.DMC10407

Page 1 of 1

RADIOLOGIST :

Facilities Available :

MRHC / GEN / FR / 15

- ★ Multispeciality Hospital ★ 24 Hours Emergency ★ X-Ray/ ECG/ Ultrasound ★ Dental
- ★ Fully Equipped Operation Theatre ★ Fully Functional Lab ★ Casualty/ICU ★ Nursery
- ★ Labour Room ★ All Speciality OPD ★ Laparoscopic Surgery ★ ECHO ★ Plastic Surgery

Home Collection Facility Available Contact : 8587915647

UHID	PT173949	LAB No.	ULC2205768
Name	Mrs. PREETI SRIVASTAVA	Regn. No.	GEN2227513
Age / Sex	38 Yrs / F	Receiving Dt/Time	08/Nov/2022 02:05
		Reporting Dt/Time	08/Nov/2022 02:05 PM



U/S WHOLE ABDOMEN

Liver appears normal in size with normal echogenicity. No focal lesion seen.
CBD & portal vein normal.

Gall bladder is normally distended showing no calculi and cholecystitis.

Wall thickness normal.

Pancreas, para aortic appear normal.

Spleen is normal in size with normal echopattern...

Both kidneys are normal in size shape and echopattern.

No obvious hydronephrosis or stone seen.

Size of right kidney- 102x42mm

Size of left kidney- 100x47mm

Ureters are not dilated.

Urinary bladder is normal.No calculi or mass seen.

Uterus is normal in size shape and echopattern. (Multiload seen in upper uterine cavity)

Uterus size - 69 x 40 x 34 mm

ET -4.7mm

Both ovaries are normal in size .

No evidence of ascites or pleural effusion seen.

No abdominal lymphadenopathy seen.

Nonobstructive umbilical hernia seen .

Imp— Nonobstructive umbilical hernia

DR. K.K. SINHA
M.B.B.S. D.M.R.D.
SENIOR CONSULTANT
Reg. No. 25437 (DMC)

DR. RAJESH MALHOTRA
MBBS, MD (RADIOLOGY)
CONSULTANT RADIOLOGY
Reg.No.DMC9299

DR. T. K VOHRA
MD (RADIODIAGNOSIS)
SENIOR CONSULTANT
Reg. No. 3272 (DMC)

DR. MUKESH KOSHAL
MBBS, MD (RADIOLOGY)
CONSULTANT RADIOLOGY
Reg.No.DMC10407