



Bangalore Diagnostics & Multi-Speciality Centre

Quality Assurance : EQAP from AIIMS & CMC- Vellore

Quality. Trust. Since 1982.

198, 12th Main, 3rd Block, (Above Namma MTR, Next to SBI), Rajajinagar, Bangalore- 560 010.
Ph. : 080-23505407, 9448079978 e-mail : bangalore.d.s@gmail.com

Name : MRS. KOHILA RAJAKUMARAN

Reg. No : C6782

Age/Sex: 50 Year(s) / Female

Date : 15/03/2022

Ref. by : DR. BANK OF BARODA

Corporate: NON CORPORATE

Test Name

Result

Reference Range

Page 1 of 4

HAEMATOLOGY REPORT

COMPLETE BLOOD COUNT

Haemoglobin	8.6 gms %	Male : 13.0 - 18.0 gms % Female: 11.0 - 15.0 gms %
Red Blood Cell Count	3.73 million/cumm	Male : 4.5-6.5 millions/cumm Female : 3.7-5.5 million/cumr

Packed Cell Volume	27.7 %	Females: 32 - 45 % Males: 39 - 54%
Total Count	5,900 cells /cumm	4000-11000 cells /cumm

Differential Count

Neutrophils	49.7 %	40 - 75%
Lymphocytes	43.6 %	20 - 45%
Monocytes	5.2 %	01 - 10%
Eosinophils	1.0 %	01 - 06 %
Basophils	0.5 %	00 to 01 %

COMPLETE BLOOD COUNT

Platelet count	2,96,000 cells/cumm	150000-400000 cells/cumm
Mean Corpuscular Volume	74 fL	78 - 98 fL
Mean Corpuscular Haemoglobin	23.2 pg	27 - 32 pg
Mean Corpuscular Haemoglobin Concentration	31.1 g/dl	31 - 36 g/dl
ESR	08 mm/hour	Male: 0 - 10 mm/ hour Female: 0 - 20 mm/hour

ABSOLUTE EOSINOPHIL COUNT	59 cells/cumm	40 - 440 cells/cumm
---------------------------	---------------	---------------------

BLOOD GROUP(ABO)	"A"
Rh Type (D)	POSITIVE

BIOCHEMISTRY REPORT

FASTING BLOOD SUGAR	76 mg/dl	70 to 100 mg/dl
FASTING URINE SUGAR	NIL	NIL

Dr. MAHADEVA



Bangalore Diagnostics & Multi-Speciality Centre

Quality Assurance : EQAP from AIIMS & CMC- Vellore

Quality. Trust. Since 1982.

198, 12th Main, 3rd Block, (Above Namma MTR, Next to SBI), Rajajinagar, Bangalore- 560 010.

Ph. : 080-23505407, 9448079978 e-mail : bangalore.d.s@gmail.com

Name : MRS. KOHILA RAJAKUMARAN

Reg. No : C6782

Age/Sex: 50 Year(s) / Female

Date : 15/03/2022

Ref. by : DR. BANK OF BARODA

Corporate: NON CORPORATE

Test Name

Result

Reference Range

Page 2 of 4

BIOCHEMISTRY REPORT

POST PRANDIAL BLOOD SUGAR 87 mg/dl 80 to 140 mg/dl

POST PRANDIAL URINE SUGAR NIL NIL

Glycosylated Haemoglobin (HbA1c)

Glycosylated Haemoglobin (HbA1c) 5.2 %

Normal	<6.0 %
Good control	6.0-7.0 %
Fair control	7.0-8.0 %
Unsatisfactory	8.0-10.0 %
Poor control	>10 %

LIPID PROFILE

TOTAL CHOLESTEROL 243.1 mg/dl up to 200 mg/dl

TRIGLYCERIDES 100.1 mg/dl <150 : Normal

HDL Cholesterol 45.3 mg/dl Male: >40 mg/dl
Female: > 50 mg/dl

LDL Cholesterol 177.8 mg/dl <100 mg/dl

VLDL Cholesterol 20.0 mg/dl <40 mg/dl

CHOLESTEROL/HDL RATIO 5.4:1.0 up to 6.0 %

LIVER FUNCTION TESTS

Total Bilirubin 0.42 mg/dl up to 1.2 mg/dl

Direct Bilirubin 0.19 mg/dl 0 to 0.3 mg/dl

Indirect Bilirubin 0.23 mg/dl up to 1.5 mg/dl

S.G.O.T. (AST) 15.4 U/L 0 - 46 U/L

S.G.P.T. (ALT) 24.5 U/L 0 - 49 U/L

ALKALINE PHOSPHATASE 81.7 U/L

Men : 80-306
Women : 64-306
Children upto 15 Yrs : upto 644
Children upto 17 yrs : upto 483

Gamma Glutamyl Transpeptidase (GGT) 16.4 IU/L 0 - 55 IU/L

Total Protein 7.1 gms/dl 6.6 - 8.3 gms/dl

Albumin 4.0 gms/dl 3.4 - 5.0 gms/dl

Globulin 3.1 gms/dl 2.3 - 3.5 gms/dl

Δ/G Ratio 1.3:1.0 1.2 : 1.0



Bangalore Diagnostics & Multi-Speciality Centre

Quality Assurance : EQAP from AIIMS & CMC- Vellore

Quality. Trust. Since 1982.

198, 12th Main, 3rd Block, (Above Namma MTR, Next to SBI), Rajajinagar, Bangalore- 560 010.

Ph. : 080-23505407, 9448079978 e-mail : bangalore.d.s@gmail.com

Name : MRS. KOHILA RAJAKUMARAN

Reg. No : C6782

Age/Sex: 50 Year(s) / Female

Date : 15/03/2022

Ref. by : DR. BANK OF BARODA

Corporate: NON CORPORATE

Test Name

Result

Reference Range

Page 3 of 4

BIOCHEMISTRY REPORT

SERUM CREATININE	1.02 mg/dl	Females 0.6 – 1.2 mg/dl Males 0.7 – 1.4 mg/dl
BLOOD UREA NITROGEN (BUN)	8.78 mg/dl	7-18 mg/dl
URIC ACID	3.44 mg/dl	M: 3.5 -7.2 mg/dl F: 2.6 - 6.0 mg/dl
UREA	18.8 mg/dl	10 to 45 mg/dl

URINE EXAMINATION REPORT

PHYSICAL EXAMINATION

COLOUR	LIGHT YELLOW
APPEARANCE	CLEAR
REACTION	ACIDIC

BIOCHEMICAL EXAMINATION

PROTEIN	NIL	
GLUCOSE	NIL	
BILE SALT	NIL	
BILE PIGMENT	NIL	
SPECIFIC GRAVITY	1.019	1.003 – 1.035

MICROSCOPIC EXAMINATION

PUS CELLS	1-2/HPF
EP CELLS	1-2/HPF
MACROPHAGES	NIL
R.B.C.s	ABSENT
CASTS	NIL

Dr. MAHADEVA. K.G.



Bangalore Diagnostics & Multi-Speciality Centre

Quality Assurance : EQAP from AIIMS & CMC- Vellore

Quality. Trust. Since 1982.

198, 12th Main, 3rd Block, (Above Namma MTR, Next to SBI), Rajajinagar, Bangalore- 560 010.

Ph. : 080-23505407, 9448079978 e-mail : bangalore.d.s@gmail.com

Name : MRS. KOHILA RAJAKUMARAN

Reg. No : C6782

Age/Sex: 50 Year(s) / Female

Date : 15/03/2022

Ref. by : DR. BANK OF BARODA

Corporate: NON CORPORATE

Test Name

Result

Reference Range

Page 4 of 4

URINE EXAMINATION REPORT

MICROSCOPIC EXAMINATION

CRYSTALS

NIL

----- End of Report -----

Biochemist

Microbiologist

Pathologist

Dr. MAHADEVA. K.C.
M.D., (Path)
KMC. No.: 17647



Bangalore Diagnostics & Multi-Speciality Centre

Quality Assurance : EQAP from AIIMS & CMC- Vellore

Quality. Trust. Since 1982.

PROCESSED AT :

Thyrocare

198, 12th Main, 3rd Block, (Above Namma MTR, Next to SBI), Rajajinagar, Bangalore- 560 010.

5CA-711, 3rd Floor,

HRBR 2nd Block,

Hennur, Bengaluru-560043

Ph. : 080-23505407, 9448079978 e-mail : bangalore.d.s@gmail.com

NAME : KOKILA RAJAKUMARAN (50Y/F)

REF. BY : BDL

TEST ASKED : T3-T4-TSH

SAMPLE COLLECTED AT :

(5600101744), BANGLORE DIAGNOSTIC AND
MULTISPECIALITY CENTRE, 198 3RD BLOCK 12TH MAIN
RAJAJINAGAR BANGLORE, 560010

TEST NAME	TECHNOLOGY	VALUE	UNITS	REFERENCE RANGE
TOTAL TRIIODOTHYRONINE (T3)	C.L.I.A	69	ng/dl	60-200
TOTAL THYROXINE (T4)	C.L.I.A	3.4	µg/dl	4.5-12
THYROID STIMULATING HORMONE (TSH)	C.L.I.A	5.20	µIU/ml	0.3-5.5

Comments : IF NOT ON DRUGS SUGGESTED FT3 & FT4 ESTIMATION

Please correlate with clinical conditions.

Method :

T3 - Competitive Chemi Luminescent Immuno Assay

T4 - Competitive Chemi Luminescent Immuno Assay

TSH - SANDWICH CHEMI LUMINESCENT IMMUNO ASSAY

Pregnancy reference ranges for TSH

1st Trimester : 0.10 - 2.50

2nd Trimester : 0.20 - 3.00

3rd Trimester : 0.30 - 3.00

Reference:

Guidelines of American Thyroid Association for the Diagnosis and Management of Thyroid Disease During Pregnancy and Postpartum, Thyroid, 2011, 21; 1-46

~~ End of report ~~

Sample Collected on (SCT) : 15 Mar 2022 08:50

Sample Received on (SRT) : 15 Mar 2022 13:29

Report Released on (RRT) : 15 Mar 2022 15:24

Sample Type : SERUM

Labcode : 1503075157/BAN03

Barcode : X4083109



Dr. Prachi Sinkar MD(Path)

Dr. Caesar Sengupta MD(Micro)

Page : 1 of 1



Bangalore Diagnostics & Multi-Speciality Centre

Quality Assurance : EQAP from AIIMS & CMC- Vellore

Quality. Trust. Since 1982.

198, 12th Main, 3rd Block, (Above Namma MTR, Next to SBI), Rajajinagar, Bangalore- 560 010.

Ph. : 080-23505407, 9448079978 e-mail : bangalore.d.s@gmail.com

NAME : MRS. KOHILA RAJKUMARAN DATE: 16.03.2022

REF BY : B.O.B

AGE/ GENDER: 50 YEARS/FEMALE

ABDOMEN AND PELVIC ULTRA SOUND SCAN REPORT

Liver : Normal in size, shape and echotexture. No focal lesion seen.

No intrahepatic biliary dilatation seen. PV & CBD is normal

Gall Bladder: GB is normal. Normal in wall thickness. No abnormal intraluminal echoes.

Pancreas : Normal in size and echo texture. No focal lesion, Pancreatic duct appears normal.

Spleen : Normal in size, shape and echo texture

Kidneys : Both kidneys are normal in size, shape and position.

No calculi / hydronephrosis seen. Cortico medullary differentiation is good.

Right Kidney: 111 x 17 mm Left kidney : 115 x 16mm

Urinary Bladder: Normal in contour and wall thickness with clear contents.

Uterus : Anteverted, **Measures 103 x 45 x 44 mm, bulky in size**, normal in shape and echotexture. Endometrial thickness = 6.4 mm. POD is empty.

Ovaries : Both ovaries are visualized in adnexa.

Right ovary – 43 x 19 mm, bulky in size. Left ovary - 28 x 19mm, appears normal.

IMPRESSION:

- **Bulky uterus and right ovary.**


SONOLOGIST

**BANGALORE DIAGNOSTICS &
MULTI-SPECIALITY CENTRE**
198, 12th Main, 3rd Block
Rajajinagar, Bangalore-560 010

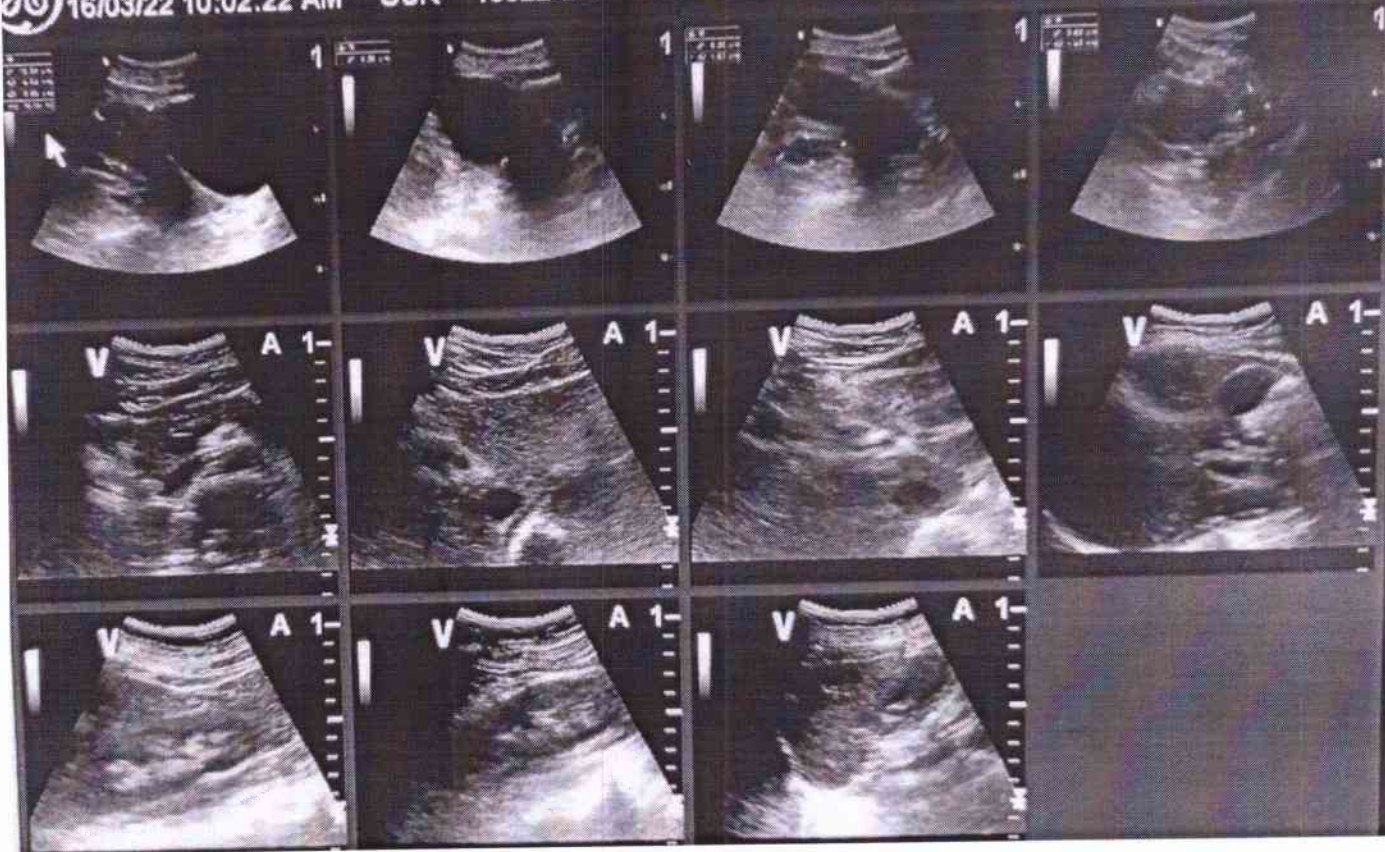

GE Healthcare
16/03/22 10:02:22 AM

USR 16322-2B

KOHILA RAJKUMARAN 50 Y,

MI 0.9 TIs 0.1 4C-RS
Abdomen



**BANGALORE DIAGNOSTICS &
MULTI-SPECIALITY CENTRE**
198, 12th Main, 3rd Block
Rajajinagar, Bangalore-560 010



Bangalore Diagnostics & Multi-Speciality Centre

Quality Assurance : EQAP from AIIMS & CMC- Vellore

Quality. Trust. Since 1982.

198, 12th Main, 3rd Block, (Above Namma MTR, Next to SBI), Rajajinagar, Bangalore- 560 010.
Ph. : 080-23505407, 9448079978 e-mail : bangalore.d.s@gmail.com

Echocardiography Report

NAME : MRS. KOHILA RAJKUMARAN

DATE: 16.03.2022

REF BY : B.O.B

AGE/ GENDER: 50 YEARS/FEMALE

LA : 33 mm

MV : E 0.83 A : 0.70 m/sec

AO : 25 mm

AV : 1.00 m/sec

RVID : 18 mm

TV : 0.43 m/sec

LVIDD : 44mm

PV : 0.66 m/sec

LVIDS : 30 mm

IVSD : 10 mm

MR : NIL

IVSS : 15mm

AR : NIL

LVPWD: 10mm

TR : NIL

LVPWS : 16 mm

PR : NIL

FS : 31%

EF : 60%

LV mass: 164 gm

IMPRESSION

- NORMAL CHAMBER DIMENSIONS.
- NO RWMA.
- NORMAL LV SYSTOLIC FUNCTION. LVEF 60%
- NORMAL VALVES.
- NORMAL COLOR FLOW AND SPECTRAL DOPPLER STUDY.
- NO THROMBUS / PE


CONSULTANT CARDIOLOGIST

**BANGALORE DIAGNOSTICS &
MULTI-SPECIALITY CENTRE**

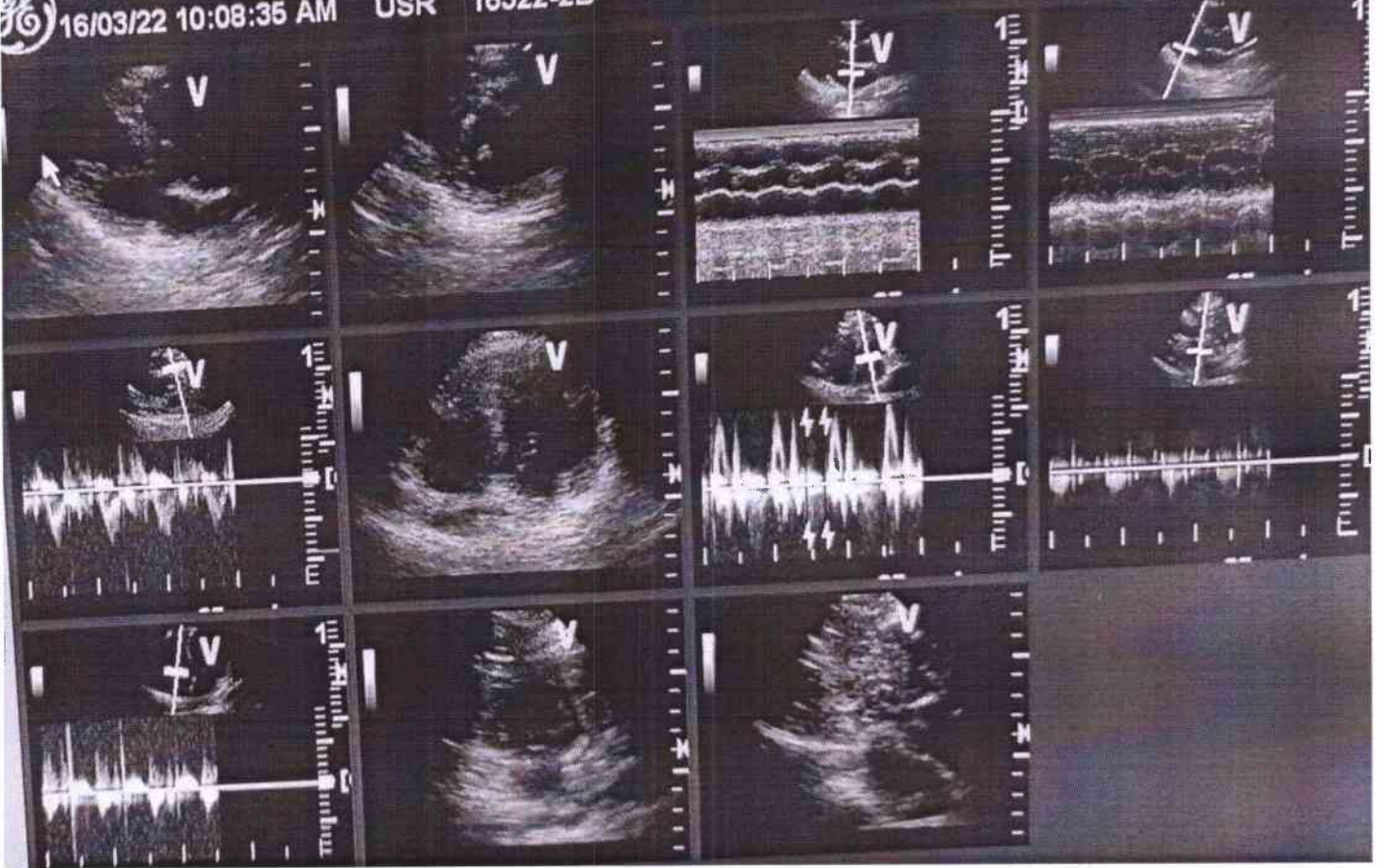


GE Healthcare
16/03/22 10:08:35 AM

USR

KOHILA RAJKUMARAN 50 Y,
16322-2B

MI 1.1 TIs 0.4 3S-RS
Cardiac1



**BANGALORE DIAGNOSTICS &
MULTI-SPECIALITY CENTRE**
198, 12th Main, 3rd Block
Rajajinagar, Bangalore-560 010



Bangalore Diagnostics & Multi-Speciality Centre

Quality Assurance : EQAP from AIIMS & CMC- Vellore

Quality. Trust. Since 1982.

198, 12th Main, 3rd Block, (Above Namma MTR, Next to SBI), Rajajinagar, Bangalore- 560 010.
Ph. : 080-23505407, 9448079978 e-mail : bangalore.d.s@gmail.com

NAME : MRS. KOHILA RAJKUMARAN

DATE: 16.03.2022

REF BY : B.O.B

AGE/ GENDER: 50 YEARS/FEMALE

BREAST ULTRA SOUND SCAN REPORT

Right breast glandular soft tissue echo texture appeared within normal limits.

Left breast glandular soft tissue echo texture appeared within normal limits.

There is no evidence of Solid/ Cystic foci's In all IV Quadrant's

No ductal dilatations seen.

Axillary regions appeared normal; no evidence of enlarged lymphnodes.

IMPRESSION:

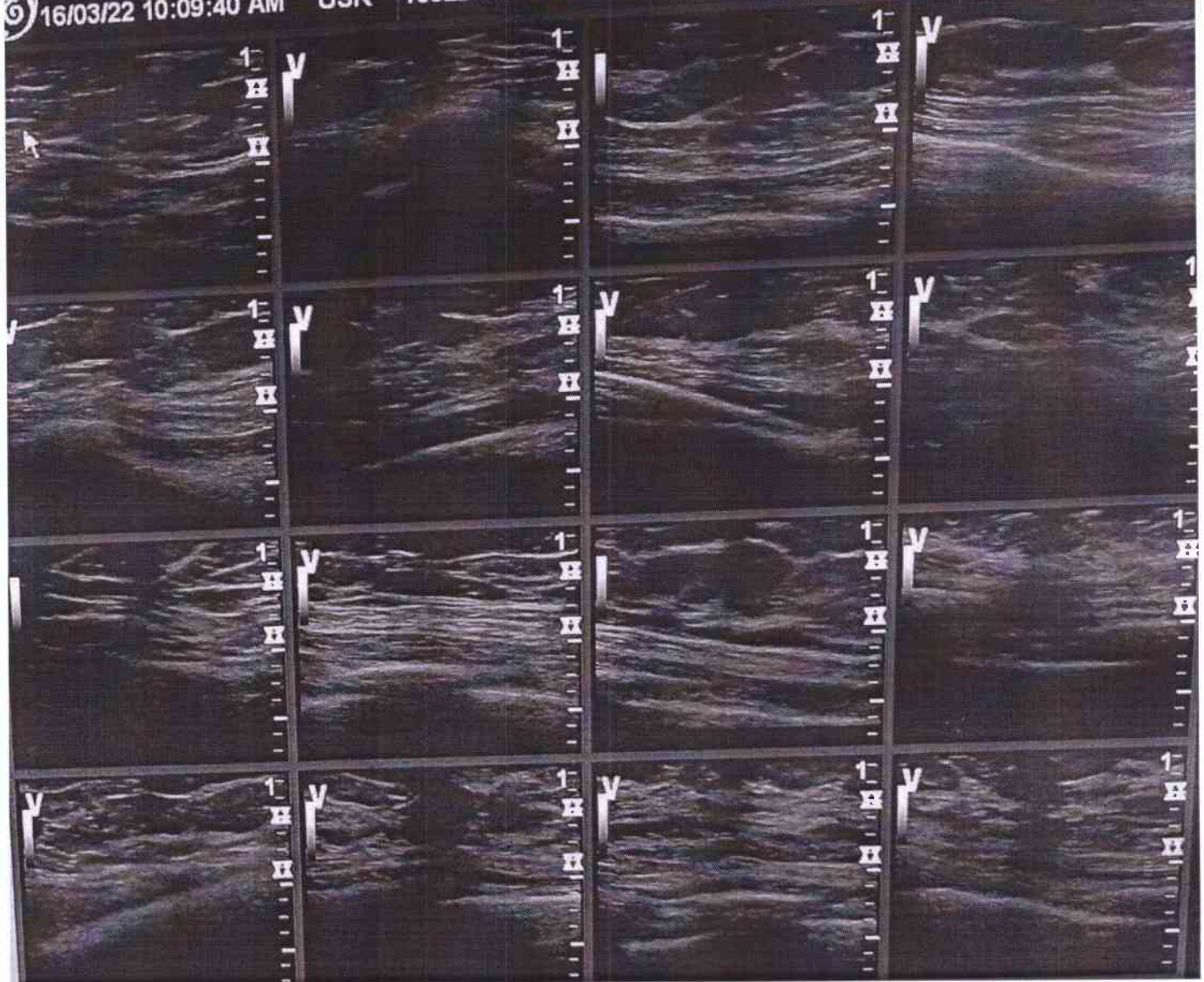
NORMAL SONOLOGIC STUDY.

BIRADS SCORE - I (Suggest routine screening)


SONOLOGIST.

GE Healthcare
16/03/22 10:09:40 AM USR

KOHILA RAJKUMARAN 50 Y,
16322-2B





Bangalore Diagnostics & Multi-Speciality Centre

Quality Assurance : EQAP from AIIMS & CMC- Vellore

Quality. Trust. Since 1982.

198, 12th Main, 3rd Block, (Above Namma MTR, Next to SBI), Rajajinagar, Bangalore- 560 010.
Ph. : 080-23505407, 9448079978 e-mail : bangalore.d.s@gmail.com

Patient Name	MRS.KOHILA RAJAKUMARAN	Patient Id	X-RAY-46
Age/DOB	50/	Gender	F
Ref.Doctor	BANK OF BARODA	Date	15/03/2022

X-RAY CHEST PA VIEW

OBSERVATION:

Both hila are normal.

Cardiophrenic and costophrenic angles are normal.

The trachea is central.

The mediastinal and cardiac silhouette are normal.

Cardiothoracic ratio is normal.

Bones of the thoracic cage are normal.

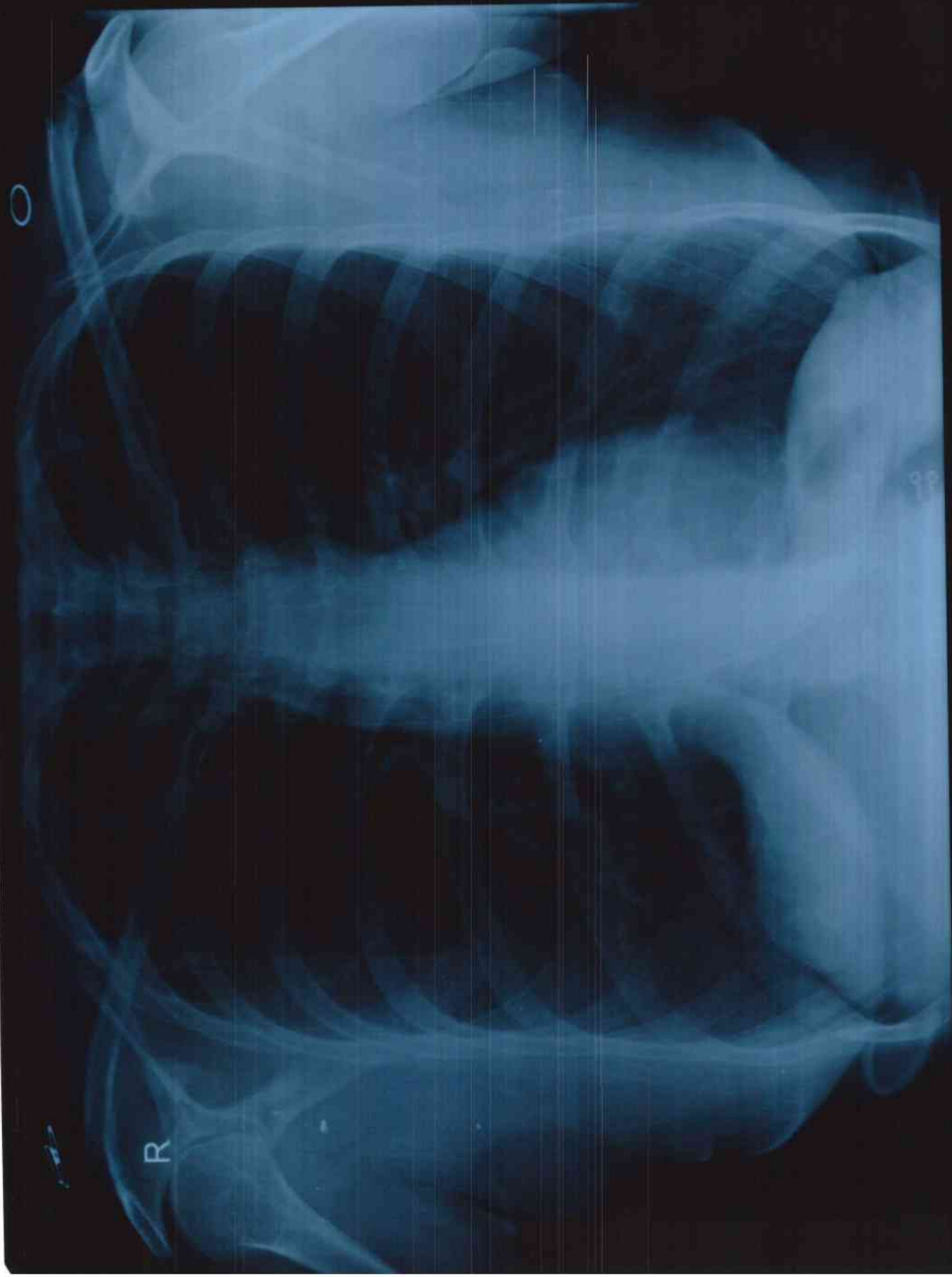
Soft tissues of the chest wall are normal.

IMPRESSION:

NORMAL STUDY

Dr. Vijay Kumar
MBBS, MDRD
Consultant Radiologist

**BANGALORE DIAGNOSTICS &
MULTI-SPECIALITY CENTRE**
198, 12th Main, 3rd Block
Rajajinagar, Bangalore-560 010



CSZ-46 MRS kohila raja kumaran 50 F 15/03/2022 10:05:14
BANGALORE DIAGNOSTIC SERVICE RAJAJINAGARA -BANGALORE-560010



Bangalore Diagnostics & Multi-Speciality Centre

Quality Assurance : EQAP from AIIMS & CMC- Vellore

Quality. Trust. Since 1982.

198, 12th Main, 3rd Block, (Above Namma MTR, Next to SBI), Rajajinagar, Bangalore- 560 010.
Ph. : 080-23505407, 9448079978 e-mail : bangalore.d.s@gmail.com

ELECTROCARDIOGRAM

NAME/AGE : mess. Kohilar Rajakumarian

Lab No.: Bank of Baroda

DATE: 15/03/20

ECG FINDINGS

Standardization	<u>un</u>	Rate	<u>76b</u>
Rhythm	<u>sin</u>	Axis	<u>N</u>
P Wave	<u>N</u>	PR Interval	<u>0.14sec</u>
Q Wave	<u>N</u>	QRS Voltage	<u>SV + AVR 1.0m</u>
QRS Duration	<u>0.09sec</u>	ST Segment	<u>T A Electro</u>
QT interval	<u>0.41sec</u>		
U Wave		T Wave	<u>N</u>
Recommendations			
<u>Normal</u>			

**BANGALORE DIAGNOSTICS &
MULTI-SPECIALITY CENTRE**
198, 12th Main, 3rd Block
Rajajinagar, Bangalore-560 010

Dr. Ashok

Dr. ASHOK
MD (Internal Medicine)
Reg No 13444

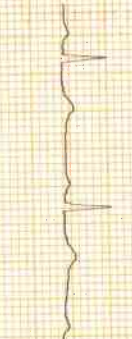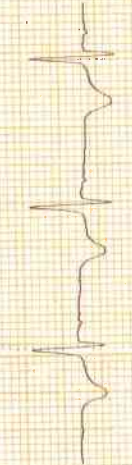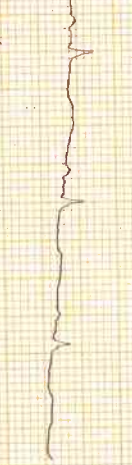
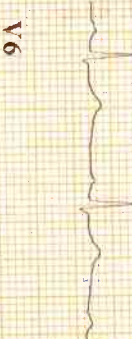
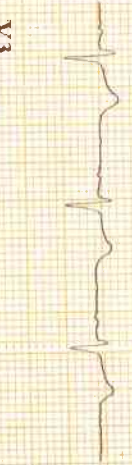
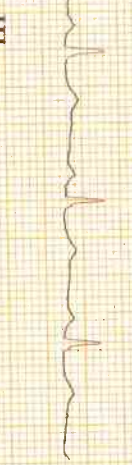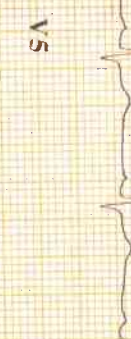
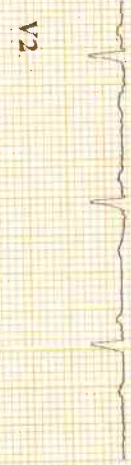

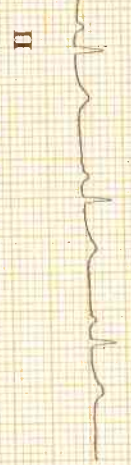10mm/mV 0.15~35Hz ACS0

2022-03-15 12:52:04
aVR

V1

V4

C - Kohda, R



25mm/s

V2.47

CARDIART

ID : 220315-1252

Minnesota Code:

Name :
Age : 50 yr
Sex : Female
BP :
Height : cm
Weight : kg

HR : 76 bpm
P Dur : 92 ms
PR int : 142 ms
QRS Dur : 94 ms
QT/QTc int : 365/411 ms
P/QRS/T axis : 51/50/13 °
RV5/SV1 amp : 0.661/0.440 mV
RV6/SV2 amp : 1.101 mV
RV6/SV2 amp : 0.626/0.424 mV

Diagnosis Information:
800: Sinus Rhythm
Normal ECG

Report Confirmed by: