

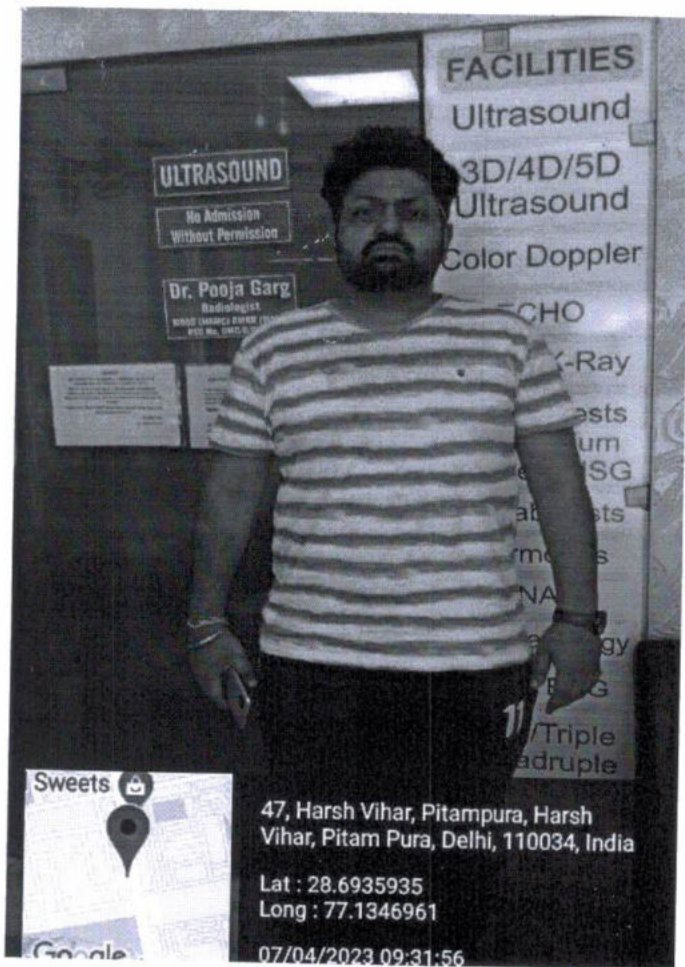


Dr. NITIN AGARWAL  
MBBS, MD  
Regn. No. DMC-R-1436


*[Handwritten signature]*



CNEPLUS ULTRASOUND LAB  
47, Harsh Vihar, Pitam Pura,  
Delhi-110034  
Ph. 011-42480101, 9599913051  
E-mail: oneplusul@gmail.com



  
Dr. NITIN AGARWAL  
MBBS, MD  
Regn. No. DMC-R-1436



ONEPLUS ULTRASOUND LAB  
47, Harsh Vihar, Pitam Pura,  
Delhi-110034  
Ph. 011-42480101, 9599913051  
E-mail: oneplusul@gmail.com

Dear Sir/Madam

I hereby want to state that  
I do not wish to submit for stool  
test.

This is for your information.



Dr. NITIN AGARWAL  
MBBS, MD  
Regn. No. DMC-R-1436









# OnePLUS

## Ultrasound Lab

— QUALITY FIRST... ALWAYS! —

**Dr. Nitin Agarwal**  
Pathologist & Director  
Ex. Sr. Res. MAMC  
& Lok Nayak Hospital  
Ex. Chief of Lab Dr. Lal Path Labs.

**Dr. Pooja (Garg) Agarwal**  
Radiologist & Director  
MAMC & Lok Nayak Hospital



NAME	:Mr. VINEET GOEL	Barcode No	:10141906
AGE/GENDER	:35 YRS/Male	SPECIMEN DATE	:07/Apr/2023 08:54AM
PATIENT ID	:112131	SPECIMEN RECEIVED	:07/Apr/2023 09:18AM
REFERRED BY	:Dr. MEDIWHEEL	REPORT DATE	:07/Apr/2023 02:10PM
CENTRE NAME	:ONEPLUS ULTRASOUND LAB	LAB NO.	:012304070007

Test Name	Result	Unit	Ref. Range
-----------	--------	------	------------

### HAEMATOLOGY

#### Medi Wheel Health checkup < 40 Male

<b>Glycosylated Hemoglobin (HbA1c)</b>	5.2	%	Non Diabetic adults <5.7 Prediabetic (at risk) 5.7-6.4 Diabetes >6.4
--	-----	---	--

<b>Estimated average blood glucose (eag)</b>	103
--	-----

Reference range (mg/dl):

90 - 120:Excellent control, 121 - 150:Good Control, 151 - 180:Average Control, 181 - 210:Action Suggested

>211:Panic value

<b>BLOOD GROUP (ABO)</b>	A
<b>Rh typing</b>	POSITIVE

#### NOTE :

- \* Apart from major A,B,H antigens which are used for ABO grouping and Rh typing, many minor blood group antigens exist. Agglutination may also vary according to titre of antigen and antibody.
- \* So before transfusion, reconfirmation of blood group as well as cross-matching is needed.
- \* Presence of maternal antibodies in newborns, may interfere with blood grouping.
- \* Auto agglutination (due to cold antibody, falciparum malaria, sepsis, internal malignancy etc.) may also cause erroneous result.

#### CBC

Haemoglobin	15.8	g/dl	13.0-17.0
Total Leucocyte Count	7000	/cumm	4000-10000
<b>Differential leucocyte count</b>			
Neutrophils	60.3	%	40-80
Lymphocyte	32.30	%	20-40
Monocytes	5.00	%	2-10
Eosinophils	2.0	%	1-6
Basophils	0.4	%	0-2
RBC Count	5.60	million/cumm	4.5 - 5.5

Checked By.

Dr. NITIN AGARWAL  
MBBS, MD (P&I)  
DMC/R/01436  
DR. NITIN AGARWAL  
MBBS, MD (PATHOLOGIST)

47, Harsh Vihar, Pitampura, New Delhi-110034 | Ph.: 011-42480101, 9599913051  
E-mail: oneplusul@gmail.com | Web.: www.oneplusul.in

Page 1 of 5



# OnePLUS Ultrasound Lab

— QUALITY FIRST... ALWAYS! —

**Dr. Nitin Agarwal**  
Pathologist & Director  
Ex. Sr. Res. MAMC  
& Lok Nayak Hospital  
Ex. Chief of Lab Dr. Lal Path Labs.

**Dr. Pooja (Garg) Agarwal**  
Radiologist & Director  
MAMC & Lok Nayak Hospital



NAME	:Mr. VINEET GOEL	Barcode No	:10141906
AGE/GENDER	:35 YRS/Male	SPECIMEN DATE	:07/Apr/2023 08:54AM
PATIENT ID	:112131	SPECIMEN RECEIVED	:07/Apr/2023 09:18AM
REFERRED BY	:Dr. MEDIWHEEL	REPORT DATE	:07/Apr/2023 02:10PM
CENTRE NAME	:ONEPLUS ULTRASOUND LAB	LAB NO.	:012304070007

Test Name	Result	Unit	Ref. Range
PCV(Hematocrit)	50.7	%	40-50
MCV	90.9	fL	83-101
MCH	28.3	Pg	27-32
MCHC	31.2	G/dL	32-35
RDW-CV	13.8	%	11.4-14.0
Platelet count	263000	/cumm	150000-450000

### BIOCHEMISTRY

<b>Blood sugar fasting</b>	102	mg/dL	70-110
<b>Bun (blood urea nitrogen )</b>	12.50	mg/dl	8.9-21.6
<b>Uric acid, serum</b>	4.6	mg/dl	3.5-7.2
<b>Creatinine, serum</b>	0.7	mg/dl	0.60-1.2

### LFT(LIVER FUNCTION TEST)

Bilirubin Total	0.54	mg/dl	0.1-1.2
Bilirubin Conjugated	0.23	mg/dl	0-0.4
Bilirubin Unconjugated	0.31	mg/dl	up to 0.7
SGOT (AST)	33	U/L	0-46
SGPT (ALT)	32	U/L	0-49
Alkaline phosphatase	94	U/L	40-129
Gamma glutamyl transpeptidase	26	U/L	10-45
Total Protein	7.8	gm/dl	6.60 - 8.70
Albumin serum	4.2	g/dL	3.0-5.2
Globulin	3.60	gm/dl	1.8-3.4
Albumin/Globulin Ratio	1.17		1.10 - 2.50

### LIPID PROFILE

Cholesterol	143	mg/dl	50-200
Triglycerides	55	mg/dL	25-150
HDL Cholesterol	45	mg/dL	40 - 60
LDL cholesterol	87	mg/dL	<130

Checked By.

Dr. NITIN AGARWAL  
MBBS, MD  
SCIR/01436  
DR. NITIN AGARWAL  
MBBS, MD (PATHOLOGIST)

47, Harsh Vihar, Pitampura, New Delhi-110034 | Ph.: 011-42480101, 9599913051  
E-mail: oneplusul@gmail.com | Web.: www.oneplusul.in

Page 2 of 5

Clinical correlation is essential for final diagnosis. \* If test results are unsatisfactory please contact personally or on phone. \* This report is for perusal of doctors only.  
\* All disputes Subject to Delhi Jurisdiction only. \* Not for medicolegal purposes. \* All congenital anomalies in a foetus may not be diagnosed in routine obstetric ultrasound.





# OnePLUS Ultrasound Lab

— QUALITY FIRST... ALWAYS! —

**Dr. Nitin Agarwal**  
Pathologist & Director  
Ex. Sr. Res. MAMC  
& Lok Nayak Hospital  
Ex. Chief of Lab Dr. Lal Path Labs.

**Dr. Pooja (Garg) Agarwal**  
Radiologist & Director  
MAMC & Lok Nayak Hospital



NAME	:Mr. VINEET GOEL	Barcode No	:10141906
AGE/GENDER	:35 YRS/Male	SPECIMEN DATE	:07/Apr/2023 08:54AM
PATIENT ID	:112131	SPECIMEN RECEIVED	:07/Apr/2023 09:18AM
REFERRED BY	:Dr. MEDIWHEEL	REPORT DATE	:07/Apr/2023 02:10PM
CENTRE NAME	:ONEPLUS ULTRASOUND LAB	LAB NO.	:012304070007

Test Name	Result	Unit	Ref. Range
VLDL cholesterol	11.0	mg/dL	5-40
Cholesterol/HDL Ratio	3.2		Low Risk 3.3-4.97 Average Risk 4.4-7.1 Moderate Risk 7.1-11.0 High Risk >11.0
LDL/HDL Ratio	1.9		0 - 3.55

According to ATP III and NCEP guidelines

Parameter	Normal	Desirable	Borderline	High
Total cholesterol	<200		200-239	240
Triglycerides	<150	150-199	200-499	500
LDL	Optimal <100 Near Optimal 100-129	130-159	160-180	190
HDL	<40 : LOW 60 : HIGH			

### BUN/Creatinine ratio

Bun (blood urea nitrogen )	12.50	mg/dl	8.9-21.6
CREATININE	0.70	mg/dl	0.30-1.10
BUN/Creatinine ratio	17.86		10.0 - 20.0

### ENDOCRINOLOGY

#### THYROID PROFILE(T3,T4,TSH)

Triiodothyronine total [t3]	0.85	ng/dl	0.52-1.9
Thyroxine total [t4]	7.60	µg/dl	4.4 - 10.8
TSH (Thyroid Stimulating Hormone)	1.91	µIU/ml	0.25-5.0

#### AGE WISE VARIATION IN TSH

AGE	TSH(µIU/ml)	AGE	TSH(µIU/ml)
1-4 weeks	1.00 - 19.0	16-20 yrs	0.25 - 5.0

Checked By.

Dr. NITIN AGARWAL  
M.B.B.S. (MBBS)  
DR. NITIN AGARWAL  
MBBS,MD(PATHOLOGIST)

47, Harsh Vihar, Pitampura, New Delhi-110034 | Ph.: 011-42480101, 9599913051

E-mail: [oneplusul@gmail.com](mailto:oneplusul@gmail.com) | Web.: [www.oneplusul.in](http://www.oneplusul.in)

Page 3 of 5

Clinical correlation is essential for final diagnosis. \* If test results are unsatisfactory please contact personally or on phone. \* This report is for perusal of doctors only. \* All disputes Subject to Delhi Jurisdiction only. \* Not for medicolegal purposes. \* All congenital anomalies in a foetus may not be diagnosed in routine obstetric ultrasound.



# OnePLUS

## Ultrasound Lab

— QUALITY FIRST... ALWAYS! —

**Dr. Nitin Agarwal**  
Pathologist & Director  
Ex. Sr. Res. MAMC  
& Lok Nayak Hospital  
Ex. Chief of Lab Dr. Lal Path Labs.

**Dr. Pooja (Garg) Agarwal**  
Radiologist & Director  
MAMC & Lok Nayak Hospital



NAME	:Mr. VINEET GOEL	Barcode No	:10141906
AGE/GENDER	:35 YRS/Male	SPECIMEN DATE	:07/Apr/2023 08:54AM
PATIENT ID	:112131	SPECIMEN RECEIVED	:07/Apr/2023 09:18AM
REFERRED BY	:Dr. MEDIWHEEL	REPORT DATE	:07/Apr/2023 02:10PM
CENTRE NAME	:ONEPLUS ULTRASOUND LAB	LAB NO.	:012304070007

Test Name	Result	Unit	Ref. Range
1-12 mths	1.70 - 9.1	21 - 80 yrs	0.25 - 5.0
1-5 yrs	0.80 - 8.2	I <sup>st</sup> trimester	0.25 - 5.0
6-10 yrs	0.25 - 5.0	II <sup>nd</sup> trimester	0.50 - 5.0
11-15 yrs	0.25 - 5.0	II <sup>rd</sup> trimester	0.4 - 6.0

**Reference ranges - Interpretation of Diagnostic tests - (Jacques Wallach)**

1. Primary hypothyroidism is accompanied by depressed serum T3 and T4 values and elevated serum TSH level.
2. Primary hyperthyroidism is accompanied by elevated serum T3 and T4 levels along with depressed TSH values.
3. Slightly elevated T3 levels may be found in pregnancy and estrogen therapy, while depressed levels may be encountered in severe illness, renal failure and during therapy with drugs like propranolol and propyl thiouracil.
4. Although elevated TSH levels are nearly always indicative of primary hypothyroidism, and may be seen in secondary thyrotoxicosis

### CLINICAL PATHOLOGY

#### URINE ROUTINE

**Physical examination**

Quantity	30	ML
Colour	PALE YELLOW	
Transparency	CLEAR	CLEAR
Sp.gravity	1.015	1.010-1.030
pH	6.00	
Reaction	ACIDIC	ACIDIC

**Chemical examination**

Urine protein	NIL	NIL
Urine sugar	NIL	NIL
Bilirubin, urine	NEGATIVE	NEGATIVE
Urobilinogen	NORMAL	NORMAL
Ketones	NEGATIVE	NEGATIVE

**Microscopic examination**

<b>Pus cells.</b>	2-3	/HPF	0-2
Epithelial cells	1-2	/HPF	NIL

Checked By.

Dr. NITIN AGARWAL  
MBBS, MD (Pathology)  
DMC/R/01436  
DR. NITIN AGARWAL  
MBBS, MD (PATHOLOGIST)

47, Harsh Vihar, Pitampura, New Delhi-110034 | Ph.: 011-42480101, 9599913051

E-mail: [oneplusul@gmail.com](mailto:oneplusul@gmail.com) | Web.: [www.oneplusul.in](http://www.oneplusul.in)

Page 4 of 5



# OnePLUS Ultrasound Lab

— QUALITY FIRST... ALWAYS! —

**Dr. Nitin Agarwal**

Pathologist & Director  
Ex. Sr. Res. MAMC  
& Lok Nayak Hospital  
Ex. Chief of Lab Dr. Lal Path Labs.

**Dr. Pooja (Garg) Agarwal**

Radiologist & Director  
MAMC & Lok Nayak Hospital



NAME	:Mr. VINEET GOEL	Barcode No	:10141906
AGE/GENDER	:35 YRS/Male	SPECIMEN DATE	:07/Apr/2023 08:54AM
PATIENT ID	:112131	SPECIMEN RECEIVED	:07/Apr/2023 09:18AM
REFERRED BY	:Dr. MEDIWHEEL	REPORT DATE	:07/Apr/2023 02:10PM
CENTRE NAME	:ONEPLUS ULTRASOUND LAB	LAB NO.	:012304070007

Test Name	Result	Unit	Ref. Range
R.B.C.	NIL	/HPF	NIL
Casts	NIL	/HPF	NIL
Crystals	NIL	/HPF	NIL
Bacteria	NIL	/HPF	NIL
Others.	NIL	NIL	NIL

\*\*\* End Of Report \*\*\*

Checked By.

Dr NITIN AGARWAL  
MBBS, MD (Path)  
DMC/R/0143  
DR. NITIN AGARWAL  
MBBS,MD(PATHOLOGIST)

47, Harsh Vihar, Pitampura, New Delhi-110034 | Ph.: 011-42480101, 9599913051

E-mail: [oneplusul@gmail.com](mailto:oneplusul@gmail.com) | Web.: [www.oneplusul.in](http://www.oneplusul.in)

Page 5 of 5

Clinical correlation is essential for final diagnosis. • If test results are unsatisfactory please contact personally or on phone. • This report is for perusal of doctors only.  
• All disputes Subject to Delhi Jurisdiction only. • Not for medicolegal purposes. • All congenital anomalies in a foetus may not be diagnosed in routine obstetric ultrasound.



# ONEPLUS ULTRASOUND LAB

Mr. VINEET GOEL  
I.D. : 999  
AGE/SEX : 35/M  
RECORDED : 7-4-2023 9:32

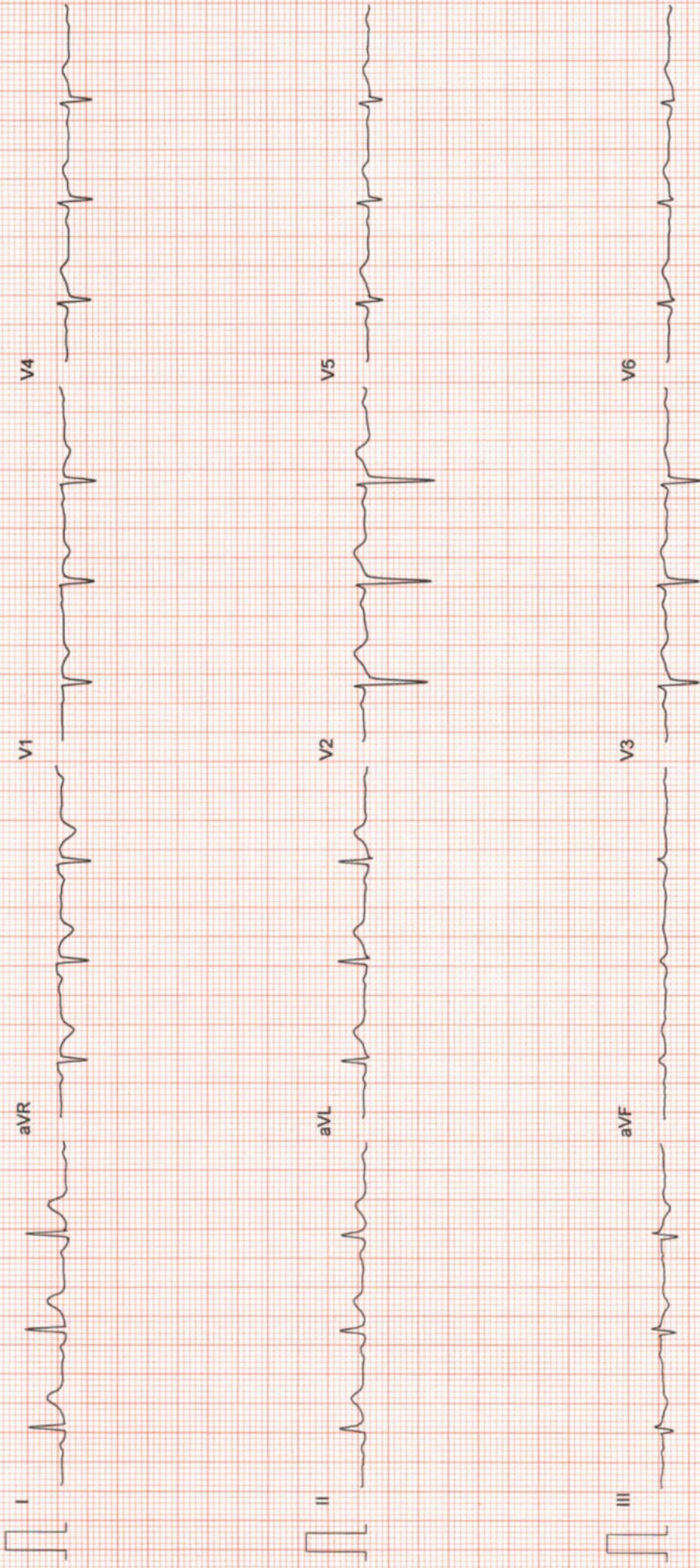
RATE : 91 BPM  
B.P. : 120/84 mmHg

SUPINE  
PRETEST

ST @ 10mm/mV  
80ms PostJ

RAW E.C.G.

**Dr. P.K. GUPTA**  
MBBS, MD  
Reg. No-1071



**ONEPLUS ULTRASOUND LAB**  
47, Harsh Vihar, Pitam Pura,  
Delhi-110034  
Ph. 011-42480101, 9599913051  
E-mail: [oneplusul@gmail.com](mailto:oneplusul@gmail.com)



# ONEPLUS ULTRASOUND LAB

47, HARSH VIHAR PITAMPURA DELHI 110034

Mr. VINEET GOEL

Age/Sex : 35/M  
 Ref. by : MEDIWHEEL  
 Indication1 :  
 Indication2 :  
 Indication3 :

ID : 995

H/Wt : 174/101  
 Recorded : 7-4-2023 9:40

## TREADMILL TEST SUMMARY REPORT

Protocol: BRUCE

History:

Medication1 :

Medication2 :

Medication3 :

PHASE	PHASE TIME	STAGE TIME	SPEED (Km./Hr.)	GRADE (%)	H.R. (BPM)	B.P. (mmHg)	RPP X100	II	ST LEVEL (mm) V2	V5	METS
SUPINE STANDING					85 88	120/84 120/84	102 105	0.5 0.4	1.0 1.1	0.5 0.3	
STAGE 1	2:59	2:59	2.70	10.00	107	132/86	141	0.4	1.2	0.6	4.80
STAGE 2	5:59	2:59	4.00	12.00	125	142/88	177	0.8	1.6	0.7	7.10
STAGE 3	8:59	2:59	5.40	14.00	145	154/90	223	0.6	2.4	1.3	10.00
STAGE 4	9:59	0:59	6.70	16.00	160	166/92	265	0.4	2.4	1.2	11.32
PEAK EXER	10:00	1:00			160	166/92	265	0.4	2.5	1.2	11.34
RECOVERY	2:59	2:59	0:00	0.00	136	126/84	171	0.6	1.2	0.6	

### RESULTS

Exercise Duration : 10:00 Minutes  
 Max Heart Rate : 160 bpm 86 % of target heart rate 185 bpm  
 Max Blood Pressure : 166/92 mmHg  
 Max Work Load : 11.34 METS

*Negative for ischemia also*

### IMPRESSIONS

ONEPLUS ULTRASOUND LAB  
 47, Harsh Vihar, Pitam Pura,  
 Delhi-110034  
 Ph. 011-42480101, 9599913051  
 E-mail: oneplusul@gmail.com

*[Signature]*  
**Dr. P. GUPTA**  
 MBBS, MD  
 Reg. Cardiologist



# ONEPLUS ULTRASOUND LAB

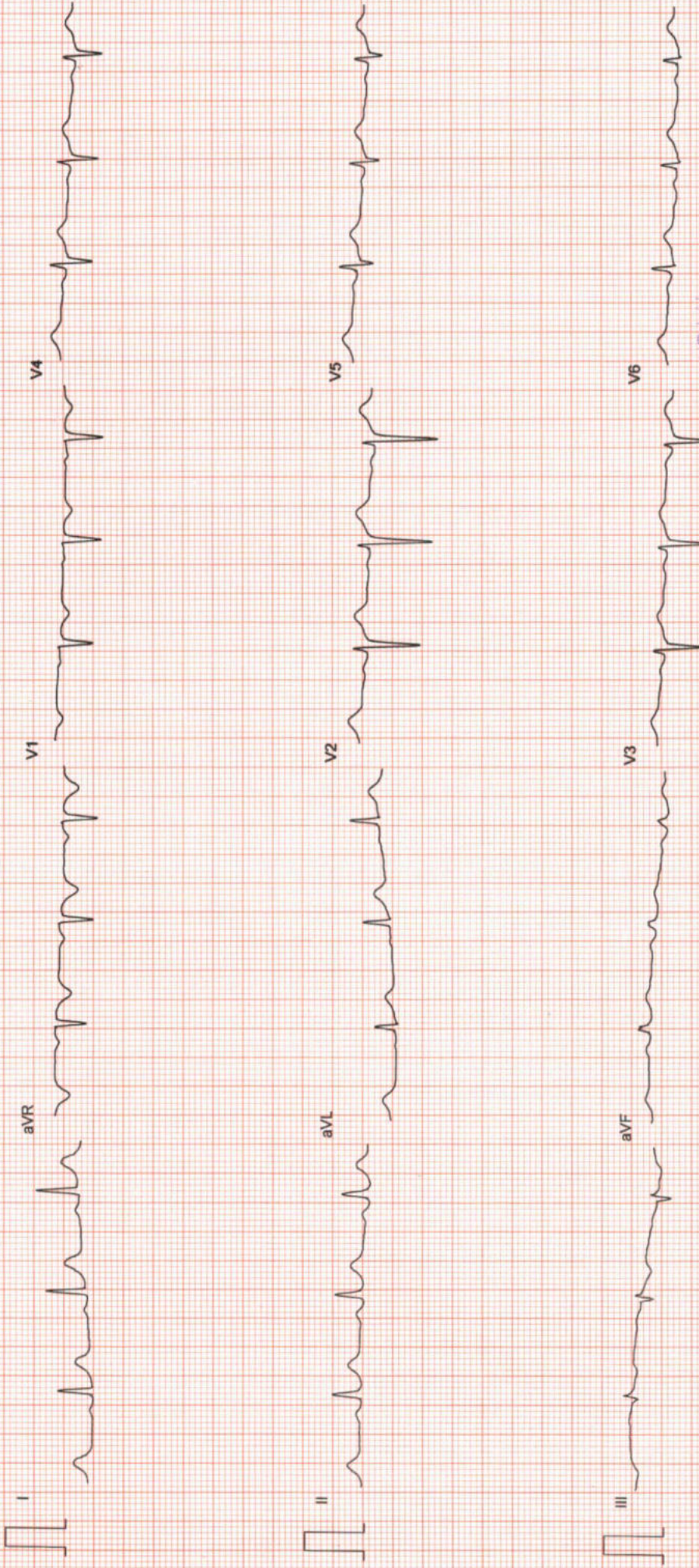
Mr. VINEET GOEL  
I.D. : 995  
AGE/SEX : 35/M  
RECORDED : 7-4-2023 9:40

RATE : 85 BPM  
B.P. : 120/84 mmHg

ST @ 10mm/mV  
80ms PostJ

SUPINE  
PRETEST

RAW E.C.G.



ONEPLUS ULTRASOUND Ltc  
47, Harsn Vihar, Pitam Pura,  
Delhi-110034  
Ph. 011-42480101, 9599913051  
E-mail: onepiusul@gmail.com



# ONEPLUS ULTRASOUND LAB

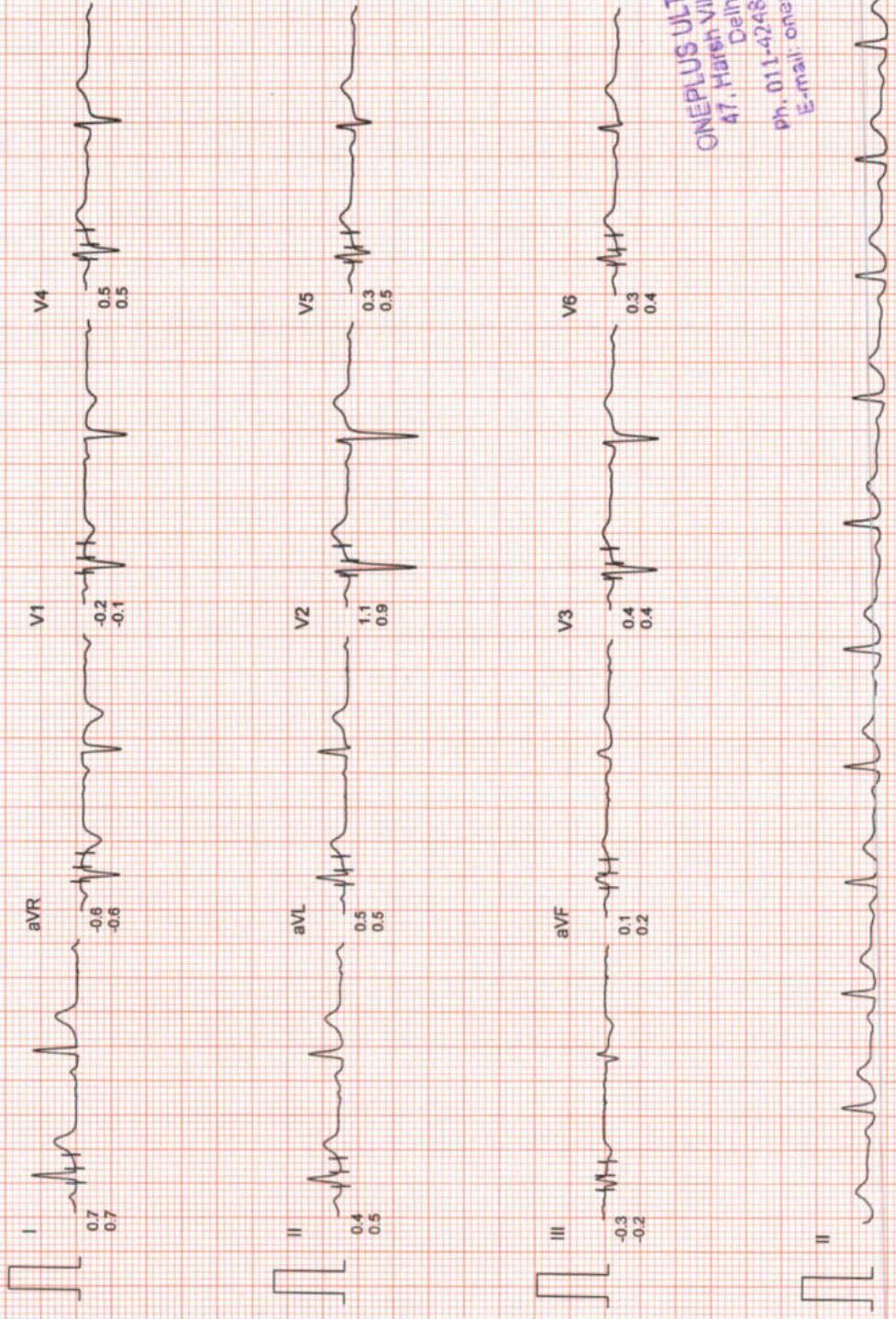
STANDING  
PRETEST

-Mr. VINEET GOEL  
I.D. : 995  
AGE/SEX : 35/M  
RECORDED : 7-4-2023 9:40

RATE : 88 BPM  
B.P. : 120/84 mmHg

ST @ 10mm/mV  
80ms PostJ

LINKED MEDIAN



50mm/sec 20mm/mV

ONEPLUS ULTRASOUND LAB  
47, Hareh Vihar, Pitam Pura,  
Delhi-110034  
Ph. 011-42480101, 9599913051  
E-mail: oneplusul@gmail.com



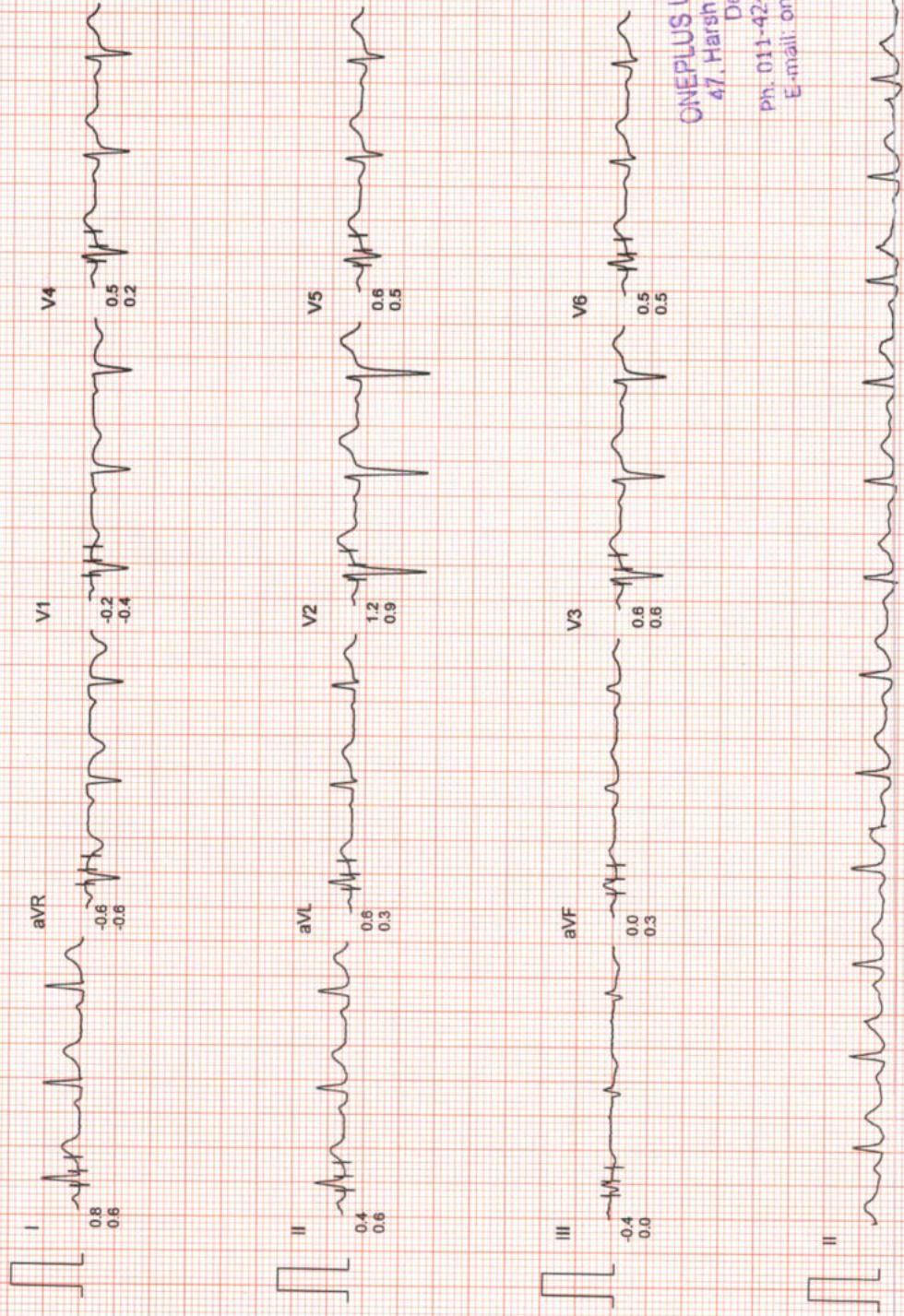
# ONEPLUS ULTRASOUND LAB

Mr. VINEET GOEL  
I.D. : 995  
AGE/SEX : 35/M  
RECORDED : 7-4-2023 9:40

RATE : 107 BPM  
B.P. : 132/86 mmHg

ST @ 10mm/mV  
80ms PostJ  
SPEED : 2.7 Km./Hr.  
GRADE : 10.0 %

LINKED MEDIAN



ONEPLUS ULTRASOUND LAB  
47, Harsh Vihar, Pitam Pura,  
Delhi-110034  
Ph. 011-42480101, 9599913051  
E-mail: oneplusul@gmail.com

Filtered

Computer Corrected Baseline

25mm/sec 10mm/mV

CardiCom, INDIA Ph.:091-731-2620740, TeleFax:091-731-2431214



# ONEPLUS ULTRASOUND LAB

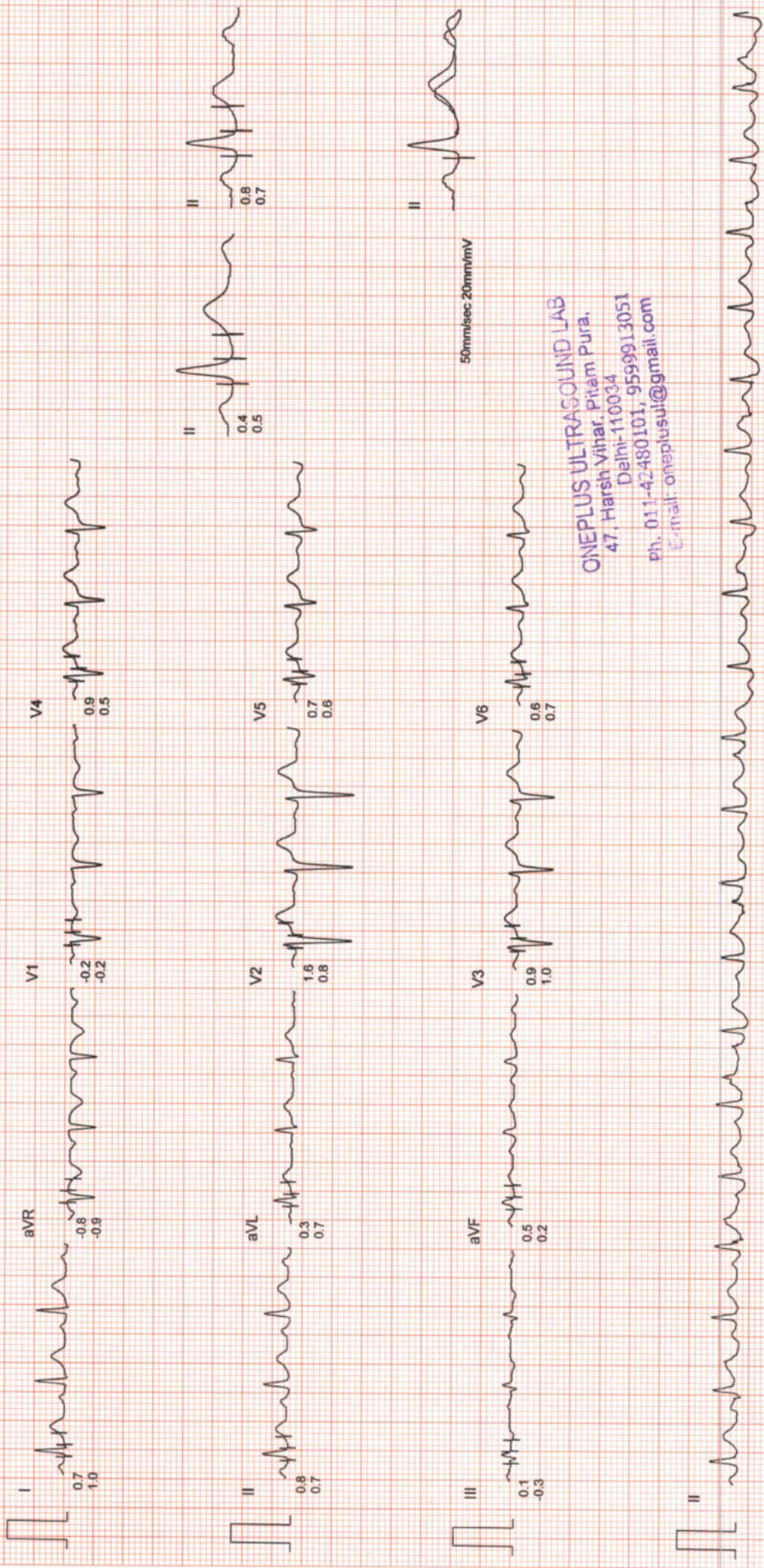
Mr. VINEET GOEL  
I.D. : 995  
AGE/SEX : 35/M  
RECORDED : 7-4-2023 9:40

RATE : 125 BPM  
B.P. : 142/88 mmHg

BRUCE  
EXERCISE 2  
PHASE TIME : 5:59  
STAGE TIME : 2:59

ST @ 10mm/mV  
80ms PostJ  
SPEED : 4.0 Km./Hr.  
GRADE : 12.0 %

LINKED MEDIAN



ONEPLUS ULTRASOUND LAB  
47, Harsh Vihar, Pitam Pura,  
Delhi-110034  
Ph. 011-42480101, 9599913051  
E-mail: oneplusul@gmail.com



# ONEPLUS ULTRASOUND LAB

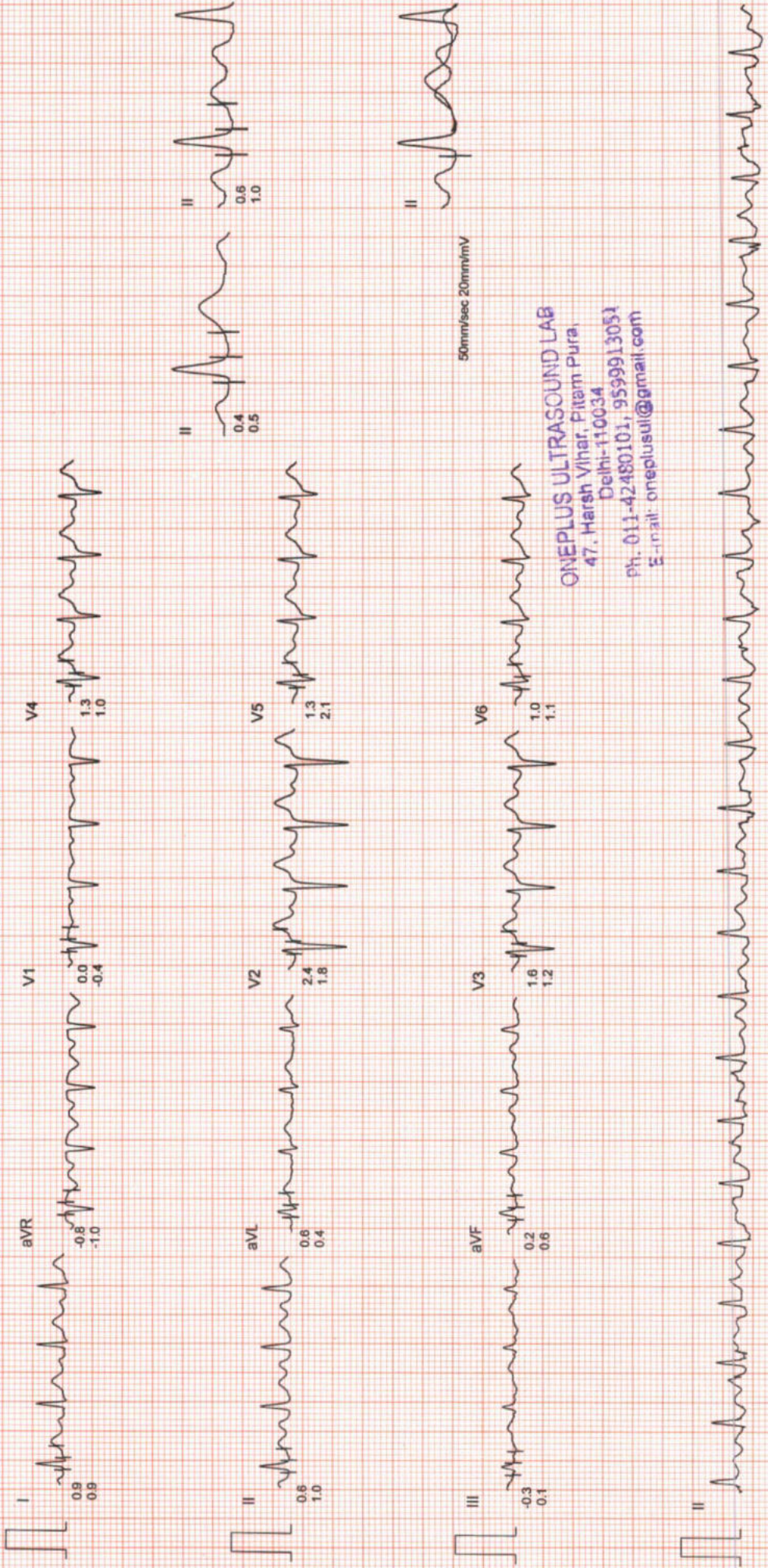
Mr. VINEET GOEL  
I.D. : 995  
AGE/SEX : 35/M  
RECORDED : 7-4-2023 9.40

RATE : 145 BPM  
B.P. : 154/90 mmHg

BRUCE  
EXERCISE 3  
PHASE TIME : 8:59  
STAGE TIME : 2:59

ST @ 10mm/mV  
80ms PostJ  
SPEED : 5.4 Km./Hr.  
GRADE : 14.0 %

LINKED MEDIAN



50mm/sec 20mm/mV

ONEPLUS ULTRASOUND LAB  
47, Harsh Vihar, Pitam Pura,  
Delhi-110034  
Ph. 011-42480101, 9599913051  
E-mail: oneplusul@gmail.com







# ONEPLUS ULTRASOUND LAB

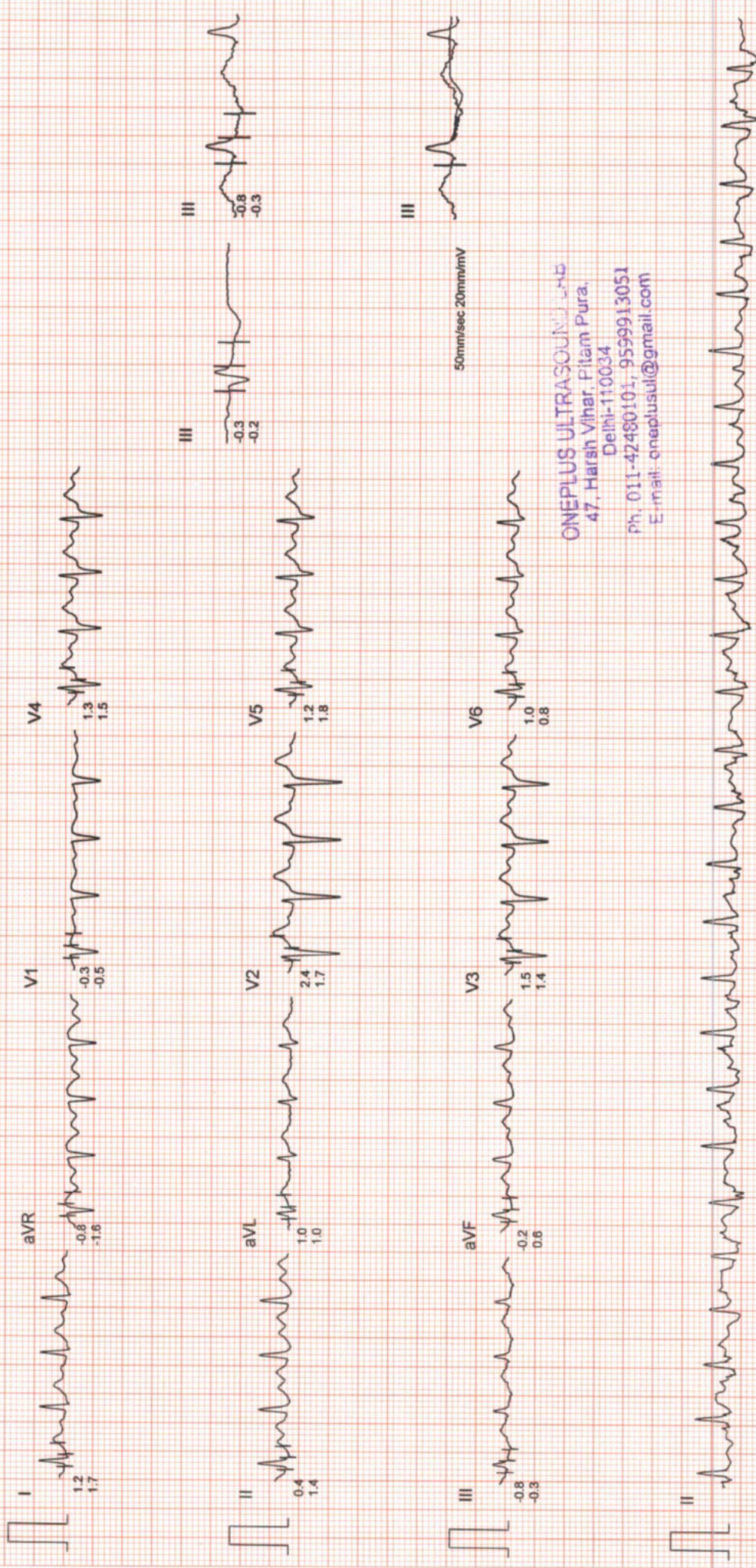
Mr. VINEET GOEL  
I.D. : 995  
AGE/SEX : 35/M  
RECORDED : 7-4-2023 9:40

RATE : 160 BPM  
B.P. : 166/92 mmHg

BRUCE  
EXERCISE 4  
PHASE TIME : 9:59  
STAGE TIME : 0:59

ST @ 10mm/mV  
80ms PostJ  
SPEED : 6.7 Km./Hr.  
GRADE : 16.0 %

LINKED MEDIAN



ONEPLUS ULTRASOUND LAB  
47, Harsh Vihar, Pitam Pura,  
Delhi-110034  
Ph. 011-42480101, 9599913051  
E-mail: eneplusul@gmail.com



# ONEPLUS ULTRASOUND LAB

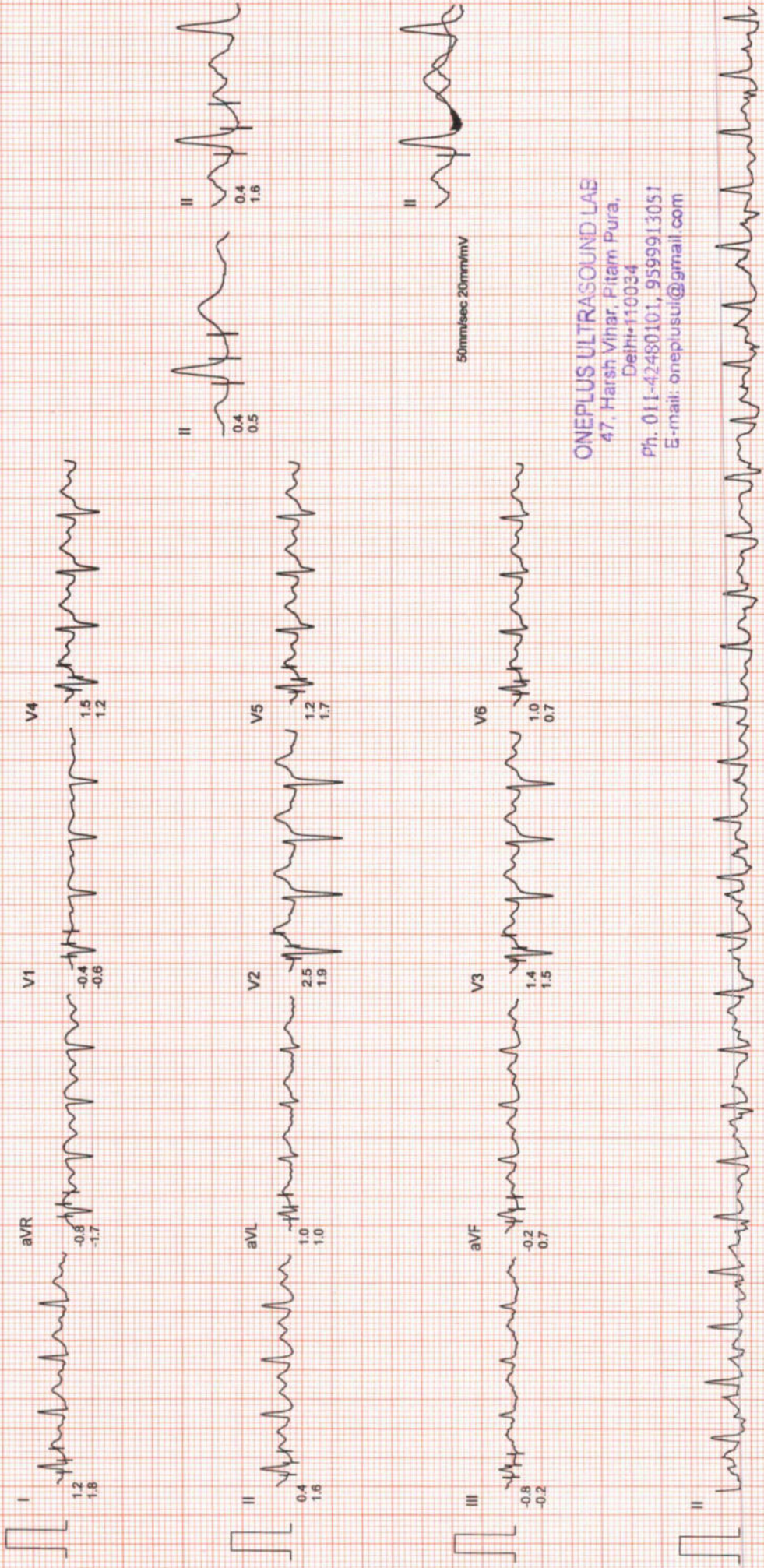
Mr. VINEET GOEL  
I.D. : 995  
AGE/SEX : 35/M  
RECORDED : 7-4-2023 9:40

RATE : 160 BPM  
B.P. : 166/92 mmHg

ST @ 10mm/mV  
80ms PostJ  
SPEED : 6.7 Km./Hr.  
GRADE : 16.0 %

BRUCE  
PEAK EXER  
PHASE TIME : 10:00  
STAGE TIME : 1:00

LINKED MEDIAN



50mm/sec 20mm/mV

ONEPLUS ULTRASOUND LAB  
47, Harsh Vihar, Pitam Pura,  
Delhi-110034  
Ph. 011-42480101, 9599913051  
E-mail: oneplusui@gmail.com



# ONEPLUS ULTRASOUND LAB

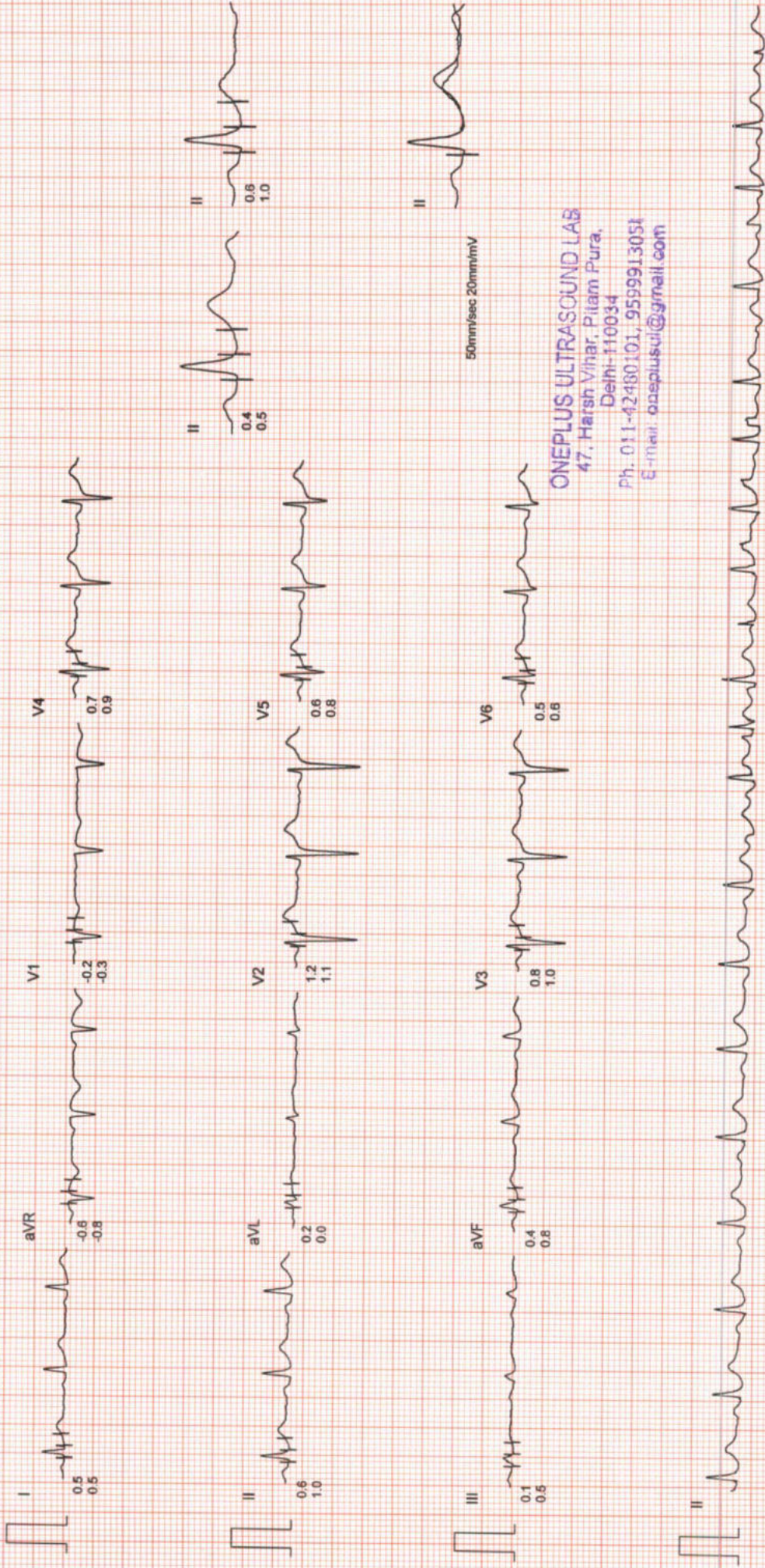
Mr. VINEET GOEL  
I.D. : 995  
AGE/SEX : 35/M  
RECORDED : 7-4-2023 9:40

RATE : 136 BPM  
B.P. : 126/84 mmHg

BRUCE  
RECOVERY  
PHASE TIME : 2:59

ST @ 10mm/mV  
80ms PostJ  
SPEED : 0.0 Km./Hr.  
GRADE : 0.0 %

LINKED MEDIAN



ONEPLUS ULTRASOUND LAB  
47, Harsh Vihar, Pitam Pura,  
Delhi-110034  
Ph. 011-42480101, 9599913058  
E-mail: [oneplusul@gmail.com](mailto:oneplusul@gmail.com)



# ONEPLUS ULTRASOUND LAB

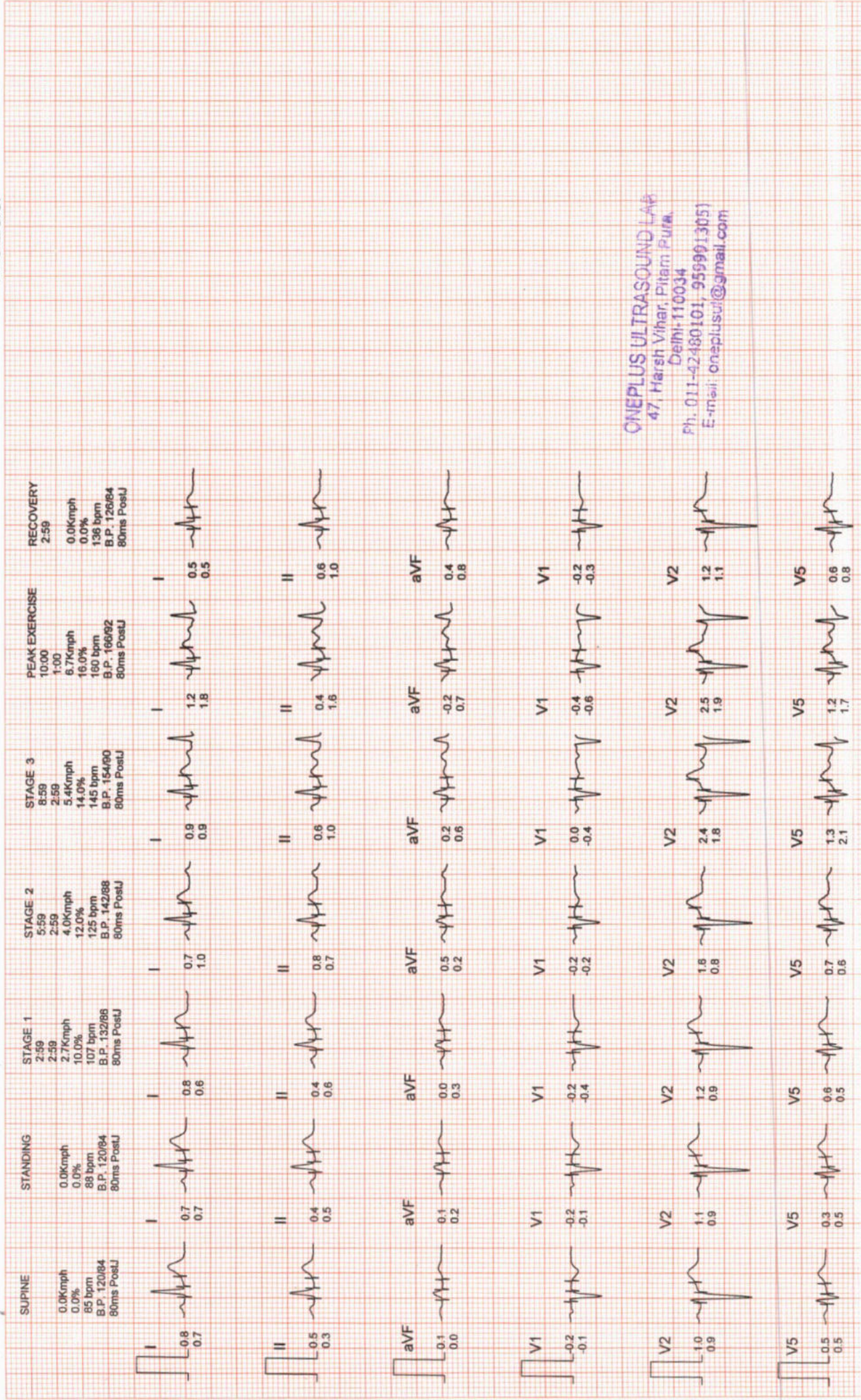
Mr. VINEET GOEL

I.D. : 995

AGE/SEX : 35/M

RECORDED : 7-4-2023 9:40

AVG E.C.G.



ONEPLUS ULTRASOUND LAB  
47, Harsh Vihar, Pitam Pura,  
Delhi-110034  
Ph. 011-42480101, 9599913051  
E-mail: onepplusul@gmail.com



# ONEPLUS ULTRASOUND LAB

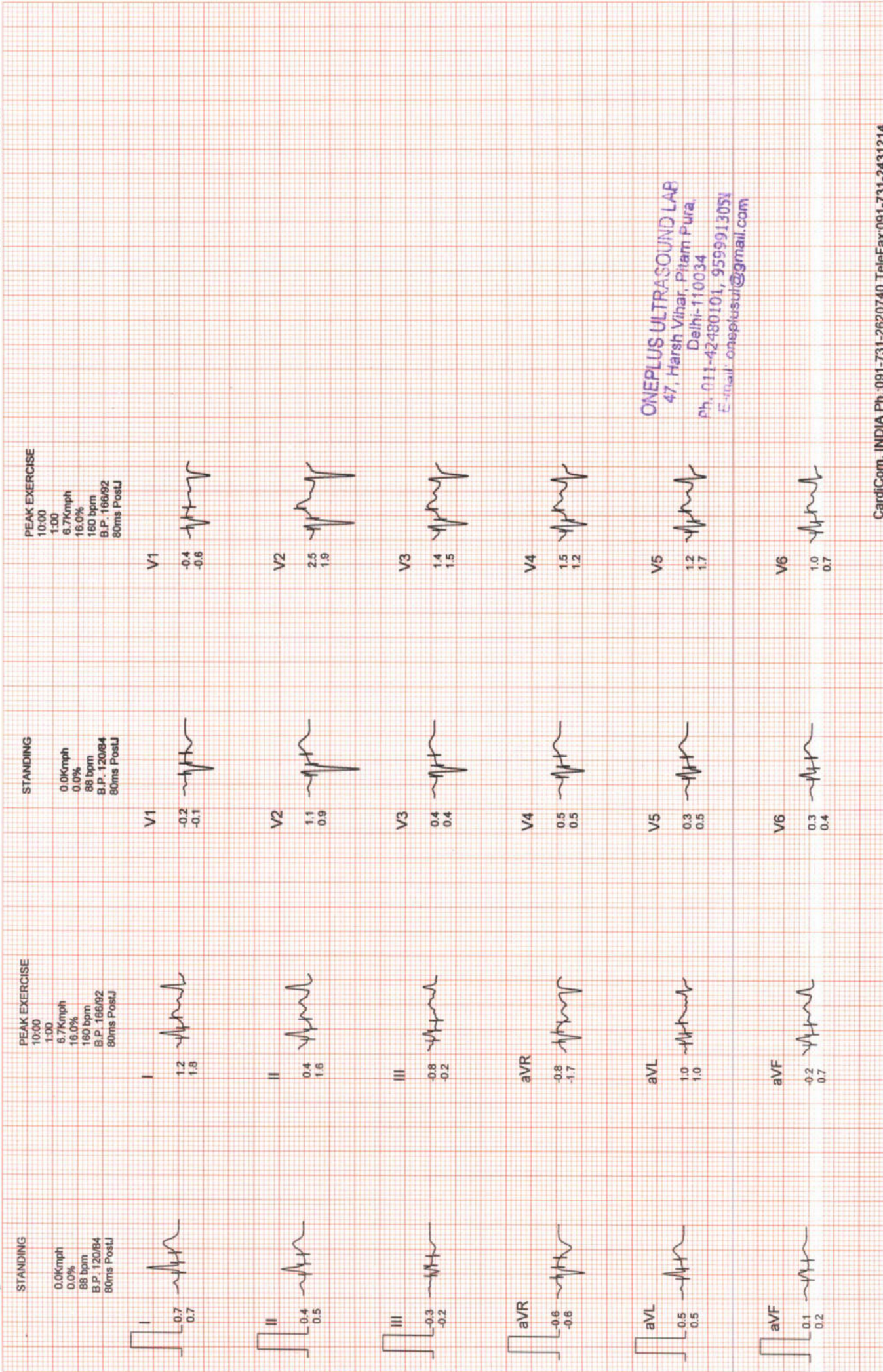
AGE/SEX : 35/M

I.D. : 995

Mr. VINEET GOEL

RECORDED : 7-4-2023 9:40

## COMPARISON REPORT



ONEPLUS ULTRASOUND LAB  
47, Harsh Vihar, Pitam Pura,  
Delhi-110034  
Ph. 011-42480101, 9599913051  
E-mail: onepplusul@gmail.com





**OnePLUS**  
Ultrasound Lab

— QUALITY FIRST... ALWAYS! —

**Dr. Nitin Agarwal**

Pathologist & Director  
Ex. Sr. Res. MAMC  
& Lok Nayak Hospital  
Ex. Chief of Lab Dr. Lal Path Labs.

**Dr. Pooja (Garg) Agarwal**

Radiologist & Director  
MAMC & Lok Nayak Hospital

Name	: Mr. VINEET GOEL	Age/Sex	: 35 YRS/Male
Ref. By	: Dr. MEDIWHEEL	Lab No	: 012304070007
Date	: 07-Apr-2023	Patient ID	: LSHHI112131

### ULTRASOUND EXAMINATION----WHOLE ABDOMEN

**Liver** is normal in size and outline with normal echopattern. No abscess or mass lesion seen. Hepatic veins, portal vein, IVC and aorta are normal. Intrahepatic biliary radicles are not dilated. CBD is normal in caliber.

Gall bladder is well distended with anechoic lumen. Wall thickness is normal.

Both kidneys are normal in size, shape, position, outline and echopattern. Corticomedullary differentiation is maintained. No pelvicalyceal dilation or calculus or mass lesion is seen.

Spleen is normal in size and echotexture. No mass lesion seen.


Pancreas is normal in size, outline and echotexture.

Urinary bladder is normal in shape and position. No evidence of intravesical stone or mass seen.

Prostate is normal in size, shape and echopattern.  
Prostate measures 3.6 x 3.3 x 2.7cm. Weight of prostate is 18 grams.

No abnormal bowel wall thickening seen in right iliac fossa.  
No mass or free fluid seen anywhere in abdomen.

**IMPRESSION: No significant abnormality is seen.**

  
**DR. POOJA GARG**  
RADIOLOGIST  
M.B.B. (R) D.M.C.R.D.  
Reg No. DMC/R/03398  
Radiologist

Type By : pooja

47, Harsh Vihar, Pitampura, New Delhi-110034 | Ph.: 011-42480101, 9599913051  
E-mail: oneplusul@gmail.com | Web.: www.oneplusul.in

W550A MR VINEET 35/M OnePlus Ultrasound Lab MI 1.4 07-04-2023  
CA1-7A / Abdomen / FR 24Hz Tis 0.1 10:20:17 AM

20 G60 DR135-FAB P90 Frq Gen: 17.0cm 83/30

W550A MR VINEET 35/M OnePlus Ultrasound Lab MI 1.4 07-04-2023  
CA1-7A / Abdomen / FR 24Hz Tis 0.1 10:20:26 AM

20 G60 DR135-FAB P90 Frq Gen: 17.0cm 83/30

W550A MR VINEET 35/M OnePlus Ultrasound Lab MI 1.4 07-04-2023  
CA1-7A / Abdomen / FR 24Hz Tis 0.1 10:20:30 AM

20 G60 DR135-FAB P90 Frq Gen: 17.0cm 83/30

W550A MR VINEET 35/M OnePlus Ultrasound Lab MI 1.4 07-04-2023  
CA1-7A / Abdomen / FR 24Hz Tis 0.1 10:20:44 AM

20 G60 DR135-FAB P90 Frq Gen: 17.0cm 83/30

20 G80 DR135-FAB P90 Frq Gen: 17.0cm 61/30

D1	3.29 cm
D2	3.77 cm
D3	3.86 cm
Vol.	18.41 ml

D1	3.29 cm
D2	2.77 cm

W550A MR VINEET 35/M OnePlus Ultrasound Lab MI 1.4 07-04-2023  
CA1-7A / Abdomen / FR 24Hz Tis 0.1 10:20:54 AM

20 G60 DR135-FAB P90 Frq Gen: 17.0cm 83/30

W550A MR VINEET 35/M OnePlus Ultrasound Lab MI 1.4 07-04-2023  
CA1-7A / Abdomen / FR 21Hz Tis 0.1 10:21:09 AM

20 G60 DR135-FAB P90 Frq Gen: 20.0cm 83/30

W550A MR VINEET 35/M OnePlus Ultrasound Lab MI 1.4 07-04-2023  
CA1-7A / Abdomen / FR 21Hz Tis 0.1 10:21:28 AM

20 G60 DR135-FAB P90 Frq Gen: 20.0cm 83/30

20 G60 DR135-FAB P90 Frq Gen: 20.0cm 83/30

D1	3.29 cm
D2	3.77 cm
D3	3.86 cm
Vol.	18.41 ml

W550A MR VINEET 35/M OnePlus Ultrasound Lab MI 1.4 07-04-2023  
CA1-7A / Abdomen / FR 21Hz Tis 0.1 10:21:38 AM

20 G58 DR135-FAB P90 Frq Gen: 20.0cm 83/30





NAME: [illegible] ID: [illegible]  
 DATE: 11/24/2011 TIME: 11:28:39 AM  
 CHANNEL: [illegible] [illegible]



NAME: [illegible] ID: [illegible]  
 DATE: 11/24/2011 TIME: 11:31:48 AM  
 CHANNEL: [illegible] [illegible]




NAME: [illegible] ID: [illegible]  
 DATE: 11/24/2011 TIME: 11:32:59 AM  
 CHANNEL: [illegible] [illegible]



NAME: [illegible] ID: [illegible]  
 DATE: 11/24/2011 TIME: 11:34:09 AM  
 CHANNEL: [illegible] [illegible]




NAME: [illegible] ID: [illegible]  
 DATE: 11/24/2011 TIME: 11:35:20 AM  
 CHANNEL: [illegible] [illegible]



NAME: [illegible] ID: [illegible]  
 DATE: 11/24/2011 TIME: 11:37:30 AM  
 CHANNEL: [illegible] [illegible]



NAME: [illegible] ID: [illegible]  
 DATE: 11/24/2011 TIME: 11:38:41 AM  
 CHANNEL: [illegible] [illegible]



NAME: [illegible] ID: [illegible]  
 DATE: 11/24/2011 TIME: 11:39:51 AM  
 CHANNEL: [illegible] [illegible]



**OnePLUS**  
Ultrasound Lab

— QUALITY FIRST... ALWAYS! —

**Dr. Nitin Agarwal**

Pathologist & Director  
Ex. Sr. Res. MAMC  
& Lok Nayak Hospital  
Ex. Chief of Lab Dr. Lal Path Labs.

**Dr. Pooja (Garg) Agarwal**

Radiologist & Director  
MAMC & Lok Nayak Hospital

Name	: Mr. VINEET GOEL	Age/Sex	: 35 YRS/Male
Ref. By	: Dr. MEDIWHEEL	Lab No	: 012304070007
Date	: 07-Apr-2023	Patient ID	: LSHHI112131

### X-ray-Chest PA view

Bony cage and soft tissues are normal.  
Cardiothoracic ratio is normal.  
Mediastinum is normal.  
Both hila are normal.  
Both costophrenic angles are clear.  
Both domes of diaphragm are normal.  
Lung fields are clear. No parenchymal lesion seen.

**IMPRESSION: Normal Study.**

Dr. POOJA GARG  
M.B.B.S., D.M.R.D.  
Reg No DMC/R/03398  
Radiologist  
**DR. POOJA GARG**  
RADIOLOGIST  
REG NO- DMC/R/03398

Type By : darshita

47, Harsh Vihar, Pitampura, New Delhi-110034 | Ph.: 011-42480101, 9599913051  
E-mail: oneplusul@gmail.com | Web.: www.oneplusul.in

ОИЕГЛС ПГТВАСОИД ГАВ'АТ-НАРSH VИAВ'PITAMЬУPA  
VINEET COEГ 32YIW 413053 M CHECTPA VEM 413053

В



R

VINEET GOEL 35Y/M 7/4/2023 M CHEST PA VIEW 4/7/2023  
ONEPLUS ULTRASOUND LAB.47-HARSH VIHAR.PITAMPURA