



सत्यमेव जयते
भारत सरकार



आधार

भारतीय विशिष्ट पहचान प्राधिकरण

भारत सरकार

Unique Identification Authority of India

Government of India

नामांकन क्रम / Enrollment No.: 2019/22167/00101

To
नीरज अग्रवाल
Neeraj Aggarwal
S/O: Padam Kant Aggarwal
C - 8/38
Rohini Sector 15
Rohini Sector 15
Narela North West Delhi
Delhi 110089
9868018806
135817370
01/07/2013
ML358173705FT



आपका आधार क्रमांक / Your Aadhaar No. :

4166 3001 1936

आधार - आम आदमी का अधिकार



भारत सरकार

Government of India



नीरज अग्रवाल
Neeraj Aggarwal
जन्म तिथि / DOB : 07/09/1980
पुरुष / Male



4166 3001 1936

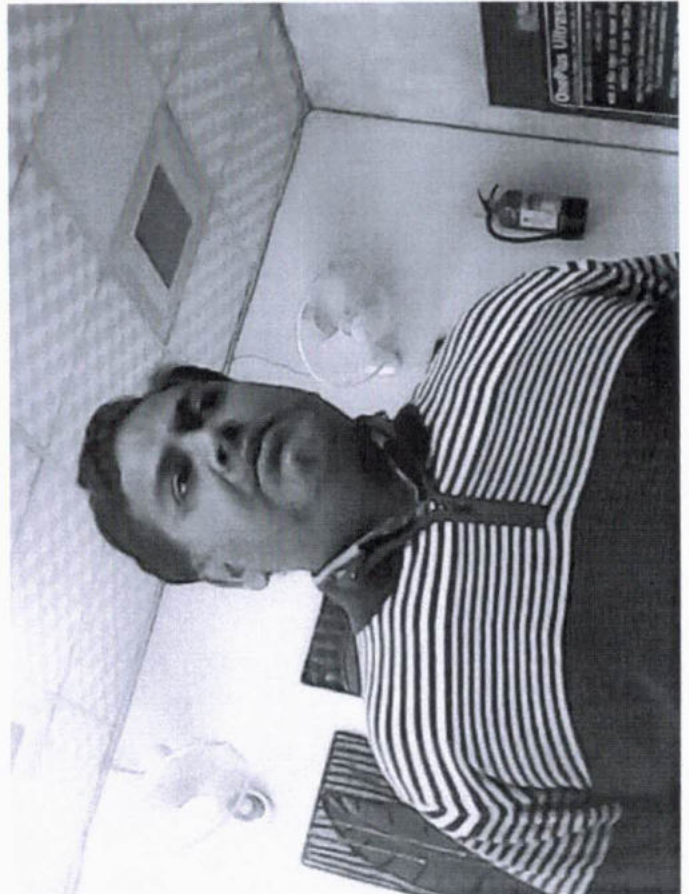
आधार - आम आदमी का अधिकार

Dr. NITIN AGGARWAL
MBBS, MD
Regn. No. DMC-R-1436

ONEPLUS ULTRASOUND LAB
47, Hareh Vihar, Pitam Pura,
Delhi-110034
Ph. 011-42480101, 95599913051
E-mail: oneplusul@gmail.com

Yam

Dr. MITIN AGARWAL
MBBS, MD
Regn. No. BME-R-1436



ONEPLUS ULTRASOUND LAB
47, Harsh Vihar, Pitam Pura,
Delhi-110034
Ph. 011-42480101, 9599913051
E-mail: onepusul@gmail.com



OnePLUS
Ultrasound Lab
— QUALITY FIRST... ALWAYS! —

Dr. Nitin Agarwal
Pathologist & Director
Ex. Sr. Res. MAMC
& Lok Nayak Hospital
Ex. Chief of Lab Dr. Lal Path Labs.


Dr. Pooja (Garg) Agarwal
Radiologist & Director
MAMC & Lok Nayak Hospital

Name	: Mr. NEERAJ AGGARWAL	Age/Sex	: 42 YRS/Male
Ref. By	: Dr. MEDIWHEEL	Lab No	: 012302110014
Date	: 11-Feb-2023	Patient ID	: LSHHI109047

X-ray-Chest PA view

Bony cage and soft tissues are normal.
Cardiothoracic ratio is normal.
Mediastinum is normal.
Both hila are normal.
Both costophrenic angles are clear.
Both domes of diaphragm are normal.
Lung fields are clear. No parenchymal lesion seen.

IMPRESSION: Normal Study.



DR. POOJA GARG
RADIOLOGIST
REG NO- DMC/R/03398

Type By : kusum

47, Harsh Vihar, Pitampura, New Delhi-110034 | Ph.: 011-42480101, 9599913051
E-mail: oneplusul@gmail.com | Web.: www.oneplusul.in

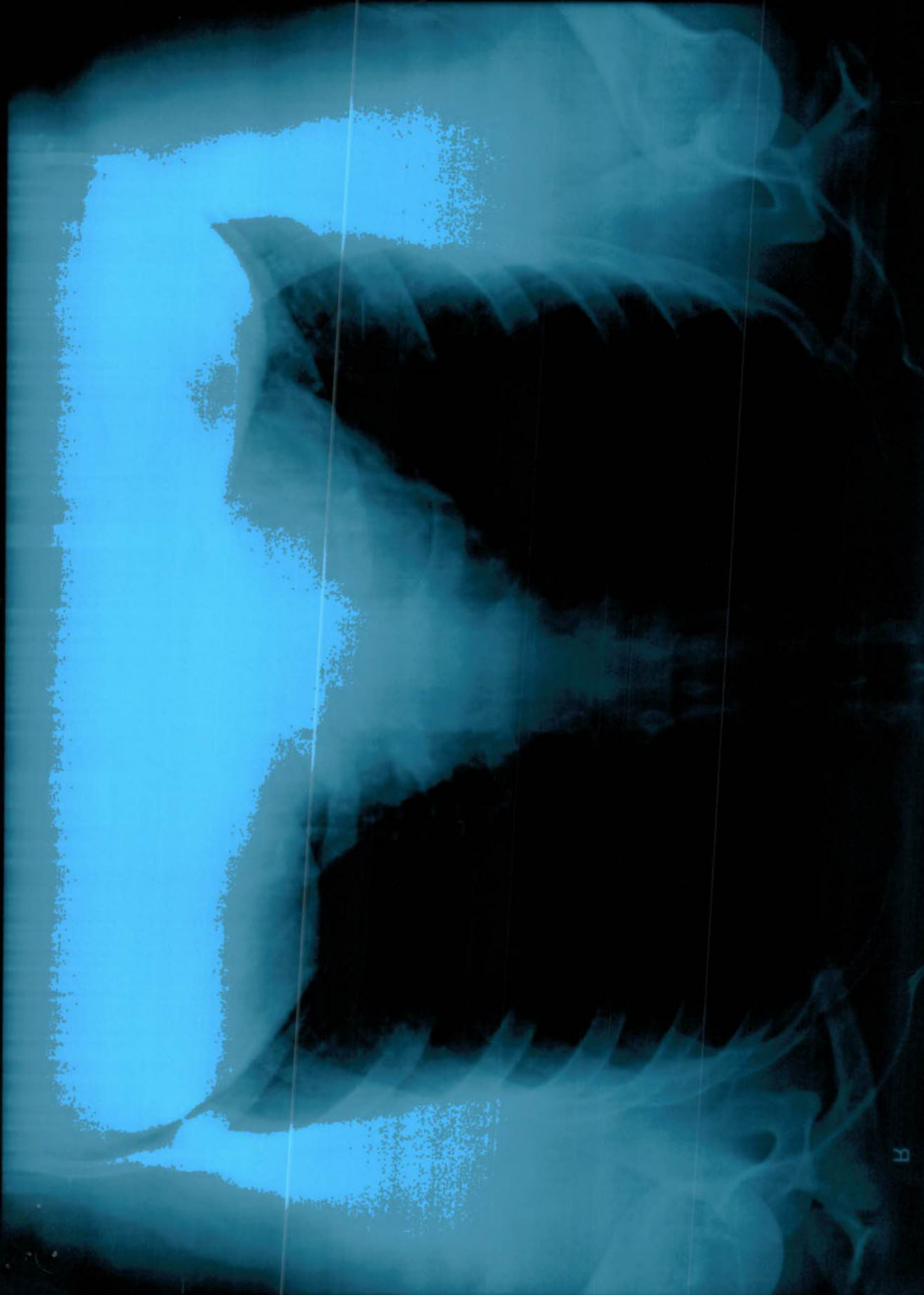
Clinical correlation is essential for final diagnosis. • If test results are unsatisfactory please contact personally or on phone. • This report is for perusal of doctors only.
• All disputes Subject to Delhi Jurisdiction only. • Not for medicolegal purposes. • All congenital anomalies in a foetus may not be diagnosed in routine obstetric ultrasound.

R



MR NEERAJ AGGARWAL 42 YRS 11/2/2023 M CHEST PA VIEW 2/11/2023
ONEPLUS ULTRASOUND LAB 47 HARSH VIHAR PITAMPURA

MR. MEEBUL ACCAPWAL 25 YRS 65051111 2RY SA JAWPADDA LAEENI 5MI
ONEPI US UL TRAGOUND I AV TA VA I QINDART JU 2U 1991O
APUMATIPI RANIN H2AN TA VA I HARSH VIANR 5I AMPI 5A V15053



Name	: Mr. NEERAJ AGGARWAL	Age/Sex	: 42 YRS/Male
Ref. By	: Dr. MEDIWHEEL	Lab No	: 012302110014
Date	: 11-Feb-2023	Patient ID	: LSHHI109047

ULTRASOUND EXAMINATION----WHOLE ABDOMEN

Liver is normal in size (13.4 cm) and normal in outline with **altered echopattern. Diffuse increase in echogenicity of liver parenchyma is noted, suggestive of fatty infiltration (grade II). Intrahepatic biliary radicles are not dilated.** No abscess or mass lesion seen. Hepatic veins, portal vein, IVC and aorta are normal. CBD is normal in caliber.

Gall bladder is well distended with anechoic lumen. Wall thickness is normal.

Both kidneys are normal in size, shape, position, outline and echopattern. Corticomedullary differentiation is maintained. No pelvicalyceal dilation or mass lesion is seen.

Spleen is normal in size and echotexture. No mass lesion seen.

Pancreas is normal in size, outline and echotexture.

Urinary bladder is normal in shape and position. No evidence of intravesical stone or mass seen.


Prostate is normal in size, shape and echopattern.

Prostate measures 2.9 x 2.6 x 3.5 cm. **Weight of prostate is 13.7 grams.**

No abnormal bowel wall thickening seen in right iliac fossa.
No free fluid seen anywhere in abdomen.

IMPRESSION:

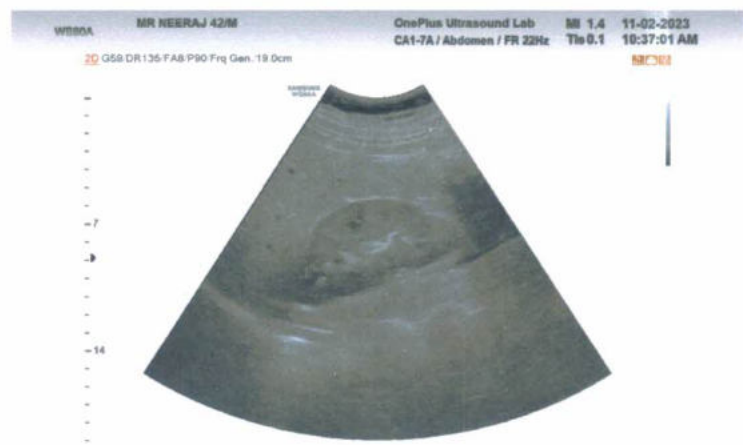
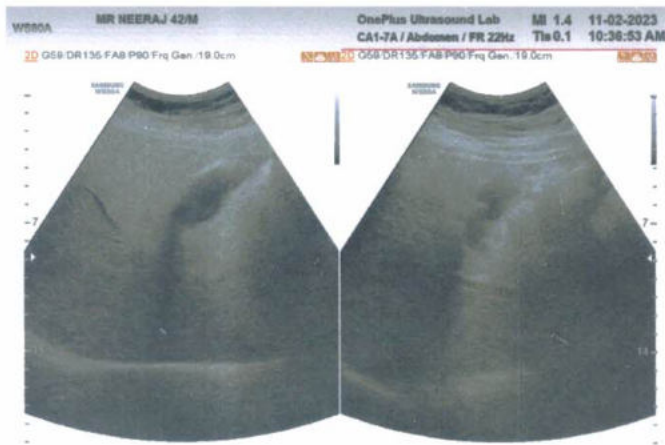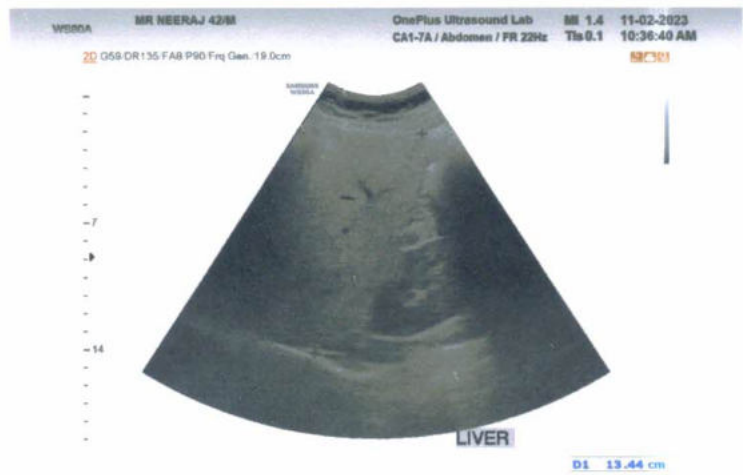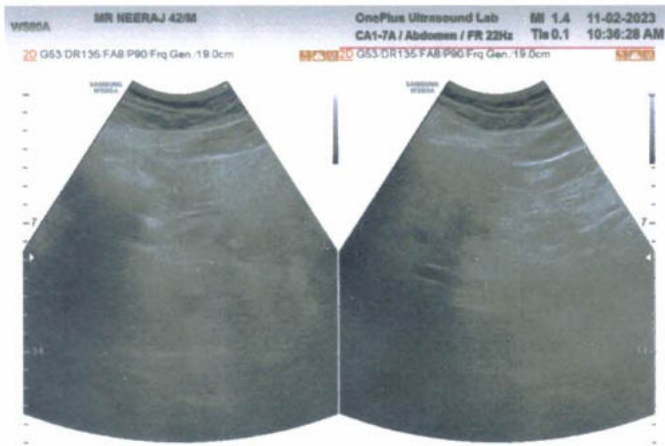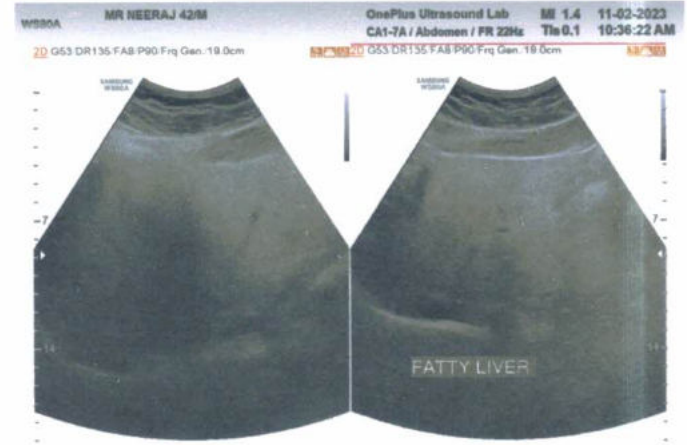
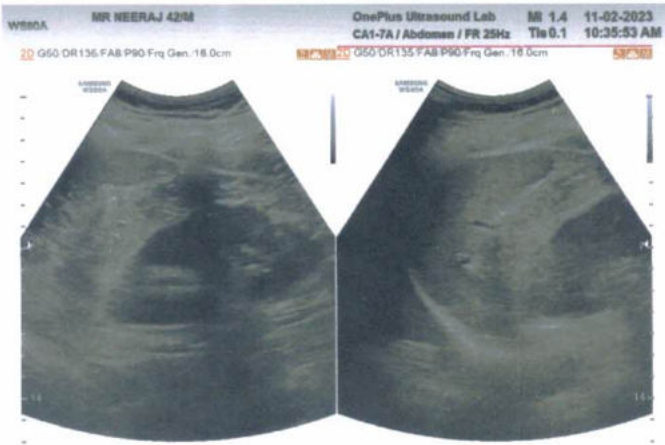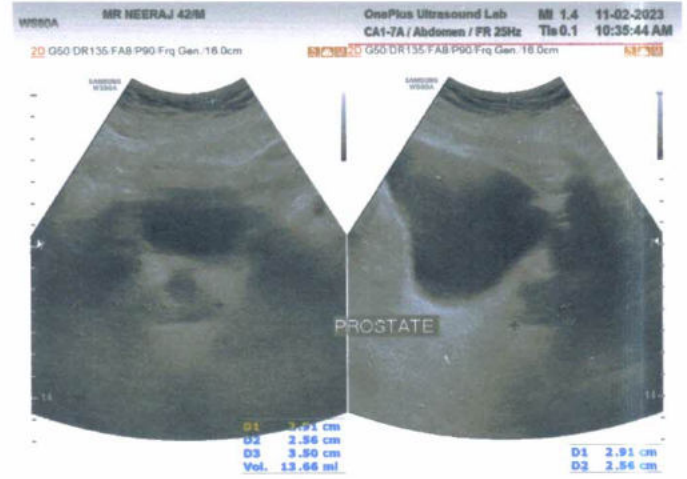
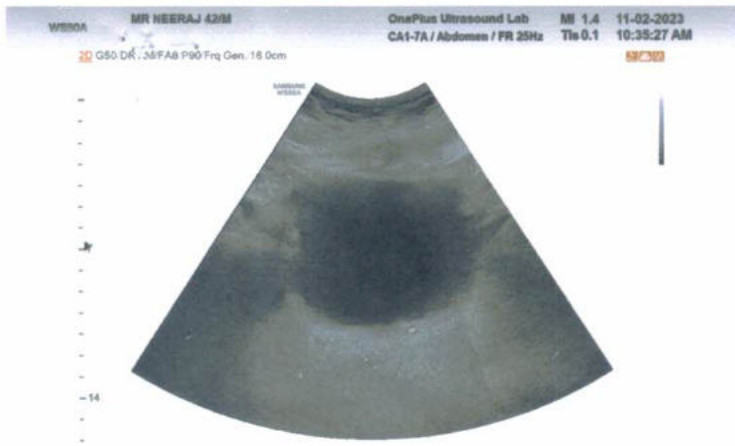- **Fatty infiltration of liver (grade II) with no hepatomegaly.**


DR. POOJA GARG
RADIOLOGIST
REG NO- DMC/R/03398

Type By : kusum

47, Harsh Vihar, Pitampura, New Delhi-110034 | Ph.: 011-42480101, 9599913051

E-mail: oneplusul@gmail.com | Web.: www.oneplusul.in





OnePLUS Ultrasound Lab

QUALITY FIRST... ALWAYS!

Dr. Nitin Agarwal
Pathologist & Director
Ex. Sr. Res. MAMC
& Lok Nayak Hospital
Ex. Chief of Lab Dr. Lal Path Labs.

Dr. Pooja (Garg) Agarwal
Radiologist & Director
MAMC & Lok Nayak Hospital



NAME	:Mr. NEERAJ AGGARWAL	Barcode No	:10137657
AGE/GENDER	:42 YRS/Male	SPECIMEN DATE	:11/Feb/2023 09:16AM
PATIENT ID	:109047	SPECIMEN RECEIVED	:11/Feb/2023 10:41AM
REFERRED BY	:Dr. MEDIWHEEL	REPORT DATE	:11/Feb/2023 02:11PM
CENTRE NAME	:ONEPLUS ULTRASOUND LAB	LAB NO.	:012302110014

Test Name	Result	Unit	Ref. Range
-----------	--------	------	------------

HAEMATOLOGY

Medi Wheel Health checkup < 40 Male

<u>Glycosylated Hemoglobin (HbA1c)</u>	4.9	%	Non Diabetic adults <5.7 Prediabetic (at risk) 5.7-6.4 Diabetes >6.4
--	-----	---	--

<u>Estimated average blood glucose (eag)</u>	94
Reference range (mg/dl):	

90 - 120:Excellent control, 121 - 150:Good Control, 151 - 180:Average Control, 181 - 210:Action Suggested

>211:Panic value

<u>BLOOD GROUP (ABO)</u>	B
<u>Rh typing</u>	POSITIVE

NOTE :

- * Apart from major A,B,H antigens which are used for ABO grouping and Rh typing, many minor blood group antigens exist. Agglutination may also vary according to titre of antigen and antibody.
- * So before transfusion, reconfirmation of blood group as well as cross-matching is needed.
- * Presence of maternal antibodies in newborns, may interfere with blood grouping.
- * Auto agglutination (due to cold antibody, falciparum malaria, sepsis, internal malignancy etc.) may also cause erroneous result.

CBC

Haemoglobin	16.0	g/dl	13.0-17.0
Total Leucocyte Count	8000	/cumm	4000-10000
<u>Differential leucocyte count</u>			
Neutrophils	56.6	%	40-80
Lymphocyte	37.50	%	20-40
Monocytes	3.90	%	2-10
Eosinophils	1.5	%	1-6
Basophils	0.5	%	0-2
RBC Count	5.40	million/cumm	4.5 - 5.5

Checked By.

DR. NITIN AGARWAL
MBBS,MD(PATHOLOGIST)

47, Harsh Vihar, Pitampura, New Delhi-110034 | Ph.: 011-42480101, 9599913051

E-mail: oneplusul@gmail.com | Web.: www.oneplusul.in

Page 1 of 5



OnePLUS Ultrasound Lab

— QUALITY FIRST. ALWAYS! —

Dr. Nitin Agarwal

Pathologist & Director
Ex. Sr. Res. MAMC
& Lok Nayak Hospital
Ex. Chief of Lab Dr. Lal Path Labs.

Dr. Pooja (Garg) Agarwal

Radiologist & Director
MAMC & Lok Nayak Hospital



NAME	:Mr. NEERAJ AGGARWAL	Barcode No	:10137657
AGE/GENDER	:42 YRS/Male	SPECIMEN DATE	:11/Feb/2023 09:16AM
PATIENT ID	:109047	SPECIMEN RECEIVED	:11/Feb/2023 10:41AM
REFERRED BY	:Dr. MEDIWHEEL	REPORT DATE	:11/Feb/2023 02:11PM
CENTRE NAME	:ONEPLUS ULTRASOUND LAB	LAB NO.	:012302110014

Test Name	Result	Unit	Ref. Range
PCV(Hematocrit)	51.8	%	40-50
MCV	94.9	fL	83-101
MCH	29.3	Pg	27-32
MCHC	30.8	G/dL	32-35
Platelet count	290000	/cumm	150000-450000
RDW-CV	13.6	%	11.4-14.0
ESR(WESTEGRENs METHOD)	10	mm in 1st hr	0-20

BIOCHEMISTRY

<u>Bun (blood urea nitrogen)</u>	12.40	mg/dl	8.9-21.6
<u>Uric acid, serum</u>	4.8	mg/dl	3.5-7.2
<u>BLOOD SUGAR RANDOM</u>	94	mg/dL	<140 Normal 140-199 Pre Diabetes >200 Diabetes

Comments :-

- Random blood sugar measures the glucose levels regardless of the last meal/intake.
- Random testing is useful because glucose levels in healthy individuals do not vary widely throughout the day.
- A random blood sugar - $> / = 200$ mg/ dL denotes diabetes- $> / = 140$ but < 199 mg/ dL suggest fasting blood glucose levels and Post Prandial blood glucose levels to be done.

<u>Creatinine, serum</u>	0.90	mg/dl	0.60-1.2
--------------------------	------	-------	----------

LFT(LIVER FUNCTION TEST)

Bilirubin Total	0.54	mg/dl	0.1-1.2
Bilirubin Conjugated	0.24	mg/dl	0-0.4
Bilirubin Unconjugated	0.30	mg/dl	up to 0.7
SGOT (AST)	38	U/L	0-46
SGPT (ALT)	61	U/L	0-49
Alkaline phosphatase	106	U/L	40-129
Gamma glutamyl transpeptidase	28	U/L	10-45
Total Protein	7.8	gm/dl	6.60 - 8.70
Albumin serum	4.6	g/dL	3.0-5.2
Globulin	3.20	gm/dl	1.8-3.4

Checked By.

DR. NITIN AGARWAL
MBBS,MD(PATHOLOGIST)

47, Harsh Vihar, Pitampura, New Delhi-110034 | Ph.: 011-42480101, 9599913051
E-mail: oneplusul@gmail.com | Web.: www.oneplusul.in

Page 2 of 5

Clinical correlation is essential for final diagnosis. • If test results are unsatisfactory please contact personally or on phone. • This report is for perusal of doctors only.
• All disputes Subject to Delhi Jurisdiction only. • Not for medicolegal purposes. • All congenital anomalies in a foetus may not be diagnosed in routine obstetric ultrasound.



OnePLUS Ultrasound Lab

QUALITY FIRST... ALWAYS!

Dr. Nitin Agarwal
Pathologist & Director
Ex. Sr. Res. MAMC
& Lok Nayak Hospital
Ex. Chief of Lab Dr. Lal Path Labs.

Dr. Pooja (Garg) Agarwal
Radiologist & Director
MAMC & Lok Nayak Hospital



NAME	:Mr. NEERAJ AGGARWAL	Barcode No	:10137657
AGE/GENDER	:42 YRS/Male	SPECIMEN DATE	:11/Feb/2023 09:16AM
PATIENT ID	:109047	SPECIMEN RECEIVED	:11/Feb/2023 10:41AM
REFERRED BY	:Dr. MEDIWHEEL	REPORT DATE	:11/Feb/2023 02:11PM
CENTRE NAME	:ONEPLUS ULTRASOUND LAB	LAB NO.	:012302110014

Test Name	Result	Unit	Ref. Range
Albumin/Globulin Ratio	1.44		1.10 - 2.50

LIPID PROFILE

Cholesterol	161	mg/dl	50-200
Triglycerides	87	mg/dL	25-150
HDL Cholesterol	42	mg/dL	40 - 60
LDL cholesterol	102	mg/dL	<130
VLDL cholesterol	17.4	mg/dL	5-40
Cholesterol/HDL Ratio	3.8		Low Risk 3.3-4.97 Average Risk 4.4-7.1 Moderate Risk 7.1-11.0 High Risk >11.0
LDL/HDL Ratio	2.4		0 - 3.55

According to ATP III and NCEP guidelines

Parameter	Normal	Desirable	Borderline	High
Total cholesterol	<200		200-239	240
Triglycerides	<150	150-199	200-499	500
LDL	Optimal <100 Near Optimal 100-129	130-159	160-180	190
HDL	<40 : LOW 60 : HIGH			

BUN/Creatinine ratio

Bun (blood urea nitrogen)	12.40	mg/dl	8.9-21.6
CREATININE	0.90	mg/dl	0.30-1.10
BUN/Creatinine ratio	13.78		10.0 - 20.0

ENDOCRINOLOGY

THYROID PROFILE(T3,T4,TSH)

Checked By.

DR. NITIN AGARWAL
MBBS,MD(PATHOLOGIST)

47, Harsh Vihar, Pitampura, New Delhi-110034 | Ph.: 011-42480101, 9599913051

E-mail: oneplusul@gmail.com | Web.: www.oneplusul.in

Page 3 of 5

Clinical correlation is essential for final diagnosis. • If test results are unsatisfactory please contact personally or on phone. • This report is for perusal of doctors only. • All disputes Subject to Delhi Jurisdiction only. • Not for medicolegal purposes. • All congenital anomalies in a foetus may not be diagnosed in routine obstetric ultrasound.



OnePLUS Ultrasound Lab

QUALITY FIRST... ALWAYS!

Dr. Nitin Agarwal
Pathologist & Director
Ex. Sr. Res. MAMC
& Lok Nayak Hospital
Ex. Chief of Lab Dr. Lal Path Labs.

Dr. Pooja (Garg) Agarwal
Radiologist & Director
MAMC & Lok Nayak Hospital



NAME	:Mr. NEERAJ AGGARWAL	Barcode No	:10137657
AGE/GENDER	:42 YRS/Male	SPECIMEN DATE	:11/Feb/2023 09:16AM
PATIENT ID	:109047	SPECIMEN RECEIVED	:11/Feb/2023 10:41AM
REFERRED BY	:Dr. MEDIWHEEL	REPORT DATE	:11/Feb/2023 02:11PM
CENTRE NAME	:ONEPLUS ULTRASOUND LAB	LAB NO.	:012302110014

Test Name	Result	Unit	Ref. Range
Triiodothyronine total [t3]	0.94	ng/dl	0.52-1.9
Thyroxine total [t4]	8.20	µg/dl	4.4 - 10.8
TSH (Thyroid Stimulating Hormone)	1.99	µIU/ml	0.25-5.0

AGE WISE VARIATION IN TSH

AGE	TSH(µIU/ml)	AGE	TSH(µIU/ml)
1-4 weeks	1.00 - 19.0	16-20 yrs	0.25 - 5.0
1-12 mths	1.70 - 9.1	21 - 80 yrs	0.25 - 5.0
1-5 yrs	0.80 - 8.2	I st trimester	0.25 - 5.0
6-10 yrs	0.25 - 5.0	II nd trimester	0.50 - 5.0
11-15 yrs	0.25 - 5.0	III rd trimester	0.4 - 6.0

Reference ranges - Interpretation of Diagnostic tests - (Jacques Wallach)

1. Primary hypothyroidism is accompanied by depressed serum T3 and T4 values and elevated serum TSH level.
2. Primary hyperthyroidism is accompanied by elevated serum T3 and T4 levels along with depressed TSH values.
3. Slightly elevated T3 levels may be found in pregnancy and estrogen therapy, while depressed levels may be encountered in severe illness, renal failure and during therapy with drugs like propranolol and propyl thiouracil.
4. Although elevated TSH levels are nearly always indicative of primary hypothyroidism, and may be seen in secondary thyrotoxicosis

CLINICAL PATHOLOGY

URINE ROUTINE

Physical examination

Quantity	20	ML
Colour	PALE YELLOW	
Transparency	CLEAR	CLEAR
Sp.gravity	1.015	1.010-1.030
pH	7.50	
Reaction	ACIDIC	ACIDIC

Chemical examination

Urine protein	NIL	NIL
Urine sugar	NIL	NIL

Checked By.

DR. NITIN AGARWAL
MBBS,MD(PATHOLOGIST)

47, Harsh Vihar, Pitampura, New Delhi-110034 | Ph.: 011-42480101, 9599913051

E-mail: oneplusul@gmail.com | Web.: www.oneplusul.in

Page 4 of 5



OnePLUS Ultrasound Lab

QUALITY FIRST... ALWAYS!

Dr. Nitin Agarwal
Pathologist & Director
Ex. Sr. Res. MAMC
& Lok Nayak Hospital
Ex. Chief of Lab Dr. Lal Path Labs.

Dr. Pooja (Garg) Agarwal
Radiologist & Director
MAMC & Lok Nayak Hospital



NAME	:Mr. NEERAJ AGGARWAL	Barcode No	:10137657
AGE/GENDER	:42 YRS/Male	SPECIMEN DATE	:11/Feb/2023 09:16AM
PATIENT ID	:109047	SPECIMEN RECEIVED	:11/Feb/2023 10:41AM
REFERRED BY	:Dr. MEDIWHEEL	REPORT DATE	:11/Feb/2023 02:11PM
CENTRE NAME	:ONEPLUS ULTRASOUND LAB	LAB NO.	:012302110014

Test Name	Result	Unit	Ref. Range
Bilirubin, urine	NEGATIVE		NEGATIVE
Urobilinogen	NORMAL		NORMAL
Ketones	NEGATIVE		NEGATIVE
Microscopic examination			
Pus cells.	1-2	/HPF	0-2
Epithelial cells	1-2	/HPF	NIL
R.B.C.	NIL	/HPF	NIL
Casts	NIL	/HPF	NIL
Crystals	NIL	/HPF	NIL
Bacteria	NIL	/HPF	NIL
Others.	NIL	NIL	NIL

*** End Of Report ***

Checked By.

DR. NITIN AGARWAL
MBBS,MD(PATHOLOGIST)

47, Harsh Vihar, Pitampura, New Delhi-110034 | Ph.: 011-42480101, 9599913051
E-mail: oneplusul@gmail.com | Web.: www.oneplusul.in

Page 5 of 5

Clinical correlation is essential for final diagnosis. • If test results are unsatisfactory please contact personally or on phone. • This report is for perusal of doctors only.
• All disputes Subject to Delhi Jurisdiction only. • Not for medicolegal purposes. • All congenital anomalies in a foetus may not be diagnosed in routine obstetric ultrasound.

ONEPLUS ULTRASOUND LAB

47, HARSH VIHAR, PITAMPURA, DELHI- 110034

Mr. NEERAJ AGGARWAL
 Age : 42/M
 Ref. by : MEDIWHEEL
 Indication1 :
 Indication2 :
 Indication3 :
 COMMENTS :

ID : 2104
 H/WV : 168/85
 Recorded : 11-2-2023 10:49
 Medication1 :
 Medication2 :
 Medication3 :

BPM : 83
 BP : 122/82
 P Axis : 62 deg
 QRS Axis : 52 deg
 T Axis : 67 deg

P duration : 100 msec
 PR duration : 140 msec
 QRS duration : 113 msec
 QT interval : 320 msec
 QTc interval : 360 msec

Raw E.C.G.(Seq)

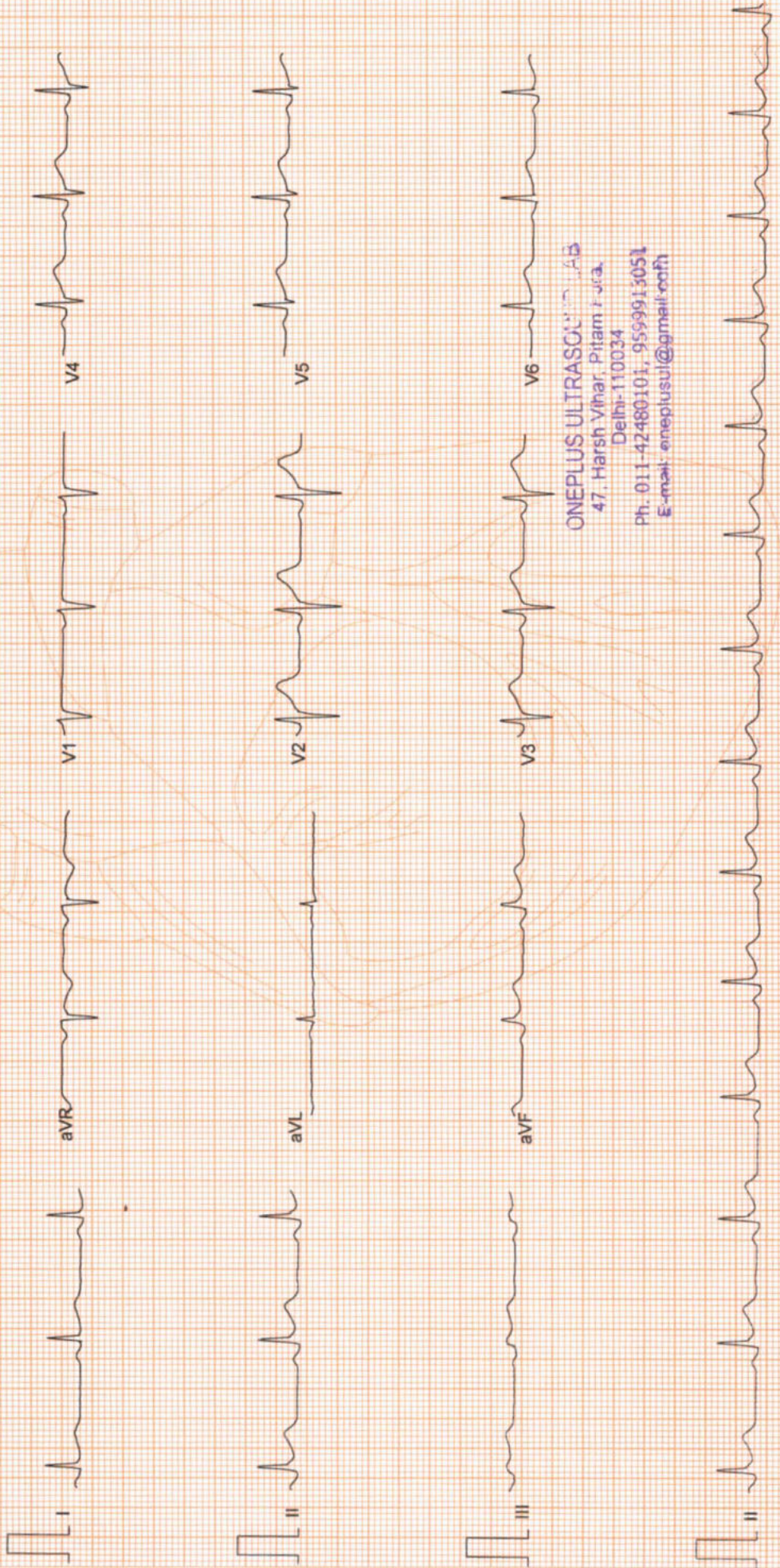
Dr. A. GUPTA
 MBBS, MD
 Reg. No: 1071

Unconfirmed Report Reviewed By:

Cardiologist

WNL

dgaw



ONEPLUS ULTRASOUND LAB
 47, Harsh Vihar, Pitam Pura,
 Delhi-110034
 Ph. 011-42480101, 9599913051
 E-mail: oneplusul@gmail.com

ONEPLUS ULTRASOUND LAB

47, HARSH VIHAR PITAMPURA DELHI 110034

Mr. NEERAJ AGGARWAL
 Age/Sex : 42/M
 Ref. by : MEDIWHEEL
 Indication1 :
 Indication2 :
 Indication3 :

ID : 993
 H/W : 168/85
 Recorded : 11-2-2023 10:52

TREADMILL TEST SUMMARY REPORT
 Protocol: BRUCE
 History:
 Medication1 :
 Medication2 :
 Medication3 :

PHASE	PHASE TIME	STAGE TIME	SPEED (Km./Hr.)	GRADE (%)	H.R. (BPM)	B.P. (mmHg)	RPP X100	II	ST LEVEL (mm) V2	V5	METS
SUPINE STANDING					86 92	122/82 122/82	104 112	1.2 1.3	1.1 0.9	0.6 0.7	
STAGE 1	2:59	2:59	2.70	10.00	102	122/82	124	1.3	1.6	1.2	4.80
STAGE 2	5:59	2:59	4.00	12.00	118	136/84	160	1.3	1.5	1.2	7.10
STAGE 3	8:59	2:59	5.40	14.00	148	150/88	222	0.9	1.4	0.8	10.00
STAGE 4	9:29	0:29	6.70	16.00	169	160/90	270	0.9	0.8	0.6	10.65
PEAK EXER	9:31	0:31			168	160/90	268	0.9	0.8	0.6	10.69
RECOVERY	2:59	2:59	0.00	0.00	110	124/82	136	0.7	0.9	0.6	

RESULTS

Exercise Duration : 9:31 Minutes
 Max Heart Rate : 169 bpm 94 % of target heart rate 178 bpm
 Max Blood Pressure : 160/90 mmHg
 Max Work Load : 10.69 METS
 Reason of Termination :

IMPRESSIONS

: Negative for Ischemic Ishm.

Dr. P.K. GUPTA
 MBBS MD
 Cardiologist 011

[Signature]

ONEPLUS ULTRASOUND Lab
 47, Harsh Vihar, Pitam Pura,
 Delhi-110034
 Ph: 011-42480101, 9599913051
 E-mail: oneplusul@gmail.com

ONEPLUS ULTRASOUND LAB

Mr. NEERAJ AGGARWAL
I.D. : 993

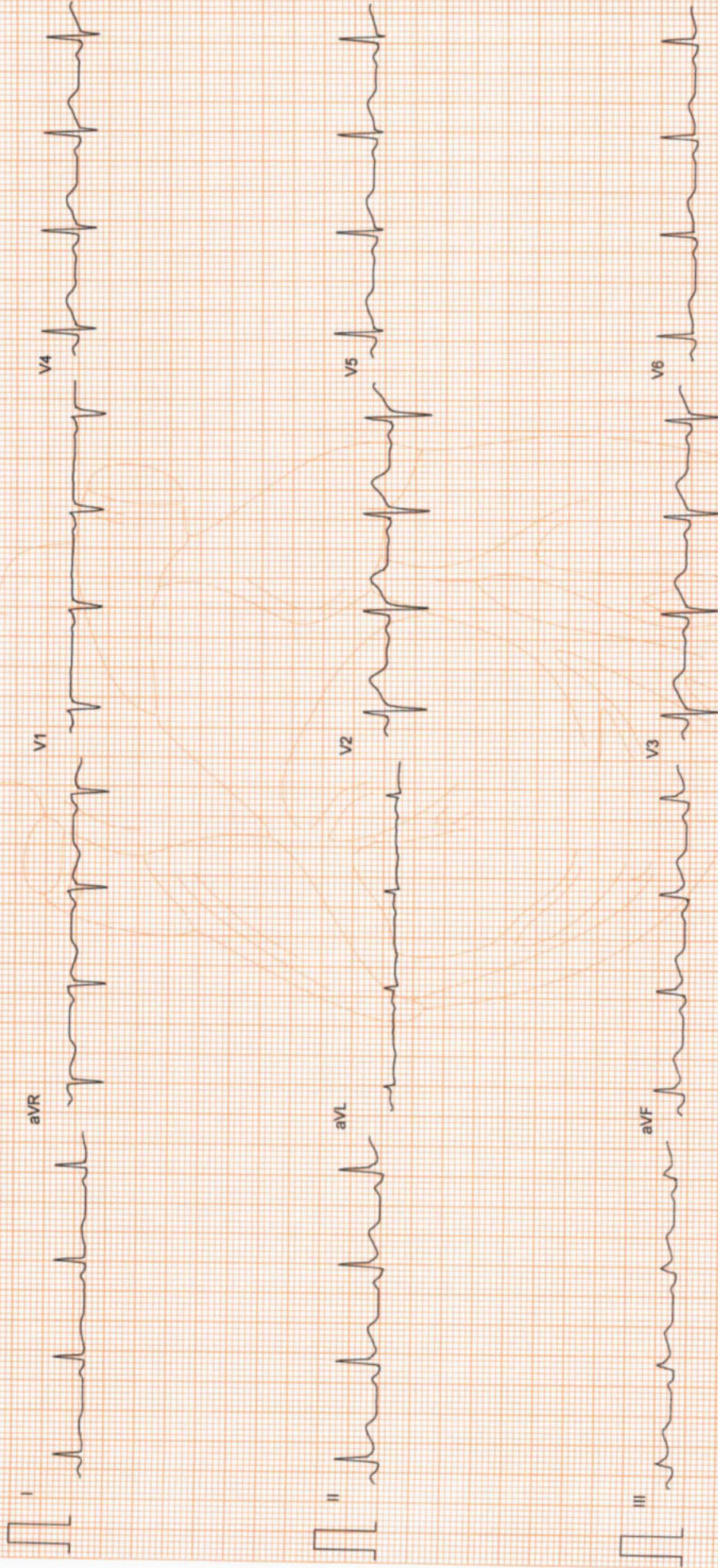
SUPINE
PRETEST

ST @ 10mm/mV
80ms PostJ

RATE : 86 BPM
B.P. : 122/82 mmHg

RECORDED : 11-2-2023 10:52

RAW E.C.G.



ONEPLUS ULTRASOUND LAB

47, Harsh Vihar, Pitam Pura
Delhi-110034

Ph: 011-42480101, 9599913051

E-mail: oneplusul@gmail.com

ONEPLUS ULTRASOUND LAB

Mr. NEERAJ AGGARWAL

I.D. : 993

AGE/SEX : 42/M

RECORDED : 11-2-2023 10:52

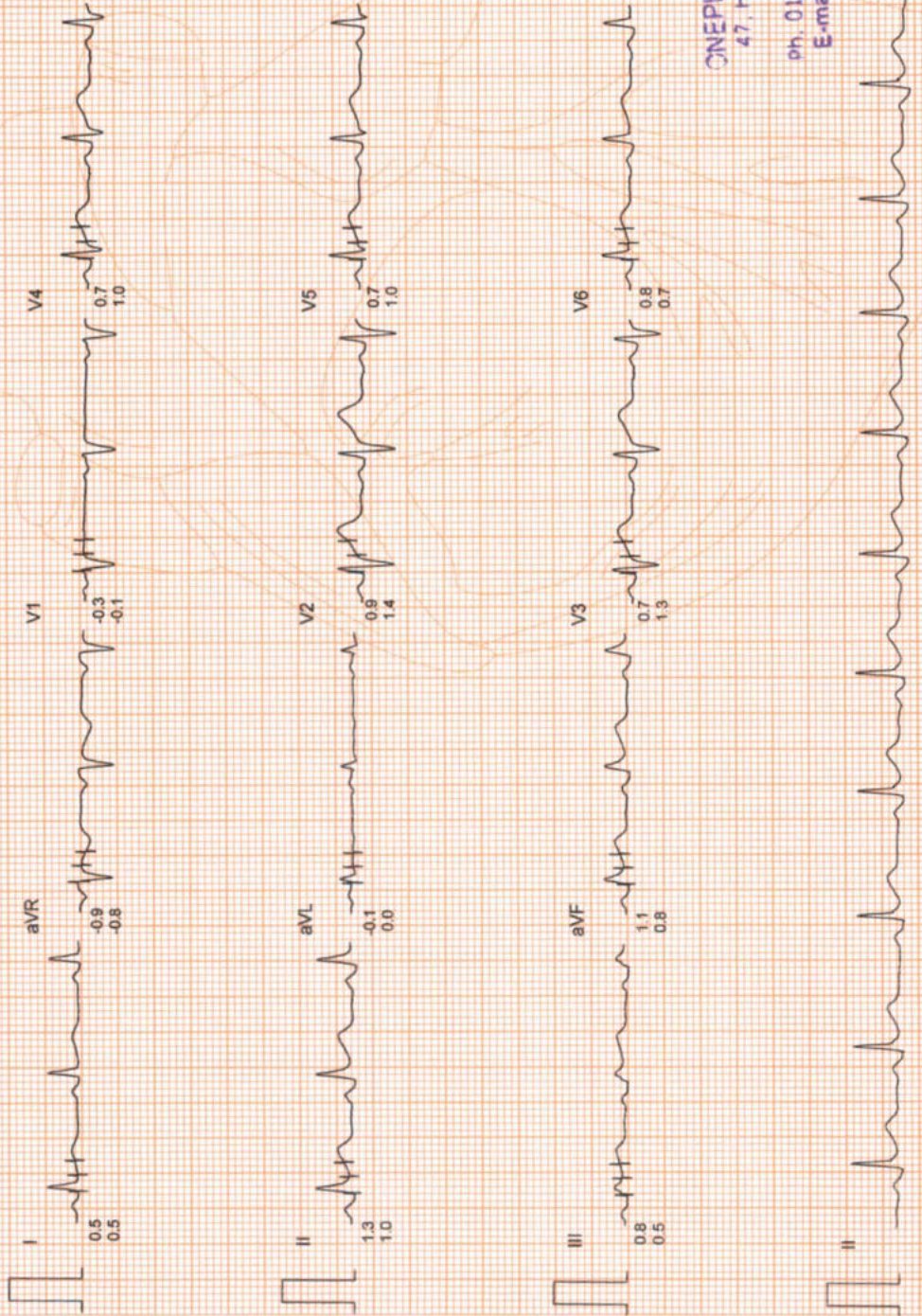
RATE : 92 BPM

B.P. : 122/82 mmHg

ST @ 10mm/mV

80ms PostJ

LINKED MEDIAN



ONEPLUS ULTRASOUND L&C
47, Harsh Vihar, Pitam Pura,
Delhi-110034
ph. 011-42480101, 9599913051
E-mail: oneplusul@gmail.com

ONEPLUS ULTRASOUND LAB

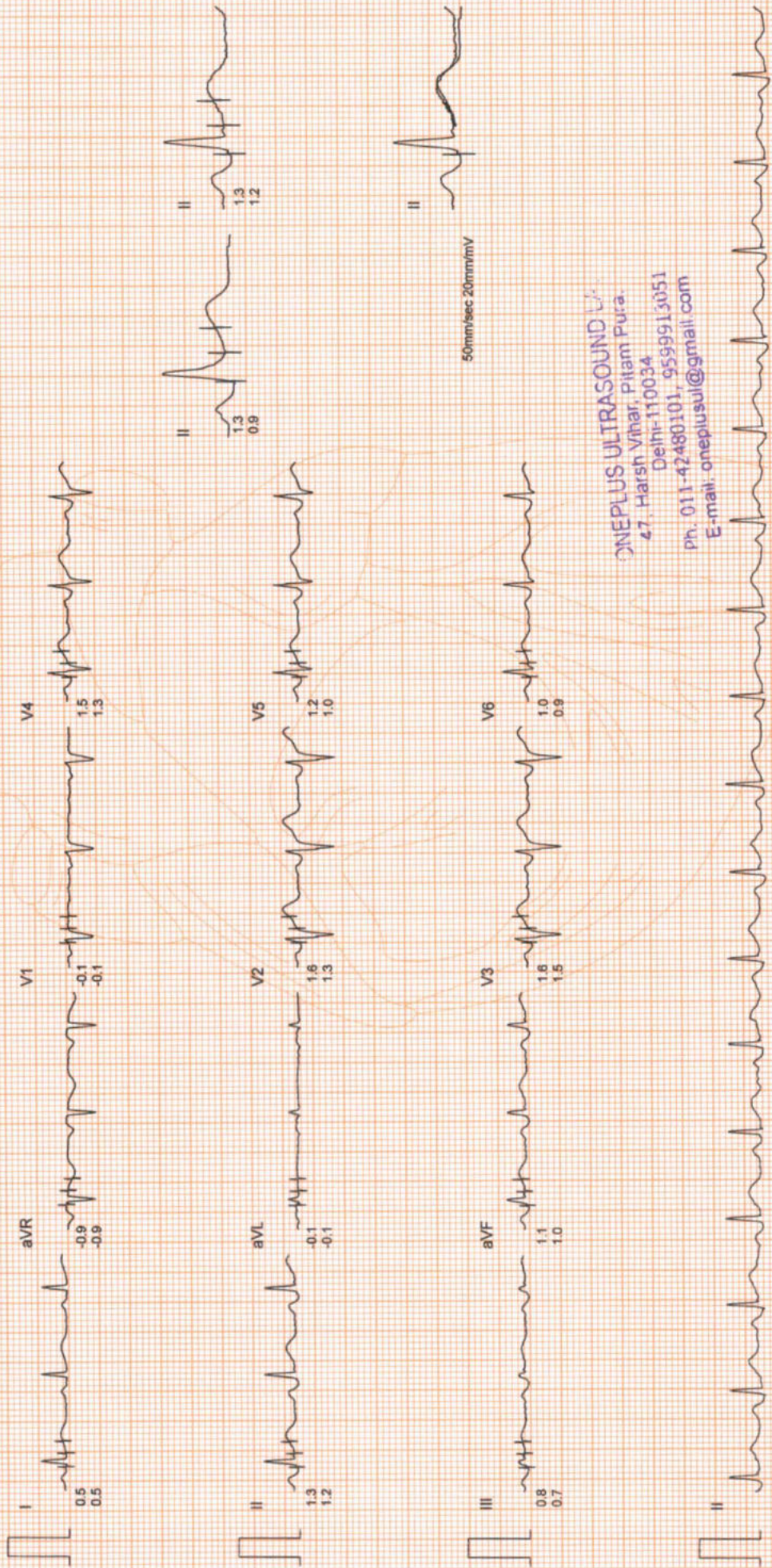
Mr. NEERAJ AGGARWAL
I.D. : 993

AGE/SEX : 42/M
RECORDED : 11-2-2023 10:52

BRUCE
EXERCISE 1
PHASE TIME : 2:59
STAGE TIME : 2:59

ST @ 10mm/mV
80ms PostJ
SPEED : 2.7 Km./Hr.
GRADE : 10.0 %

LINKED MEDIAN



ONEPLUS ULTRASOUND Lab.
47, Harsh Vihar, Pitam Pura,
Delhi-110034
Ph. 011-42480101, 9599913051
E-mail: oneplusul@gmail.com

ONEPLUS ULTRASOUND LAB

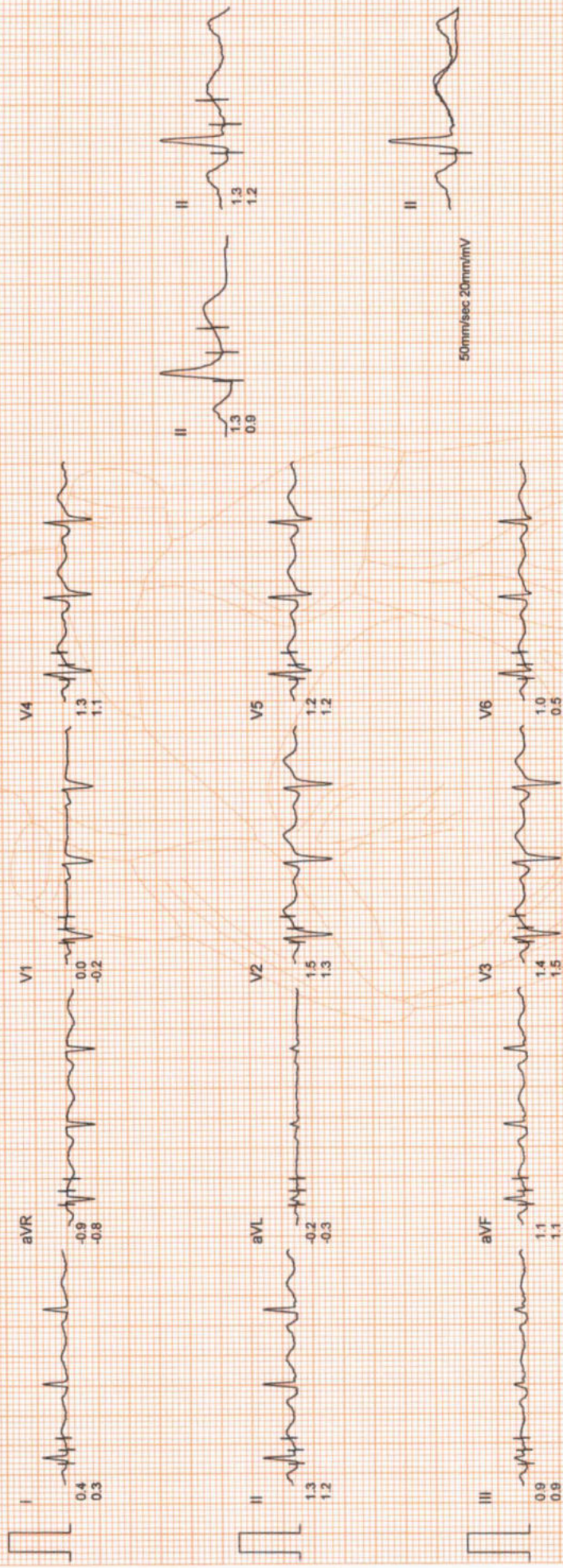
Mr. NEERAJ AGGARWAL
I.D. : 993

AGE/SEX : 42/M
RECORDED : 11-2-2023 10:52

BRUCE
EXERCISE 2
PHASE TIME : 5:59
STAGE TIME : 2:59

ST @ 10mm/mV
80ms PostJ
SPEED : 4.0 Km./Hr.
GRADE : 12.0 %

LINKED MEDIAN



ONEPLUS ULTRASOUND
47, Harsh Vihar, Pitam F.C.S.
Delhi-110034
Ph. 011-42480101, 9599913051
E-mail: oneplusul@gmail.com

Handwritten signature/initials across the bottom of the page.

ONEPLUS ULTRASOUND LAB

Mr. NEERAJ AGGARWAL

I.D. : 993

AGE/SEX : 42/M

RECORDED : 11-2-2023 10:52

RATE : 148 BPM

B.P. : 150/88 mmHg

BRUCE
EXERCISE 3

PHASE TIME : 8:59

STAGE TIME : 2:59

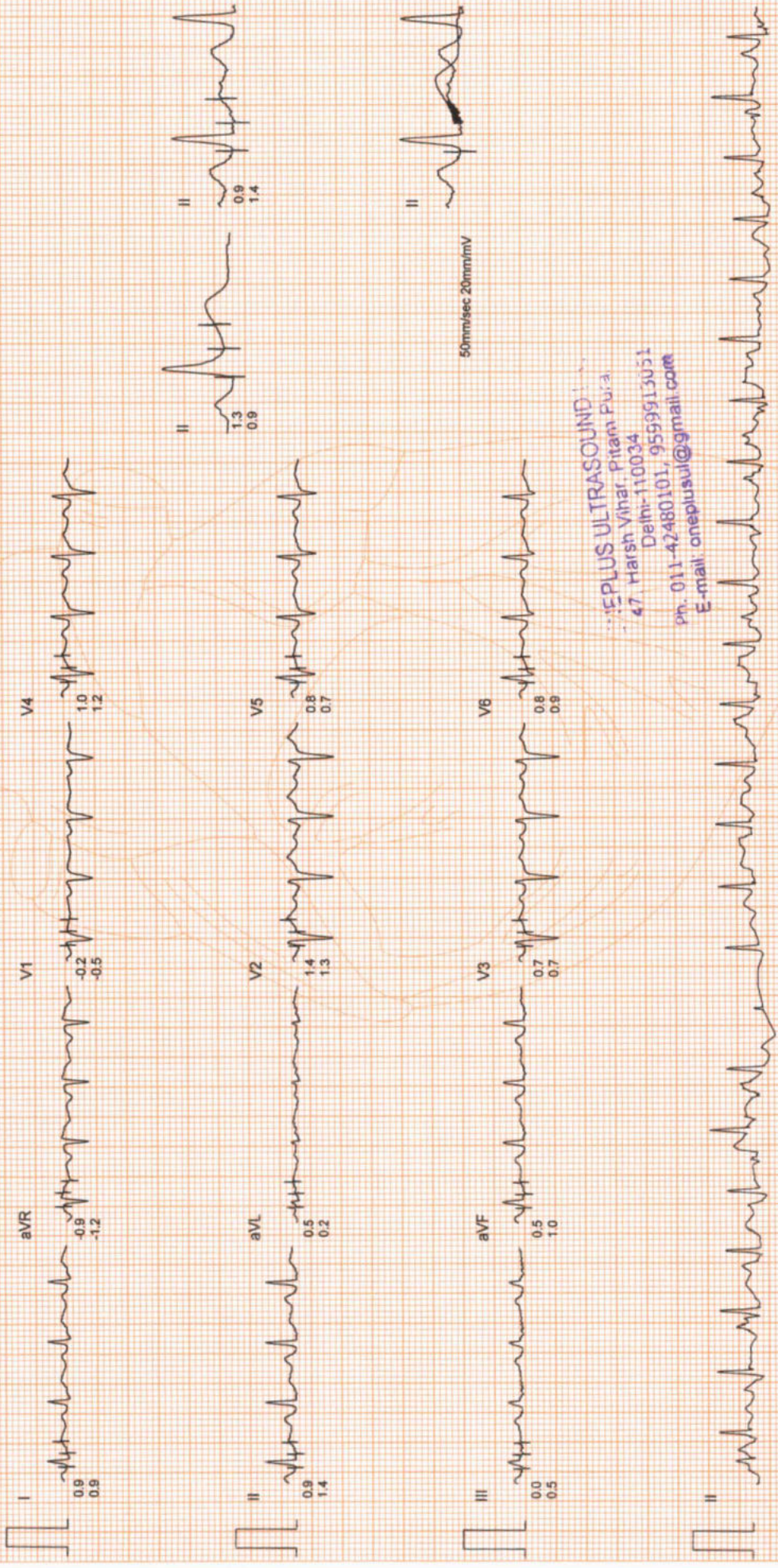
ST @ 10mm/mV

80ms PostJ

SPEED : 5.4 Km./Hr.

GRADE : 14.0 %

LINKED MEDIAN



ONEPLUS ULTRASOUND
47, Harsh Vihar, Pitam Pura,
Delhi-110034
Ph. 011-42480101, 9559913051
E-mail: oneplusul@gmail.com

ONEPLUS ULTRASOUND LAB

Mr. NEERAJ AGGARWAL

I.D. : 993

AGE/SEX : 42/M

RECORDED : 11-2-2023 10:52

RATE : 169 BPM

B.P. : 160/90 mmHg

BRUCE
EXERCISE 4

PHASE TIME : 9:29

STAGE TIME : 0:29

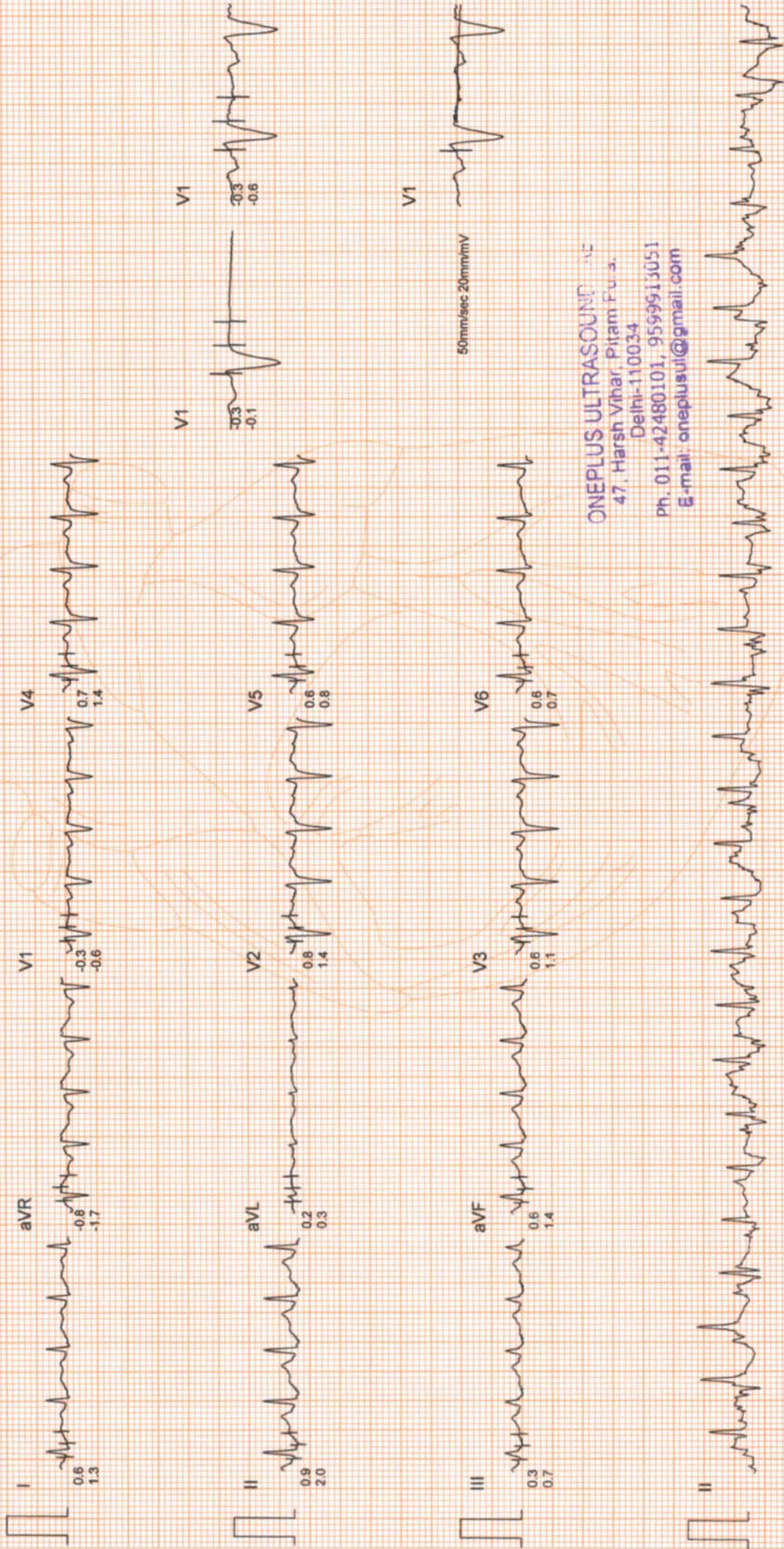
ST @ 10mm/mV

80ms PostJ

SPEED : 6.7 Km./Hr.

GRADE : 16.0 %

LINKED MEDIAN



ONEPLUS ULTRASOUND LAB

47, Harsh Vihar, Pitam P.S.

Delhi-110034

Ph. 011-42480101, 9599913051

E-mail: oneplusul@gmail.com

ONEPLUS ULTRASOUND LAB

Mr. NEERAJ AGGARWAL

I.D. : 993

AGE/SEX : 42/M

RECORDED : 11-2-2023 10:52

RATE : 168 BPM

B.P. : 160/90 mmHg

BRUCE

PEAK EXER

PHASE TIME : 9:31

STAGE TIME : 0:31

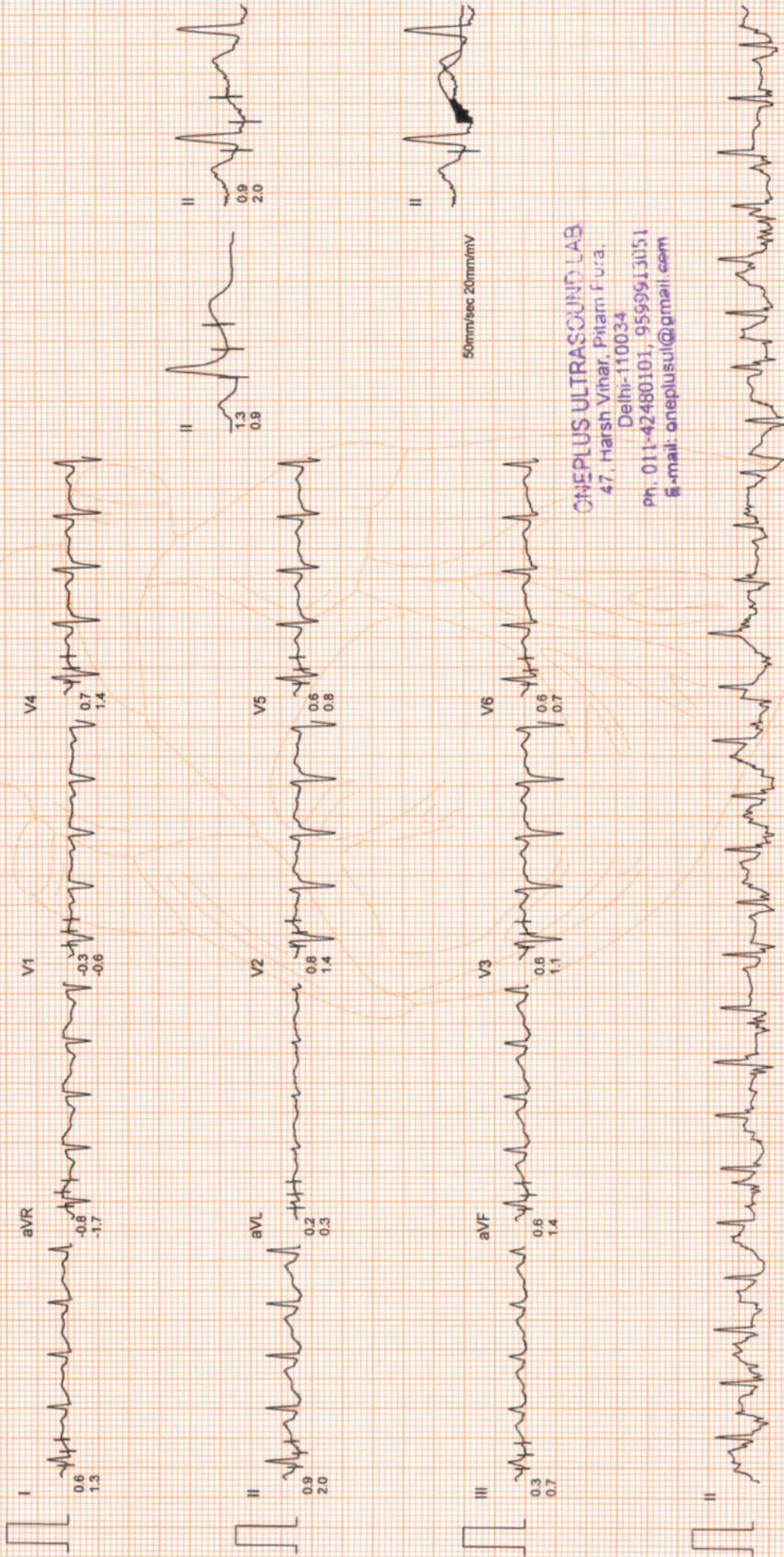
ST @ 10mm/mV

80ms PostJ

SPEED : 6.7 Km./Hr.

GRADE : 16.0 %

LINKED MEDIAN



50mm/sec 20mm/mV

ONEPLUS ULTRASOUND LAB

47, Harsh Vihar, Pitam Pura,

Delhi-110034

Ph. 011-42480101, 9599913051

E-mail: oneplusul@gmail.com

ONEPLUS ULTRASOUND LAB

Mr. NEERAJ AGGARWAL

I.D. : 993

AGE/SEX : 42/M

RECORDED : 11-2-2023 10:52

RATE : 110 BPM

B.P. : 124/82 mmHg

BRUCE
RECOVERY

PHASE TIME : 2:59

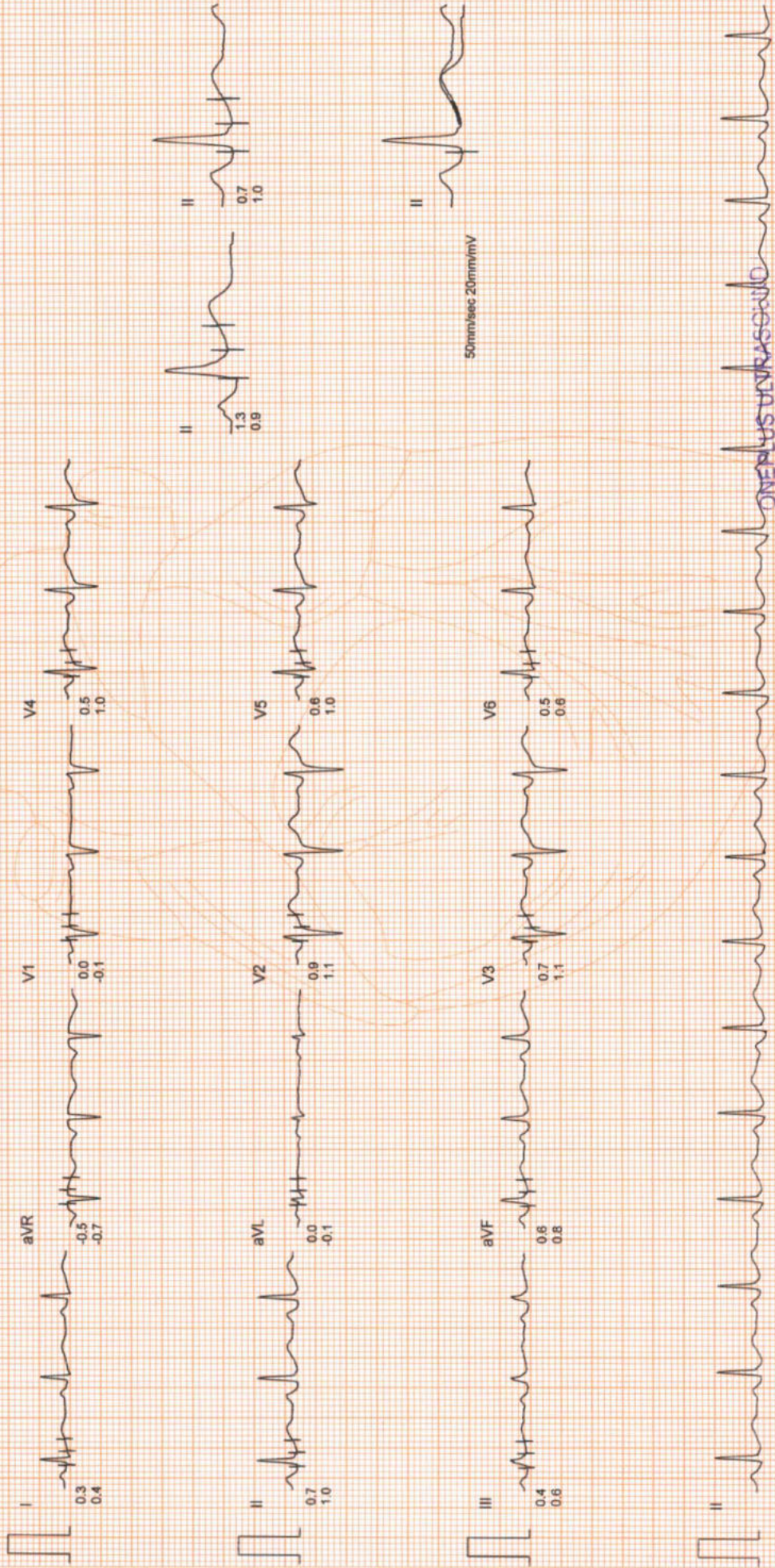
ST @ 10mm/mV

80ms PostJ

SPEED : 0.0 Km./Hr.

GRADE : 0.0 %

LINKED MEDIAN



ONEPLUS ULTRASOUND
47, Harsh Vihar, Pitam Pū
Delhi-110034
Ph. 011-42480101, 9559511111
E-mail: oneplusul@gmail.com

ONEPLUS ULTRASOUND LAB

Mr. NEERAJ AGGARWAL

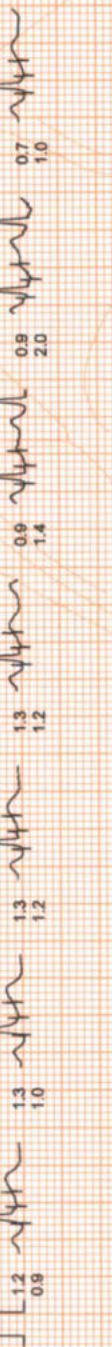
I.D. : 993

AGE/SEX : 42/M

RECORDED : 11-2-2023 10:52

AVG E.C.G.

SUPINE	STANDING	STAGE 1	STAGE 2	STAGE 3	PEAK EXERCISE	RECOVERY
0.0Kmph 0.0% 86 bpm B.P. 122/82 80ms PostU	0.0Kmph 0.0% 92 bpm B.P. 122/82 80ms PostU	2:59 2:59 2.7Kmph 10.0% 102 bpm B.P. 122/82 80ms PostU	5:59 2:59 4.0Kmph 12.0% 118 bpm B.P. 136/84 80ms PostU	8:59 2:59 5.4Kmph 14.0% 148 bpm B.P. 150/88 80ms PostU	9:31 0:31 6.7Kmph 16.0% 168 bpm B.P. 160/90 80ms PostU	2:59 0.0Kmph 0.0% 110 bpm B.P. 124/82 80ms PostU



ONEPLUS ULTRASOUND L.A.
47, Harsh Vihar, Pitam Pur, Delhi-110034
Ph. 011-42480101, 9599913951
E-mail: oneplusul@gmail.com

ONEPLUS ULTRASOUND LAB

Mr. NEERAJ AGGARWAL

I.D. : 993


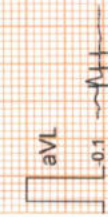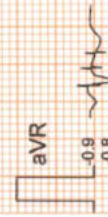
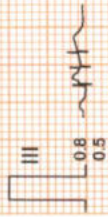
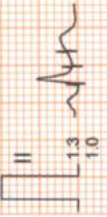
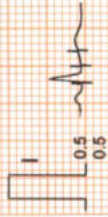
AGE/SEX : 42/M

RECORDED : 11-2-2023 10:52

COMPARISON REPORT

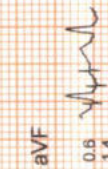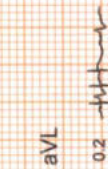
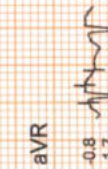
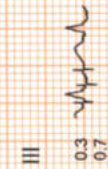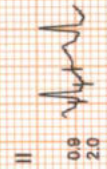
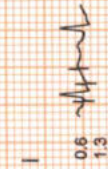STANDING

0.0Kmph
0.0%
92 bpm
B.P. 122/62
80ms PostJ



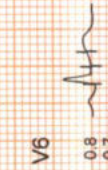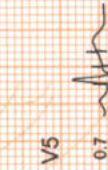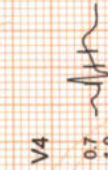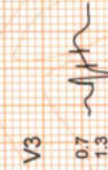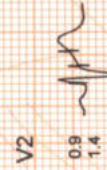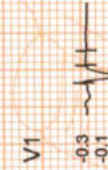
PEAK EXERCISE

9:31
0:31
6.7Kmph
16.0%
168 bpm
B.P. 160/90
80ms PostJ



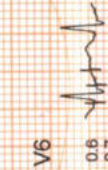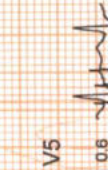
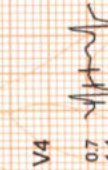
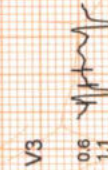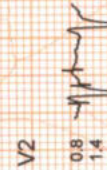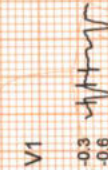STANDING

0.0Kmph
0.0%
92 bpm
B.P. 122/62
80ms PostJ



PEAK EXERCISE

9:31
0:31
6.7Kmph
16.0%
168 bpm
B.P. 160/90
80ms PostJ



ONEPLUS ULTRASOUND
47, Harsh Vihar, Pitam Pura
Delhi-110034
Ph. 011-42480101, 9599513131
E-mail: oneplusul@gmail.com