



PRE – EMPLOYMENT HEALTH CHECK UP REPORT

DATE - 26/11/22

PATIENT NAME - Mr Ankur Gupta AGE - 31 yr GENDER - M
WEIGHT(KG) - 94.1 kg HEIGHT - 177 cm
PHYSICAL EXAMINATION

PULSE

BP 180/90

BLOOD SUGAR(RANDOM)

FINDINGS

INVESTIGATIONS : Investigation reports are attached

FITNESS CERTIFICATE



SIGNATURE

(This is only professional opinion and not the diagnosis, Please correlate clinically)

Q Block South City 11, Sohna Road, Main Sector-47, Gurgaon, Haryana
Ph.: 0124-4900000 (100 Lines) Fax : 0124-2218733 E-mail : parkmedicenters@gmail.com

PARK GROUP OF HOSPITALS : West Delhi • South Delhi • Gurgaon • Karnal • Panipat • Hodal • Ambala • Behror

the **health** care providers

the **health** care providers



Mr. Ankur Gupta

31/11

Vitals :

BP = 130/90

WT = 94.1 kg

HT = 171 cm

Chief Complaints :

clo anxiety
Lethargy.
H/O Hypertension, not on regular
treatment.

H/O Present Illness :

Vaccinated for covid.

Past History :

OIE

Investigation :

ECG - Normal
Sinus rhythm.

Drug Allergies : (if any)

Pt is safe.

P.O.E.

Treatment :

Chest - B/L vesicular breath sounds
o/s - S1 S2 (+)

BP - 130/90 mm of Hg.

Adv



1. Tab Neurokind gold 1 Tab od x 10 days.
2. Tab Esopam lite (10/0.25) 1 Tb x 5 day.
3. Review with reports

[Signature]



Ophthalm



Pt. Name - Gupta Anur.

age - 84/14.

Dr. Anur Anur.

date - 26/11/22

Health checkup

Vitals :

Chief Complaints :

vn { 6/6
 glasses.

H/O Present Illness :

6/6.

NOCTA { 19
 - 19

Past History :

NU { 10/6
 glasses.

Investigation :

Drug Allergies : (if any)

Treatment :

Calcare vision - normal.

Fundus - Normal



[Signature]



DEPARTMENT OF PATHOLOGY

Patient Name : Mr. ANKUR GUPTA
 MR No : 666669 Bill Date : 26/11/2022
 Age/Sex : 31 Years 10 Months 13 Days / Male Reporting Date : 26/11/2022
 Type : OPD Sample ID : 66654
 TPA/Corporate : MEDIWHEEL PVT LTD Bill/Req. No. : 22998690
 Ref Doctor : Dr.RMO

Test	Result	Bio. Ref. Interval	Units
THYROID PROFILE			
TRI-IODOTHYRONINE (T3)	0.86	0.60 - 1.81	ng/ml
THYROXINE (T4)	5.1	5.01 - 12.45	µg/dL
THYROID STIMULATING HORMONE (TSH)	3.83	0.5-5.50	µIU/ml
SPECIMEN TYPE	SERUM		

Method : chemiluminescent immunoassay

Note : Clinical Significance:

Thyroid function tests (TFTs) is a collective term for blood tests used to check the function of the thyroid. TFTs may be requested if a patient is thought to suffer from hyperthyroidism (overactive thyroid) or hypothyroidism (underactive thyroid), or to monitor the effectiveness of either thyroid-suppression or hormone replacement therapy. It is also requested routinely in conditions linked to thyroid disease, such as atrial fibrillation and anxiety disorder. A TFT panel typically includes thyroid hormones such as thyroid-stimulating hormone (TSH, thyrotropin) and thyroxine (T4), and triiodothyronine (T3) depending on local laboratory policy.

Note: Please correlate with clinical condition

***** END OF THE REPORT *****



Sample no.

Dr. NALANDA BUKTARE
MD (Pathology)

Dr. PRADIP KUMAR
Consultant (Microbiology)

Dr. NISHA TIWARI
 MBBS, MD (Microbiology)
 USER NM DINESH

(This is only professional opinion and not the diagnosis, Please correlate clinically) Page 1 of 1

Q Block South City 11, Sohna Road, Main Sector-47, Gurgaon, Haryana
 Ph.: 0124-4900000 (100 Lines) Fax : 0124-2218733 E-mail : parkmedicenters@gmail.com

PARK GROUP OF HOSPITALS : West Delhi • South Delhi • Gurgaon • Karnal • Panipat • Hodal • Ambala • Behror



DEPARTMENT OF PATHOLOGY

Patient Name : Mr. ANKUR GUPTA
MR No : 666689
Age/Sex : 31 Years 10 Months 13 Days / Male
Type : OPD
TPA/Corporate : MEDIWHEEL PVT LTD
Bill Date : 26/11/2022
Reporting Date : 26/11/2022
Sample ID : 68654
Bill/Req. No. : 22998690
Ref Doctor : Dr.RMO

Test	Result	Bio. Ref. Interval	Units
THYROID PROFILIE			
TRI-IODOTHYRONINE (T3)	0.86	0.60 - 1.81	ng/ml
THYROXINE (T4)	5.1	5.01 - 12.45	µg/dL
THYROID STIMULATING HORMONE (TSH)	3.83	0.5-5.50 ,	µIU/ml
SPECIMEN TYPE	SERUM		
Method : chemiluminescent immunoassay			

Note : Clinical Significance:

Thyroid function tests (TFTs) is a collective term for blood tests used to check the function of the thyroid. TFTs may be requested if a patient is thought to suffer from hyperthyroidism (overactive thyroid) or hypothyroidism (underactive thyroid), or to monitor the effectiveness of either thyroid-suppression or hormone replacement therapy. It is also requested routinely in conditions linked to thyroid disease, such as atrial fibrillation and anxiety disorder. A TFT panel typically includes thyroid hormones such as thyroid-stimulating hormone (TSH, thyrotropin) and thyroxine (T4), and triiodothyronine (T3) depending on local laboratory policy.

Note: Please correlate with clinical condition

***** END OF THE REPORT *****



Sample no.

Dr. NALANDA BUKTARE
MD (Pathology)

Dr. PRADIP KUMAR
Consultant (Microbiology)

Nisha
Dr. NISHA TIWARI
MBBS, MD (Microbiology)
USER NM DINESH

(This is only professional opinion and not the diagnosis, Please correlate clinically) Page 1 of 1

Q Block South City 11, Sohna Road, Main Sector-47, Gurgaon, Haryana
Ph.: 0124-4900000 (100 Lines) Fax : 0124-2218733 E-mail : parkmedicenters@gmail.com

PARK GROUP OF HOSPITALS : West Delhi • South Delhi • Gurgaon • Karnal • Panipat • Hodal • Ambala • Behror



DEPARTMENT OF PATHOLOGY

Patient Name : Mr. ANKUR GUPTA
MR No : 666689
Age/Sex : 31 Years 10 Months 13 Days / Male
Type : OPD
TPA/Corporate : MEDIWHEEL PVT LTD

Bill Date : 26/11/2022
Reporting Date : 30/11/2022
Sample ID : 68654
Bill/Req. No. : 22998690
Ref Doctor : Dr.RMO

Test	Result	Bio. Ref. Interval	Units	Method
URINE C/S				

NAME OF SPECIMEN	URINE	Aerobic cl
ORGANISM IDENTIFIED	NO GROWTH SEEN IN CULTURE AFTER 48 HRS OF INCUBATION AT 37 C DEGREE	

Method : .

Note : .

***** END OF THE REPORT *****



Sample no.

Dr. SONIA KUMARI
MBBS, MD (PATHOLOGY) Gold medalist

Dr. PRADIP KUMAR
Consultant (Microbiology)

Dr. NISHA TIWARI
MBBS, MD (Microbiology)

(This is only professional opinion and not the diagnosis, Please correlate clinically)

USER NM

Q Block South City 11, Sohna Road, Main Sector-47, Gurgaon, Haryana
Ph.: 0124-4900000 (100 Lines) Fax : 0124-2218733 E-mail : parkmedicenters@gmail.com

PARK GROUP OF HOSPITALS : West Delhi • South Delhi • Gurgaon • Karnal • Panipat • Hodal • Ambala • Behror



DEPARTMENT OF PATHOLOGY

Patient Name :	Mr. ANKUR GUPTA	Bill Date :	26/11/2022
MR No :	666689	Reporting Date :	26/11/2022
Age/Sex :	31 Years 10 Months 13 Days / Male	Sample ID :	68654
Type :	OPD	Bill/Req. No. :	22998690
TPA/Corporate :	MEDIWHEEL PVT LTD	Ref Doctor :	Dr.RMO

Test	Result	Bio. Ref. Interval	Units	Method
BLOOD SUGAR 2 HR. PP				
BLOOD SUGAR P.P.	108	80 - 150	mg/dl	

***** END OF THE REPORT *****



Sample no.

Dr. SONIA KUMARI
MBBS, MD (PATHOLOGY) Gold medalist

Dr. PRADIP KUMAR
Consultant (Microbiology)

Dr. NISHA TIWARI
MBBS, MD (Microbiology)

USER NM NEERAJPA7

(This is only professional opinion and not the diagnosis, Please correlate clinically)

Q Block South City-11, Sohna Road, Main Sector-47, Gurgaon, Haryana
Ph.: 0124-4900000 (100 Lines) Fax : 0124-2218733 E-mail : parkmedicenters@gmail.com Page 1 of 1

PARK GROUP OF HOSPITALS : West Delhi • South Delhi • Gurgaon • Karnal • Panipat • Hodal • Ambala • Behror



Cart No. MC - 4830

Cart No. H-2515-5389

DEPARTMENT OF PATHOLOGY

Patient Name : Mr. ANKUR GUPTA
MR No : 666689
Age/Sex : 31 Years 10 Months 13 Days / Male
Type : OPD
TPA/Corporate : MEDIWHEEL PVT LTD

Bill Date : 26/11/2022
Reporting Date : 26/11/2022
Sample ID : 66654
Bill/Req. No. : 22098690
Ref Doctor : Dr.RMO

Test	Result	Blo. Ref. Interval	Units	Method
BLOOD SUGAR FASTING				
PLASMA GLUCOSE FASTING	96	60 - 100	mg/dl	GOD TRINDERS

***** END OF THE REPORT *****



Sample no.

Dr. SONIA KUMARI
MBBS, MD (PATHOLOGY) Gold medalist

Dr. PRADIP KUMAR
Consultant (Microbiology)

Dr. NISHA TIWARI
MBBS, MD (Microbiology)

USER NM RAMKISHAN

(This is only professional opinion and not the diagnosis, Please correlate clinically)

Q-Block South City-11, Sohna Road, Main Sector-47, Gurgaon, Haryana
Ph.: 0124-4900000 (100 Lines) Fax : 0124-2218733 E-mail : parkmedicenters@gmail.com Page 1 of 1

PARK GROUP OF HOSPITALS : West Delhi • South Delhi • Gurgaon • Karnal • Panipat • Hodal • Ambala • Behror



DEPARTMENT OF PATHOLOGY

Patient Name : Mr. ANKUR GUPTA
MR No : 666689
Age/Sex : 31 Years 10 Months 13 Days / Male
Type : OPD
TPA/Corporate : MEDIWHEEL PVT LTD

Bill Date : 26/11/2022
Reporting Date : 26/11/2022
Sample ID : 68654
Bill/Req. No. : 22998690
Ref Doctor : Dr.RMO

Test	Result	Bio. Ref. Interval	Units	Method
URINE ROUTINE AND MICROSCOPY				
PHYSICAL CHARACTERISTICS				
QUANTITY	40ml	5 - 100	ml	
COLOUR	Pale Yellow	Pale Yellow		Vishal
TURBIDITY	Clear	clear		
SPECIFIC GRAVITY	1.015	1.000-1.030		urinometer
PH	Acidic	Acidic/Alkaline		PH PAPER
CHEMICAL EXAMINATION-1				
UROBILINOGEN	NIL	NIL		Ehrlich
URINE PROTEIN	NIL	NIL	mg/dl	Protein error indicator
BLOOD	NIL	NIL		
URINE BILIRUBIN	NIL	NIL		
GLUCOSE	NIL	NIL	mg/dL	GOD-POD/Benedicts
URINE KETONE	NIL	NIL		SOD.
MICRO EXAMINATION				
PUS CELL	1-2	0-5	cells/hpf	Microscopic
RED BLOOD CELLS	Nil	0-2	cells/hpf	
EPITHELIAL CELLS	2-4	0-5	cells/hpf	
CASTS	NIL	NIL	/lpf	
CRYSTALS	NIL	NIL	/hpf	
OTHER	NIL			

***** END OF THE REPORT *****



Sample no.

Dr. SONIA KUMARI
MBBS, MD (PATHOLOGY) Gold medalist

Dr. PRADIP KUMAR
Consultant (Microbiology)

Dr. NISHA TIWARI
MBBS, MD (Microbiology)

USER NM RAMKISHAN

(This is only professional opinion and not the diagnosis, Please correlate clinically)

Q Block South City 11, Sohna Road, Main Sector 47, Gurgaon, Haryana

Ph.: 0124-4900000 (100 Lines) Fax : 0124-2218733 E-mail : parkmedicenters@gmail.com Page 1 of 1

PARK GROUP OF HOSPITALS : West Delhi • South Delhi • Gurgaon • Karnal • Panipat • Hodal • Ambala • Behror



DEPARTMENT OF PATHOLOGY

Patient Name :	Mr. ANKUR GUPTA	Bill Date :	26/11/2022
MR No :	666689	Reporting Date :	26/11/2022
Age/Sex :	31 Years 10 Months 13 Days / Male	Sample ID :	68654
Type :	OPD	Bill/Req. No. :	22998690
TPA/Corporate :	MEDIWHEEL PVT LTD	Ref Doctor :	Dr.RMO

Test	Result	Blo. Ref. Interval	Units	Method
BLOOD GROUPING AND RH FACTOR				
BLOOD GROUP	" B " RH POSITIVE			MATRIX GEL

***** END OF THE REPORT *****



Sample no.

Dr. SONIA KUMARI
MBBS, MD (PATHOLOGY) Gold medalist

Dr. PRADIP KUMAR
Consultant (Microbiology)

Dr. NISHA TIWARI
MBBS, MD (Microbiology)

USER NM NEERAJPA

(This is only professional opinion and not the diagnosis, Please correlate clinically)

Q Block South City 11, Sohna Road, Main Sector-47, Gurgaon, Haryana

Ph.: 0124-4900000 (100 Lines) Fax : 0124-2218733 E-mail : parkmedicenters@gmail.com Page 1 of 1

PARK GROUP OF HOSPITALS : West Delhi • South Delhi • Gurgaon • Karnal • Panipat • Hodal • Ambala • Behror

the **health** care providers

the **health** care providers



DEPARTMENT OF PATHOLOGY

Patient Name : Mr. ANKUR GUPTA
MR No : 666689
Age/Sex : 31 Years 10 Months 13 Days / Male
Type : OPD
TPA/Corporate : MEDIWHEEL PVT LTD

Bill Date : 26/11/2022
Reporting Date : 26/11/2022
Sample ID : 68654
Bill/Req. No. : 22998690
Ref Doctor : Dr.RMO

Test	Result	Blo. Ref. Interval	Units	Method
CBC				
HAEMOGLOBIN	14.7	12 - 16	gm/dL	COLORIMETRY
TOTAL LEUCOCYTE COUNT	5400	4000 - 10000	/ μ L	ELECTRICAL
DIFFERENTIAL COUNT				
NEUTROPHILS	56	40.0 - 80.0	%	FLOW CYTOMETRY
LYMPHOCYTES	35	20.0 - 40.0	%	FLOW CYTOMETRY
MONOCYTES	07	2.0 - 10.0	%	FLOW CYTOMETRY
EOSINOPHILS	02	0.0 - 5.0	%	FLOW CYTOMETRY
BASOPHILS	00	0.0 - 2.0	%	FLOW CYTOMETRY
RED BLOOD CELL COUNT	4.7	3.5 - 5.5	millions/ μ L	ELECTRICAL
PACKED CELL VOLUME	42.3	35.0 - 50.0	%	ELECTRICAL
MEAN CORPUSCULAR VOLUME	89.4	83 - 101	fL	ELECTRICAL
MEAN CORPUSCULAR HAEMOGLOBIN	31.1	27 - 31	Picogrammes	CALCULATED
MEAN CORPUSCULAR HB CONC	34.8	33 - 37	g/dl	CALCULATED
PLATELET COUNT	228	150 - 450	thou/ μ L	ELECTRICAL
RDW	12.2	11.6 - 14.5	%	CALCULATED

***** END OF THE REPORT *****



Sample no

Dr. SONIA KUMARI
MBBS, MD (PATHOLOGY) Gold medalist

Dr. PRADIP KUMAR
Consultant (Microbiology)

Dr. NISHA TIWARI
MBBS, MD (Microbiology)

USER NM RAMKISHAN

(This is only professional opinion and not the diagnosis, Please correlate clinically)

G Block South City 11, Sohna Road, Main Sector-47, Gurgaon, Haryana
Ph.: 0124-4900000 (100 Lines) Fax : 0124-2218733 E-mail : parkmedicenters@gmail.com Page 1 of 1

PARK GROUP OF HOSPITALS : West Delhi • South Delhi • Gurgaon • Karnal • Panipat • Hodal • Ambala • Behror



DEPARTMENT OF PATHOLOGY

Patient Name : Mr. ANKUR GUPTA
 MR No : 666689
 Age/Sex : 31 Years 10 Months 13 Days / Male
 Type : OPD
 TPA/Corporate : MEDIWHEEL PVT LTD

Bill Date : 26/11/2022
 Reporting Date : 26/11/2022
 Sample ID : 68654
 Bill/Req. No. : 22998690
 Ref Doctor : Dr.RMO

Test	Result	Bio. Ref. Interval	Units	Method
ESR (WESTERGREN)				
E.S.R. - II HR.	20		mm II Hr.	Westergren

***** END OF THE REPORT *****



Sample no.

Dr. SONIA KUMARI
MBBS, MD (PATHOLOGY) Gold medalist

Dr. PRADIP KUMAR
Consultant (Microbiology)

Dr. NISHA TIWARI
MBBS, MD (Microbiology)

USER NM RAMKISHAN

(This is only professional opinion and not the diagnosis, Please correlate clinically)

Q Block South City 11, Sohna Road, Main Sector-47, Gurgaon, Haryana
 Ph.: 0124-4900000 (100 Lines) Fax : 0124-2218733 E-mail : parkmedicenters@gmail.com Page 1 of 1

PARK GROUP OF HOSPITALS : West Delhi • South Delhi • Gurgaon • Karnal • Panipat • Hodal • Ambala • Behror



DEPARTMENT OF PATHOLOGY

Patient Name : Mr. ANKUR GUPTA
 MR No : 666689
 Age/Sex : 31 Years 10 Months 13 Days / Male
 Type : OPD
 TPA/Corporate : MEDIWHEEL PVT LTD

Bill Date : 26/11/2022
 Reporting Date : 26/11/2022
 Sample ID : 68654
 Bill/Req. No. : 22998690
 Ref Doctor : Dr.RMO

Test	Result	Bio. Ref. Interval	Units	Method
LFT (LIVER FUNCTION TEST)				
LFT				
TOTAL BILIRUBIN	1.4	H 0 - 1.2	mg/dL	DIAZO
DIRECT BILIRUBIN	0.4	0 - 0.4	mg/dL	DIAZO
INDIRECT BILIRUBIN	1.0	H 0.10 - 0.6	mg/dL	CALCULATED
SGOT (AST)	63	H 0 - 45	U/L	IFCC WITHOUT
SGPT (ALT)	149	H 0 - 45	U/L	IFCC WITHOUT
ALKALINE PHOSPHATASE	184	H 30 - 170	IU/L	MODIFIED IFCC
TOTAL PROTEINS	6.7	6.4 - 8.0	g/dL	BIURET
ALBUMIN	4.2	3.3 - 5.5	g/dL	BCG DYE
GLOBULIN	2.5	2.3 - 4.5	g/dL	CALCULATED
A/G RATIO	1.68	1.1 - 2.2		CALCULATED

***** END OF THE REPORT *****



Sample no.

Dr. SONIA KUMARI
 MBBS, MD (PATHOLOGY) Gold medalist

Dr. PRADIP KUMAR
 Consultant (Microbiology)

Dr. NISHA TIWARI
 MBBS, MD (Microbiology)

USER NM RAMKISHAN

(This is only professional opinion and not the diagnosis, Please correlate clinically)

O Block South City 11, Sohna Road, Main Sector-47, Gurgaon, Haryana

Ph.: 0124-4900000 (100 Lines) Fax : 0124-2218733 E-mail : parkmedicenters@gmail.com Page 1 of 1

PARK GROUP OF HOSPITALS : West Delhi • South Delhi • Gurgaon • Karnal • Panipat • Hodal • Ambala • Behror



DEPARTMENT OF PATHOLOGY

Patient Name : Mr. ANKUR GUPTA
MR No : 666689
Age/Sex : 31 Years 10 Months 13 Days / Male
Type : OPD
TPA/Corporate : MEDIWHEEL PVT LTD

Bill Date : 26/11/2022
Reporting Date : 26/11/2022
Sample ID : 68654
Bill/Req. No. : 22998690
Ref Doctor : Dr.RMO

Test	Result	Bio. Ref. Interval	Units	Method
KFT (RENAL PROFILE)				
KFT				
SERUM UREA	14	10 - 45	mg/dL	UREASE-GLDH
SERUM CREATININE	1.1	0.4 - 1.4	mg/dL	MODIFIED JAFFES
SERUM URIC ACID	4.8	2.5 - 7.0	mg/dL	URICASE
SERUM SODIUM	146	<i>H</i> 136 - 145	meq/l	ISE
SERUM POTASSIUM	4.8	3.5 - 5.5	meq/l	ISE
SERUM CALCIUM	8.8	8.5 - 10.5	mg/dL	ARSENazo III
SERUM PHOSPHORUS	2.6	2.5 - 4.5	mg/dL	AMMONIUM

***** END OF THE REPORT *****



Sample no.

Dr. SONIA KUMARI
MBBS, MD (PATHOLOGY) Gold medalist

Dr. PRADIP KUMAR
Consultant (Microbiology)

Dr. NISHA TIWARI
MBBS, MD (Microbiology)

USER NM RAMKISHAN

(This is only professional opinion and not the diagnosis, Please correlate clinically)

Q Block South City 11, Sohna Road, Main Sector-47, Gurgaon, Haryana

Ph.: 0124-4900000 (100 Lines) Fax : 0124-2218733 E-mail : parkmedicenters@gmail.com Page 1 of 1

PARK GROUP OF HOSPITALS : West Delhi • South Delhi • Gurgaon • Karnal • Panipat • Hodal • Ambala • Behror



DEPARTMENT OF PATHOLOGY

Patient Name : Mr. ANKUR GUPTA
 MR No : 666689
 Age/Sex : 31 Years 10 Months 13 Days / Male
 Type : OPD
 TPA/Corporate : MEDIWHEEL PVT LTD

Bill Date : 26/11/2022
 Reporting Date : 26/11/2022
 Sample ID : 66654
 Bill/Req. No. : 22996690
 Ref Doctor : Dr.RMO

Test	Result	Bio. Ref. Interval	Units	Method
LIPID PROFILE				
LIPID PROFILE				
TOTAL CHOLESTEROL	213	0 - 250	mg/dL	CHOD -Trinder
SERUM TRIGLYCERIDES	179	H 60 - 165	mg/dl	GPO-TRINDER
HDL-CHOLESTEROL	44	30 - 70	mg/dl	DIRECT
VDL CHOLESTEROL	35	H 6 - 32	mg/dL	calculated
LDL	134	50 - 135	mg/dl	calculated
LDL CHOLESTEROL/HDL RATIO	3.0	1.0 - 3.0	mg/dL	calculated
TOTAL CHOLESTEROL/HDL RATIO	4.8	2.0 - 5.0	mg/dl	calculated

***** END OF THE REPORT *****



Sample no.

Dr. SONIA KUMARI
 MBBS, MD (PATHOLOGY) Gold medalist

Dr. PRADIP KUMAR
 Consultant (Microbiology)

Dr. NISHA TIWARI
 MBBS, MD (Microbiology)

USER NM RAMKISHAN

(This is only professional opinion and not the diagnosis, Please correlate clinically)

Q Block South City 11, Sohna Road, Main Sector-47, Gurgaon, Haryana

Ph.: 0124-4900000 (100 Lines) Fax : 0124-2218733 E-mail : parkmedicenters@gmail.com Page 1 of 1

PARK GROUP OF HOSPITALS : West Delhi • South Delhi • Gurgaon • Karnal • Panipat • Hodal • Ambala • Behror



NAME	: MR. GUPTA ANKUR	DATE	: 29 / 11 / 2022
Age Sex	: 31Years / Male	Inpatient No	:
PERFORMED BY	: Dr. ELA MADAAN	BILL NO.	: 22998690

TRANS THORACIC ECHO CARDIOGRAPHY REPORT

MITRAL VALVE

Morphology AML: Normal / Thickening / Calcification / Flutter / Vegetation / Non significant Prolapse / SAM
PML: Normal / Thickening / Calcification / Prolapse / Paradoxical Motion / Fixed.
Subvalvular deformity: Present / Absent

Doppler

Normal / Abnormal
Mitral Stenosis Present / Absent
Mitral Regurgitation; Absent / Normal / Mild / Trace / Moderate / Severe.

TRICUSPID VALVE

Morphology Normal / Atresia / Thickening / Calcification / Prolapse / Vegetation / Doming.

Doppler

Normal / Abnormal
Tricuspid Stenosis: Present / Absent.
Tricuspid Regurgitation: Absent / Mild / Trace / Moderate

PULMONARY VALVE

Morphology Normal / Atresia / Thickening / Calcified / Doming / Vegetation.

Doppler

Normal / Abnormal.
Pulmonary Stenosis: Present / Absent
Pulmonary regurgitation: Present / Absent

AORTIC VALVE

Morphology Normal / Thickened / Mildly / Calcified / Flutter / Vegetation / Restricted / Opening
No. of Cusps 1 / 2 / 3 / 4

Doppler

Normal / Abnormal
Aortic Stenosis : Present / Absent
Aortic regurgitation : Present / Absent / Mild / Trace



(This is only professional opinion and not the diagnosis, Please correlate clinically)

Q Block South City 11, Sohna Road, Main Sector-47, Gurgaon, Haryana
Ph.: 0124-4900000 (100 Lines) Fax : 0124-2218733 E-mail : parkmedicenters@gmail.com

PARK GROUP OF HOSPITALS : West Delhi • South Delhi • Gurgaon • Karnal • Panipat • Hodal • Ambala • Behror

<u>Measurements</u>	<u>Normal Values</u>	<u>Measurements</u>	<u>Normal Value</u>
IVSD : 1.0cm	(0.6-1.1cm)	LA : 3.6cm	(1.9-4.0cm)
LVID : 4.5cm	(3.7-5.6cm)	LVOT : 1.5cm	
LVPW : 1.0cm	(0.6-1.1cm)	AORTA : 2.5cm	(2.0-3.7cm)
EF : 60%	(55% - 80%)	IVSmotion :	Normal / Flat / Paradoxical
Any Other			

CHAMBERS:-

- LV Normal / Enlarged / Clear / Thrombus / Contraction Normal LV shows concentric LVH, no gradient across LVOT / Inetic / Intra capillary Regional wall motion abnormality: Absent / Present
- LA Normal / Enlarged / Clear / Thrombus / Myxoma; LAA: Clear / Thrombus
- RA Normal / Clear / Thrombus, Dilated.
- RV Normal / Mildly Dilated / Enlarged / Clear / Thrombus / Hypertrophied /

PERICARDIUM Normal / Thickening / Calcification / Effusion.

COMMENTS & SUMMARY:-

- All Cardiac Chamber Dimensions are within normal limits.
- Global LVEF 60%
- No RWMA
- NORMAL LV FUNCTION
- NO MR / NO AR
- TRACE TR
- GOOD RV FUNCTION
- IAS/IVS. No Flow seen across IAS/IVS.
- No Thrombus/Mass in any chamber.
- No Pericardial Effusion.

Please correlate clinically

Dr. ELA MADAAN
MBBS, PGDCC
Fellowship in non Invasive
Cardiology



(This is only professional opinion and not the diagnosis, Please correlate clinically)

Q Block South City 11, Sohna Road, Main Sector-47, Gurgaon, Haryana
Ph.: 0124-4900000 (100 Lines) Fax : 0124-2218733 E-mail : parkmedicenters@gmail.com

PARK GROUP OF HOSPITALS : West Delhi • South Delhi • Gurgaon • Karnal • Panipat • Hodal • Ambala • Behror



DEPARTMENT OF RADIOLOGY

Patient Name	Mr ANKUR GUPTA	Billed Date	: 26/11/2022	9.00 AM
Reg No	666689	Reported Date	: 26/11/2022	
Age/Sex	31 Years 10 Months 13Days / Male	Req. No.	: 22998690	
Type	OPD	Consultant Doctor	: Dr. RMO	

X-RAY CHEST AP/PA

X-RAY CHEST P.A. VIEW

Bilateral lungs appears normal.

No focal lung lesion seen.

No evidence of free fluid is seen.

Both hila are normal in size, have equal density and bear normal relationship.

The heart and trachea are central in position and no mediastinal abnormality is visible.

The cardiac size is normal for patient age and view.

The domes of the diaphragms are normal in position, and show smooth outline.

To be correlated clinically




Dr. ANSHU K. SHARMA
MBBS, MD
CONSULTANT RADIOLOGIST

Dr. MANJEET SEHRAWAT
MBBS, MD, PDCC
CONSULTANT RADIOLOGIST

Dr. NEENA SIKKA
MBBS, DNB
CONSULTANT RADIOLOGIST

(This is only professional opinion and not the diagnosis, Please correlate clinically)

Q Block South City 11, Sohna Road, Main Sector-47, Gurgaon, Haryana
Ph.: 0124-4900000 (100 Lines) Fax : 0124-2218733 E-mail : parkmedicenters@gmail.com

PARK GROUP OF HOSPITALS : West Delhi • South Delhi • Gurgaon • Karnal • Panipat • Hodal • Ambala • Behror



Patient Name	Mr ANKUR GUPTA	Billed Date	: 26/11/2022	9:00 AM
Reg No	666689	Reported Date	: 26/11/2022	
Age/Sex	31 Years 10 Months 13Days / Male	Req. No.	: 22998690	
Type	OPD	Consultant Doctor	: Dr. RMO	

USG WHOLE ABDOMEN

The Real time, B mode, gray scale sonography of the abdominal organs was performed.

LIVER : The liver is mild enlarged in size 15.0cm with fatty infiltration. No evidence of any focal lesion. IHBR is not dilated.

GALL BLADDER :The gall bladder is well distended. No evidence any calculus or mass seen.No evidence of pericholecystic fluid is seen.

BILE DUCT :The common bile duct is normal in caliber. No evidence of calculus is noted in common bile duct.

SPLEEN :The spleen is normal in size and shape.Its echotexture is homogeneous.No evidence of focal lesion is noted.

PANCREAS :The pancreas is normal in size, shape, contours and echotexture.No evidence of solid or cystic mass lesion is noted.MPD is not dilated. No evidence of peripancreatic collection.

KIDNEYS :RK:9.4x3.8 cm. LK: 9.9x5.0 cm.

The bilateral kidneys are normal in size and echotexture. Cortico-medullary differentiation is maintained.There is no evidence of obvious calculus or hydronephrosis.

URINARY BLADDER :The urinary bladder is well distended.Wall thickness within normal limits.No evidence of calculus is seen.No evidence of mass or diverticulum is noted.

PROSTATE: Prostate appears normal in shape, size 12cc and echotexture.

No evidence of ascites or interbowel free fluid is seen.

No evidence of obvious retroperitoneal or mesentric lymphadenopathy is seen.

IMPRESSION- Mild hepatomegaly with fatty liver grade-I

To be correlated clinically

Dr. ANSHU K. SHARMA
MBBS, MD
CONSULTANT RADIOLOGIST

Dr. MANJEET SEHRAWAT
MBBS, MD, PDCC
CONSULTANT RADIOLOGIST

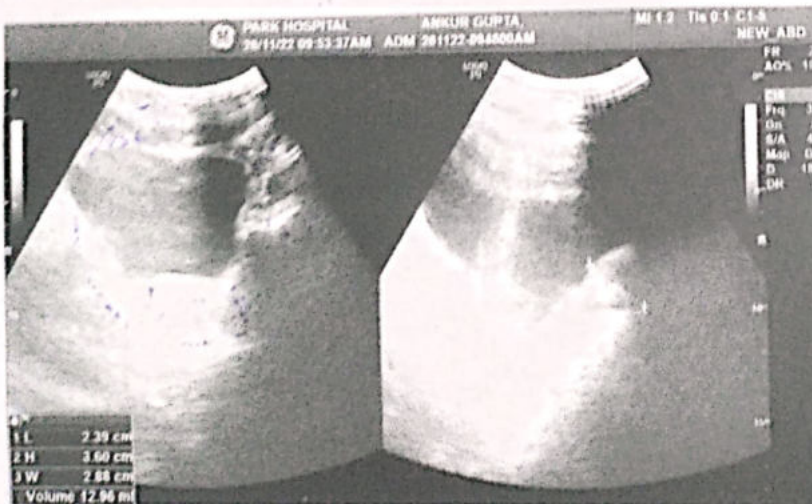
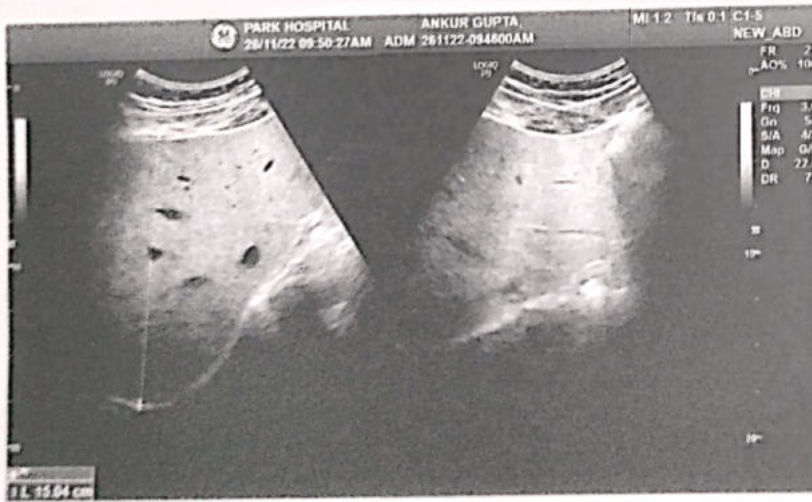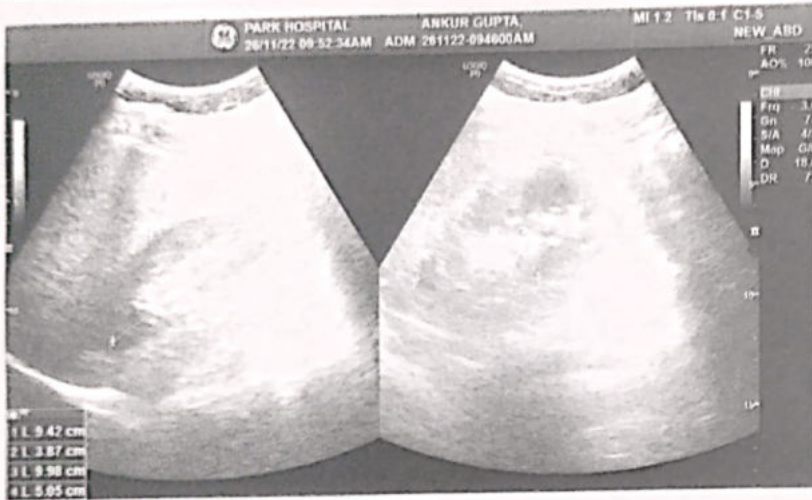
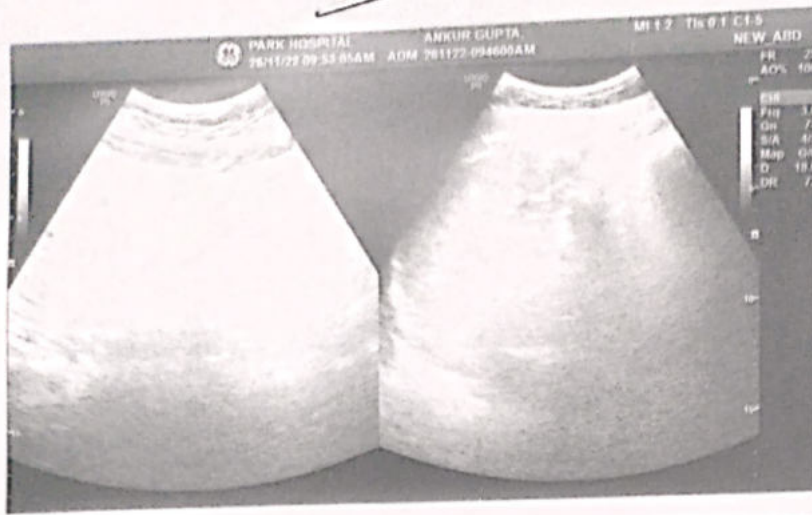
Dr. NEENA SIKKA
MBBS, DNB
CONSULTANT RADIOLOGIST



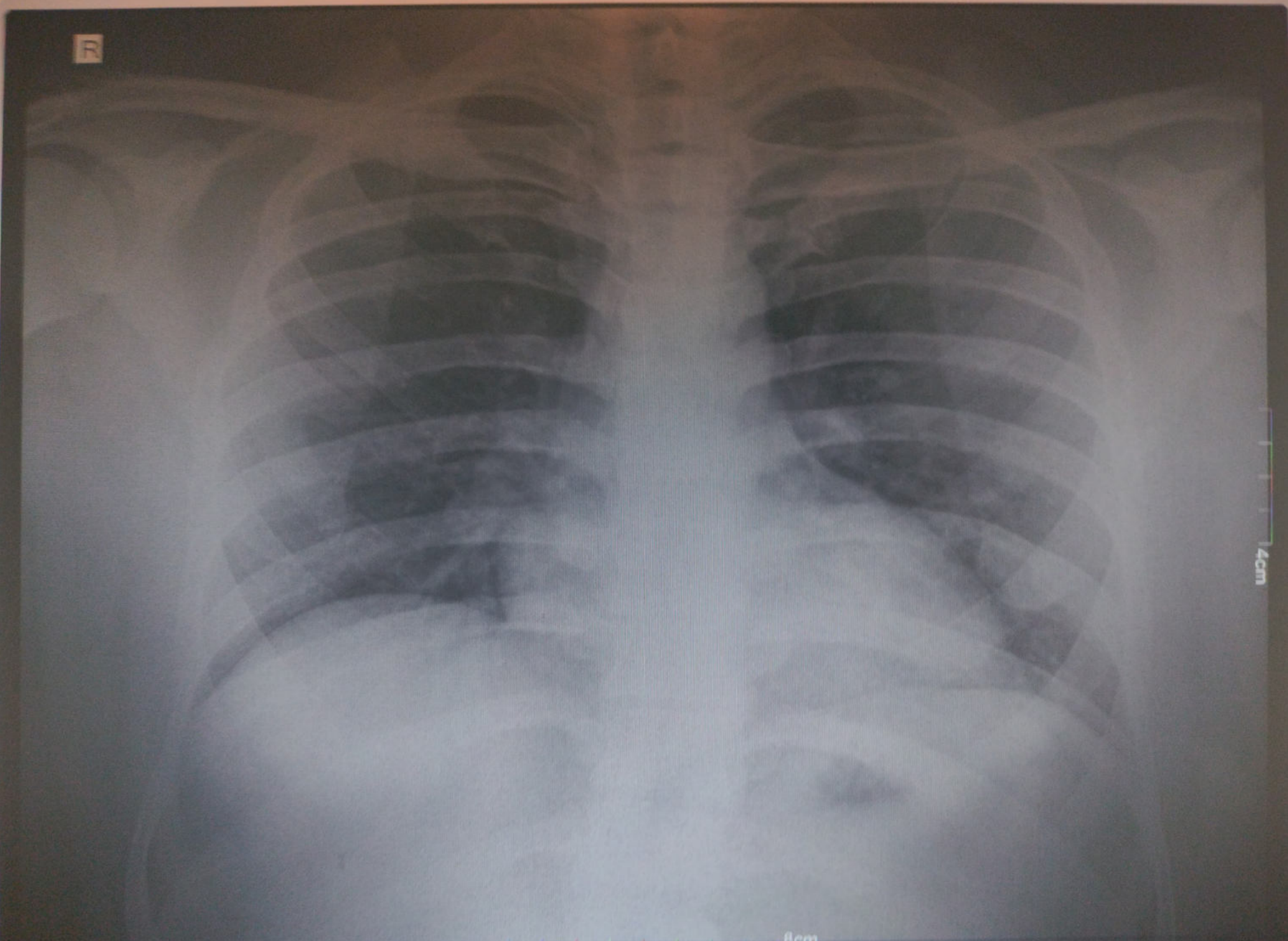
(This is only professional opinion and not the diagnosis, Please correlate clinically)

Q Block South City 11, Sohna Road, Main Sector-47, Gurgaon, Haryana
Ph.: 0124-4900000 (100 Lines) Fax : 0124-2218733 E-mail : parkmedicenters@gmail.com

PARK GROUP OF HOSPITALS : West Delhi • South Delhi • Gurgaon • Karnal • Panipat • Hodal • Ambala • Behror



R



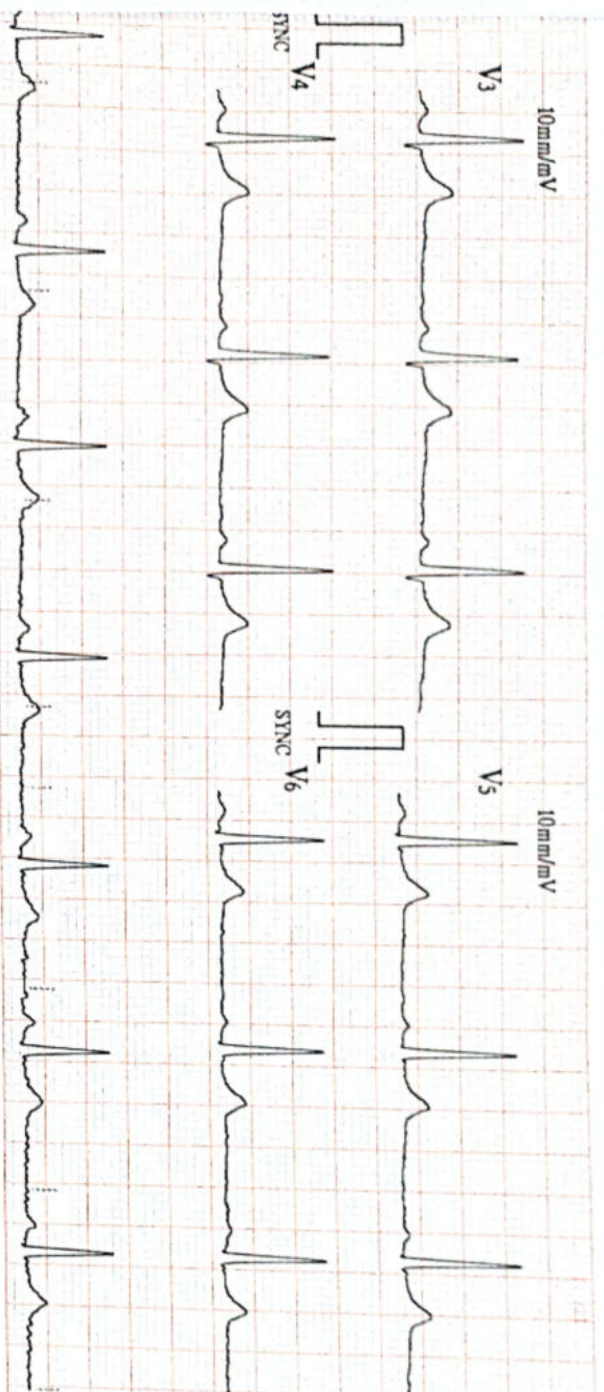
4cm

8cm

ANKUR GUPTA 31Y,
PARK HOSPITAL, SOUTH CITY II, GURGAON, HARYANA

CHEST

26/11/2022 09:31:28
REQ-22998890



ID : 0096

HR : 61 bpm

Name: GURPTA

R-R : 980 ms

Sex : pt

P-R : 148 ms

Age : 31

QRS : 100 ms

28/11/2025 Sinus Rhythm
Indespecific T Abnormality

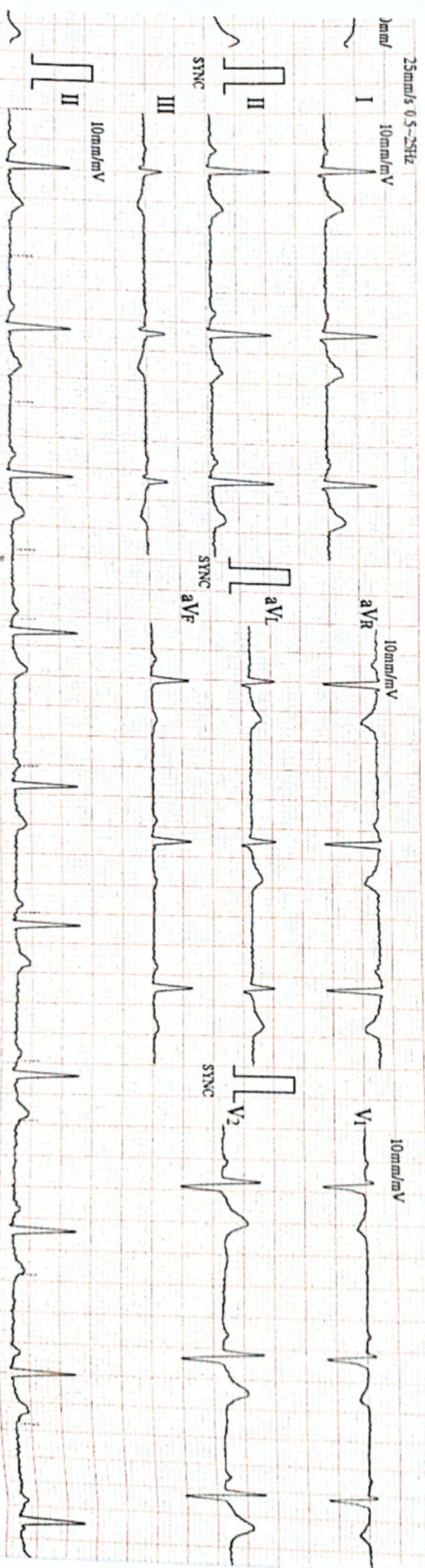
QT/QTc : 374/377 ms

P/QRS/T : 50/45/19

RV5/SV1 : 1-390/0-690 mV

RV5-SV1 : 2.080 mV

Unconfirmed report Verified by:



25mm/s 0.5-25Hz

ECG-1203 V2.000(BIOS:V2.000/AMP:V1.001) 2016-01-01 00:00