



भारत सरकार

GOVERNMENT OF INDIA



लोकेश कुमार भास्कर

Lokesh Kumar Bhashkar

जन्म तिथि / DOB: 05/03/1986

पुरुष / MALE

Mobile No.: 9212779905

3177 2389 7342

मेरा आधार, मेरी पहचान

Lokesh Kumar Bhashkar

Dr. Nitin Agarwal
Dr. NITIN AGARWAL
MBBS, MD
Regn. No. DMC-R-1436



भारतीय विशिष्ट पहचान प्राधिकरण

UNIQUE IDENTIFICATION AUTHORITY OF INDIA

पता:

S/O कैलाश पासवान, डब्लू जेड-११०९-सी, समीप
गुरुद्वारा, रानी बाग, शकूर बस्ती, मोरथ वेस्ट देहली,
देहली - 110034

Address:

S/O Kailash Paswan, WZ-1109-C, NEAR
GURUDWARA, RANI BAGH, SHAKUR BASTI,
North West Delhi, Delhi - 110034



3177 2389 7342




1947
1800 300 1947

hsp@uidai.gov.in

www.uidai.gov.in

P.O. Box No. 1947,
Bengaluru-560 001

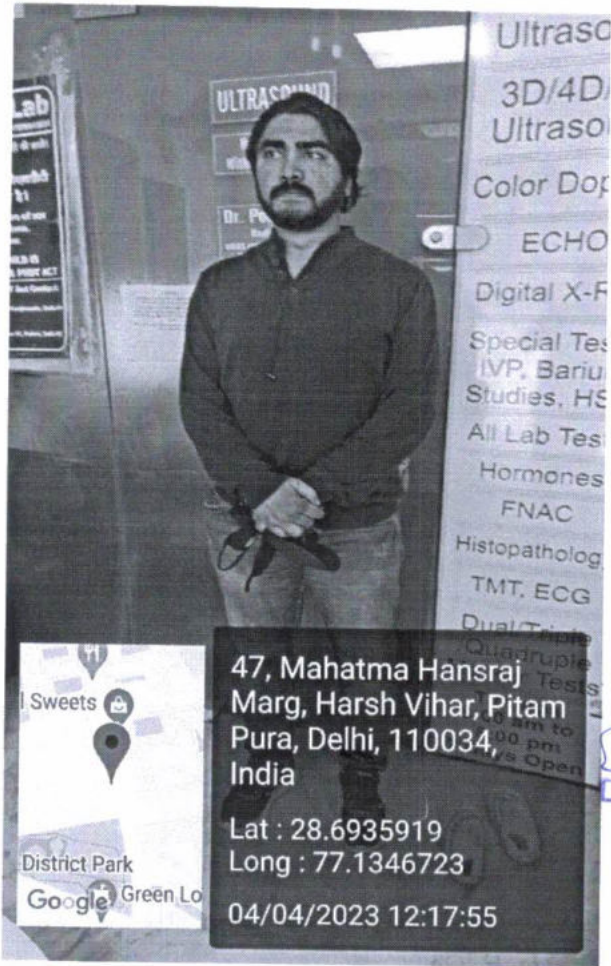
ONEPLUS ULTRASOUND LAB
47, Harsh Vihar, Pitam Pura,
Delhi-110034
Ph. 011-42480101, 9599913054
E-mail: onepusul@gmail.com



	<p>Dr. LILIAN</p>		
--	-------------------	--	--

Date:

.....
 (Signature of Doctor)
 Name
 Designation



[Signature]
Dr. NITIN AGARWAL
MBBS, MD
Regn. No. DMC-R-1436

[Handwritten Signature]

ONEPLUS ULTRASOUND LAB
47, Harsh Vihar, Pitam Pura,
Delhi-110034
Ph. 011-42480101, 9599913051
E-mail: oneplusul@gmail.com

ONEPLUS ULTRASOUND LAB

47, HARSH VIHAR, PITAMPURA, DELHI- 110034

Mr. LOKESH KUMAR BHASKAR
 Age : 34M
 Ref. by : MEDWHEEL
 Indication1 :
 Indication2 :
 Indication3 :
 COMMENTS : Normal ECG

ID : 2202
 HMMT : 173/88
 Recorded : 4-4-2023 11:48
 Medication1 :
 Medication2 :
 Medication3 :

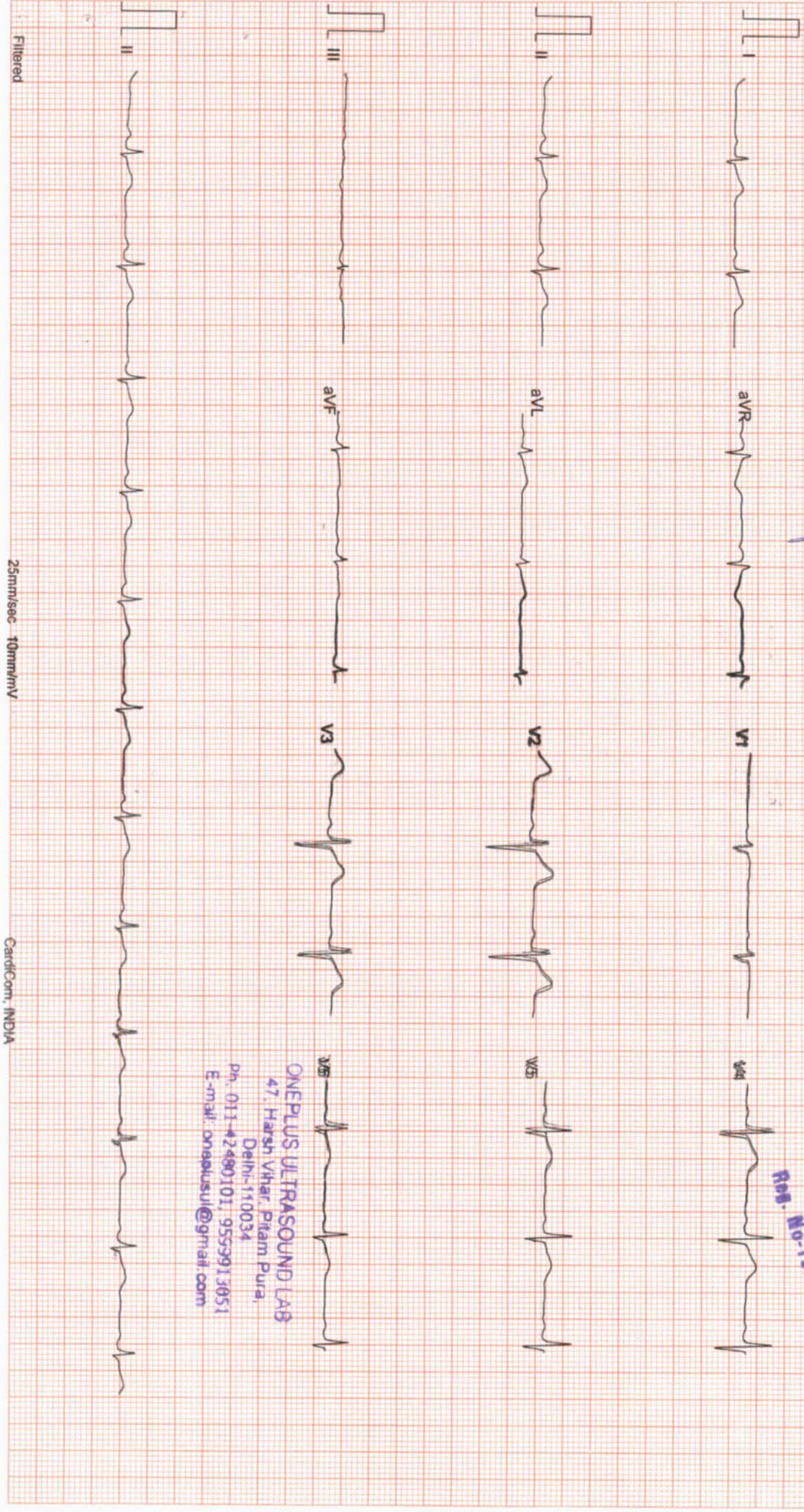
Handwritten Signature

BPM : 75
 BP : 126/88
 P Axis : 42 deg
 QRS Axis : 48 deg
 T Axis : 24 deg

Unconfirmed Report Reviewed By:
 Cardiologist

P duration : 83 msec
 PR duration : 153 msec
 QRS duration : 110 msec
 QT interval : 326 msec
 QTc interval : 352 msec

Raw E.C.G. (SQ)
Handwritten Signature
 Dr. R. B. S. S. S.
 Reg. No. 10111



ONEPLUS ULTRASOUND LAB
 47, Harsh Vihar, Pitam Pura,
 Delhi-110034
 Ph. 011-42480101, 9559913051
 E-mail: onaplusul@gmail.com

Filtered

25mm/sec 10mm/mV

CardCom, INDIA

ONEPLUS ULTRASOUND LAB

47, HARSH VIHAR PITAMPURA DELHI 110034

Mr. LOKESH KUMAR BHASKAR

Age/Sex: 34/M
Ref. by: MEDIWHEEL

Indication1:
Indication2:
Indication3:

ID : 996
H/Wt: 173/88
Recorded : 4-4-2023 11:51

TREADMILL TEST SUMMARY REPORT
Protocol: BRUCE
History:
Medication1:
Medication2:
Medication3:

PHASE	PHASE TIME	STAGE TIME	SPEED (Km./Hr.)	GRADE (%)	H.R (BPM)	B.P. (mmHg)	RPP X100	II	ST LEVEL V2 (mm)	V5	METS
SUPINE STANDING					80	126/88	100	0.8	2.2	1.1	
STAGE 1	2:59	2:59	2.70	10.00	114	126/88	105	0.8	2.1	1.1	4.80
STAGE 2	5:59	2:59	4.00	12.00	140	140/90	143	0.9	2.3	0.9	7.10
STAGE 3	7:44	1:44	5.40	14.00	160	150/94	196	0.9	2.2	1.2	8.78
PEAK EXER	7:48	1:48			160	150/94	240	0.9	1.9	1.0	
RECOVERY	2:59	2:59	0.00	0.00	93	150/94	139	0.5	1.2	0.4	8.85

RESULTS
Exercise Duration
Max Heart Rate
Max Blood Pressure
Max Work Load
Reason of Termination

7:48 Minutes
160 bpm 86 % of target heart rate 186 bpm
150/94 mmHg
8.85 METS

IMPRESSIONS

Negative for ischaemic

Dr. R.K. GUPTA
MBBS, MD
Cardiologist No.11071

ONEPLUS ULTRASOUND LAB
47, Harsh Vihar, Pitam Pura,
Delhi-110034
Ph: 011-42440101, 9559913051
E-mail: oneplusul@gmail.com

ONEPLUS ULTRASOUND LAB

SUPINE
PRETEST

ST @ 10mm/mV
80ms PostU

Mr. LOKESH KUMAR BHASKAR

I.D. : 996

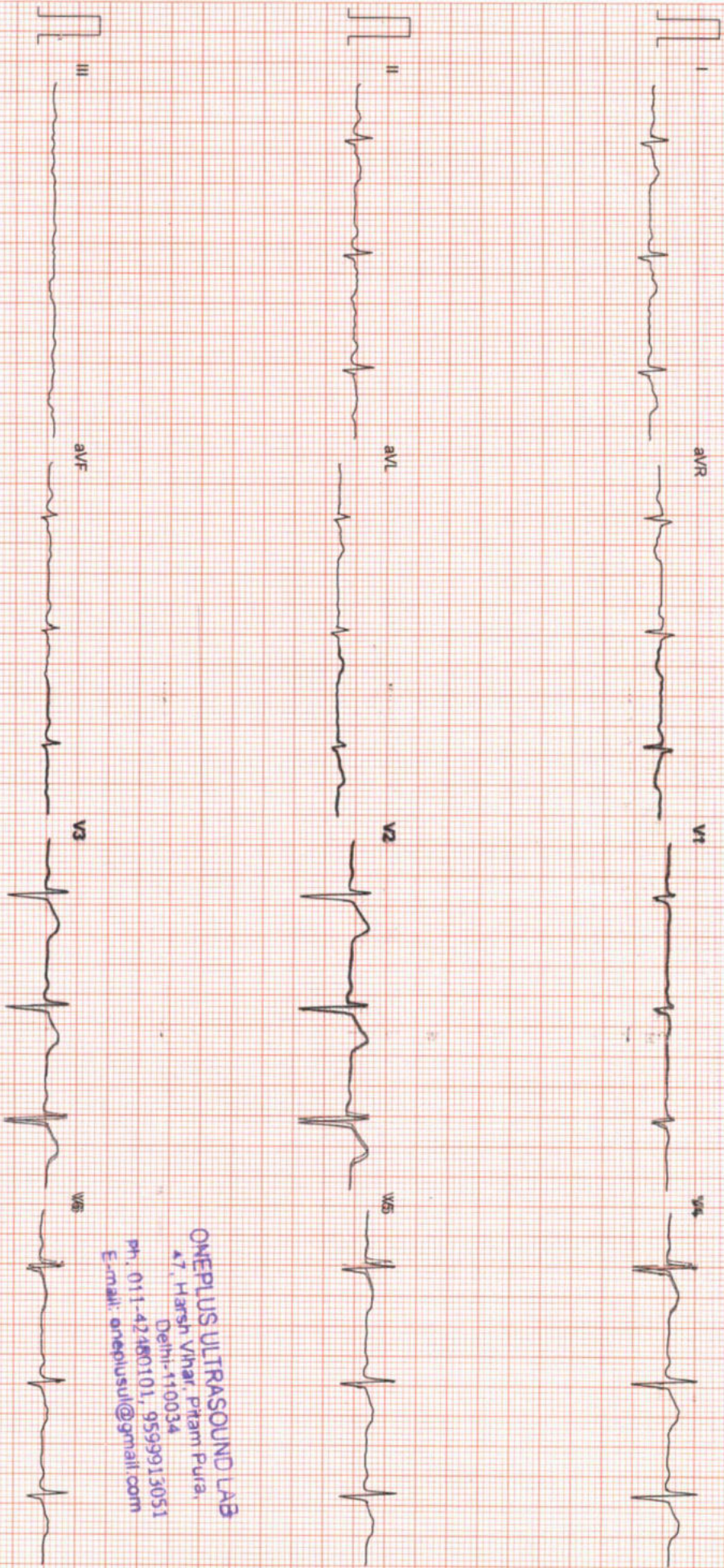
AGE/SEX : 34/M

RECORDED : 4-4-2023 11:51

RATE : 80 BPM

B.P. : 126/88 mmHg

RAW E.C.G.



ONEPLUS ULTRASOUND LAB
47, Harsh Vihar, Pitam Pura,
Delhi-110034
Ph. 011-42460101, 9599913051
E-mail: oneplusul@gmail.com

Filtered

25mm/sec 10mm/mV

CardiCom, INDIA Ph. 091-731-2620740, Tele/Fax: 091-731-2431214

ONEPLUS ULTRASOUND LAB

STANDING
PRETEST

ST @ 10mm/mV
80ms PostJ

Mr. LOKESH KUMAR BHASKAR

I.D. : 996

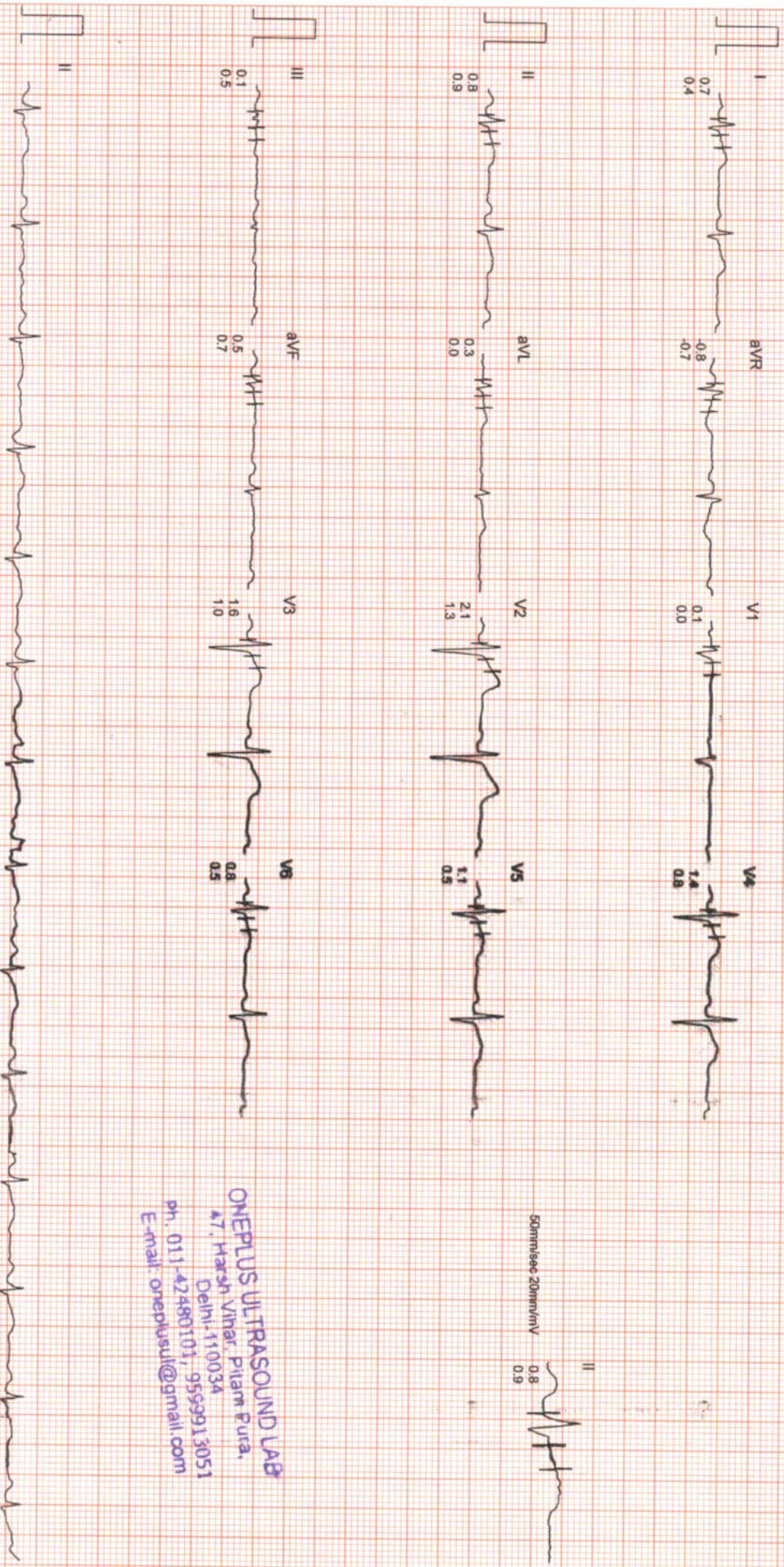
AGE/SEX : 34/M

RECORDED : 4-4-2023 11:51

RATE : 84 BPM

B.P. : 126/88 mmHg

LINKED MEDIAN



50mm/sec 20mm/mV



ONEPLUS ULTRASOUND LAB
47, Harsh Vihar, Pitam Pura,
Delhi-110034
Ph. 011-42480101, 9559913051
E-mail: oneplusul@gmail.com

Filtered Computer-Corrected Baseline

25mm/sec 10mm/mV

CardiCom, INDIA Ph.:091-731-2620740, TeleFax:091-731-2431214

ONEPLUS ULTRASOUND LAB

Mr. LOKESH KUMAR BHASKAR
ID : 996

AGE/SEX : 34/M

RECORDED : 4-4-2023 11:51

RATE : 114 BPM

B.P : 126/88 mmHg

BRUCE

EXERCISE 1

PHASE TIME : 2:59

STAGE TIME : 2:59

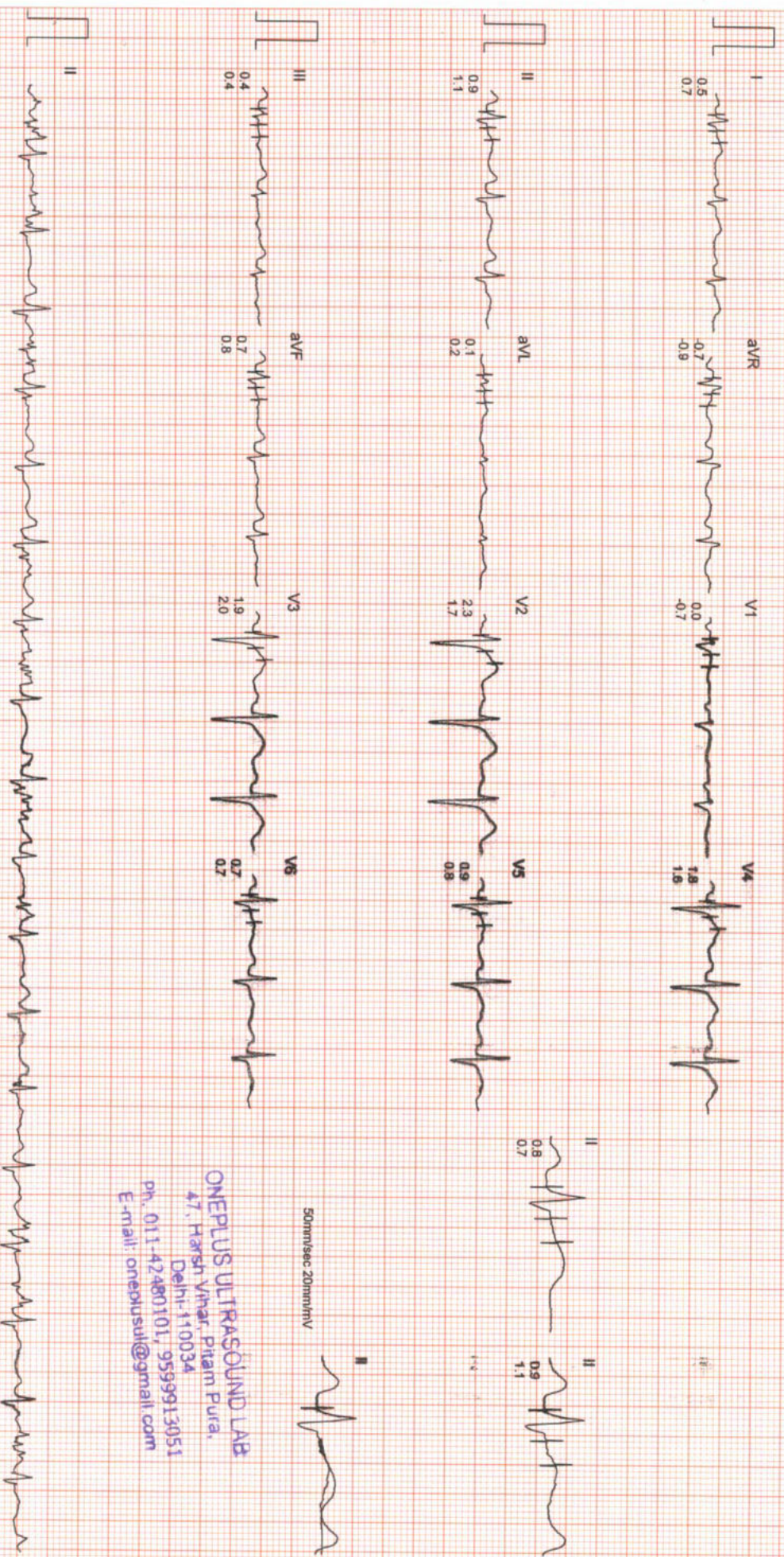
ST @ 10mm/mV

80ms PostJ

SPEED : 2.7 Km./Hr.

GRADE : 10.0 %

LINKED MEDIAN



ONEPLUS ULTRASOUND LAB
47, Harsh Vihar, Pitam Pura,
Delhi-110034
Ph. 011-42480101, 9599913051
E-mail: oneplusul@gmail.com

Filtered Computer Corrected Baseline 25mm/sec 10mm/mV Cardicom, INDIA Ph.:091-731-2620740, Telefax:091-731-2431214

ONEPLUS ULTRASOUND LAB

Mr. LOKESH KUMAR BHASKAR

I.D. : 996

AGE/SEX : 34/M

RECORDED : 4-4-2023 11:51

RATE : 140 BPM

B.P. : 140/90 mmHg

BRUCE

EXERCISE 2

PHASE TIME : 5:59

STAGE TIME : 2:59

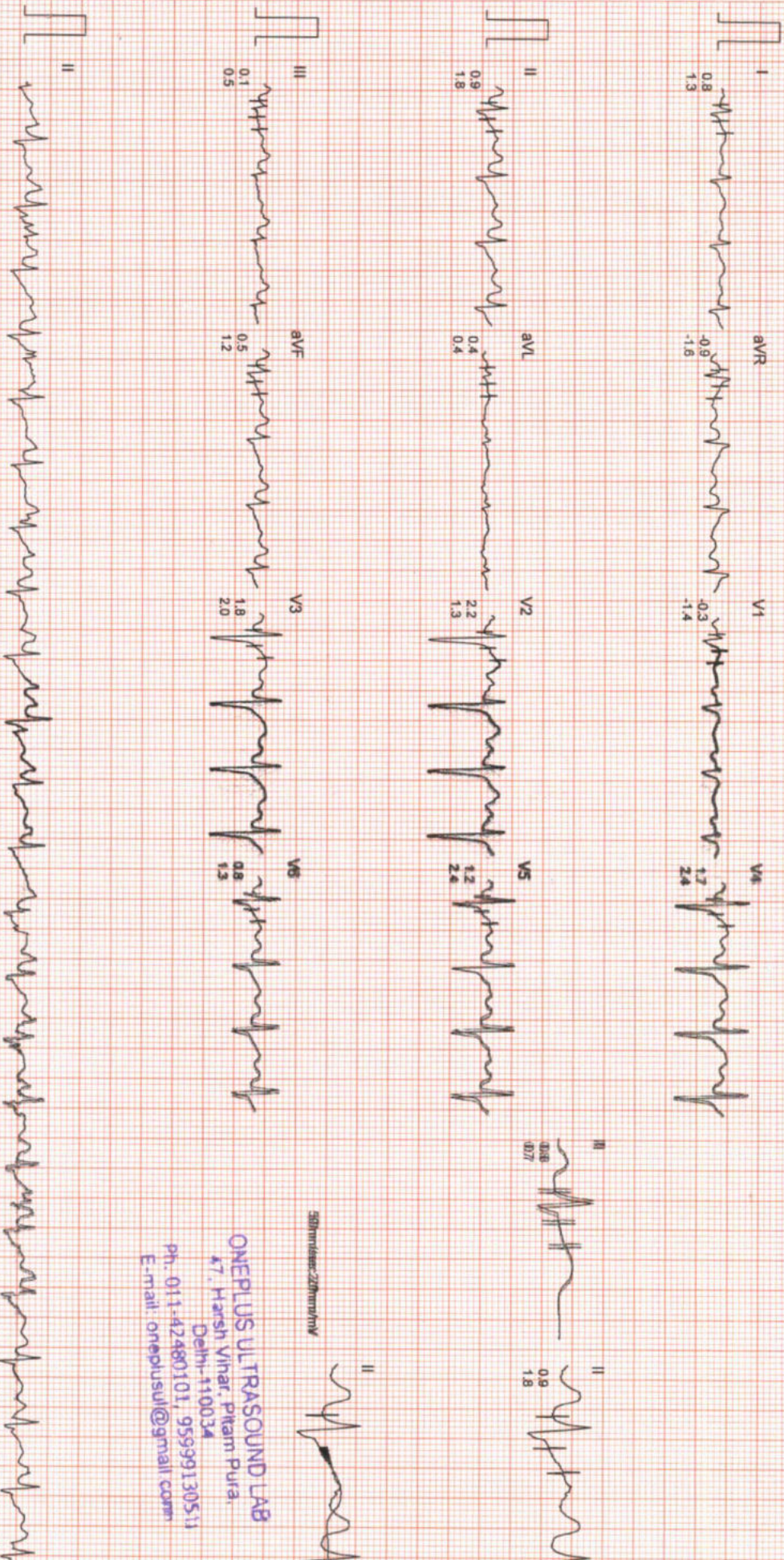
ST @ 10mm/mV

80ms PostJ

SPEED : 4.0 Km./Hr.

GRADE : 12.0 %

LINKED MEDIUM



50mm/sec-20mm/mV

ONEPLUS ULTRASOUND LAB

47, Hansh Vihar, Pitam Pura,

Delhi-110034

Ph. 011-42480101, 9599913051

E-mail: oneplusul@gmail.com

Filtered

Computer-Corrected-Baseline

25mm/sec-10mm/mV

CardiCom, INDIA Ph.:091-731-2620740, Tele/Fax:091-731-2431214

ONEPLUS ULTRASOUND LAB

Mr. LOKESH KUMAR BHASKAR

I.D. : 996

AGE/SEX : 34/M

RECORDED : 4-4-2023 11:51

RATE : 160 BPM

B.P. : 150/94 mmHg

BRUCE

EXERCISE 3

PHASE TIME : 7:44

STAGE TIME : 1:44

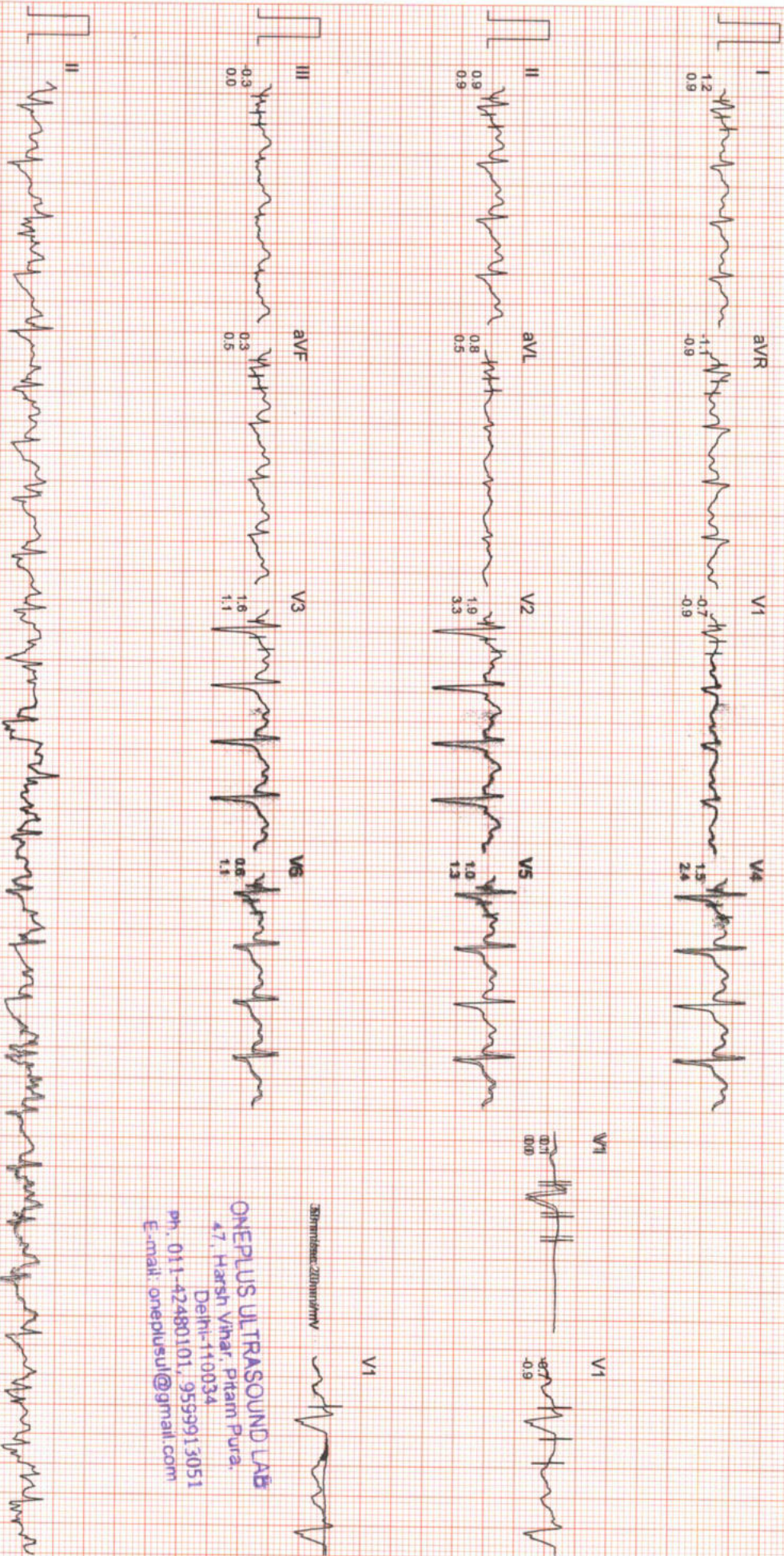
ST @ 10mm/mV

80ms PostJ

SPEED : 5.4 Km./Hr.

GRADE : 14.0 %

LINKED MEDIAN



25mm/sec 10mm/mV

ONEPLUS ULTRASOUND LAB
47, Harsh Vihar, Pitam Pura,
Delhi-110034
Ph. 011-42480101, 9559913051
E-mail: oneplusul@gmail.com

Filtered

Computer Corrected Baseline

25mm/sec 10mm/mV

CardiCom, IN/DIA Ph..091-731-26207 40, TeleFax:091-731-2431214

ONEPLUS ULTRASOUND LAB

Mr. LOKESH KUMAR BHASKAR

ID : 996

AGE/SEX : 34/M

RECORDED : 4-4-2023 11:51

RATE : 160 BPM

B.P. : 150/94 mmHg

BRUCE

PEAK EXER

PHASE TIME : 7:48

STAGE TIME : 1:48

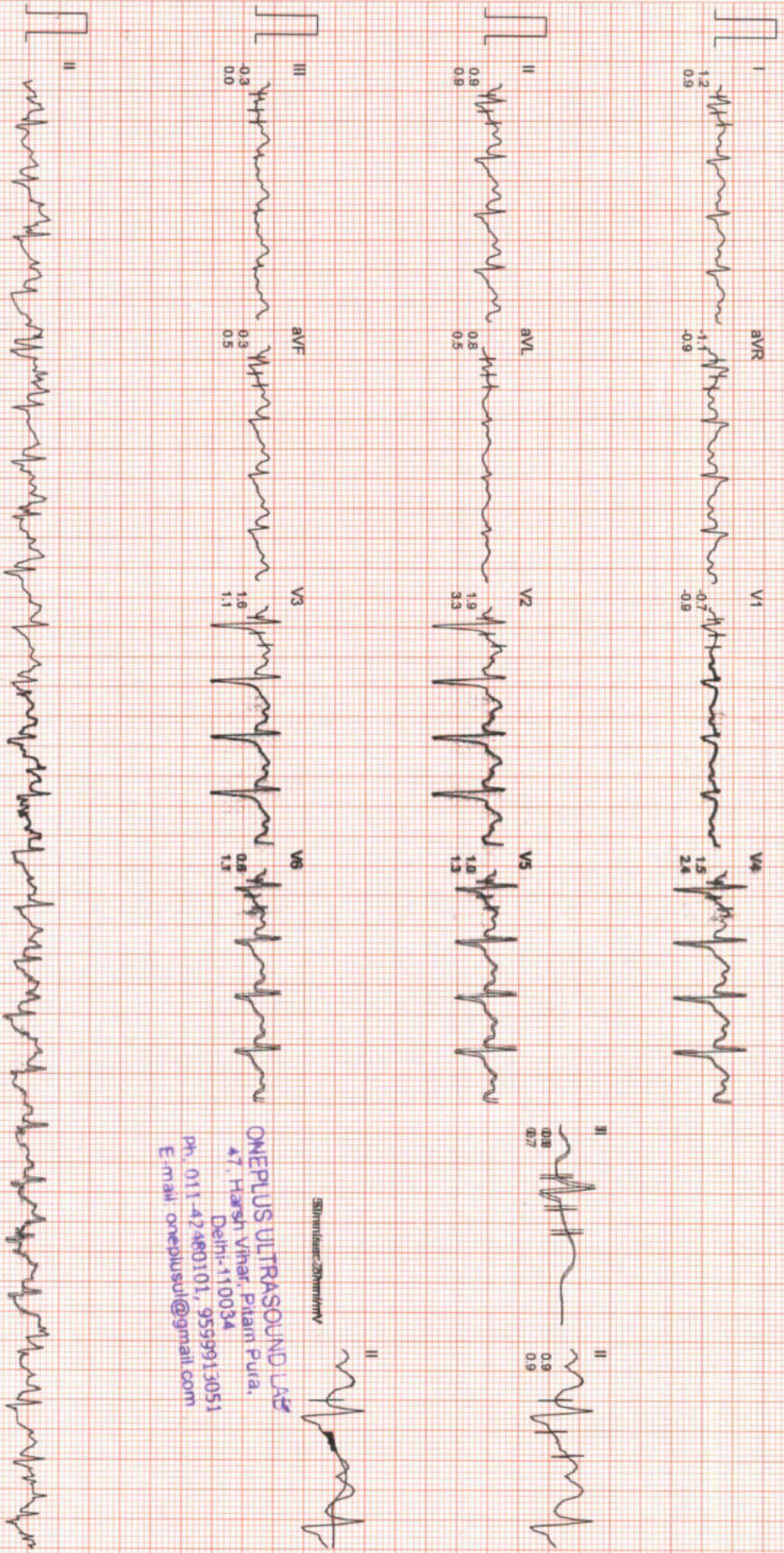ST @ 10mm/mV

80ms PostJ

SPEED : 5.4 Km./Hr.

GRADE : 14.0 %

LINKED MEDIUM



50mm/Sec: 250mm/mV
ONEPLUS ULTRASOUND LAB
47, Harsh Vihar, Pitam Pura,
Delhi-110034
Ph. 011-42480101, 9559913051
E-mail: oneplusul@gmail.com

ONEPLUS ULTRASOUND LAB

Mr. LOKESH KUMAR BHASKAR

ID : 996

AGE/SEX : 34/M

RECORDED : 4-4-2023 11:51

RATE : 93 BPM

B.P : 150/94 mmHg

BRUCE ..

RECOVERY

PHASE TIME : 2:59

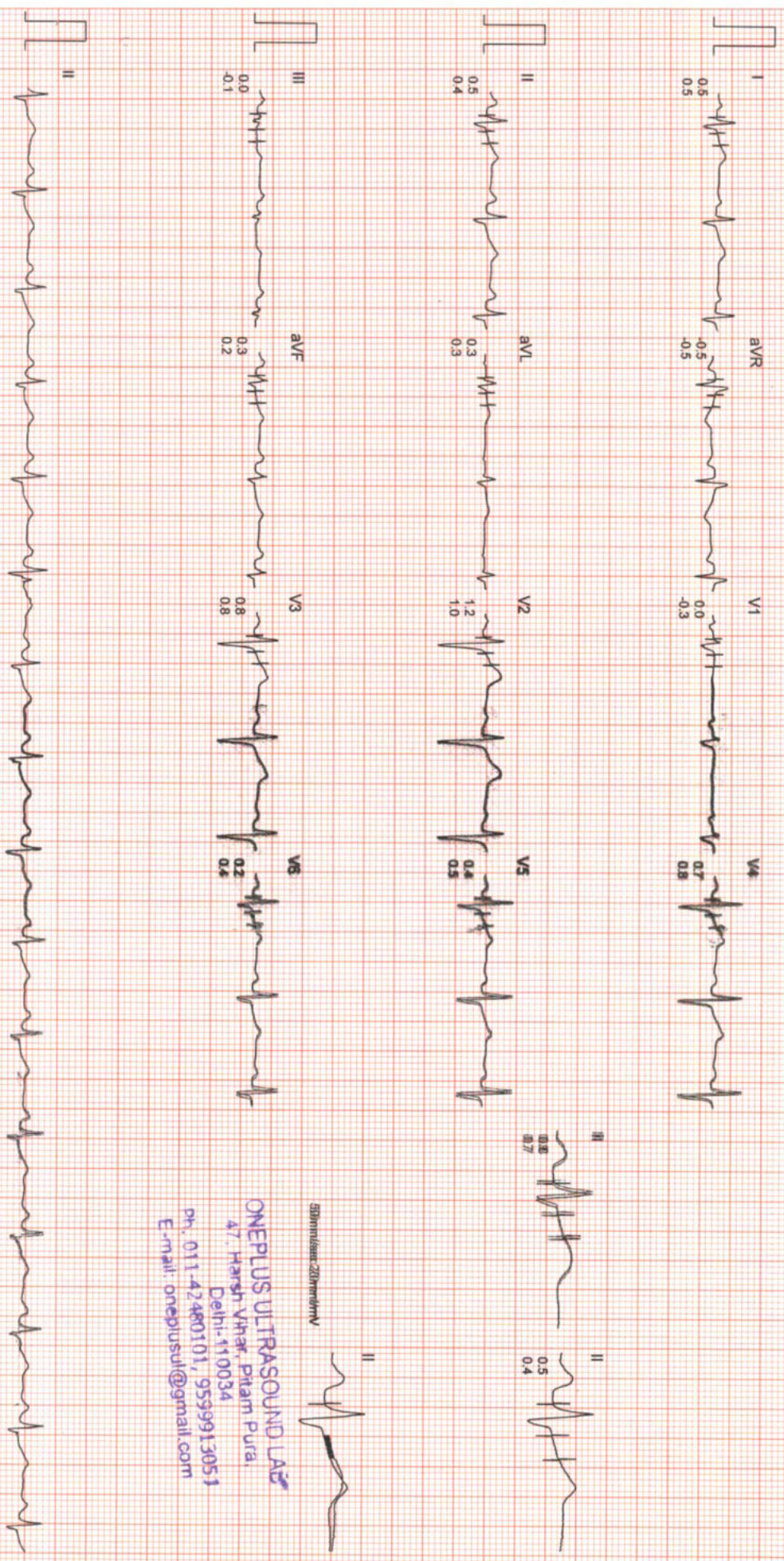
ST @ 10mm/mV

80ms PostJ

SPEED : 0.0 Km./Hr.

GRADE : 0.0 %

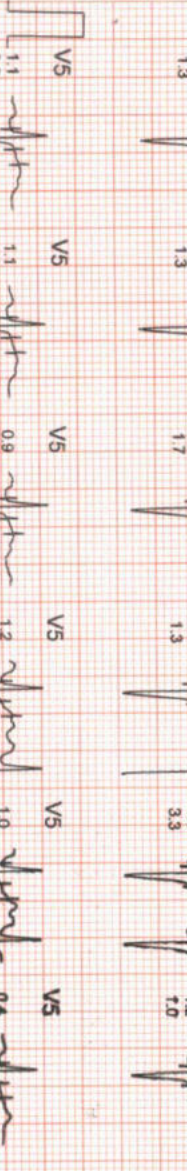
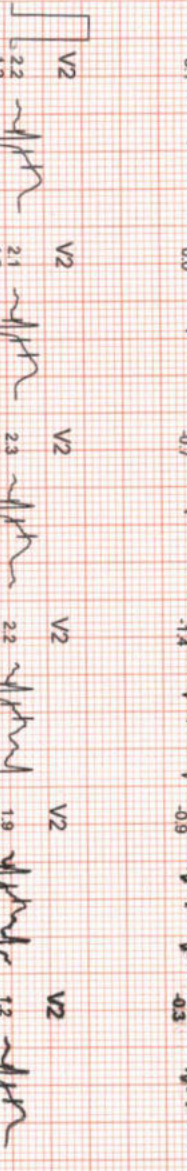
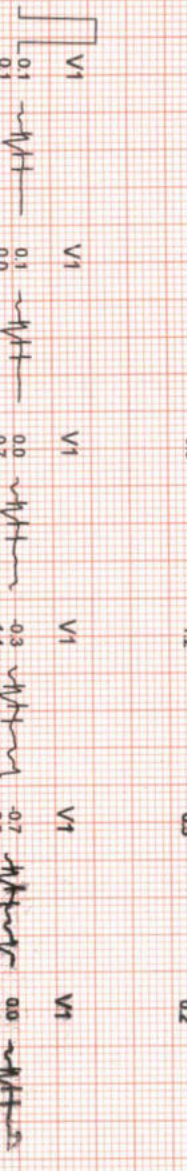
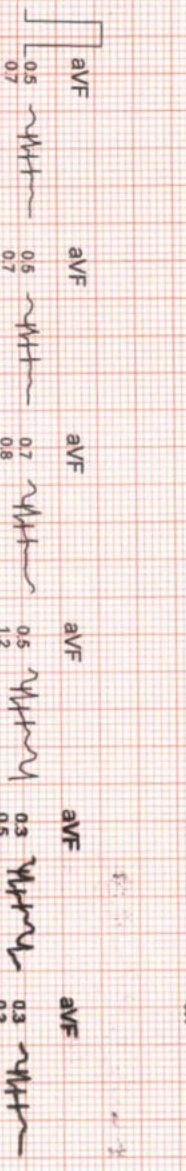
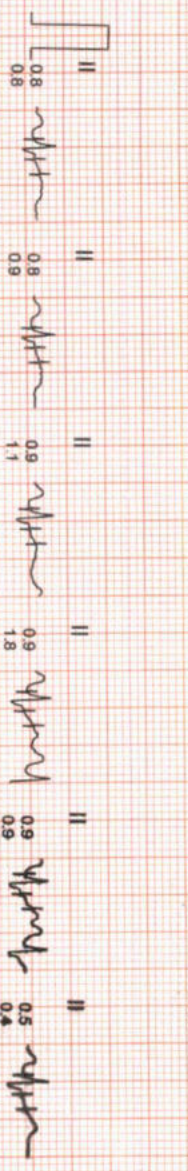
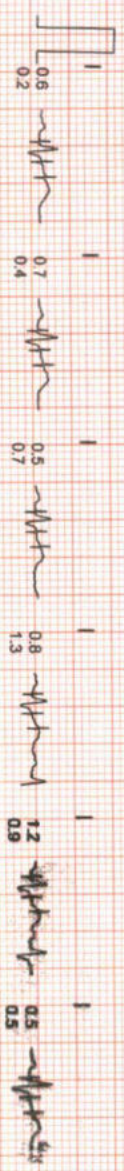
LINKED MEDIAN



30mm/Sec 25mm/mV

ONEPLUS ULTRASOUND LAB
47 Hansh Vihar, Pitam Pura,
Delhi-110034
Ph. 011-42480101, 9539913051
E-mail: oneplusul@gmail.com

SUPINE	STANDING	STAGE 1	STAGE 2	PEAK EXERCISE	RECOVERY
0.0kmph 0.0% 80 bpm B.P. 120/88 80ms PostJ	0.0kmph 0.0% 84 bpm B.P. 120/88 80ms PostJ	2.7kmph 2.5% 114 bpm B.P. 120/88 80ms PostJ	4.0kmph 12.0% 140 bpm B.P. 140/90 80ms PostJ	5.4kmph 14.0% 160 bpm B.P. 150/94 80ms PostJ	0.0kmph 0.0% 93 bpm B.P. 150/94 80ms PostJ



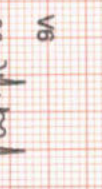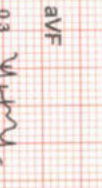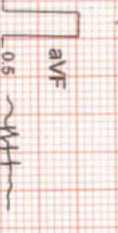
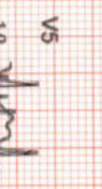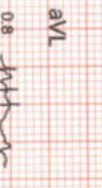
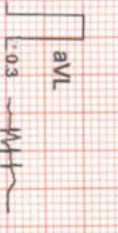
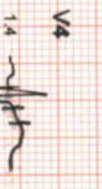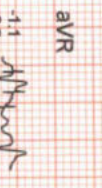
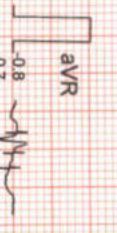

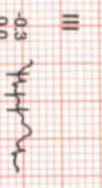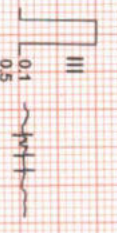
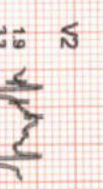
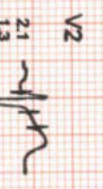
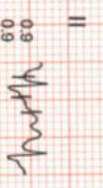
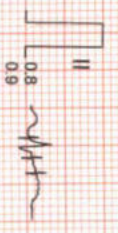

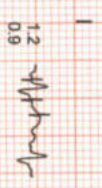
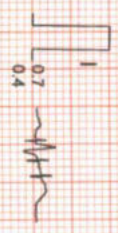
ONEPLUS ULTRASOUND LAB
 41, Harsh Vihar, Pitam Pura,
 Delhi-110034
 Ph. 011-42480101, 9599913051
 E-mail: oneplusul@gmail.com

STANDING
0.0kmph
0.0%
84 bpm
B.P. 120/88
80ms PostU

PEAK EXERCISE
7:48
1:48
5.4kmph
14.0%
160 bpm
B.P. 150/94
80ms PostU

STANDING
0.0kmph
0.0%
84 bpm
B.P. 120/88
80ms PostU

PEAK EXERCISE
7:48
1:48
5.4kmph
14.0%
160 bpm
B.P. 150/94
80ms PostU



ONEPLUS ULTRASOUND LAB
47, Harsh Vihar, Pitam Pura,
Delhi-110034
Ph. 011-42480101, 9599913053
E-mail: oneplusul@gmail.com



OnePLUS Ultrasound Lab

QUALITY FIRST... ALWAYS!

Dr. Nitin Agarwal
Pathologist & Director
Ex. Sr. Res. MAMC
& Lok Nayak Hospital
Ex. Chief of Lab Dr. Lal Path Labs.

Dr. Pooja (Garg) Agarwal
Radiologist & Director
MAMC & Lok Nayak Hospital



NAME	:Mr. LOKESH KUMAR BHASKAR	Barcode No	:10141636
AGE/GENDER	:34 YRS/Male	SPECIMEN DATE	:04/Apr/2023 10:30AM
PATIENT ID	:111932	SPECIMEN RECEIVED	:04/Apr/2023 01:15PM
REFERRED BY	:Dr. MEDIWHEEL	REPORT DATE	:04/Apr/2023 02:08PM
CENTRE NAME	:ONEPLUS ULTRASOUND LAB	LAB NO.	:012304040033

Test Name	Result	Unit	Ref. Range
-----------	--------	------	------------

HAEMATOLOGY

Medi Wheel Health checkup < 40 Male

Glycosylated Hemoglobin (HbA1c)	5.2	%	Non Diabetic adults <5.7 Prediabetic (at risk) 5.7-6.4 Diabetes >6.4
--	-----	---	--

Estimated average blood glucose (eag) 103

Reference range (mg/dl):

90 - 120:Excellent control, 121 - 150:Good Control, 151 - 180:Average Control, 181 - 210:Action Suggested
>211:Panic value

BLOOD GROUP (ABO)	O
Rh typing	POSITIVE

NOTE :

- * Apart from major A,B,H antigens which are used for ABO grouping and Rh typing, many minor blood group antigens exist. Agglutination may also vary according to titre of antigen and antibody.
- * So before transfusion, reconfirmation of blood group as well as cross-matching is needed.
- * Presence of maternal antibodies in newborns, may interfere with blood grouping.
- * Auto agglutination (due to cold antibody, falciparum malaria, sepsis, internal malignancy etc.) may also cause erroneous result.

CBC

Haemoglobin	12.9	g/dl	13.0-17.0
Total Leucocyte Count	7900	/cumm	4000-10000
Differential leucocyte count			
Neutrophils	63.7	%	40-80
Lymphocyte	30.70	%	20-40
Monocytes	3.00	%	2-10
Eosinophils	2.0	%	1-6
Basophils	0.6	%	0-2
RBC Count	4.30	million/cumm	4.5 - 5.5

Checked By.

Dr. NITIN AGARWAL
MBBS, MD (P)
DMCR/01136
DR. NITIN AGARWAL
MBBS, MD (PATHOLOGIST)

47, Harsh Vihar, Pitampura, New Delhi-110034 | Ph.: 011-42480101, 9599913051

E-mail: oneplusul@gmail.com | Web.: www.oneplusul.in

Page 2 of 2



OnePLUS Ultrasound Lab

QUALITY FIRST... ALWAYS!

Dr. Nitin Agarwal
Pathologist & Director
Ex. Sr. Res. MAMC
& Lok Nayak Hospital
Ex. Chief of Lab Dr. Lal Path Labs.

Dr. Pooja (Garg) Agarwal
Radiologist & Director
MAMC & Lok Nayak Hospital



NAME	:Mr. LOKESH KUMAR BHASKAR	Barcode No	:10141636
AGE/GENDER	:34 YRS/Male	SPECIMEN DATE	:04/Apr/2023 10:30AM
PATIENT ID	:111932	SPECIMEN RECEIVED	:04/Apr/2023 01:15PM
REFERRED BY	:Dr. MEDIWHEEL	REPORT DATE	:04/Apr/2023 02:08PM
CENTRE NAME	:ONEPLUS ULTRASOUND LAB	LAB NO.	:012304040033

Test Name	Result	Unit	Ref. Range
PCV(Hematocrit)	43.3	%	40-50
MCV	100	fL	83-101
MCH	29.9	Pg	27-32
MCHC	29.9	G/dL	32-35
RDW-CV	13.4	%	11.4-14.0
Platelet count	168000	/cumm	150000-450000

BIOCHEMISTRY

<u>Blood sugar fasting</u>	96	mg/dL	70-110
<u>Bun (blood urea nitrogen)</u>	12.60	mg/dl	8.9-21.6
<u>Uric acid, serum</u>	4.6	mg/dl	3.5-7.2
<u>Creatinine, serum</u>	0.6	mg/dl	0.60-1.2

LFT(LIVER FUNCTION TEST)

Bilirubin Total	0.65	mg/dl	0.1-1.2
Bilirubin Conjugated	0.32	mg/dl	0-0.4
Bilirubin Unconjugated	0.33	mg/dl	up to 0.7
SGOT (AST)	27	U/L	0-46
SGPT (ALT)	35	U/L	0-49
Alkaline phosphatase	106	U/L	40-129
Gamma glutamyl transpeptidase	28	U/L	10-45
Total Protein	6.9	gm/dl	6.60 - 8.70
Albumin serum	3.9	g/dL	3.0-5.2
Globulin	3.00	gm/dl	1.8-3.4
Albumin/Globulin Ratio	1.30		1.10 - 2.50

LIPID PROFILE

Cholesterol	162	mg/dl	50-200
Triglycerides	94	mg/dL	25-150
HDL Cholesterol	45	mg/dL	40 - 60
LDL cholesterol	98	mg/dL	<130

Checked By.

DR. NITIN AGARWAL
MBBS, MD (PATHO)
GMC/19/01136
DR. NITIN AGARWAL
MBBS, MD (PATHOLOGIST)

47, Harsh Vihar, Pitampura, New Delhi-110034 | Ph.: 011-42480101, 9599913051

E-mail: oneplusul@gmail.com | Web.: www.oneplusul.in

Page 2 of 5



OnePLUS Ultrasound Lab

QUALITY FIRST... ALWAYS!

Dr. Nitin Agarwal
Pathologist & Director
Ex. Sr. Res. MAMC
& Lok Nayak Hospital
Ex. Chief of Lab Dr. Lal Path Labs.

Dr. Pooja (Garg) Agarwal
Radiologist & Director
MAMC & Lok Nayak Hospital



NAME	:Mr. LOKESH KUMAR BHASKAR	Barcode No	:10141636
AGE/GENDER	:34 YRS/Male	SPECIMEN DATE	:04/Apr/2023 10:30AM
PATIENT ID	:111932	SPECIMEN RECEIVED	:04/Apr/2023 01:15PM
REFERRED BY	:Dr. MEDIWHEEL	REPORT DATE	:04/Apr/2023 02:08PM
CENTRE NAME	:ONEPLUS ULTRASOUND LAB	LAB NO.	:012304040033

Test Name	Result	Unit	Ref. Range
VLDL cholesterol	18.8	mg/dL	5-40
Cholesterol/HDL Ratio	3.6		Low Risk 3.3-4.97 Average Risk 4.4-7.1 Moderate Risk 7.1-11.0 High Risk >11.0
LDL/HDL Ratio	2.2		0 - 3.55

According to ATP III and NCEP guidelines

Parameter	Normal	Desirable	Borderline	High
Total cholesterol	<200		200-239	240
Triglycerides	<150	150-199	200-499	500
LDL	Optimal <100 Near Optimal 100-129	130-159	160-180	190
HDL	<40 : LOW 60 : HIGH			

BUN/Creatinine ratio

Bun (blood urea nitrogen)	12.60	mg/dl	8.9-21.6
CREATININE	0.60	mg/dl	0.30-1.10
BUN/Creatinine ratio	21.00		10.0 - 20.0

ENDOCRINOLOGY

THYROID PROFILE(T3,T4,TSH)

Triiodothyronine total [t3]	0.67	ng/dl	0.52-1.9
Thyroxine total [t4]	6.40	µg/dl	4.4 - 10.8
TSH (Thyroid Stimulating Hormone)	5.50	µIU/ml	0.25-5.0

AGE WISE VARIATION IN TSH

AGE	TSH(µIU/ml)	AGE	TSH(µIU/ml)
1-4 weeks	1.00 - 19.0	16-20 yrs	0.25 - 5.0

Checked By.

DR. NITIN AGARWAL
MBBS, MD (P&T)
DMC/19/01436

DR. NITIN AGARWAL
MBBS, MD (PATHOLOGIST)

47, Harsh Vihar, Pitampura, New Delhi-110034 | Ph.: 011-42480101, 9599913051
E-mail: oneplusul@gmail.com | Web.: www.oneplusul.in

Page 3 of 5



OnePLUS Ultrasound Lab

QUALITY FIRST... ALWAYS!

Dr. Nitin Agarwal
Pathologist & Director
Ex. Sr. Res. MAMC
& Lok Nayak Hospital
Ex. Chief of Lab Dr. Lal Path Labs.

Dr. Pooja (Garg) Agarwal
Radiologist & Director
MAMC & Lok Nayak Hospital



NAME	:Mr. LOKESH KUMAR BHASKAR	Barcode No	:10141636
AGE/GENDER	:34 YRS/Male	SPECIMEN DATE	:04/Apr/2023 10:30AM
PATIENT ID	:111932	SPECIMEN RECEIVED	:04/Apr/2023 01:15PM
REFERRED BY	:Dr. MEDIWHEEL	REPORT DATE	:04/Apr/2023 02:08PM
CENTRE NAME	:ONEPLUS ULTRASOUND LAB	LAB NO.	:012304040033

Test Name	Result	Unit	Ref. Range
1-12 mths	1.70 - 9.1	21 - 80 yrs	0.25 - 5.0
1-5 yrs	0.80 - 8.2	I st trimester	0.25 - 5.0
6-10 yrs	0.25 - 5.0	II nd trimester	0.50 - 5.0
11-15 yrs	0.25 - 5.0	III rd trimester	0.4 - 6.0

Reference ranges - Interpretation of Diagnostic tests - (Jacques Wallach)

1. Primary hypothyroidism is accompanied by depressed serum T3 and T4 values and elevated serum TSH level.
2. Primary hyperthyroidism is accompanied by elevated serum T3 and T4 levels along with depressed TSH values.
3. Slightly elevated T3 levels may be found in pregnancy and estrogen therapy, while depressed levels may be encountered in severe illness, renal failure and during therapy with drugs like propranolol and propyl thiouracil.
4. Although elevated TSH levels are nearly always indicative of primary hypothyroidism, and may be seen in secondary thyrotoxicosis

CLINICAL PATHOLOGY

URINE ROUTINE

Physical examination

Quantity	20	ML
Colour	PALE YELLOW	
Transparency	SLIGHTLY TURBID	CLEAR
Sp. gravity	1.015	1.010-1.030
pH	6.00	
Reaction	ACIDIC	ACIDIC

Chemical examination

Urine protein	NIL	NIL
Urine sugar	NIL	NIL
Bilirubin, urine	NEGATIVE	NEGATIVE
Urobilinogen	NORMAL	NORMAL
Ketones	NEGATIVE	NEGATIVE

Microscopic examination

Pus cells.	2-3	/HPF	0-2
Epithelial cells	1-2	/HPF	NIL

Checked By.

Dr. NITIN AGARWAL
MBBS, MD (Pathology)
DMC/R/01436
DR. NITIN AGARWAL
MBBS, MD (PATHOLOGIST)

47, Harsh Vihar, Pitampura, New Delhi-110034 | Ph.: 011-42480101, 9599913051

E-mail: oneplusul@gmail.com | Web.: www.oneplusul.in

Page 4 of 5



OnePLUS Ultrasound Lab

QUALITY FIRST... ALWAYS!

Dr. Nitin Agarwal
Pathologist & Director
Ex. Sr. Res. MAMC
& Lok Nayak Hospital
Ex. Chief of Lab Dr. Lal Path Labs.

Dr. Pooja (Garg) Agarwal
Radiologist & Director
MAMC & Lok Nayak Hospital



NAME	:Mr. LOKESH KUMAR BHASKAR	Barcode No	:10141636
AGE/GENDER	:34 YRS/Male	SPECIMEN DATE	:04/Apr/2023 10:30AM
PATIENT ID	:111932	SPECIMEN RECEIVED	:04/Apr/2023 01:15PM
REFERRED BY	:Dr. MEDIWHEEL	REPORT DATE	:04/Apr/2023 02:08PM
CENTRE NAME	:ONEPLUS ULTRASOUND LAB	LAB NO.	:012304040033

Test Name	Result	Unit	Ref. Range
R.B.C.	NIL	/HPF	NIL
Casts	NIL	/HPF	NIL
Crystals	NIL	/HPF	NIL
Bacteria	NIL	/HPF	NIL
Others.	NIL	NIL	NIL

STOOL ROUTINE

Physical examination

Colour	BROWNISH		
Consistency	SEMI FORMED		Semi Formed
Blood	ABSENT		Absent
Mucus	ABSENT		Absent

Chemical examination, stool

pH	6.00		
----	------	--	--

Microscopic examination

Pus cells	0-1	/HPF	
R.B.C.	NIL	/HPF	NIL
Ova	NIL		NIL
Cysts	NIL		NIL
Bacteria	PRESENT	/HPF	NIL
Others	NIL		NIL

*** End Of Report ***

Checked By.

DR. NITIN AGARWAL
MBBS, MD (PATH)
DMLR/01436
DR. NITIN AGARWAL
MBBS, MD (PATHOLOGIST)

47, Harsh Vihar, Pitampura, New Delhi-110034 | Ph.: 011-42480101, 9599913051

E-mail: oneplusul@gmail.com | Web.: www.oneplusul.in

Page 5 of 5

Clinical correlation is essential for final diagnosis. • If test results are unsatisfactory please contact personally or on phone. • This report is for perusal of doctors only. • All disputes Subject to Delhi Jurisdiction only. • Not for medicolegal purposes. • All congenital anomalies in a foetus may not be diagnosed in routine obstetric ultrasound.



OnePLUS
Ultrasound Lab
— QUALITY FIRST... ALWAYS! —

Dr. Nitin Agarwal
Pathologist & Director
Ex. Sr. Res. MAMC
& Lok Nayak Hospital
Ex. Chief of Lab Dr. Lal Path Labs.

Dr. Pooja (Garg) Agarwal
Radiologist & Director
MAMC & Lok Nayak Hospital

Name	: Mr. LOKESH KUMAR BHASKAR	Age/Sex	: 34 YRS/Male
Ref. By	: Dr. MEDIWHEEL	Lab No	: 012304040033
Date	: 04-Apr-2023	Patient ID	: LSHHI111932

ULTRASOUND EXAMINATION----WHOLE ABDOMEN

Liver is normal in size and outline with normal echopattern. No abscess or mass lesion seen. Hepatic veins, portal vein, IVC and aorta are normal. Intrahepatic biliary radicles are not dilated. CBD is normal in caliber.

Gall bladder is well distended with anechoic lumen .Wall thickness is normal.

Both kidneys are normal in size, shape, position, outline and echopattern. Corticomedullary differentiation is maintained. No pelvicalyceal dilation or calculus or mass lesion is seen.

Spleen is normal in size and echotexture. No mass lesion seen.

Pancreas is normal in size, outline and echotexture .

Urinary bladder is normal in shape and position. No evidence of intravesical stone or mass seen.

Prostate is normal in size, shape and echopattern.

Prostate measures 3.6 x 3.1 x 2.9 cm. **Weight of prostate is 17.4 grams.**

No abnormal bowel wall thickening seen in right iliac fossa.

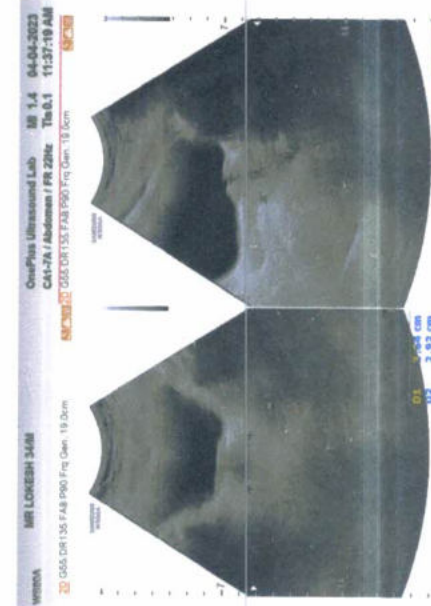
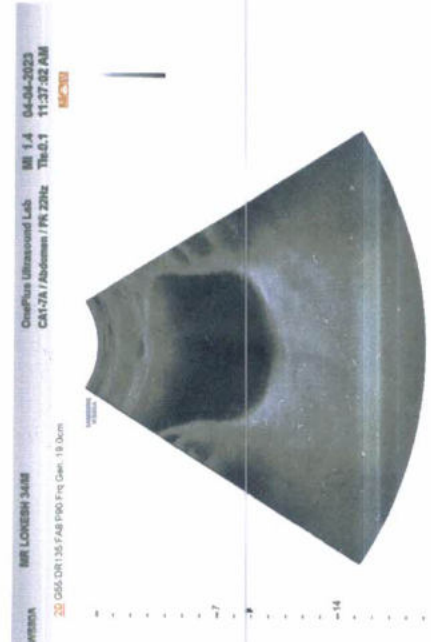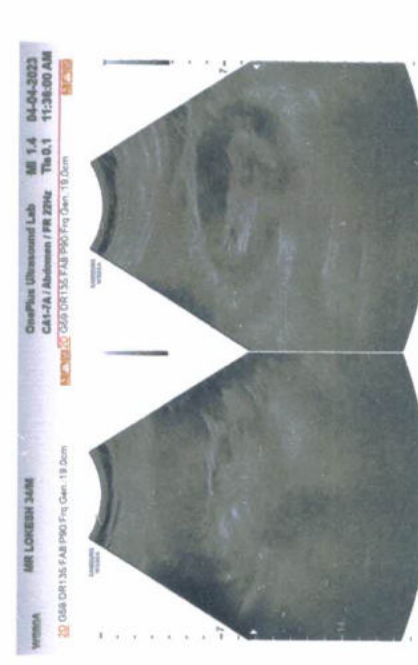
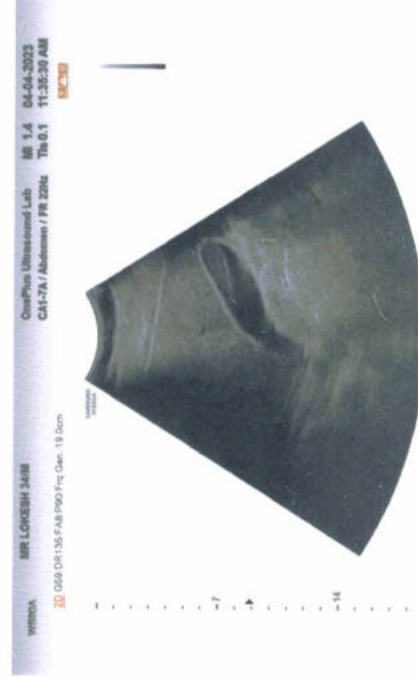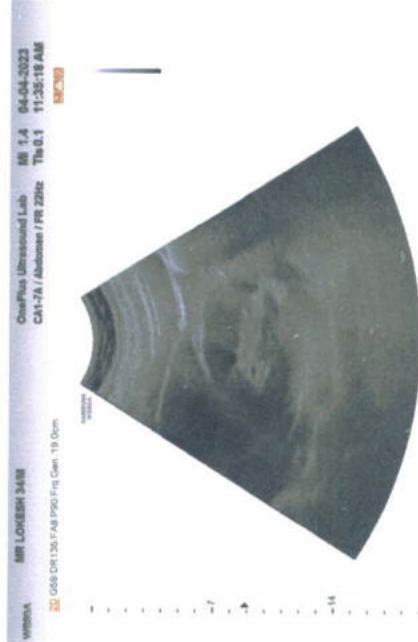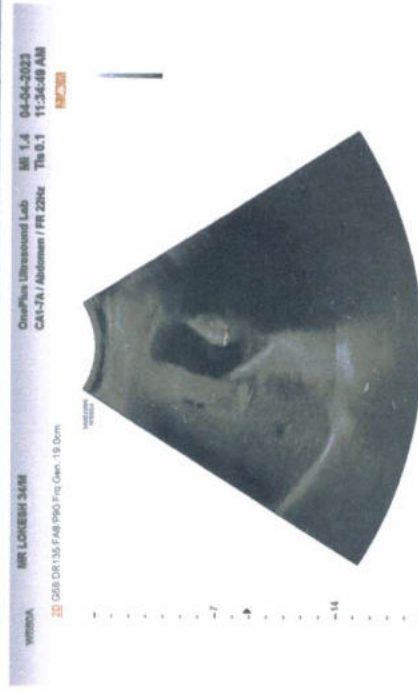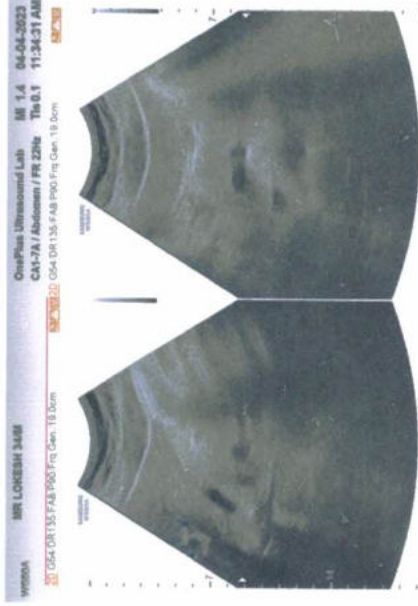No free fluid seen anywhere in abdomen.

IMPRESSION: Normal Study.

Dr. POOJA GARG
M.B.B.S., D.M.R.D.
Reg No DMC/R/03398
RADIOLOGIST
REG NO- DMC/R/03398

Type By : darshita

47, Harsh Vihar, Pitampura, New Delhi-110034 | Ph.: 011-42480101, 9599913051
E-mail: oneplusul@gmail.com | Web.: www.oneplusul.in



D1 3.64 cm
D2 3.95 cm
D3 2.93 cm
Vol 17.41 ml



OnePLUS
Ultrasound Lab
— QUALITY FIRST... ALWAYS! —

Dr. Nitin Agarwal

Pathologist & Director
Ex. Sr. Res. MAMC
& Lok Nayak Hospital
Ex. Chief of Lab Dr. Lal Path Labs.

Dr. Pooja (Garg) Agarwal

Radiologist & Director
MAMC & Lok Nayak Hospital

Name	: Mr. LOKESH KUMAR BHASKAR	Age/Sex	: 34 YRS/Male
Ref. By	: Dr. MEDIWHEEL	Lab No	: 012304040033
Date	: 04-Apr-2023	Patient ID	: LSHHI111932

X-ray-Chest PA view

Bony cage and soft tissues are normal.

Cardiothoracic ratio is normal.

Mediastinum is normal.

Both hila are normal.

Both costophrenic angles are clear.

Both domes of diaphragm are normal.

A nodular opacity is seen in right mid zone ? calcified granuloma. Rest of the lung fields are clear. No other parenchymal lesion seen.

Please correlate clinically.

DR. POOJA GARG
RADIOLOGIST
REG. NO. DMC/R/03398

Type By : darshita

47, Harsh Vihar, Pitampura, New Delhi-110034 | Ph.: 011-42480101, 9599913051
E-mail: oneplusul@gmail.com | Web.: www.oneplusul.in

ОИЕБГУС ПГТРАСОИИД ГЛВ.ДТ-НАРГН ВНАР.ПТАМПУРА
ГОКЕГН КУМАР ВНАСКАР ЗТМ 412033 M CHEST PA



В

R

LOKESH KUMAR BHASKAR 37Y/M 4/4/2021 M CHEST PA
ONEPLUS ULTRASOUND LAB. 47-HARSH VIHAR PITAMPURA