

Name : Mrs. INDIRA M NAIK

Age: 51 Y

UHID:CKOR.0000248309

Address : kml

Sex: F



Plan : ARCOFEMI MEDIWHEEL FEMALE AHC CREDIT PAN  
INDIA OP AGREEMENT

OP Number:CKOROPV389784

Bill No :CKOR-OCR-79253

Date : 30.11.2023 08:47

Sno	Service Type/ServiceName	Department
1	ARCOFEMI - MEDIWHEEL - FULL BODY ANNUAL PLUS CHECK ADVANCED - FEMALE - 2D ECHO - PAN INDIA - FY2324	
✓ 1	URINE GLUCOSE(FASTING)	
✓ 2	GAMMA GLUTAMYL TRANSFERASE (GGT)	
✓ 3	SONO MAMOGRAPHY - SCREENING	
✓ 4	HbA1c, GLYCATED HEMOGLOBIN	
✓ 5	2D ECHO	
✓ 6	LIVER FUNCTION TEST (LFT)	
✓ 7	X-RAY CHEST PA	
✓ 8	GLUCOSE, FASTING	
✓ 9	HEMOGRAM + PERIPHERAL SMEAR	
✓ 10	DENT CONSULTATION	
✓ 11	FITNESS BY GENERAL PHYSICIAN	
✓ 12	GYNAECOLOGY CONSULTATION	
✓ 13	DIET CONSULTATION	
✓ 14	COMPLETE URINE EXAMINATION	
✓ 15	URINE GLUCOSE(POST PRANDIAL)	
✓ 16	PERIPHERAL SMEAR	
✓ 17	ECG	
✓ 18	BLOOD GROUP ABO AND RH FACTOR	
✓ 19	LIPID PROFILE	
✓ 20	BODY MASS INDEX (BMI)	
✓ 21	LBC PAP TEST- PAPSURE	
✓ 22	ORTHAL BY GENERAL PHYSICIAN → (20)	
✓ 23	RENAL PROFILE/RENAL FUNCTION TEST (RFT/KFT)	
✓ 24	ULTRASOUND - WHOLE ABDOMEN	
✓ 25	THYROID PROFILE (TOTAL T3, TOTAL T4, TSH)	
✓ 26	DENTAL CONSULTATION	
✓ 27	GLUCOSE, POST PRANDIAL (PP), 2 HOURS (POST MEAL)	

28 physio  
29 dental  
30 opthal.

wt - 78.2 kg  
ht - 156 cm  
Bp - 98/64 mmofHg  
111/73 mmofHg  
pulse - 82 bts/mts

NAME: MRS. INDIRA M NAIK

AGE: 51Y

SEX: FEMALE

DATE: 30/11/2023

## ECHOCARDIOGRAPHY REPORT

### MEASUREMENT

AO -25(20 – 35)mm	LIVD d – 40(36-52)mm	IVS - 10 (06 - 11)mm
LA -28(19- 40)mm	LVID s - 27(23- 39)mm	PWD – 11(06- 11)mm
EF - 60% (>50%)	RVID-22	

### VALVES

Mitral Valve : Normal  
Aortic Valve : Normal  
Tricuspid Valve : Normal  
Pulmonary Valve : Normal

### CHAMBERS

Left Atrium : Normal  
Right Atrium : Normal  
Left Ventricle : Normal  
Right Ventricle : Normal

### SEPTAE

IVS : Intact  
IAS : Intact

**GREAT ARTERIES**

Aorta : Normal  
Pulmonary Artery : Normal

**DOPPLER DATA**

Mitral : E > A  
Aortic : Normal  
Tricuspid : Normal  
Pulmonary : Normal

WALL MOTION ABNORMALITIES : No RWMA

Pericardium : Normal

**FINAL DIAGNOSIS**

**NORMAL CHAMBERS AND VALVES  
NORMAL BIVENTRICULAR FUNCTION  
NO RWMA AT REST, LV EF -60%**



**DR. MOHAN MURALI  
CONSULTANT  
CARDIOLOGIST**

**Patient Name** : Mrs Indira M Nalk

**Patient ID** : 248309

**Age** : 51 Years

**Sex** : Female

**Referring Doctor** : H/C

**Date** : 30.11.23

**SONOMAMMOGRAPHY**

Both breast shows normal parenchymal echotexture. There is no evidence of distortion of parenchymal architecture.

There is no evidence of focal solid, cystic lesions or calcifications seen.

The nipple and areolar region show no abnormality.

The bilateral axillary region shows no abnormality and there is no evidence of enlarge lymph nodes.

**IMPRESSION: NORMAL SONOMAMMOGRAPHY STUDY – BIRADS 1**

  
**DR VINOD JOSEPH DNB,DMRD**  
**RADIOLOGIST**

OPHTHAL REPORT

NAME: Indira M naik  
GENDER: MALE/FEMALE ✓

AGE: 52

RIGHT EYE

	SPH	CYL	AXIS
DV	with glass		6/6
NV	"	"	N6

LEFT EYE

	SPH	CYL	AXIS
DV	with glass		6/6
NV	"	"	N6

REMARK: use same glasses

DATE: 20/1/23

chans  
OPTOMETRIST

BRING THIS PRESCRIPTION IN YOUR NEXT VISIT



**DR. MAHABALESHWAR.M**  
**MBBS.(MYS), MD(AIIMS DELHI)FICS**  
**D.O (JIPMER)**  
**REG.NO:KMC:9748**

**DATE: 30.11.22**  
**OP NO:**

**THE APOLLO MEDICAL CENTER KORAMANGALA**

**NAME:** *Indira Naik*  
**AGE :** *57*  
**GENDER:** *F*

**OPHTHALMIC REPORT**

**RIGHT EYE**

**LEFT EYE**

**GENERAL APPEARANCE**

**VISION - DISTANCE**

WITHOUT GLASS

*6/6*

*6/6*

WITH GLASS

GLASS POWER

**NEAR**

WITHOUT GLASS

*N6*

*N6*

WITH GLASS

GLASS POWER

**COLOUR**

*normal*

**ANTERIOR SEGMENT:-**

*Presbyopia*

**FUNDUS**

**I.O.P: DIGITAL**

**DOCTOR SIGNATURE**



Date  
MRNO  
Name  
Age/Gender:

: 30/11/23  
: m Indira  
: 51y

M/C

Department : OBSTETRICS & GYNAECOLOGY  
Consultant : DR JYOTHI RAJESH  
KMC NO-42823  
Qualification : DGO (DNB)  
Consultation Timings: 9.30pm to 12.00pm  
PHONE NO: 9972044580

Height :	Weight :	BMI :	Waist Circum :
Temp :	Pulse :	Resp :	B.P :

General Examination / Allergies  
History

Clinical Diagnosis & Management Plan

No gynae complaints  
menopause - 2y  
OBN, P2L2 F1P0  
Past 4 - 4/2000 on 4/20  
Family 11 - 2/05  
O/E. P/A 50/11  
Pls Cx @ LBC Lab

Follow up date:

Doctor Signature



**DR VIJAYA LAKSHMI M**  
**M.B.B.S, D.L.O, D.N.B(ENT)**  
**Phone No.9972044580,080-25633823/24/23**

30/11/23

**HEALTH CHECK- ENT**

**NAME:** *Iradia M. Naik P* **AGE:** *51*

**EAR:** **RE:** **LE:**

EXTERNAL EAR

MIDDLE EAR

INNER EAR (FN)

*Normal*

**HEARING ASSESSMENT:** **RE:** **LE:**

RHINNE

WEBER

ABC

*Normal*

NOSE

THROAT

AIRWAY

ORAL CAVITY

SEPTUM

OROPHARYNX

TURBINATES

PHARYNX

OTHERS

LARYNX

*Normal*

NECK

NECK NODES

OTHER

*Normal*

AUDIOMETRY

IMPRESSION

*Normal*

*[Signature]*

**SIGNATURE:**



Patient Name	: Mrs. INDIRA M NAIK	Age	: 51 Y F
UHID	: CKOR.0000248309	OP Visit No	: CKOROPV389784
Reported on	: 30-11-2023 13:38	Printed on	: 30-11-2023 13:57
Adm/Consult Doctor	:	Ref Doctor	: SELF

**DEPARTMENT OF RADIOLOGY**

**X-RAY CHEST PA**

Both lungs fields appear normal.

Both hila are normal.

Both costophrenic and cardiophrenic angles are normal.

The cardiac and mediastinal shadows appear normal.

Bones and soft tissues appear normal.

**IMPRESSION : NORMAL STUDY.**

  
DR VINOD JOSEPH DNB,DMRD  
RADIOLOGIST

Printed on:30-11-2023 13:38

---End of the Report---

**Patient Name** : Mrs Indira M Naik

**Patient ID** : 248309

**Age** : 51ear(s)

**Sex** : Female

**Referring Doctor** : H/C

**Date** : 30.11 .2023

**ULTRASOUND ABDOMEN AND PELVIS**

**Liver** is normal in size and shows increased echo pattern. No biliary dilatation .No focal lesion

**Portal vein** is normal in size, course and caliber. CBD is not dilated.

**Gall bladder** is normal without evidence of calculi, wall thickening or pericholecystic fluid

**Pancreas** to the extent visualized, appears normal in size, contour and echogenicity

**Spleen** is normal in size, shape, contour and echopattern. No evidence of mass or focal lesion.

**Right kidney** is normal in size, position, shape and echopattern. Corticomedullary differentiation is maintained. No evidence of calculi or hydronephrosis.

**Left kidney** is normal in size, position, shape and echopattern.corticomedullary differentiation is maintained. No evidence of calculi or hydronephrosis.

**Urinary Bladder** is well distended. wall thickness is normal. No internal echoes.

**Uterus:** is normal in size. Endometrial echoes are normal

**Endometrium:** measures 4.0 mm.

**Both ovaries** are normal in size and echopattern.

**Both adnexa:** Normal, no mass seen.

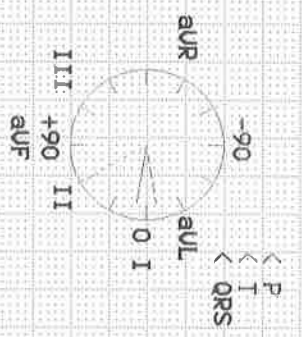
There is no ascites.

**IMPRESSION:**

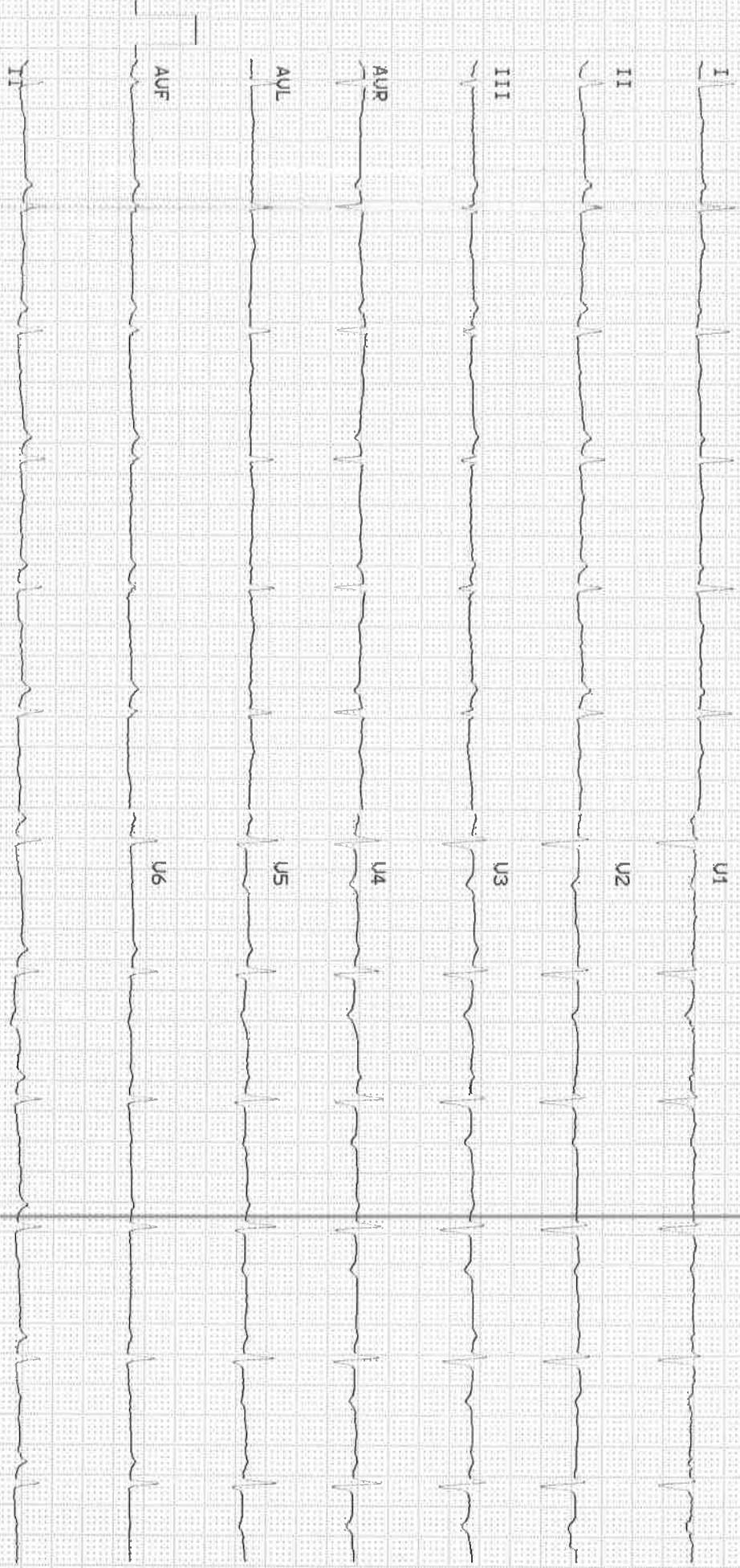
- **GRADE- I FATTY LIVER**

**DR VINOD JOSEPH DNB,DMRD**  
**RADIOLOGIST**

AGE: 51  
 Measurement Results:  
 QRS : 96 ms  
 QT/QTcB : 392 / 427 ms  
 PR : 164 ms  
 P : 102 ms  
 RR/PP : 844 / 845 ms  
 P/ORS/T : 60 / 10 / -10 degrees  
 QTd/QTcBd : 46 / 50 ms  
 Sokolow : 1.1 mV  
 NK : 10



Interpretation:



Unconfirmed report.

SR

Patient Name	: Mrs. INDIRA M NAIK	Age	: 51 Y/F
UHID	: CKOR.0000248309	OP Visit No	: CKOROPV389784
Reported By:	: Dr. MOHAN MURALI	Conducted Date	: 30-11-2023 15:27
Referred By	: SELF		

### ECG REPORT

#### Observation :-

1. Normal Sinus Rhythm.
2. Heart rate is 71beats per minutes.
3. No pathological Q wave or S-T,T changes seen.
4. Normal P,Q,R,S,T waves and axis.
5. No evidence of chamber, hypertrophy or enlargement seen.

#### Impression:

NORMAL RESTING ECG.

Dr. MOHAN MURALI  
CARDIOLOGIST

NOTE : KINDLY TAKE A PHOTOCOPY OF THE GRAPH  
FOR FUTURE REFERENCE IF NEEDED.

----- END OF THE REPORT -----

## Apollo Clinic

### Consent Form

Patient Name: Mohan Naik & Indira Naik Age: 54 / 51 years

UHD Number: ..... Company Name: Bank of Baroda

I Mr/Mrs/Miss: ..... Employee of Bank of Baroda

(Company) want to inform you that I am not getting the Consultation

Test which is a part of health check package.

Reason if any: 16-12-2023 - coming for consultation

And I claim the above statement in my full consciousness.

Patient Signature:  Date: 30-11-2023