



# ABI SCANS & LABS

A unit of Aarthi Scans and Labs

Patient Name	MR.JEYAKUMAR J	Age	54Yr
Patient ID	133107	Sex	Male
Referral Dr	MEDIWHEEL	Study Date	27 Mar 2023

## X-RAY - CHEST PA VIEW

### **OBSERVATION:**

The trachea is central.  
The mediastinal and cardiac silhouette are normal.  
Cardiothoracic ratio is normal.  
Cardiophrenic and costophrenic angles are normal.  
Both hila are normal.  
Lung zones are clear.  
Bones of the thoracic cage are normal.  
Soft tissues of the chest wall are normal.

### **IMPRESSION:**

**No significant abnormality seen.**

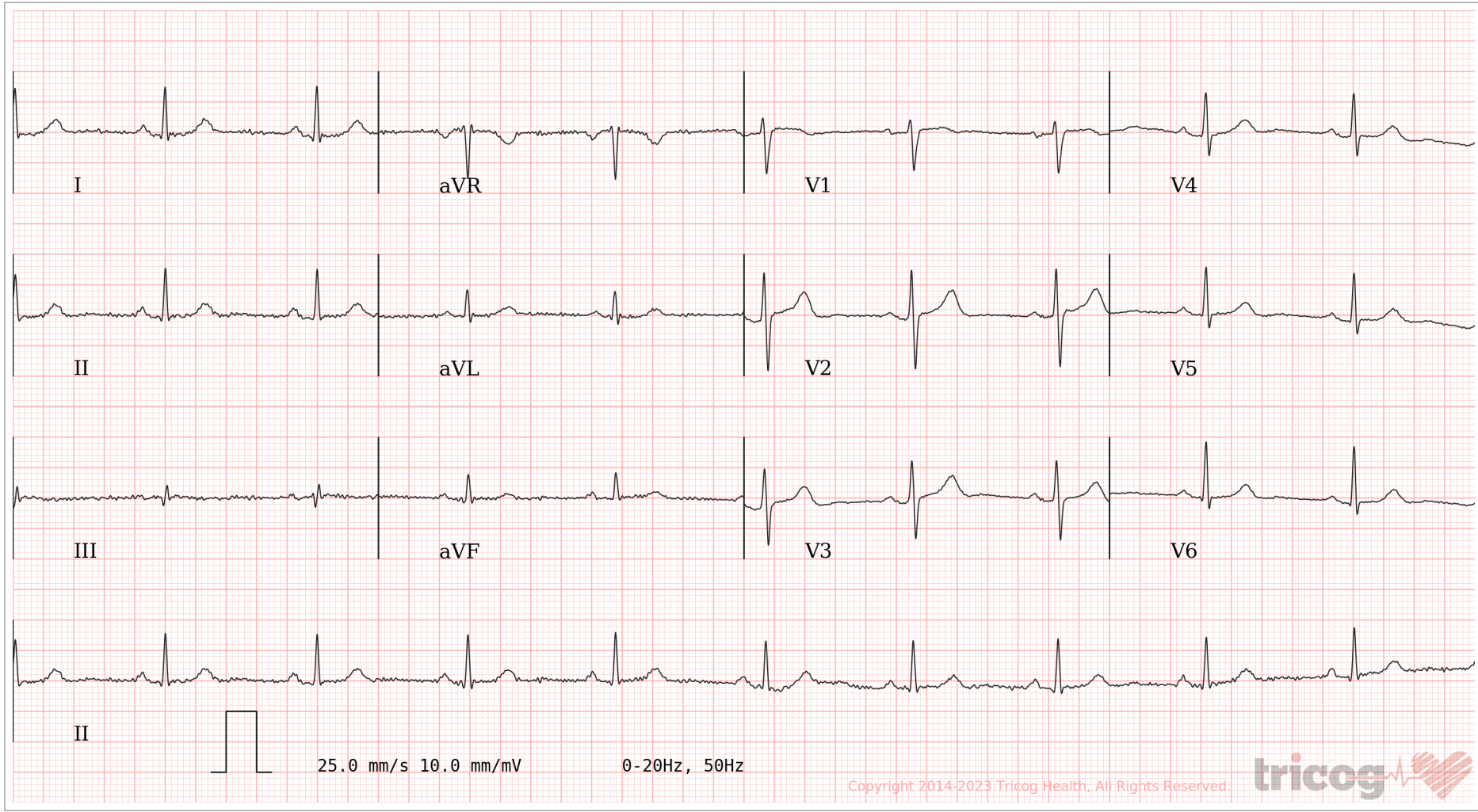

Dr. Abinaya., MD., (RD)  
Consultant Radiologist

# Aarthi CT and MRI Scans, R S Puram West



Age / Gender: 54/Male  
Patient ID: 0000125895  
Patient Name: MR. JEYAKUMAR J

Date and Time: 27th Mar 23 10:13 AM



AR: 62bpm    VR: 62bpm    QRSD: 74ms    QT: 392ms    QTc: 397ms    PRI: 156ms    P-R-T: 36° 36° 39°

**ECG Within Normal Limits: Sinus Rhythm. Please correlate clinically.**



Disclaimer: Analysis in this report is based on ECG alone and should only be used as an adjunct to clinical history, symptoms and results of other invasive and non-invasive tests and must be interpreted by a qualified physician.



# ABI SCANS & LABS

A unit of Aarthi Scans and Labs

Patient Name	MR. JEYAKUMAR J	Age	54Yr
Patient ID	125895	Sex	Male
Referral Dr	MEDIWHEEL	Study Date	27 Mar 2023

## USG REPORT - ABDOMEN AND PELVIS

### LIVER:

Is normal in size and shows normal echo texture.

No obvious focal lesion seen. No intra – Hepatic biliary radical dilatation seen.

### GALL BLADDER:

Is adequately distended. No calculus or internal echoes are seen. Wall thickness is normal.

### PANCREAS:

Appears normal in size and it shows uniform echo texture.

### SPLEEN:

Is normal in size and shows uniform echogenicity.

### RIGHT KIDNEY:

The shape, size and contour of the right kidney appear normal.

Cortico medullary differentiation is within normal.

No evidence of pelvicalyceal dilatation.

No calculi seen.

### LEFT KIDNEY:

The shape, size and contour of the left kidney appear normal.

Cortico medullary differentiation is within normal.

No evidence of pelvicalyceal dilatation.

No calculi seen.

### URINARY BLADDER:

Is normal contour. No intra luminal echoes are seen.

### PROSTATE:

Prostate appears normal, Measures ~ 2.3 x 2.4 x 3.8 cms (Vol – 11 cc).



# ABI SCANS & LABS

A unit of Aarthi Scans and Labs

Patient Name	MR. JEYAKUMAR J	Age	54Yr
Patient ID	125895	Sex	Male
Referral Dr	MEDIWHEEL	Study Date	27 Mar 2023

## **RIGHT ILIAC FOSSA:**

No focal fluid collections seen.

No evidence of hernia seen in anterior abdominal wall.

## **IMPRESSION:**

- **No significant abnormality seen in the present study.**
- **Suggested clinical correlation.**

**Dr. S. Sudalaimuthu., MBBS., DMRD.,  
Consultant Radiologist**