



AMRUTHA SAI DIAGNOSTIC CENTRE



Cell: 868 898 4900, 9966 77 4621

email: amruthasailab@gmail.com

ISO.9001:2015 Certificate Number: Q91864141412

Name :- Mr H Kesava Hari kumar

Age/Sex :- 46 y/male

Date :- 31-03-2022

Ref.by :- Mediwheel (BOBES-11285)

ID.No:- D2/2022

EMPLOYEE MEDICAL CHEK UP FORM

Physical Examination :-

Height :- 174 cms.

Weight :- 85 kgs.

Abdomen (CMS) :- 97cms

Chest Expir(CMS):- 90

Chest Insp(CMS) : 95

Body mass index(BMI) :- 24.9

Pulse Rate :- 74 minute. (Regular / Abnormal)

Skin :- Normal Open Lesions :- Nil

Oral Hygeine : Healthy

Complaints if Any :- Nil

Family History :- Nil

Complaints if Any :- Nil

Systemic Examination (Abnormality – if Yes Please Explain) :-

CVS - Yes/ No

CNS - Yes/ No

Gi Tract - Yes/No

Abdomen - Yes/ No

Respiratory Tract - Yes/ No

INVESTIGATIONS : (N= Normal, R= See Report)

Complete Blood Picture With ESR = NORMAL

Complete Urine Examination = NORMAL

FBS, PLBS = NORMAL

Colour Vision = NORMAL

USG = NORMAL

* ECG = NORMAL

* SGPT = NORMAL

* Cholesterol = NORMAL

* Eye Examination = NORMAL

* 2D ECHO = NORMAL

Diagnosis (If Any) :- Nil

RECOMMENDATIONS / IMPRESION :- Nil

Dr. V.Narayanappa,
PHYSICIAN SIGNATURE, S.F.C.C.P.
PHYSICIAN & SURGEON
Regd.No. 06543
Authorised Doctor,
For State Bank of India
ANANTAPUR

Under AP Govt. Regd. Diagnostic Centre R.No.98/2012-2013

Genuineness is our gene



बैंक ऑफ बड़ोदा
Bank of Baroda



नाम एच. केशव हरि कुमार
Name Hariyapuraju Kesava Hari Kumar


इलेक्ट्रॉनिक नंबर
E. C. No. 56661

अधिकारी
Issuing Authority

होल्डर
Signature of Holder

1 Hariyapuraju

1st Cross, Sai Nagar,
Near Surya Nagar Bus Stop,
ANANTAPURAMU - 515001.
Contact : +91 79893 30974



VASUNDHARA
DIAGNOSTICS
FETAL MEDICINE CENTRE

Patient Name : Mrs. H.Kesava Hari
Referred By : Amrutha Sai diagnostic center

Patient Id : 220330-003 Gender/Age : Female / 46 Y
Reg Date : 30-03-2022

ULTRASONOGRAPHY OF WHOLE ABDOMEN

- Liver** : Normal in size(12.4cm) with normal echotexture.
No focal lesions or dilated biliary radicles.
No IHBD / CBD dilatation. Portal vein is normal.
- Gall bladder** : Well distended . No calculi . No wall thickening.
- CBD** : Normal in course and calibre .Lumen echo free.
- Portal vein** : Normal in size and course. Lumen echo free .
- Spleen** : Normal in size(10cm) with normal echotexture. No focal lesions.
- Pancreas** : Head, body, visualized parts of tail are normal. No focal lesions
or peripancreatic collections are seen.
- Kidneys** : Right kidney: 9 x 4.1 cm Left kidney: 9.8 x 4.4 cm.
Normal in size, shape and echotexture.Corticomedullary junction made out.
Renal cortical thickness measuring 16.5 mm on right side and 18mm on left side
Prominent right renal pelvis -Likely Extra renal pelvis
Mild dilated left pelvicalyceal system with disproportionately dilated renal pelvis
- Urinary bladder** : Well distended. No calculi are seen.No wall thickening seen.
- Prostate** : Normal in size and echotexture.Volume measuring 13.5cc
- Others** : No evidence of ascites. Appendix not seen due to bowel gas.
No evidence of lymph node enlargement. No obvious inflammed bowel seen
- Impression** : **Mild left hydronephrosis with disproportionately dilated renal pelvis**
-Likely Partial PUJ stricture /?? Extra renal pelvis

Dr.N.Vasundhara
MD Radiology
Consultant in fetal medicine

For clinical correlation please...

Handwritten signature

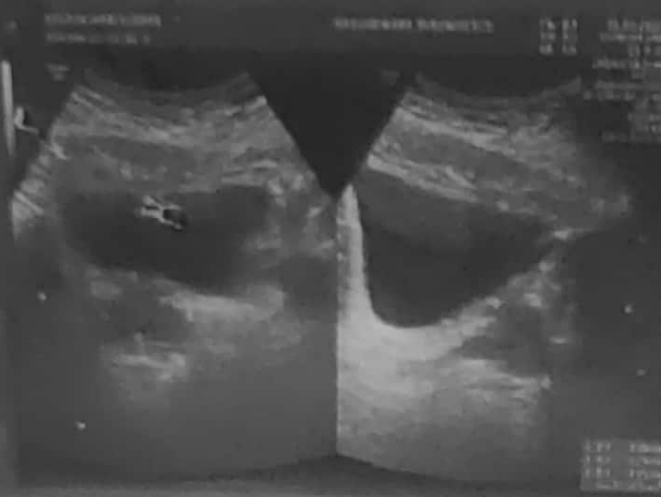
ED0306 22-03-2022

KEJAYA HARI KUMAR

30 03 2022 10:06:12 AM

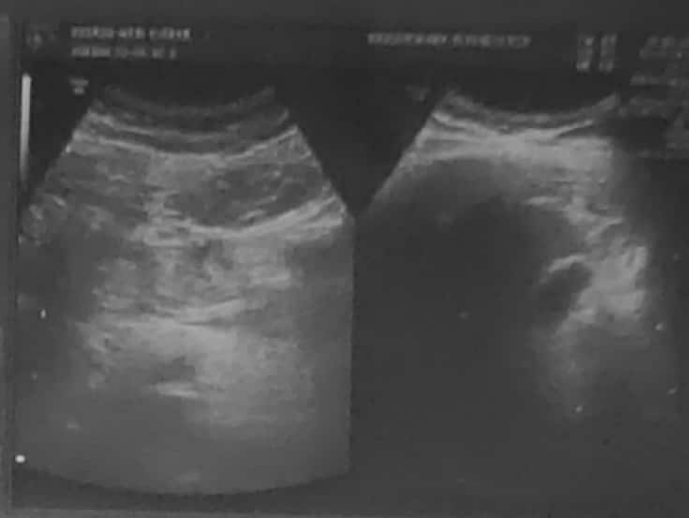Layout 2x2

1 / 2 / 10



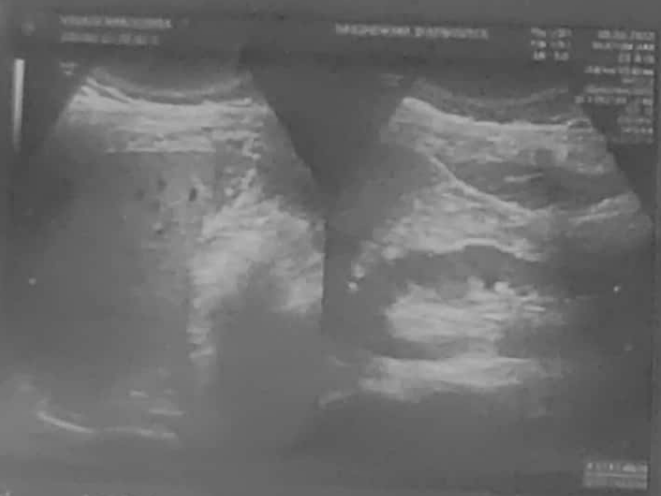
Default Full Data

2D



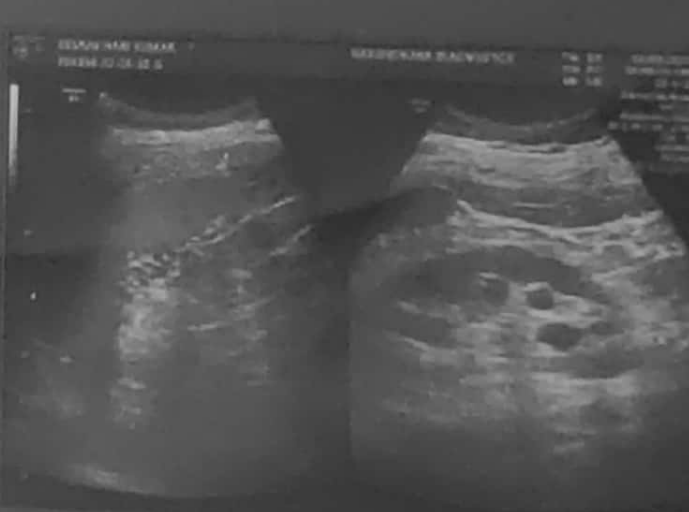Reload Full Data

2D



Default Full Data

2D



Reload Full Data

2D



AMRUTHA SAI DIAGNOSTIC CENTRE



Cell: 868 898 4900, 9966 77 4621

email: amruthasailab@gmail.com

ISO.9001:2015 Certificate Number: Q91864141412

Patient Name : Mr H Kesava Hari kumar Sex : Male Age : 46 Yrs

Id.No : D2/22 Bill Date : 30-03-2022 Report Date : 30-03-2022

Ref. by : Mediwheel Health chek Address : A T P

LAB REPORT

Blood For :-

Parameter	Findings	Reference Range
Complete Haemogram (CBP) :-		
Haemoglobin % (C M G)	: 13.0 gm %	M : 12.0 – 17.0 gm %
Total WBC Count	: 9100 ce/cu mm	A : 4000 – 11000 ce/cu mm
Differential WBC Count	: Neutrophils – 60 % Lymphocytes – 34 % Eosinophils – 04 % Monocytes – 02 %	45 – 65 % 25 – 45 % 01 – 06 % 02 – 08 %
E S R (Westergren Method)	: 28 mm/ 1 hr	M : 01 – 15 mm/1 hr
RBC Count	: 4.8 mill/cu mm	M : 4.5 – 6.5 mill/cu mm
Platelet Count	: 3.1 Lach/cu mm	1.5 – 4.0 Lach/cu mm
Packed Cell Volume (PCV)	: 44.1 %	M : 40 – 54 %
Mean Corpuscular Volume (MCV)	: 83.2 fl	82 – 92 fl
Mean Corpuscular Haemoglobin (MCH)	: 28.6 pg	27 – 32 pg
Mean Corpuscular Haemoglobin Concentration (MCHC)	: 32.9 %	32 – 36 %

TEST NAME	METHOD	VALUE	UNITS
GLYCOSYLATED HAEMOGLOBIN (Hb A1 c) %	TURBIDOMETRY	5.88	%

Reference Range :-

BELOW 6.0 %	- NORMAL VALUE
6.0 % - 7.0 %	- GOOD CONTROL
7.0 % - 8.0 %	- FAIR CONTROL
8.0 % - 10.0 %	- UNSATISFACTORY CONTROL
ABOVE 10.0 %	- POOR CONTROL

@ Suggested clinical Correlation, If there is need, kindly discuss.

S. Vijaya Lakshmi
LAB INCHARGE
S. Vijaya Lakshmi
M.Sc (Biochemistry)

Under AP Govt. Regd. Diagnostic Centre R.No.98/2012-2013

Genuineness is our gene



AMRUTHA SAI DIAGNOSTIC CENTRE



Cell: 868 898 4900, 9966 77 4621

email: amruthasailab@gmail.com

ISO.9001:2015 Certificate Number: Q91864141412

Patient Name : Mr H Kesava Harl kumar

Sex : Male

Age : 46 Yrs

Id.No : D2/22

Bill Date : 30-03-2022

Report Date : 30-03-2022

Ref. by : Mediwheel Health chek

Address : A T P

LAB REPORT

Blood For :-

Parameter	Findings	Reference Range
LIPID PROFILE :-		
Cholesterol Total	: 192 mg/dl	150 - 260 mg/dl
H D L Cholesterol	: 35 mg/dl	M : 35 - 55 mg/dl
Triglycerides	: 207 mg/dl	36 - 165 mg/dl
L D L Cholesterol	: 109 mg/dl	66 - 178 mg/dl
V L D L Cholesterol	: 48 mg/dl	5 - 40 mg/dl
CHOL : HDL Chole	: 5.1 : 1	3.0 - 5.0 : 1
Fasting Blood Sugar	: 87 mg/dl	65 - 110 mg/dl
Post Prandial Blood Sugar	: 136 mg/dl	80 - 160 mg/dl
Reanal Function Test (RFT) :-		
Blood Urea	: 31 mg/dl	15 - 45 mg/dl
Serum Creatinine	: 1.2 mg/dl	0.7 - 1.4 mg/dl
Serum Uric Acid	: 5.9 mg/dl	3.0 - 5.7 mg/dl
Serum Calcium	: 9.1 mg/dl	8.7 - 10.4 mg/dl
LIVER FUNCTION TEST (LFT) :-		
Bilirubin Total	: 0.7 mg/dl	0.1 - 1.0 mg/dl
Bilirubin Direct	: 0.18 mg/dl	0.0 - 0.25 mg/dl
Bilirubin Indirect	: 0.5 mg/dl	0.2 - 0.8 mg/dl
Total Proteins	: 6.5 gm/dl	6.0 - 8.0 gm/dl
Albumin	: 4.3 gm/dl	3.7 - 5.3 gm/dl
Globulins	: 3.2 gm/dl	2.5 - 4.5 gm/dl
S G O T (A S T)	: 28 IU/L	Upto - 40 IU/L
S G P T (A L T)	: 34 IU/L	Upto - 47 IU/L
Alkaline Phosphatase (ALP)	: 174 IU/L	A : 100 - 290 IU/L
Gamma Glutamyl Transferase (GGT)	: 38 IU/L	M : Upto - 50 IU/L

@ Suggested clinical Correlation, If there is need, kindly discuss.

S. Vijaya Lakshmi
LAB IN CHARGE

S. Vijaya Lakshmi
M.Sc (Biochemistry)

Under AP Govt. Regd. Diagnostic Centre R.No.98/2012-2013

Genuineness is our gene



AMRUTHA SAI DIAGNOSTIC CENTRE



Cell: 868 898 4900, 9966 77 4621

email: amruthasailab@gmail.com

ISO.9001:2015 Certificate Number: Q91864141412

Patient Name : Mr H Kesava Hari kumar Sex : Male Age : 46 Yrs

Id.No : D2/22 Bill Date : 30-03-2022 Report Date : 30-03-2022

Ref. by : Mediwheel Health chek Address : A T P

LAB REPORT

Blood For :-

BIO-CHEMISTRY REPORT

<u>zTest Name</u>	<u>Technology</u>	<u>Value</u>	<u>units</u>
Prostate Specific Antigen(PSA)	C L I A	3.71	ng/ml

Reference Range :-

Normal : Less than 4.00 ng/ml

Borderline : 4.01 - 10.00 ng/ml

Complete Urine Analysis(C U A) :-

Physical Examination :-

Colour	: Yellow	Transparency	: Clear
Reaction	: Acidic	Sediment	: NIL
Sp.Gravity	: 1.011	pH	: 6.5


Chemical Examination :-

Sugar	: Absent	Proteins	: Traces
Bile Salts	: Absent	Bile Pigments	: Absent
Urobilinogen	: Normal	Ketone Bodies	: Negative
Blood	: Absent		

Microscopic Examination :-

Pus Cells	: 6 - 8 /hpf	E.P.Cells	: 5 - 6 /HPF
RBC's	: Absent	Casts	: Absent
Crystals	: Absent	Deposits	: Absent
Bacteria	: Absent		

@ Suggested clinical Correlation, If there is need, kindly discuss.


LAB INCHARGE
S. Vijaya Lakshmi
M.Sc (Biochemistry)

Note:- Amrutha Sai Diagnostic Centre . (Fully Automated A/C Laboratory)
***** Since - 25 Years *****

Opp.Balaji Kalyana Mantapam, Near RTC Bus Stand, Reliance Mart Road,
Srenivasa Nagar, ANANTHAPURAM. CELL - 86 88 984900.

Under AP Govt. Regd. Diagnostic Centre R.No.98/2012-2013

Genuineness is our gene



MALVINA HOSPITAL & EYE CENTRE



Name of the patient : H.KESAVA HARI KUMAR Date: 30-03 -2022
 Age/Sex : 46Y/M
 Done by : Dr. J.MILTON ALFRED., Cons. Cardiologist

2D ECHO / COLOUR DOPPLER REPORT

Mitral Valve	: NORMAL		
Tricuspid valve	: NORMAL		
Aortic Valve	: NORMAL		
Pulmonary valve	: NORMAL		
IVSD	: 1.06	cm	
LVISDD	: 4.41	cm	EDV: 85 ml
LVPWD	: 1.06	cm	ESV: 30 ml
IVSS	: 1.23	cm	
LVIDS	: 2.73	cm	
LVPWS	: 1.23	cm	
EF	: 68	%	
FS	: 38	%	
LA	: 3.0	cm	
IVs	: INTACT		
IAS	: INTACT		
RA	: NORMAL		
RV	: NORMAL		
Pulm artery	: NORMAL		
AORTA	: 2.5	cm	
Doppler Data	: NO MR/AR/TR		
Mitral Flow	:	E/A = 1.4	
A.F	:	AJV: 125	cm/s
PF	:	PJV: 95	cm/s
TF	:	PAT: 105	ms
Pericardium	: NO PERICARDIAL EFFUSION, NO CLOT.		
Others	:		
Impression	: NORMAL SIZED CARDIAC CHAMBERS, NORMAL VALVES, NO RWMA, NO MR/AR/TR, NO PAH, NO IC SHUNTS, NORMAL LV/RV SYSTOLIC FUNCTION, NO PE, NO CLOT.		

Handwritten signature

Dr. J.MILTON ALFRED., Cons. Cardiologist

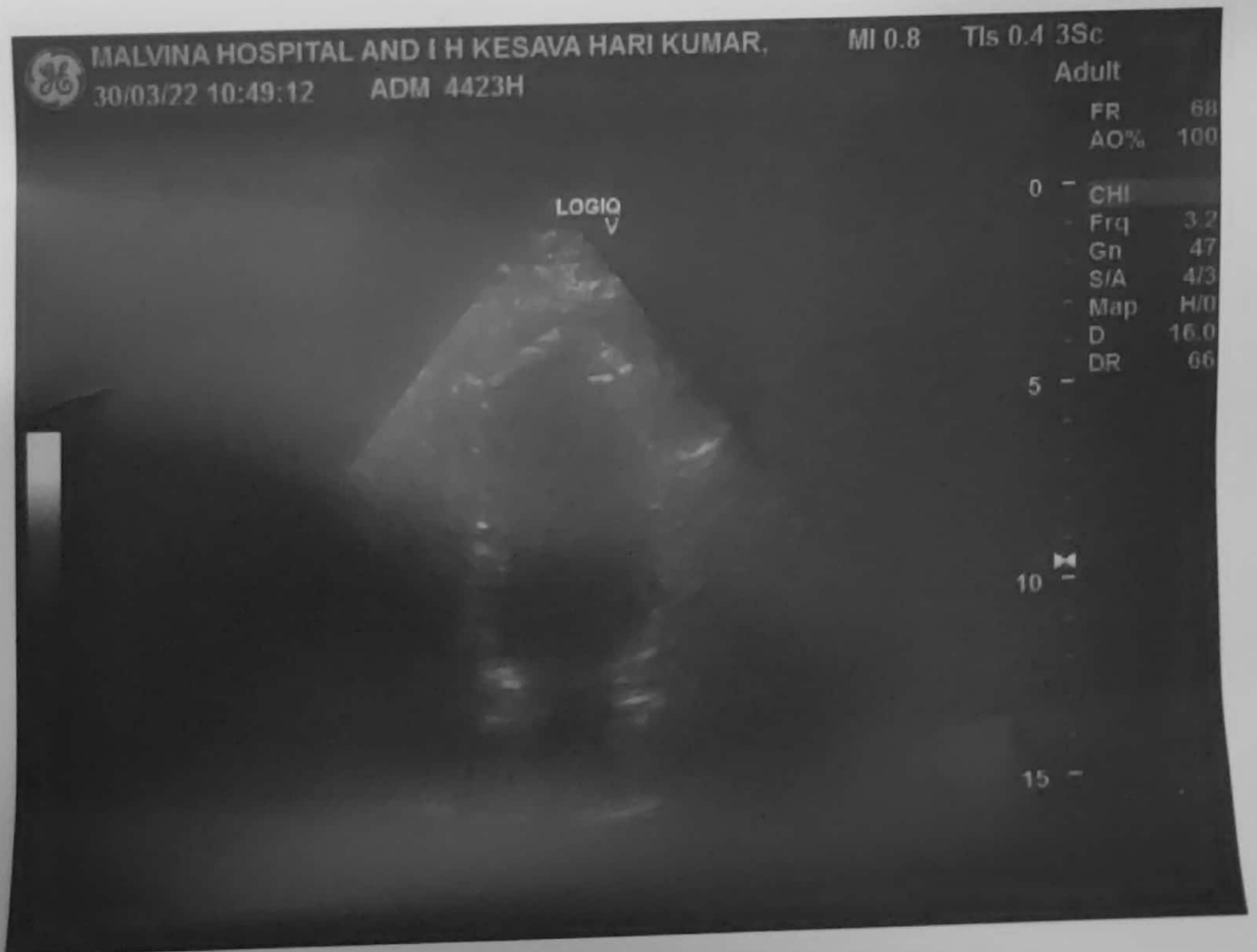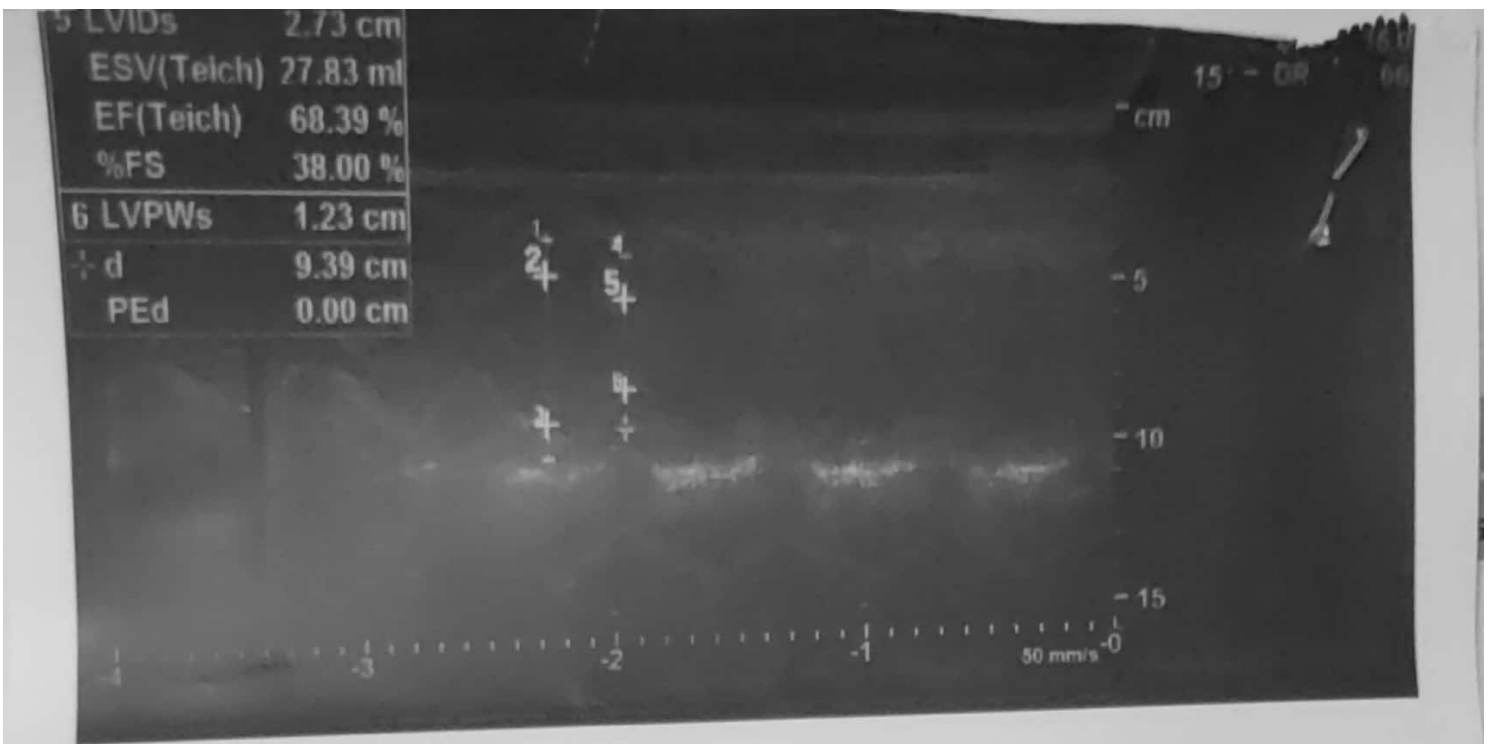
Handwritten signature of Dr. J. Milton Alfred
 M.B.B.S., M.D. (Medicine, D.M. Cardiology)
 Regd. No. 28075
 MALVINA HOSPITAL & EYE CENTRE
 8th Cross, SAI NAGAR, ANANTHAPURAMU

Recognized by Dr. Y. S. R. Aarogysri and E. H. S

Phone : 08554 - 226000, Cell : 9441722666



12-2-820, SAI NAGAR, 8th CROSS, ANANTHAPURAMU.





AMRUTHA SAI DIAGNOSTIC CENTRE



Cell: 868 898 4900, 9966 77 4621

email: amruthasailab@gmail.com

ISO.9001:2015 Certificate Number: Q91864141412

Mr H KESAVA HARI KUMAR
Age : 46 Year(s) Male

APL Code : APL-AP-271
Ref Doctor: SELF
Customer : AMRUTHA SAI
DIAGNOSTIC CENTER-ANANTAPUR

Sample Type : SERUM
SID : 1340261
Collected on : 2022-03-30 07:10
Regd on : 2022-03-31 10:29
Reported On : 2022-03-31 12:02



CLINICAL BIOCHEMISTRY

Test Description	Result	Units	Biological Reference Ranges
THYROID PANEL I			
Triiodothyronine Total (TT3) <small>(Method: Chemiluminescence)</small>	130.21	ng/dL	80 - 253 : 1 Yr-10 Yr, 76 - 199 : 11 Yr-15 Yr, 69 - 201 : 16 Yr-18 Yr, 87 - 178 : > 18 years.
Thyroxine - Total (TT4) <small>(Method: Chemiluminescence)</small>	10.69	µg/dL	5.9 - 21.5 : 0-31 Days, 5.9 - 21.5 : 0-1 Month 6.4 - 13.9 : 2-12 Months 6.09- 12.23 : >1 Yr
Thyroid Stimulating Hormone (TSH) <small>(Method: Ultra-sensitive chemiluminescence)</small>	0.78	µIU/mL	0.52-16.0 : 1 Day - 30 Days 0.55-7.10 : 1 Mon-5 Years 0.37-6.00 : 6 Yrs-18 Years 0.38-5.33 : 18 Yrs-88 Years 0.50-8.90 : > 88 Years

Clinical features of thyroid disease

Hypothyroidism	Hyperthyroidism	Grave's disease
<ul style="list-style-type: none"> Lethargy Weight gain Cold intolerance Constipation Hair loss Dry skin Depression Bradycardia Memory impairment Menorrhagia 	<ul style="list-style-type: none"> Tachycardia Palpitations (atrial fibrillation) Hyperactivity Weight loss with increased appetite Heat intolerance Sweating Diarrhoea Fine tremor Hyper-reflexia Goitre Palmar erythema Onycholysis Muscle weakness and wasting Oligomenorrhoea/amenorrhoea 	<ul style="list-style-type: none"> Exophthalmos/proptosis Chemosis Diffuse symmetrical goitre Pretibial myxoedema (rare) Other autoimmune conditions Thyroid bruit

Ch.Samuel
Manager Technical



Dr S.V.RAMANA
MD PATHOLOGIST

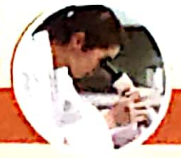This is an electronically authenticated report. Report printed date : 31/03/2022 13:32
NOTE : Assay results should be correlated clinically with other clinical findings and the total clinical status of the patient.

Genuineness is our gene

Report #



AMRUTHA SAI DIAGNOSTIC CENTRE



Cell: 868 898 4900, 9966 77 4621

email: amruthasailab@gmail.com

ISO.9001:2015 Certificate Number: Q91864141412

Patient Name : Mr H Kesava Hari kumar Sex : Male Age : 46 Yrs

Id.No : D2/22 Bill Date : 30-03-2022 Report Date : 30-03-2022

Ref. by : Mediwheel Health chek Address : A T P

XRAY-CHEST (PA) VIEW

- Trachea is central
- Both th lung fields appear normal.
- Hilar shadows are with in normal limits.
- Pulmonary vasculatures are normal.
- Cardia is normal in size.
- Both domes of the diaphragm are smooth.
- Both costophrenic recesses are clear.
- Visualized bonesand soft tissue showds appear normal.

IMPRESSION :- NORMAL X-RAY.

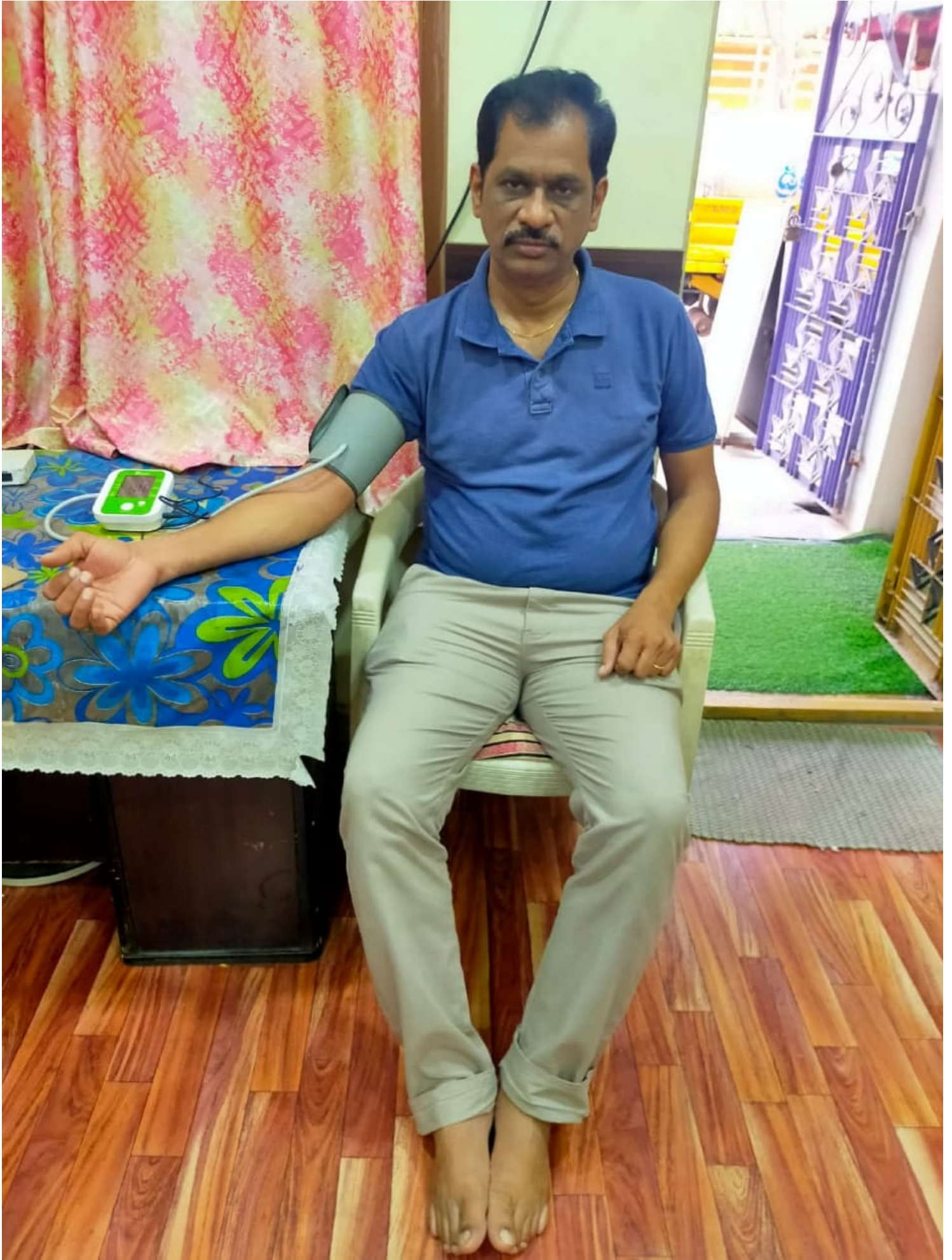Dr K. RADIARANI. MD
Specialist in Ultr- Sound
Radio Diagnosis & C.T. Scan
Asst. Civil Surgeon
Govt. Medical College &
General Hospital
ANANTHAPUR
RADIOLOGIST SIGNATURE

Note:- Amrutha Sai Diagnostic Centre . (Fully Automated A/C Laboratory)
***** Since - 25 Years *****

Opp.Balaji Kalyana Mantapam, Near RTC Bus Stand, Reliance Mart Road,
Srenivasa Nagar, ANANTHAPURAM. CELL - 86 88 984900.

Under AP Govt. Regd. Diagnostic Centre R.No.98/2012-2013

Genuineness is our gene



R00
CHEST PA

AMRUTHA SAI DIAGNOSTIC CENTER
H KESAVA HARI KUMAR, 46 Y
02
30-Mar-22
Acq Tm: 02:47 PM



LEFT

3520 X 4280

W: 4095 L: 2048

H KESAVA HARI KUMAR, 46 Y 02 CHEST PA 30-Mar-22 02:46 PM

AMRUTHA SAI DIAGNOSTIC CENTRER, OPP. BALAJI KALYANAMANDAPAM, SRINIVASA NAGAR, ANANTAPUR, 8688984900