

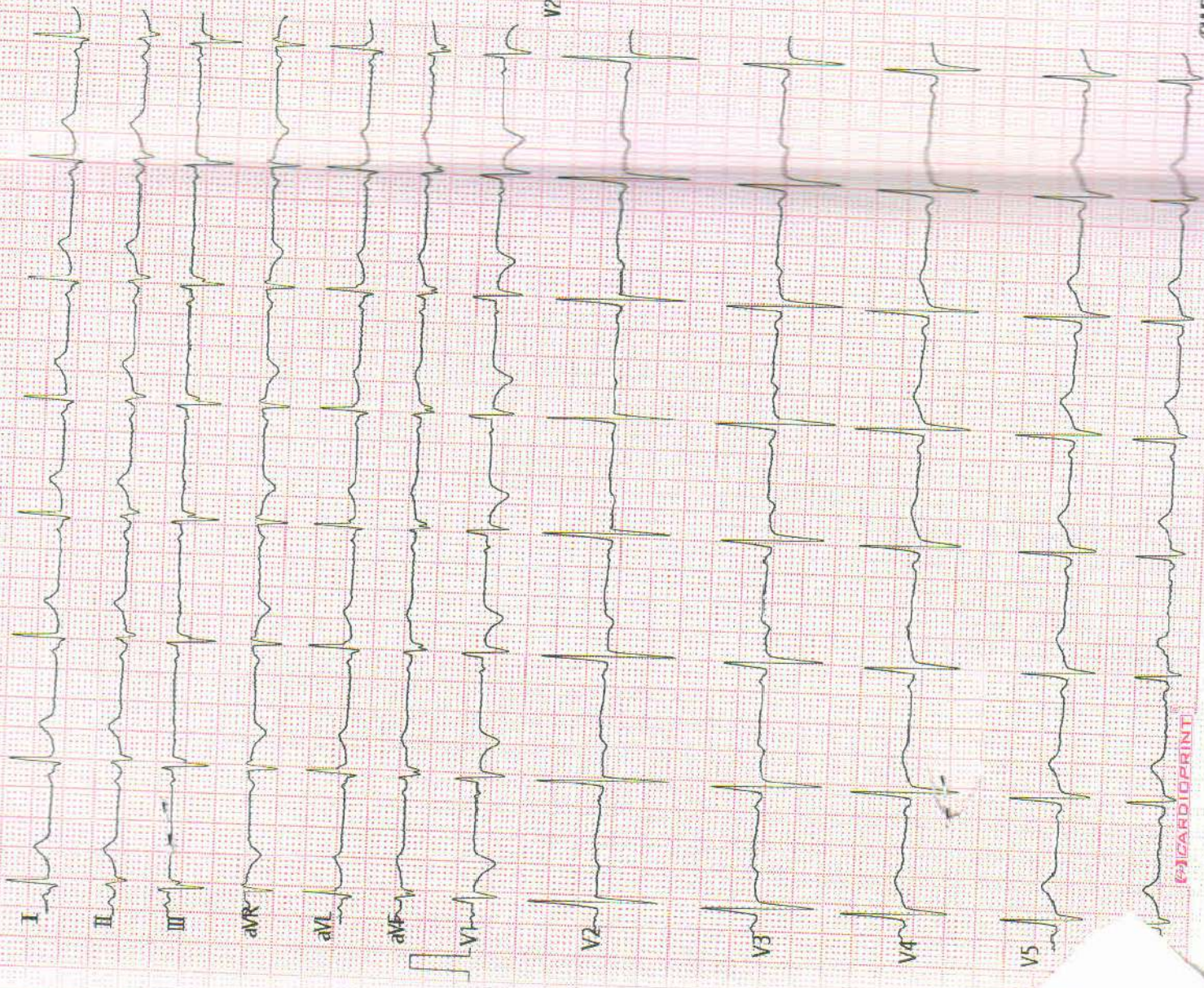
MER- MEDICAL EXAMINATION REPORT

Date of Examination	27/08/2022		
NAME	Bhupeshh mali		
AGE	32	Gender	
HEIGHT(cm)	5.4	WEIGHT (kg)	62
B.P.	125/90		
ECG	normal		
X Ray	normal		
Vision Checkup	normal		
Present Ailments			
Details of Past ailments (If Any)			
Comments / Advice : She /He is Physically Fit	fit		

Dr. BHARAT JAIN
 INSURANCE MEDICINIST
 17/11/2017

Signature with Stamp of Medical Examiner

10mm/mV



Vent. Rate(BPM) : 71

PR Int.(ms) : 132

P/QRS/T Int.(ms) : 99 101 175

QT/QTc Int.(ms) : 370 406

P/QRS/T Axis(Deg.) : 31 25 25

RV1/SV5 Amp.(mV) : 0.34 0.43

RV5/SV1 Amp.(mV) : 0.79 0.41

V2.33 Technician :

<ECG Analysis Result>

800 Normal Sinus Rhythm

611 T Abnormality(Flat T)

212 Left Axis Deviation

*** Borderline Abnormal ECG ***

Note: Unconfirmed Report Need to Review.

ST LEVEL(mV)

I	II	III	aVR	aVL	aVF
+0.02	+0.03	+0.00	-0.03	+0.00	+0.01
V1	V2	V3	V4	V5	V6
-0.03	+0.01	+0.00	+0.02	+0.03	+0.03

ECG CARDIOPRINT

Name	: Mr. Bhupesh mali	Age	: 32yrs. / M
Thanks To	: Mediwhell wellness	Date	: 27-08-2022

ULTRASOUND STUDY OF WHOLE ABDOMEN

LIVER

Liver is normal in size, shape & echotexture. No focal mass lesion is seen. Intra hepatic biliary radicles are normal. Portal vein is normal in caliber.

GALL BLADDER

Gall bladder is well distended. The wall thickness appears normal. No evidence of calculus or mass lesion is seen. C.B.D. appears normal.

PANCREAS

Pancreas is normal in size, shape & echotexture. No focal mass lesion is seen.

SPLEEN

Spleen is normal in size, shape & echotexture. No focal mass lesion is seen.

BOTH KIDNEYS

Both kidneys are normal in size, shape & echotexture. Renal parenchyma appears normal. No evidence of hydronephrosis, calculus or cortical scarring is seen in either kidney.

Right kidney measures : 8.91 x 5.0 cms.

Left kidney measures : 10.1 x 4.3 cms.

URINARY BLADDER

Urinary bladder is well distended and appears normal in contour. The wall thickness appears normal.

PROSTATE

Prostate is normal in size, shape and echotexture. It measures 3.3 x 3.0 x 3.2cms. Volume:16cc.

No obvious abdominal lymphadenopathy is seen.

No free fluid is seen in peritoneal cavity.

OPINION:

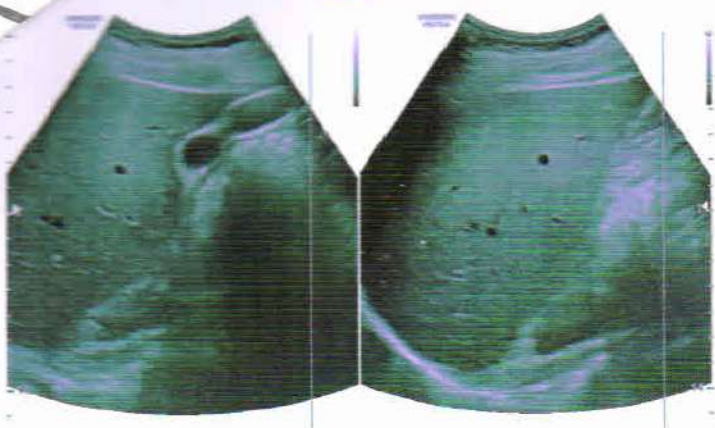
- No significant abnormality is seen.


Dr. Bharat Jain
MD (Radio-Diagnosis)
Consultant Radiologist

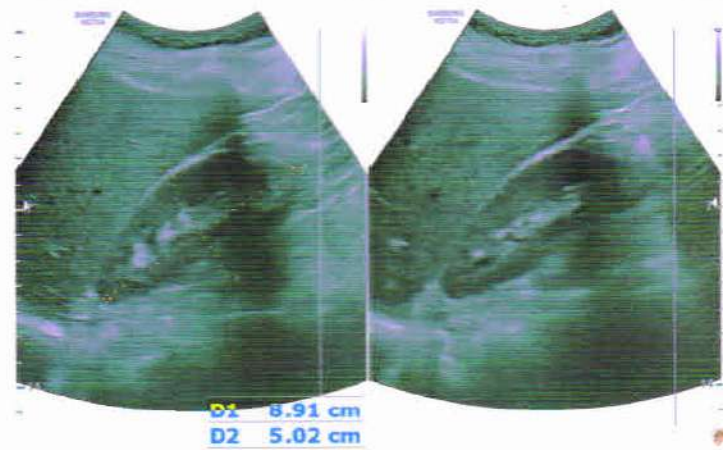
(This report is not valid for any Medico-legal purpose)

ENCL: - PCPNDT Registration Certificate is printed on the back side of this report.

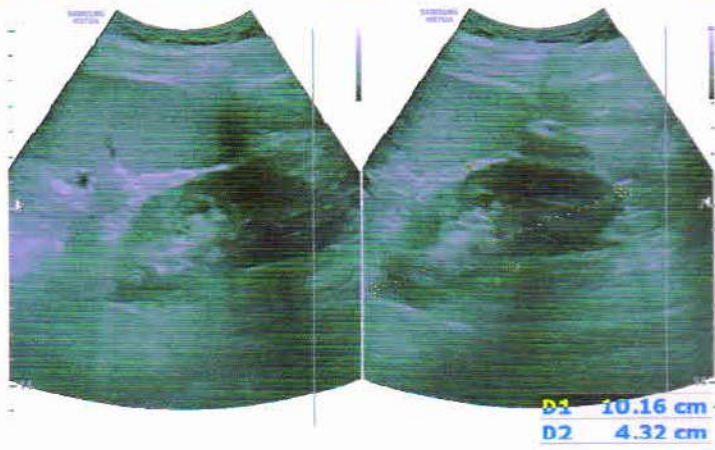
HS70A 27-08-2022-0022 KSHIPRA LABS UDAIPUR MI 1.4 27-08-2022
CA1-7A / Abdomen/ABD / FR 27Hz TIs 0.1 01:02:44 PM
G50 DR125 FA7 P95 Frq Gen: 15.0cm



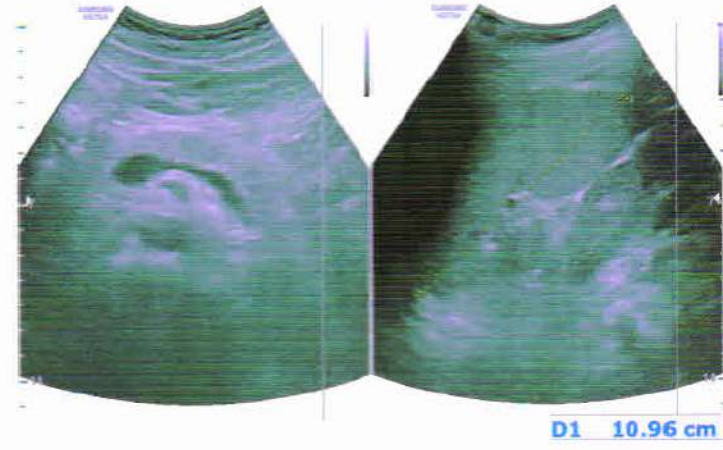
HS70A 27-08-2022-0022 KSHIPRA LABS UDAIPUR MI 1.4 27-08-2022
CA1-7A / Abdomen/ABD / FR 27Hz TIs 0.1 01:02:59 PM
G50 DR125 FA7 P95 Frq Gen: 15.0cm



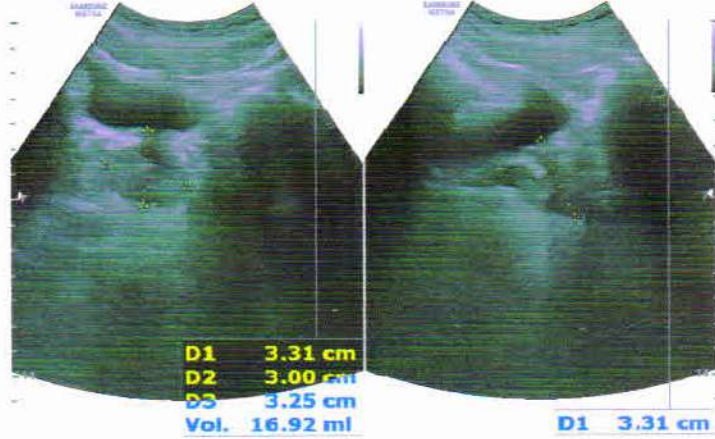HS70A 27-08-2022-0022 KSHIPRA LABS UDAIPUR MI 1.4 27-08-2022
CA1-7A / Abdomen/ABD / FR 27Hz TIs 0.1 01:03:29 PM
G50 DR125 FA7 P95 Frq Gen: 15.0cm



HS70A 27-08-2022-0022 KSHIPRA LABS UDAIPUR MI 1.4 27-08-2022
CA1-7A / Abdomen/ABD / FR 27Hz TIs 0.1 01:03:51 PM
G50 DR125 FA7 P95 Frq Gen: 15.0cm



HS70A 27-08-2022-0022 KSHIPRA LABS UDAIPUR MI 1.4 27-08-2022
CA1-7A / Abdomen/ABD / FR 27Hz TIs 0.1 01:04:15 PM
G50 DR125 FA7 P95 Frq Gen: 15.0cm



Name	:	Bhupesh mali	Age	:	32 Yrs. / M
Thanks To	:	Mediwheel wellness	Date	:	27-08-2022

X-RAY CHEST (PA VIEW)

Both lung fields appear normal.
No e/o Koch's lesion or consolidation seen.
Both CP angles appear clear.
Both domes of diaphragm appear normal.
Heart size and aorta are within normal limits.
Bony thorax under vision appears normal.
Both hila appear normal.



Consultant Radiologist

(This report is not valid for any Medico-legal purpose)



JAI
DRISHTI
Eye Hospital

www.drishtihospital.com
Call : 9982996666

Dr. Sharva Pandya

MBBS, M.S., (Ophthalmology)

RMC Reg. No. : 021537

डॉ. शर्वा पण्ड्या

करिष्ठ नेत्र रोग विशेषज्ञ सर्जन

MR. Bhupesh Mali

32/M

27/08/22

clo For Eye check up.

DVA < 6/6
6/6

NVA < N/6
N/6

coloue vision. (N)

Sharva.

Dr. SHARVA PANDYA
M.B.B.S. M.S. (Ophth.)
Jai Drishti Eye Hospital
Udaipur (Raj.)

Cosmetology Partner :

Drishti Eye Hospital, 23A, Residency Road, Near PC Jewellers, Sardarpura, Udaipur

जय दृष्टि आई हॉस्पिटल, 23-ए, रेजीडेंसी रोड, पी.सी. ज्वेलर्स के पास, सरदारपुरा, उदयपुर



www.vibraclinic.com
9166048591



12 Lead + Median

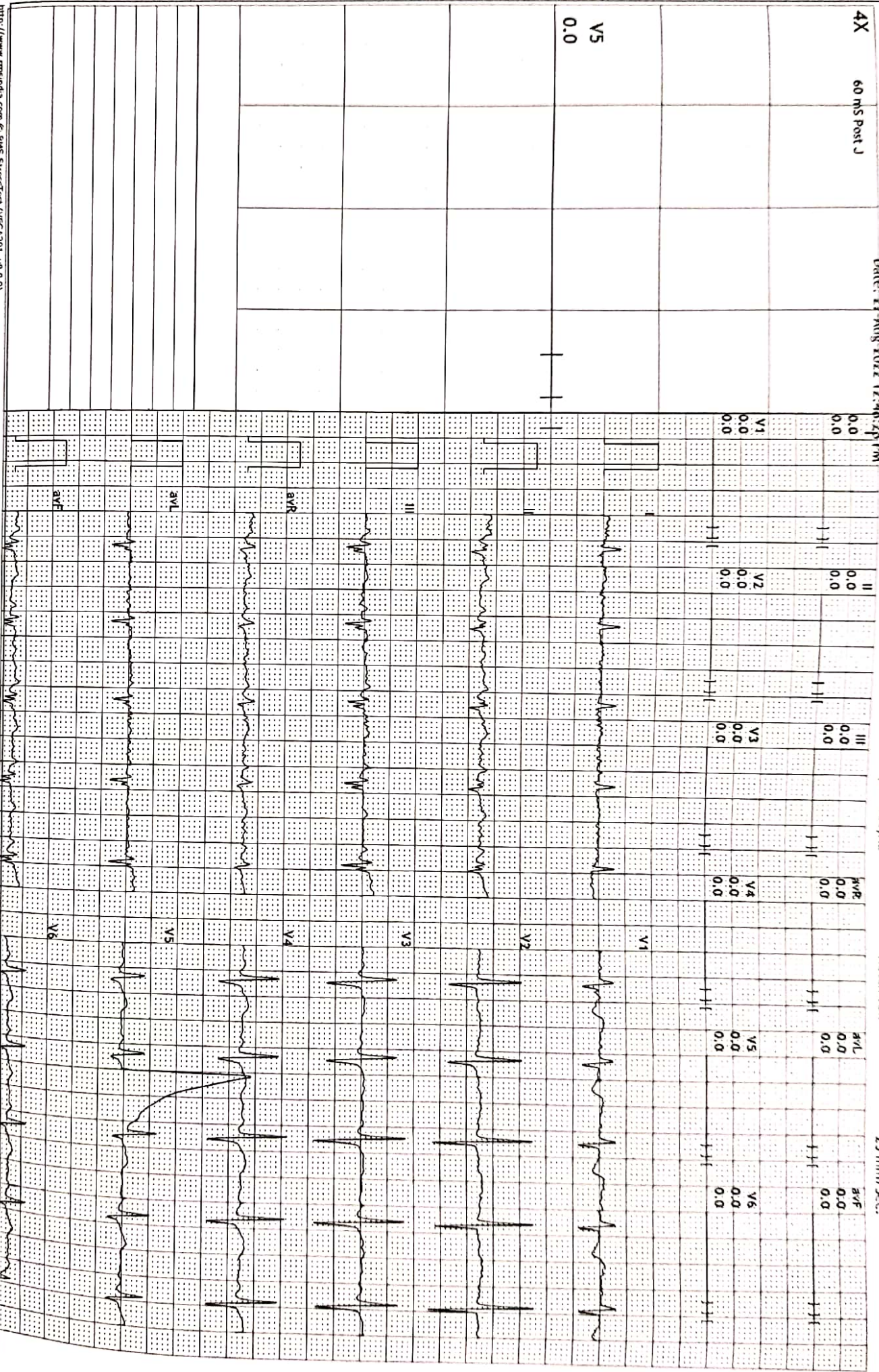
2208102558/MR RHUPESHWARA bpm
31 Yrs/Male
0 Kg/0 Cms
Date: 27-Aug-2022 12:48:28 PM
METS: 1.0
BP: 120/80

MPHR: 45% of 189
Speed: 0.0 mph
Grade: 0.0%

KSHIPRA SCANS & LABS 2B COURT CHOURAHA UDAPUR

Raw ECG
BRUCE
(1.0-100)Hz
Ex Time 01:28
BLC : On
Hatch : On

Supine
10.0 mm/mV
25 mm/Sec.





12 Lead + Median

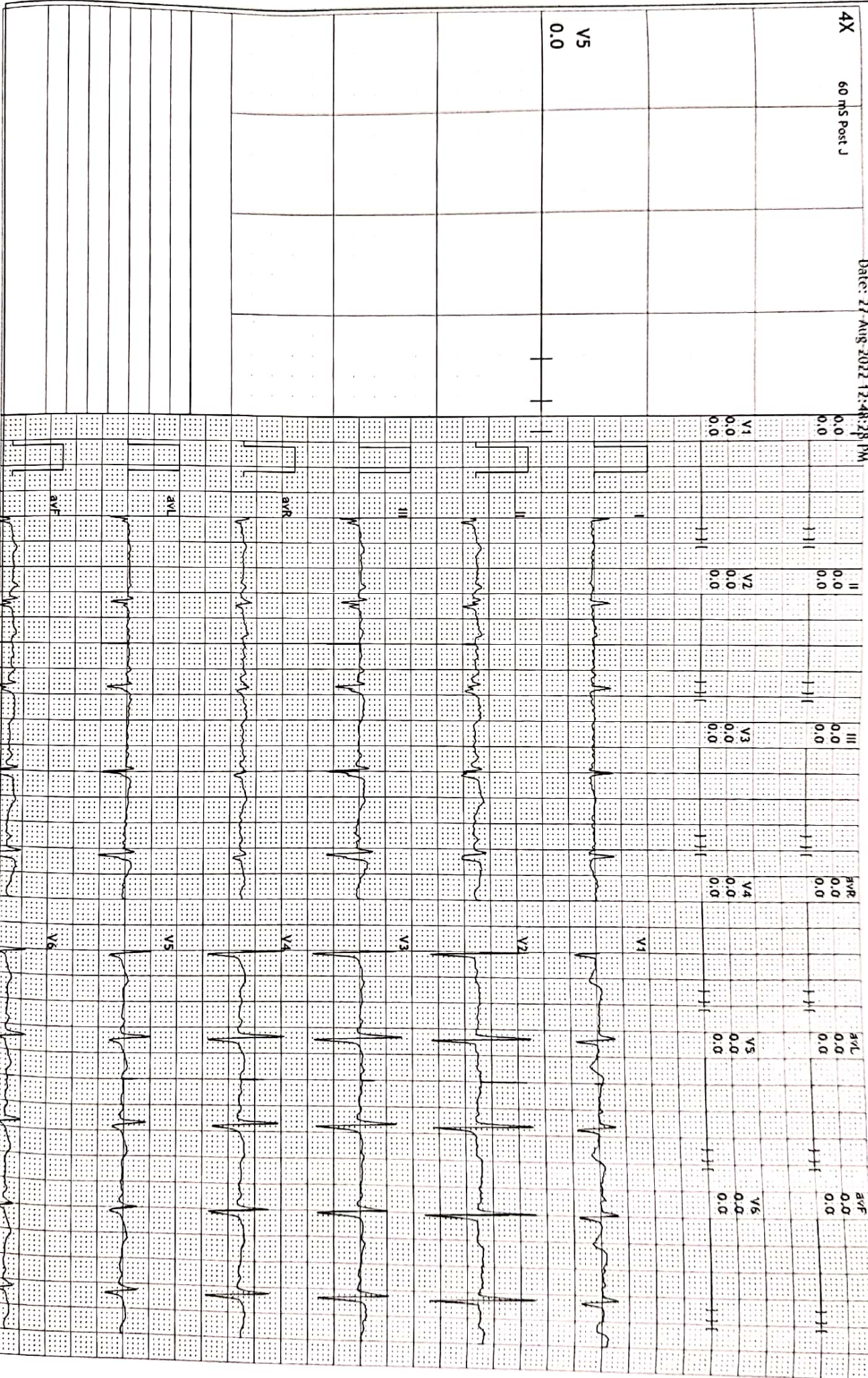
2208102558/MR BHUPESHRAO bhm
31 Yrs/Male
0 Kg/0 Cms
Date: 27-Aug-2022 12:48:28 PM

MPHR: 47% of 189
Speed: 0.0 mph
Grade: 0.0%

KSHIPRA SCANS & LABS
2B COURT CHOURAHA UDAIPUR

Raw ECG
BRUCE
(1.0-100)Hz
Ex Time 01:36
BLC : On
Hatch : On

Standing
10.0 mm/mV
25 mm/Sec.





12 Lead + Median

2208102558/HR RHUPESH/M/44 bpm
31 Yrs/Male
0 kg/0 cms
Date: 27-Aug-2022 12:48:29 PM

MPHR: 76% of 189
Speed: 1.7 mph
Grade: 10.0%

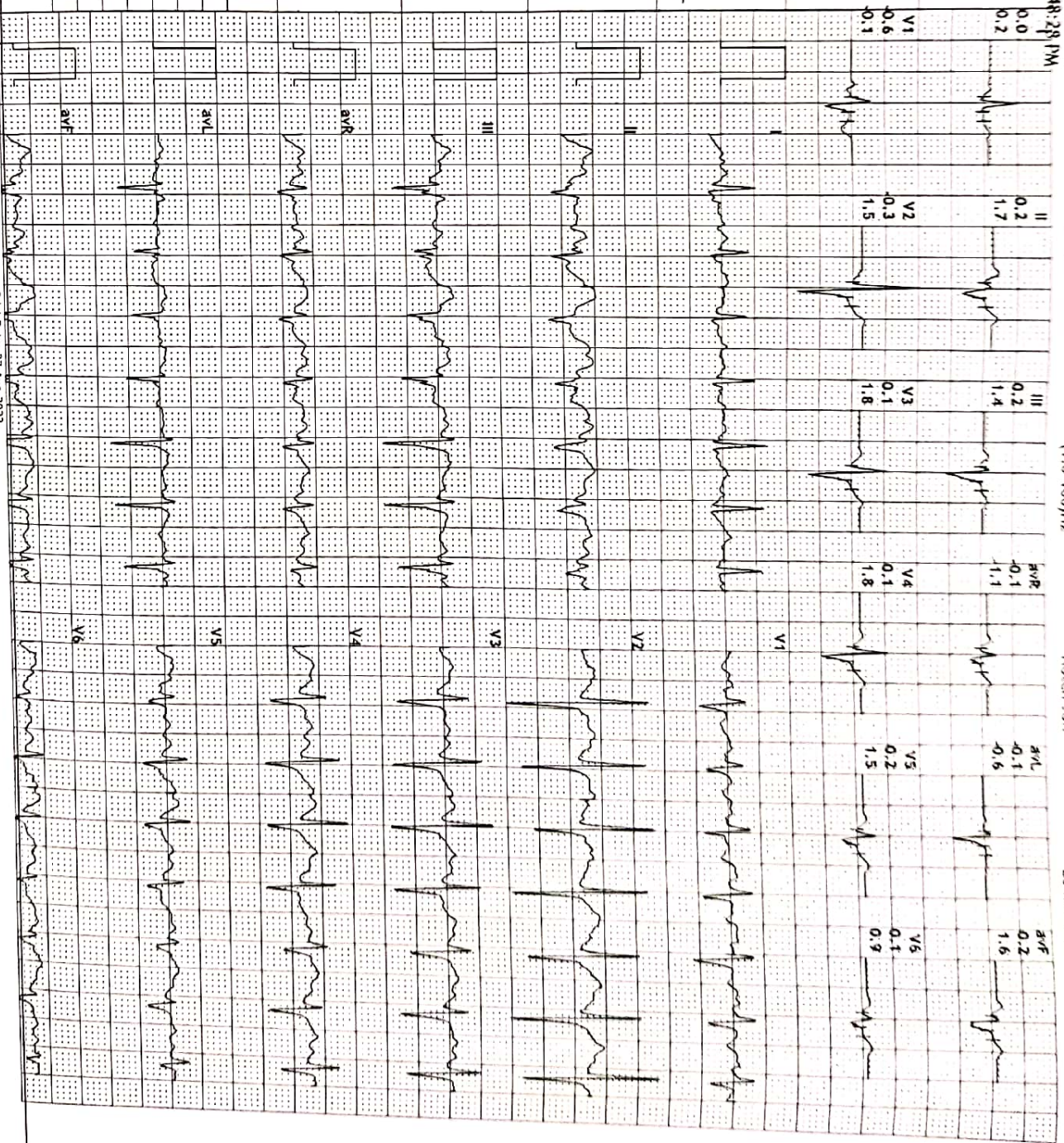
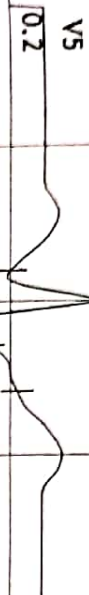KSHIPRA SCANS & LABS

2D COURT CHOURAHA UDAPUR

Raw ECG
BRUCE
(1.0-100)Hz
Ex Time 03:00
BLC :On
Hatch :On

BRUCE: Stage 1 (3:00)
10.0 mm/mV
25 mm/Sec.

4X 60 ms Post J





12 Lead + Median

2208102558/MR BHUPESHRAJ044 bpm
31 Yrs/Male
0 Kg/0 Cms
Date: 27-Aug-2022 12:48:29 PM

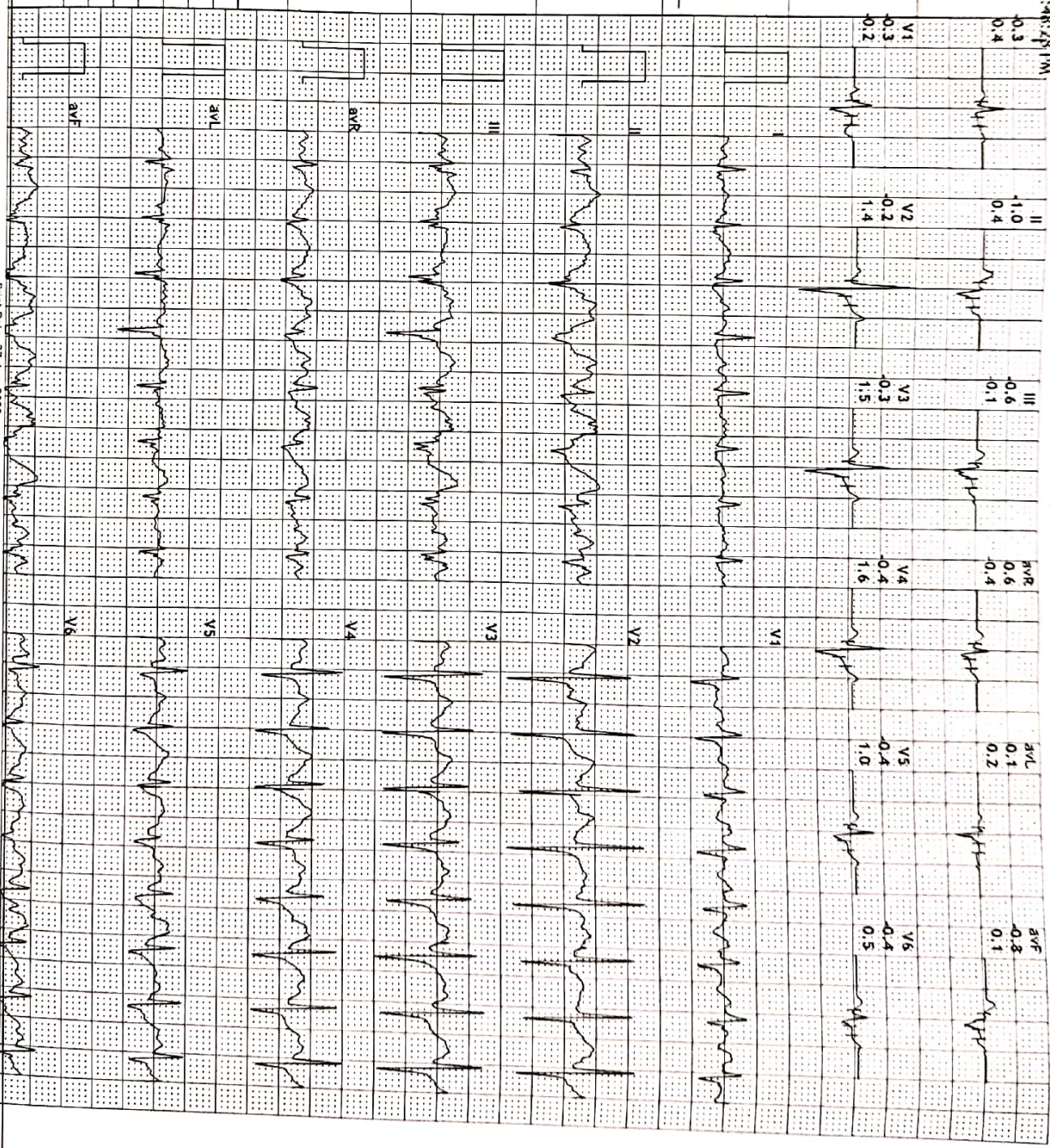

MPHR: 86% of 189
Speed: 2.5 mph
Grade: 12.0%

KSHIPRA SCANS & LABS
2B COURT CHOORAHIA UDAIPUR

Raw ECG
BRUCE
(1.0-100)Hz
Ex Time 04:12
BLC : On
Notch : On

BRUCE: Peakx(1:12)
10.0 mm/mV
25 mm/Sec.

4X 60 ms Post J





12 Lead + Median

2208102558/MR BHUPESHRAJ M01 bpm
31 Yrs/Male
0 Kg/0 Cms
Date: 27-Aug-2022 12:48:28 PM

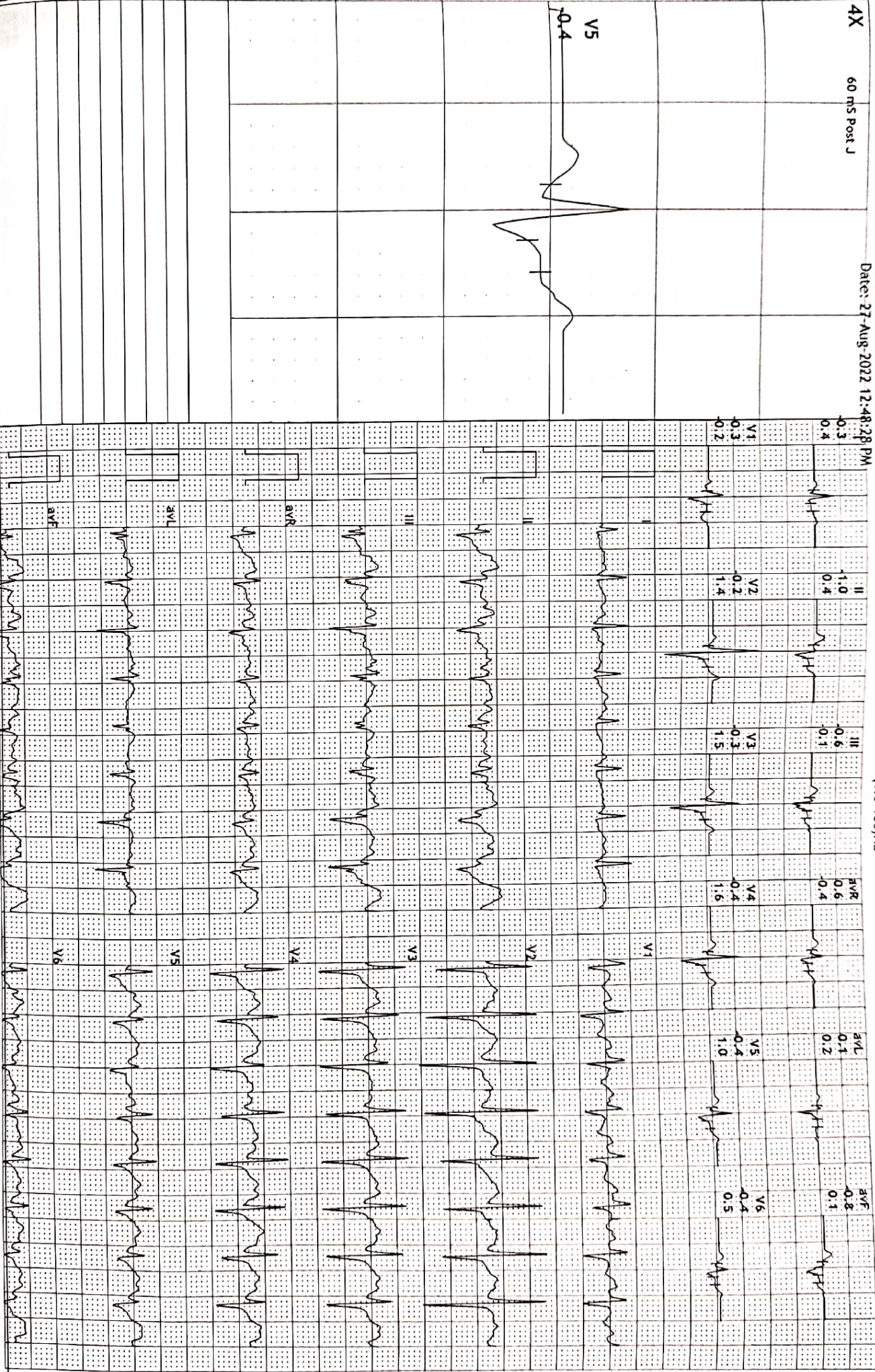
MPHR: 85% of 189
Speed: 1.1 mph
Grade: 0.0%

Raw ECG
BRUCE
(1.0-100)Hz
Ex Time 04:13
BLC : On
Notch : On

LegPain
10.0 mm/mv
25 mm/Sec.

KSHIPRA SCANS & LABS
2B COURT CHOURAHA UDAIPUR

4X 60 ms Post J





12 Lead + Median

KSHIPRA SCANS & LABS
2B COURT CHOURAHIA UDAIPUR

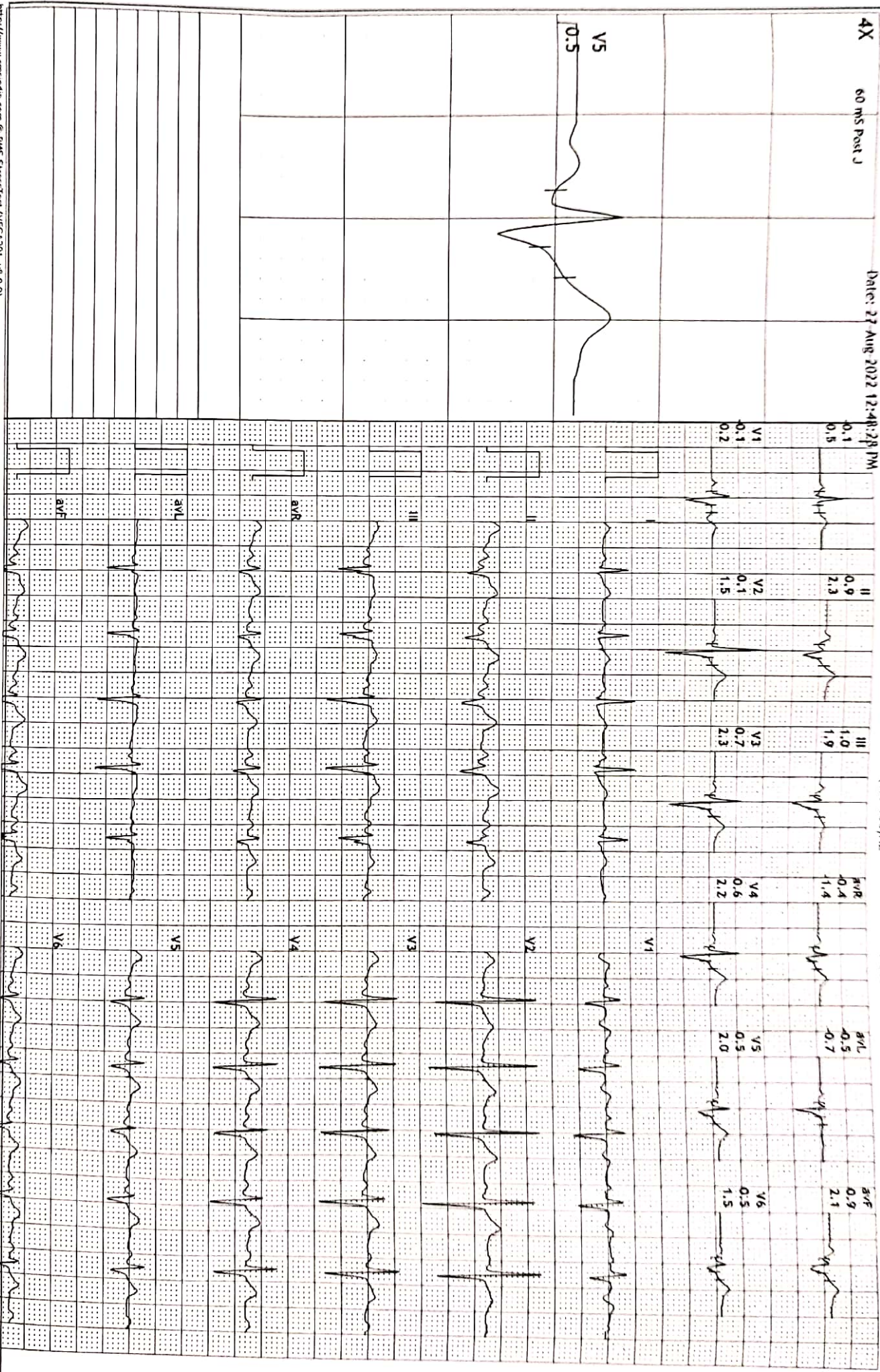2208102558/ANR BHUPESHRAJ18 bpm
31 Yrs/Male
0 Kg/0 Cms
Date: 27-Aug-2022 12:48:28 PM
METs: 1.0
DP: 130/90

MPIR: 62% of 189
Speed: 0.0 mph
Grade: 0.0%

Raw ECG
BRUCE
(1.0-100)Hz
Ez Time 04:13
BLC: On
Hatch: On

Recovery(1:00)
10.0 mm/mV
25 mm/Sec.

4X 60 ms Post J





12 Lead + Median

KSHIPRA SCANS & LABS

2B COURT CHOURAHA UDAPUR

2208102558/ANR BHUPESHRAJ01 bpm
31 Yrs/Male
0 kg/0 cms
Date: 27-Aug-2022 12:48:28 PM

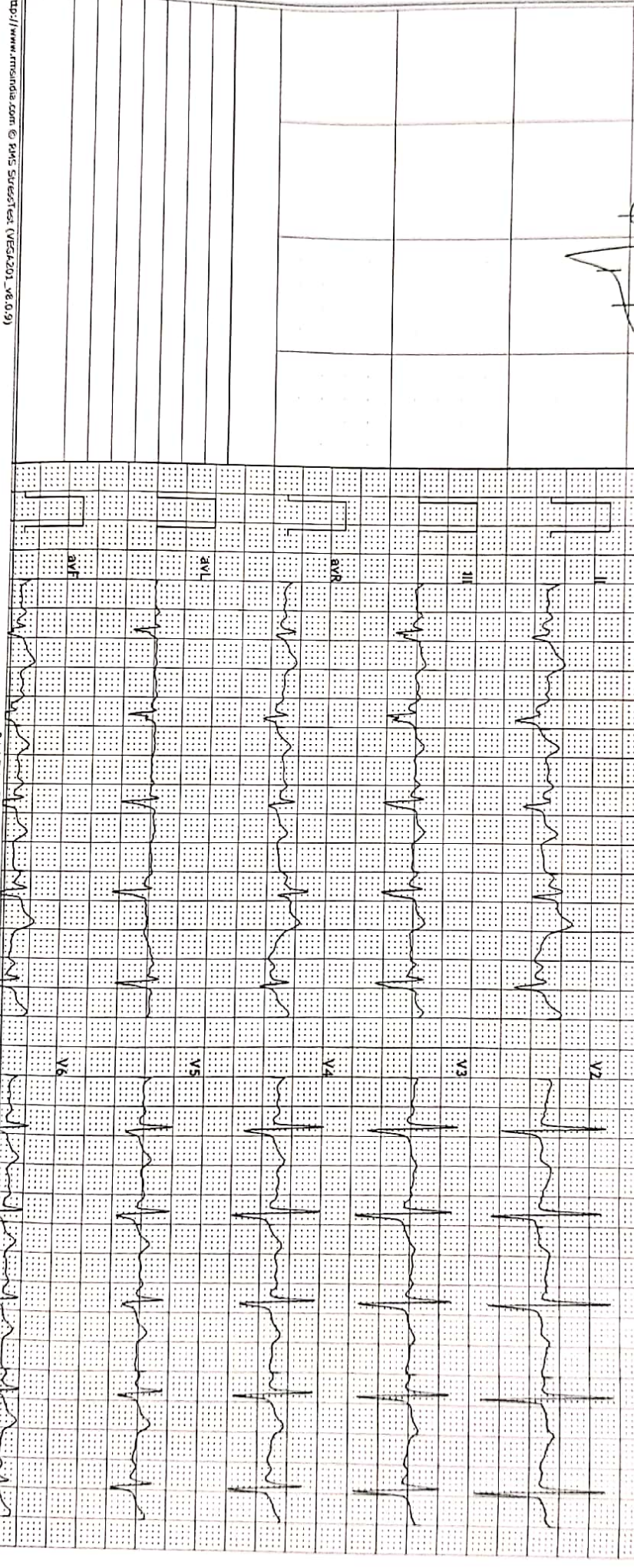
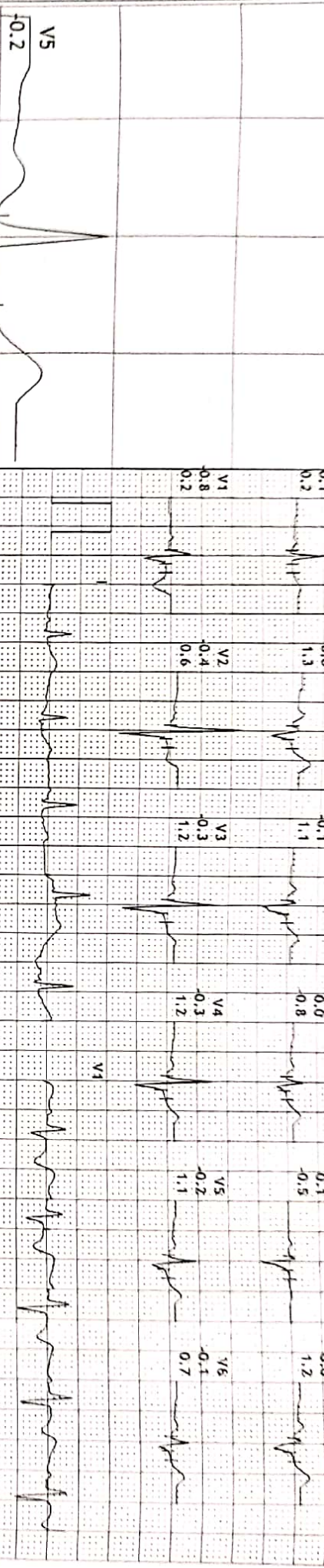
MPHR: 53% of 189
Speed: 0.0 mph
Grade: 0.0%

Raw ECG
BRUCE
(1.0-100)Hz

Ex Time 04:13
BLC : On
Hatch : On

Recovery(3:00)
10.0 mm/mV
25 mm/Sec.

4X 60 ms Post J





Summary

Ref. By :
Medication :
Objective :

Protocol : BRUCE
History :

KSHIPRA SCANS & LABS
2B COURT CHOURAHA UDAIPUR
2208102558/MR BHUPESH MALLI 31 Yrs/Male
Date: 27-Aug-2022 12:48:28 PM

0 Kg/0 Cms

Stage	StageTime (Min:Sec)	PhaseTime (Min:Sec)	Speed (mph)	Grade (%)	METS	H.R. (bpm)	B.P. (mmHg)	R.P.P. x100	PVC	Comments
Supine					1.0	86	120/80	103	-	
Standing					1.0	90	120/80	108	-	
ExStart					1.0	92	120/80	110	-	
Stage 1	3:00	3:01	1.7	10.0	4.7	144	120/80	172	-	
PeakEx	1:12	4:13	2.5	12.0	5.7	164	130/90	213	-	
LegPain	0:05	4:14	1.1	0.0	4.2	161	130/90	209	-	
Recovery	1:00		0.0	0.0	1.0	118	130/90	153	-	
Recovery	3:00		0.0	0.0	1.0	101	120/80	121	-	

Findings :

Exercise Time : 4:13 minutes
 Max HR attained : 164 bpm 87% of Max Predictable HR 189
 Max BP : 130/90(mmHg)
 Workload attained : 5.7 (Fair Effort Tolerance)
 No significant ST segment changes noted during exercise or recovery.
 No Angina/Arrhythmia/S3/murmur
 Final Impression : Test is negative for inducible ischaemia.
 Maximum Depression: 0:51

Advice/Comments:

