

Summary

KSHIPRA SCANS & LABS
 2-B, Hazareshwar Colony, Court Chouraha, Udaipur.
 774/MRS SHAKUNTALA BHOI 41 Yrs/Female 0 Kg/0 Cms
 Date: 03-Jul-2021 02:11:37 PM

Protocol : BRUCE
 History :


Ref. By :
 Medication :
 Objective :

Stage	Time (Min:Sec)	Phase	Time (Min:Sec)	Speed (mph)	Grade (%)	METS	H.R. (bpm)	B.P. (mmHg)	R.P.P. x100	PVC	Comments
Rest											
Start	3:00		3:01	1.7	10.0	4.7	115	130/80	149	-	
Stage 1	3:00		6:01	2.8	12.0	7.8	141	130/90	183	-	
Stage 2	0:36		6:37	3.4	14.0	8.3	165	130/90	214	-	
PeakEx	1:00			0.0	0.0	1.9	95	130/90	123	-	
Recovery	3:13			0.0	0.0	1.0	69	120/80	82	-	

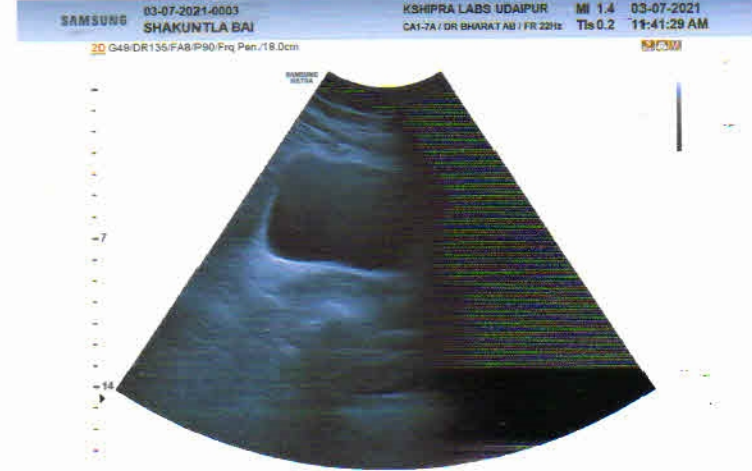
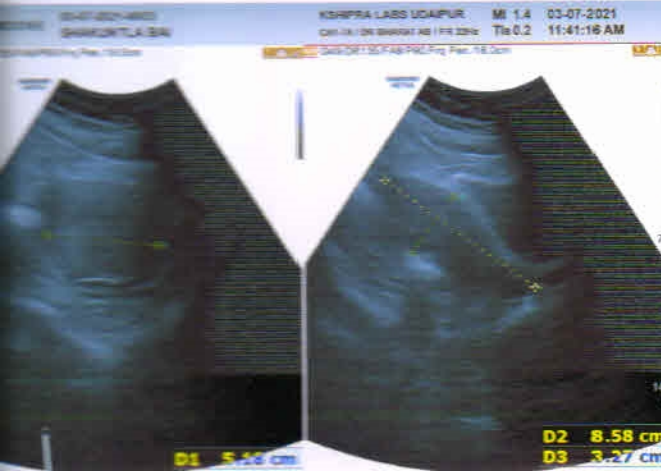
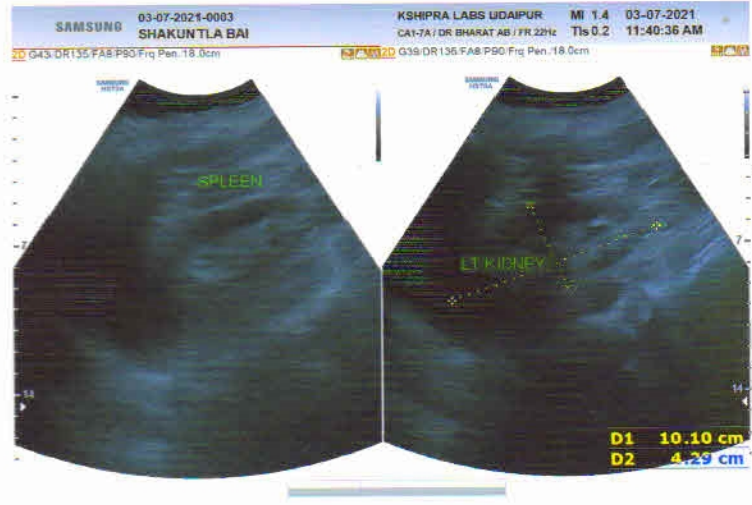
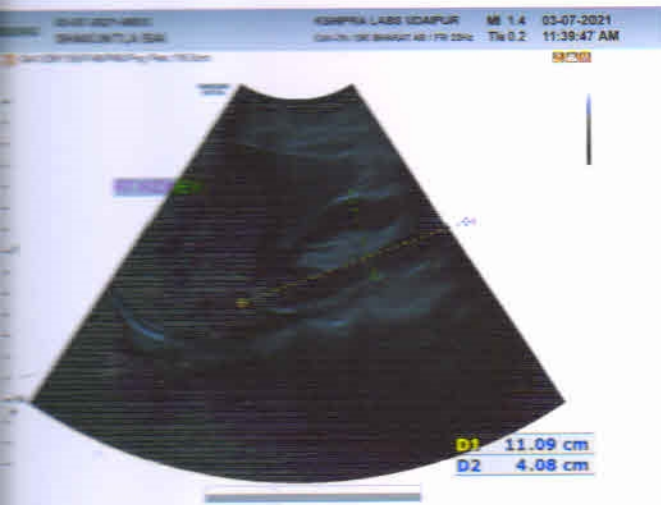
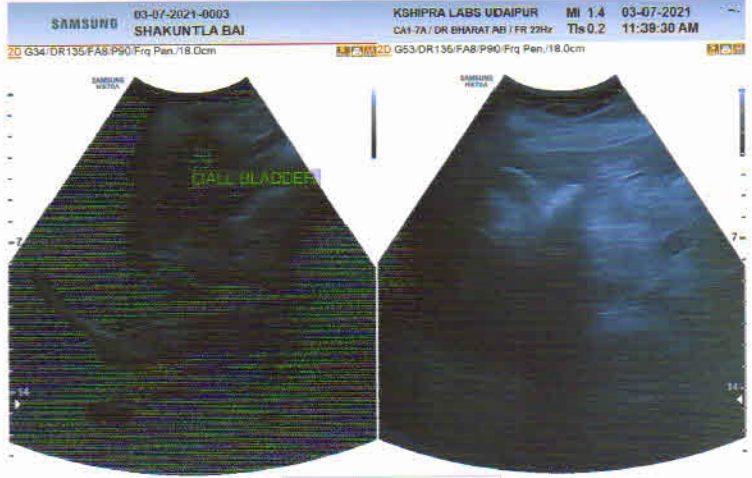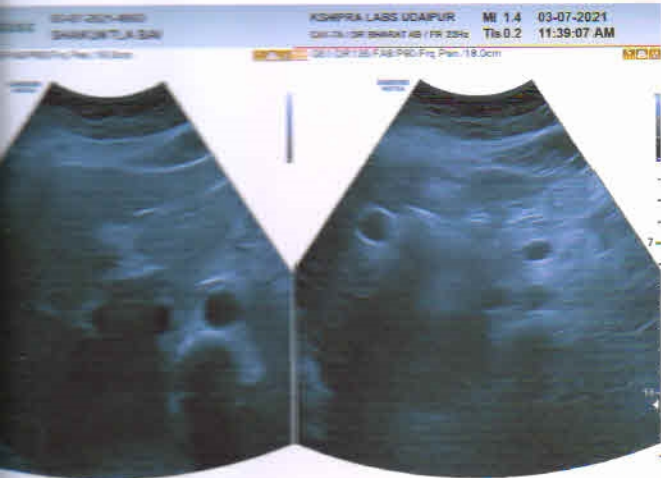
Findings :
 Exercise Time : 6:37 minutes
 Max HR attained : 165 bpm
 Max BP : 130/90(mmHg)
 Workload attained : 8.3 (Fair Effort Tolerance)
 Occasional VPCs seen.

Final Impression : Test is negative for inducible ischaemia.
 Maximum Depression: 6:37

Advice/Comments:



Print Date: 03-Jul-2021



Name	:	Shakuntala Bhoi	Age	:	41 Yrs. / F
Thanks To	:	Self	Date	:	03.07.2021

ULTRASOUND STUDY OF WHOLE ABDOMEN

LIVER:

Liver is normal in size, shape & bright echotexture. No focal mass lesion is seen. Intra hepatic biliary radicles are normal. Portal vein is normal in caliber.

GALL BLADDER :

Gall bladder is well distended. The wall thickness appears normal. No evidence of calculus or mass lesion is seen. C.B.D. appears normal.

PANCREAS :

Pancreas is normal in size, shape & echotexture. No focal mass lesion is seen.

SPLEEN :

Spleen is normal in size, shape & echotexture. No focal mass lesion is seen.

BOTH KIDNEYS :

Both kidneys are normal in size, shape & echotexture. Renal parenchyma appears normal. No evidence of hydronephrosis, calculus or cortical scarring is seen in either kidney.

Right kidney measures : 11.0 x 4.0 cms.

Left kidney measures : 10.1 x 4.2 cms.

URINARY BLADDER :

Urinary bladder is partially distended.

UTERUS :

Uterus is anteverted, normal in size, shape and echotexture. It measures 8.5 x 5.1 x 3.2 cms. Endometrial appears normal.

BOTH OVARIES :

Both ovaries are normal in size, shape and echotexture.

No obvious abdominal lymphadenopathy is seen.

No free fluid is seen in peritoneal cavity.

OPINION:

- Grade I fatty changes in liver.

Dr Ravi Soni
MD (Radio-Diagnosis)
Consultant Radiologist

(This report is not valid for any Medico-legal purpose)

ENCL: - PCPNDT Registration Certificate is printed on the back side of this report.

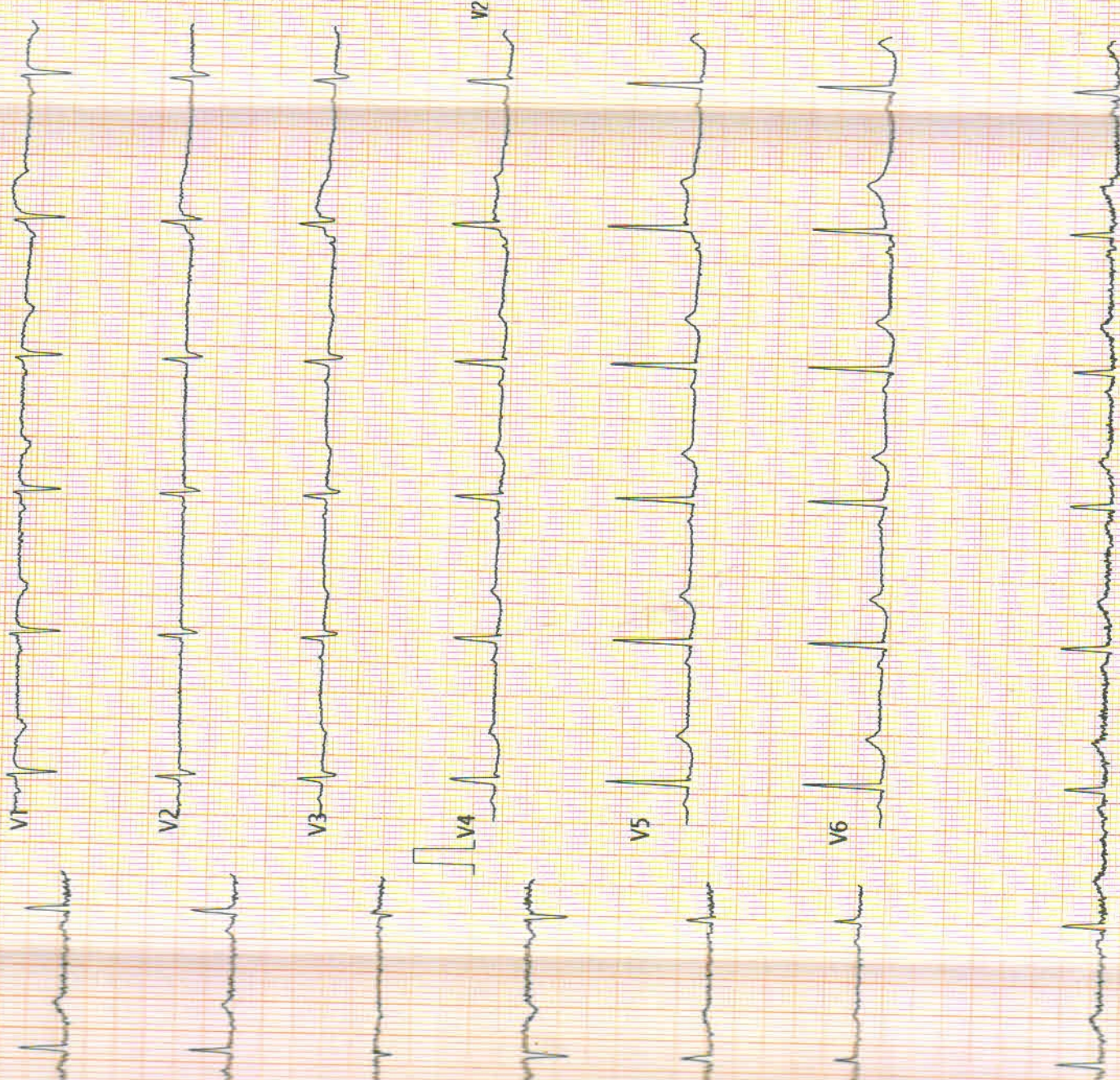
Name	:	Shakuntala Bhoi	Age	:	41 Yrs. / F
Thanks To	:	Self	Date	:	03.07.2021

X-RAY CHEST (PA VIEW)

- **Prominent bronchovascular marking noted in both lower zones.**
- Rest of the lung fields appears normal.
- Both CP angles appear clear.
- Both domes of diaphragm appear normal.
- Heart size and aorta are within normal limits.
- Bony thorax under vision appears normal.
- Both hila appear normal.

Consultant Radiologist

(This report is not valid for any Medico-legal purpose)



Vent. Rate(BPM) : 65
 PR Int. (ms) : 122
 P/QRS/T Int. (ms) : 74 98 158
 QT/QTc Int. (ms) : 417 434
 P/QRS/T Axis(Deg.) : 31 27 34
 RV1/SV5 Amp. (mV) : 0.10 0.00
 RV5/SV1 Amp. (mV) : 1.05 0.48

<ECG Analysis Result>

800 Normal Sinus Rhythm

*** Normal ECG ***

V2.33 Technician :

Note : Unconfirmed Report Need to Review.

ST LEVEL (mV)

I	II	III	aVR	aVL	aVF
-0.01	-0.01	+0.00	+0.01	-0.00	-0.00
V1	V2	V3	V4	V5	V6
+0.02	+0.00	+0.00	-0.02	-0.02	-0.01

<SHAKUNTALA JI > 799900001378 F 35Y

/ cm/Kg

/ mmHg