

Jyoti
31/11

10/12/2022

Ch No. Ocular Complaint

OD VAC 6/6p (U →) 20/20
6/6p (U →)

(A) — Ocular Defect 180° BE
6/6

- A/s. Mild conj congestion
- R/S. OK

6 Dabfit drop
0 0 0 20 days

Dr. Renuka Sharma
DOMS, (Ophthalmology)
Reg No: CGMC-2434/2009
NHMMI Raipur (C.G.)



CONSULTATION SUMMARY

Patient MRN : 17540000317618
Patient Name : Jyoti Shrawan
Gender/Age/Dob : Female , 31 Years , 28/03/91
Patient Phone No : 7974124008
Patient Address : Paikin, Mahasamund,
Chhattisgarh, India, -493558

Consultation Date: 13/12/2022 03:38 PM
Consultant : Dr. Mukesh Kumar Sharma
(GENERAL MEDICINE)
Consultation Type : OP , FOLLOW UP



CHIEF COMPLAINTS & HISTORY OF PRESENT ILLNESS

- CAME FOR HEALTH CHECK UP :
- NO COMPLAIN :
- NO H/O CO-MORBIDITIES :

VITALS

Blood Pressure: 110/70 mmHg Heart Rate: 88 /bpm

MEDICATION ORDER

DRUG NAME	PATIENT INSTRUCTION
1) ROSUVASTATIN+FENOFIBRATE-TABLET-10MG+145MG- <u>RXTOR F</u>	Once Daily (0 - 0 - 0 - 1) Tablet Orally After Food For 30 Days , Qty: 30 , Start Date: Dec 13, 2022 , End Date: Jan 11, 2023
2) BENFOTIAMINE+VIT B6+MECOBALAMIN-CAPSULE-150MG+10MG+1500MCG- <u>IROZORB PLUS</u>	Once Daily (1 - 0 - 0 - 0) Tablet After Food For 30 Days , Qty: 30 , Start Date: Dec 13, 2022 , End Date: Jan 11, 2023
3) ESOMEPRAZOLE+DOMPERIDONE-CAPSULE-40MG+30MG- <u>SOMPRAZ D</u>	Once Daily (1 - 0 - 0 - 0) Empty Stomach For 30 Days , Start Date: Dec 13, 2022 , End Date: Jan 11, 2023

NOTES

- LIFE STYLE MODIFICATIONS AS ADVISED
LOW SALT DIET, AVOID SPICY N JUNK FOODS
REGULAR EXERCISE

CONSULTANT DETAILS



Handwritten signature of Dr. Mukesh Kumar Sharma

NH MMI Narayana Superspeciality Hospital

(A Unit of Narayana Hrudayalaya Limited) CIN: L85110KA2000PLC027497

Registered Office: 258/A, Bommasandra Industrial Area, Anekal Taluk, Bangalore 560099

Hospital Address: New Dhamtari Road, Lalpur, Raipur 492001

Tel +91 771 4210901 / 902 | Fax +91 771 408 1106 | Email: info.rpr@narayanahealth.org | www.narayanahealth.org



Appointments

1800-309-0309

Emergencies

8821-818181

CONSULTANT DETAILS

Dr. Mukesh Kumar Sharma , CONSULTANT , GENERAL MEDICINE
Registration No : 5549/2014

Printed By: Dr. Mukesh Kumar Sharma | Printed On: 13.12.2022 15:41



NH MMI Narayana Superspecialty Hospital

(A unit of Narayana Hrudayalaya Limited) CIN: L86110KA2000FLC027497

Registered Office: 258/A, Bommasandra Industrial Area, Anekal Taluk, Bangalore 560099

Hospital Address: New Dhamtari Road, Lalpur, Raipur 492001

Tel +91 771 4210901 / 902 | Fax +91 771 408 1106 | Email: info.rpr@narayanahealth.org | www.narayanahealth.org



Appointments

1800-309-0309


Emergencies

8821-818181

CONSULTATION SUMMARY

Patient MRN : 17540000317618
Patient Name : Jyoti Shrawan
Gender/Age/Dob : Female , 31 Years , 28/03/91
Patient Phone No : 7974124008
Patient Address : Paikin, Mahasamund,
Chhattisgarh, India, -493558

Consultation Date: 10/12/2022 10:59 AM
Consultant : Dr. Manisha Sharma
(OBSTETRICS & GYNAECOLOGY)
Consultation Type : OP , NEW VISIT



CHIEF COMPLAINTS & HISTORY OF PRESENT ILLNESS

- Came for health check-up:
- p11 lcb 3 years normal :
delivery Imp 3.12.22

INVESTIGATION ORDER

PAP SMEAR - SMVDNSH

MEDICATION ORDER

- DRUG NAME
- 1) SERTACONAZOLE+BECLOMETASONE-
CREAM-15GM-**ONABET B**
 - 2) CALCIUM CITRATE+MG+ZINC+VIT
D3+MINERALS-TABLET--**SUPRACAL XT PLUS**
 - 3) MULTIVITAMINS+MINERALS-CAPSULE--
ABSOLUT WOMAN
 - 4) CLINDAMYCIN+CLOTRIMAZOLE+TINIDAZOLE-
SUPPOSITORY-100MG+100MG+100MG-
CLINGEN FORTE (8/12 22/2022)
 - 5) THERAPY LIQUID SOAP-SOLUTION-100ML-
INTIWASH

PATIENT INSTRUCTION

Once Daily (0 - 0 - 0 - 1) Vaginal After Food For 20
Days , Qty: 1 , Start Date: Dec 10, 2022 , End Date:
Dec 29, 2022

Once Daily (1 - 0 - 0 - 0) Tablet After Food For 1
Month , Qty: 30 , Start Date: Dec 10, 2022 , End
Date: Jan 09, 2023

Once Daily (1 - 0 - 0 - 0) Capsule Orally After Food
For 1 Month , Qty: 30 , Start Date: Dec 10, 2022 ,
End Date: Jan 08, 2023

Once Daily (0 - 0 - 0 - 1) Vaginal At Bed Time For 7
Days (For vaginal insertion only) Qty: 1 , Start Date:
Dec 10, 2022 , End Date: Dec 16, 2022

Qty: 1 , Start Date: Dec 10, 2022

CONSULTANT DETAILS



Dr. Manisha Sharma , VISITING CONSULTANT , OBSTETRICS & GYNAECOLOGY

MS
Dr. MANISHA SHARMA
D.G.O G.M.B
Reg No- CGMS-017/2010
NH RAIPUR (C.S.)

One free consultation with the same doctor within next 6 days.

DEPARTMENT OF LABORATORY MEDICINE Unit of Narayana Health

MRN	: 17540000317618	Department	: OBSTETRICS & GYNAECOLOGY
Name	: Jyoti Shrawan	Specimen	: WHOLE BLOOD
Age / Sex	: 31 Year(s) / Female	Visit Type	: OP
Sample No	: 22212100143	Collected On	: 10/12/2022 10:58 AM
Consulting DR	: Dr. Manisha Sharma	Referred DR	: Dr. Manisha Sharma
Patient Address	: Paikin Chhattisgarh,India	Received On	: 10/12/2022 11:49 AM
		Reported On	: 10/12/2022 12:51 PM
		Report Type	: Final

HAEMATOLOGY LAB

Test	Result	Unit	Biological Reference Interval
EHP MEDIWHEEL FULL BODY HEALTH CHECK PACKAGE FEMALE BELOW 40 YRS			
ERYTHROCYTE SEDIMENTATION RATE (ESR)	15.00	mm/hr	0-19

(Signature)

Dr. SMRITI RATHOREMBBS MD
PATHOLOGY



DEPARTMENT OF LABORATORY MEDICINE Narayana Health

MRN : 17540000317618 Name : Jyoti Shrawan Age / Sex : 31 Year(s) / Female Sample No : 1R2212100269 Consulting DR : Dr. Manisha Sharma Patient Address : Paikin Chhattisgarh, India	Department : OBSTETRICS & GYNAECOLOGY Specimen : SERUM Visit Type : OP Collected On : 10/12/2022 10:58 AM Referred DR : Dr. Manisha Sharma Received On : 10/12/2022 11:49 AM Reported On : 10/12/2022 01:06 PM Report Type : Final
---	---

BIOCHEMISTRY

Test	Result	Unit	Biological Reference Interval
FASTING BLOOD SUGAR (FBS)	81.00	mg/dl	70-99
LIPID PROFILE (CHOL, TRIG, HDL, LDL, VLDL)			
CHOLESTEROL TOTAL	<u>237.00 H</u>		50-200
TRIGLYCERIDES	<u>242.00 H</u>	mg/dl	0-150
RENAL PACKAGE - 2 (RFT FASTING)			
SERUM CREATININE			
SERUM CREATININE	0.6	mg/dl	0.6-1.2
eGFR	113.68	mL/min/1.73m2	
BLOOD UREA NITROGEN (BUN)	10.00	mg/dl	7-20
HDL CHOLESTROL (HDLC)	36.00	mg/dl	35-70
LDL CHOLESTEROL	<u>153.00 H</u>	mg/dl	0-100
SODIUM, SERUM	144.00	mmol/L	135-150
POTASSIUM, SERUM	4.90	mmol/L	3.5-5
VLDL CHOLESTEROL	<u>48.40 H</u>	mg/dl	0-40
CHOLESTEROL /HDL RATIO	<u>6.58 H</u>		0-5
CHLORIDE	102.00	mmol/L	95-106
CALCIUM	9.60	mg/dl	8.5-10.1
MAGNESIUM	2.10	mg/dL	1.8-2.4



Dr. SMRITI RATHORE MBBS MD
PATHOLOGY



NH MMI Narayana Superspeciality Hospital

(A Unit of Narayana Hrudayalaya Limited) CIN: L85110KA2000PLC027497

Registered Office: 258/A, Bommasandra Industrial Area, Anekal Taluk, Bangalore 560099

Hospital Address: New Dhamtari Road, Lalpur, Raipur 492001

Tel +91 771 4210901 / 902 | Fax +91 771 408 1106 | Email: info.rpr@narayanahealth.org | www.narayanahealth.org

Page 2 of 11

Appointments

1800-309-0309

Emergencies

8821-818181

DEPARTMENT OF LABORATORY MEDICINE

MRN : 17540000317618	Department : OBSTETRICS & GYNAECOLOGY
Name : Jyoti Shrawan	Specimen : SERUM
Age / Sex : 31 Year(s) / Female	Visit Type : OP
Sample No : IR2212100269	Collected On : 10/12/2022 10:58 AM
Consulting DR : Dr. Manisha Sharma	Referred DR : Dr. Manisha Sharma
Patient Address : Paikin Chhattisgarh,India	Received On : 10/12/2022 11:49 AM
	Reported On : 10/12/2022 01:06 PM
	Report Type : Final

BIOCHEMISTRY

Test	Result	Unit	Biological Reference Interval
URIC ACID	4.30	mg/dl	2.6-6
PHOSPHORUS	3.80	mg/dl	2.6-4.7



Dr. SMRITI RATHORE MBBS MD
PATHOLOGY



DEPARTMENT OF LABORATORY MEDICINE

MRN : 17540000317618	Department : OBSTETRICS & GYNAECOLOGY
Name : Jyoti Shrawan	Specimen : PLASMA
Age / Sex : 31 Year(s) / Female	Visit Type : OP
Sample No : 1R2212100268	Collected On : 10/12/2022 10:58 AM
Consulting DR : Dr. Manisha Sharma	Referred DR : Dr. Manisha Sharma
Patient Address : Paikin Chhattisgarh,India	Received On : 10/12/2022 11:49 AM
	Reported On : 10/12/2022 03:05 PM
	Report Type : Final

Test	Result	Unit	Biological Reference Interval
POST PRANDIAL BLOOD SUGAR (PPBS)	106.00		



Dr. SMRITI RATHORE MBBS MD
PATHOLOGY

DEPARTMENT OF LABORATORY MEDICINE Narayana Health

MRN : 17540000317618	Department : OBSTETRICS & GYNAECOLOGY
Name : Jyoti Shrawan	Specimen : WHOLE BLOOD
Age / Sex : 31 Year(s) / Female	Visit Type : OP
Sample No : 22212100144	Collected On : 10/12/2022 10:58 AM
Consulting DR : Dr. Manisha Sharma	Referred DR : Dr. Manisha Sharma
Patient Address : Paikin Chhattisgarh, India	Received On : 10/12/2022 11:49 AM
	Reported On : 10/12/2022 12:53 PM
	Report Type : Final

Test	Result	Unit	Biological Reference Interval
COMPLETE BLOOD COUNT (CBC)			
HAEMOGLOBIN (HB%)	12.40 L	g/dl	13-18
RED BLOOD CELL COUNT	4.69	Million/ul	3.8-5.8
PCV (PACKED CELL VOLUME) / HEMATOCRIT	36.6	%	36-46
MCV (MEAN CORPUSCULAR VOLUME)	78.2	fl	76-96
MCH (MEAN CORPUSCULAR HAEMOGLOBIN)	26.50 L	pg	27-32
MCHC (MEAN CORPUSCULAR HAEMOGLOBIN CONCENTRATION)	33.90	%	30-35
RED CELL DISTRIBUTION WIDTH (RDW)	14.70 H	%	11.6-14.0
PLATELET COUNT	200.00	Thous/ μ l	150-400
TOTAL LEUKOCYTE COUNT (TLC)	5.0	Thousand/cu.mm	4.0-10.0
DIFFERENTIAL COUNT (DC)			
Neutrophils	55	%	40-75
Lymphocytes	37	%	20-45
Monocytes	05	%	2-10
Eosinophils	03	%	1-6
Basophils	00	%	0-1
NRBC	0.0		


Dr. SMRITI RATHORE MBBS MD
 PATHOLOGY

NH MMI Narayana Superspeciality Hospital
(A unit of Narayana Hrudayalaya Limited) CIN: LB5110KA2000PLC027497

Registered Office: 258/A, Bommasandra Industrial Area, Anekal Taluk, Bangalore 560099

Hospital Address: New Dhamtari Road, Lalpur, Raipur 492001

Tel +91 771 4210901 / 902 | Fax +91 771 408 1106 | Email: info.rpr@narayanahealth.org | www.narayanahealth.org

Page 5 of 11

 Appointments
1800-309-0309

 Emergencies
8821-818181

DEPARTMENT OF LABORATORY MEDICINE Unit of Narayana Health

MRN : 17540000317618 Name : Jyoti Shrawan Age / Sex : 31 Year(s) / Female Sample No : 1R2212100270 Consulting DR : Dr. Manisha Sharma Patient Address : Paikin Chhattisgarh,India	Department : OBSTETRICS & GYNAECOLOGY Specimen : blood Visit Type : OP Collected On : 10/12/2022 10:58 AM Referred DR : Dr. Manisha Sharma Received On : 10/12/2022 11:49 AM Reported On : 10/12/2022 01:06 PM Report Type : Final
--	---

Test	Result	Unit	Biological Reference Interval
LIVER FUNCTION TEST(LFT)			
BILIRUBIN TOTAL	0.60	mg/dl	0-1.3
BILIRUBIN DIRECT	0.20	mg/dl	0-0.3
TOTAL PROTEIN	7.60	gm/dL	6.4-8.2
BILIRUBIN INDIRECT	0.40		
SERUM ALBUMIN	4.90	gm/dL	3.4-5
SERUM GLOBULIN	2.70		
ALBUMIN TO GLOBULIN (A/G)RATIO	1.81		1-2.1
SGOT (AST)	22.00	IU/L	15-37
SGPT (ALT)	<u>27.00 L</u>	IU/L	30-65
ALKALINE PHOSPHATASE (ALP)	<u>43.00 L</u>	IU/L	50-136
GAMMA GLUTAMYL TRANSFERASE (GGT)	19	U/L	5-85



Dr. SMRITI RATHORE MBBS MD
PATHOLOGY



DEPARTMENT OF LABORATORY MEDICINE Narayana Health

MRN : 17540000317618	Department : OBSTETRICS & GYNAECOLOGY
Name : Jyoti Shrawan	Specimen : SERUM
Age / Sex : 31 Year(s) / Female	Visit Type : OP
Sample No : 1R2212100271	Collected On : 10/12/2022 10:58 AM
Consulting DR : Dr. Manisha Sharma	Referred DR : Dr. Manisha Sharma
Patient Address : Paikin Chhattisgarh,India	Received On : 10/12/2022 11:49 AM
	Reported On : 10/12/2022 05:17 PM
	Report Type : Final

Test	Result	Unit	Biological Reference Interval
THYROID PROFILE (T3, T4, TSH)			
TRI IODO THYRONINE (T3)	1.37	ng/dL	0.6-1.81
THYROXINE (T4)	7.30	ug/dl	3.2-12.6
TSH (THYROID STIMULATING HORMONE)	1.80	mIU/mL	0.35-5.50

Dr. SMRITI RATHORE MBBS MD
PATHOLOGY



DEPARTMENT OF LABORATORY MEDICINE Narayana Health

MRN : 17540000317618	Department : OBSTETRICS & GYNAECOLOGY
Name : Jyoti Shrawan	Specimen : WHOLE BLOOD
Age / Sex : 31 Year(s) / Female	Visit Type : OP
Sample No : 1R2212100272	Collected On : 10/12/2022 10:58 AM
Consulting DR : Dr. Manisha Sharma	Referred DR : Dr. Manisha Sharma
Patient Address : Paikin Chhattisgarh,India	Received On : 10/12/2022 11:49 AM
	Reported On : 10/12/2022 02:38 PM
	Report Type : Final

Test	Result	Unit	Biological Reference Interval
HBA1C			
HBA1C	4.4	%tage	

Reference Group HBA1c in %

Non diabetic Adult (18 years or more) < 5.7

At risk (Prediabetes) 5.7 - 6.4

Diagnosing Diabetes >= 6.5

Estimated Average Glucose	79.58	mg/dL	
---------------------------	-------	-------	--



Dr. SMRITI RATHORE MD
PATHOLOGY



DEPARTMENT OF LABORATORY MEDICINE Narayana Health

MRN : 17540000317618	Department : OBSTETRICS & GYNAECOLOGY
Name : Jyoti Shrawan	Specimen : URINE
Age / Sex : 31 Year(s) / Female	Visit Type : OP
Sample No : 7R2212100066	Collected On : 10/12/2022 10:58 AM
Consulting DR : Dr. Manisha Sharma	Referred DR : Dr. Manisha Sharma
Patient Address : Paikin Chhattisgarh,India	Received On : 10/12/2022 11:49 AM
	Reported On : 10/12/2022 01:43 PM
	Report Type : Final

CLINICAL PATHOLOGY

Test	Result	Unit	Biological Reference Interval
URINE ROUTINE & MICROSCOPY			
PHYSICAL EXAMINATION			
VOLUME	35	ml	
COLOUR	PALE YELLOW		
APPEARANCE	SLIGHTLY TURBID		
SP. GRAVITY	1.005		1.002-1.03
CHEMICAL EXAMINATION			
pH(REACTION)	5.5		4.8-7.5
PROTEIN	Negative		Negative
URINE GLUCOSE	Negative		Negative
KETONE BODIES	Negative		Negative
BILE SALTS	Negative		Negative
BILE PIGMENT (BILIRUBIN)	Negative		Negative
UROBILINOGEN	Negative		
BLOOD URINE	Negative		Negative
URINE LEUCOCYTE ESTERASE	Negative		Negative
MICROSCOPIC EXAMINATION			
NITRITE	Negative		Negative



Dr. SMRITI RATHORE MBBS MD
PATHOLOGY

NH MMI Narayana Superspeciality Hospital

(A unit of Narayana Hrudayalaya Limited) CIN: L85110KA2000PLC027497

Registered Office: 25B/A, Bommasandra Industrial Area, Anekal Taluk, Bangalore 560099

Hospital Address: New Dhamtari Road, Lalpur, Raipur 492001

Tel +91 771 4210901 / 902 | Fax +91 771 408 1106 | Email: info.rpr@narayanahealth.org | www.narayanahealth.org



Appointments

1800-309-0309

Emergencies

8821-818181

DEPARTMENT OF LABORATORY MEDICINE Narayana Health

MRN : 17540000317618	Department : OBSTETRICS & GYNAECOLOGY
Name : Jyoti Shrawan	Specimen : URINE
Age / Sex : 31 Year(s) / Female	Visit Type : OP
Sample No : 7R2212100066	Collected On : 10/12/2022 10:58 AM
Consulting DR : Dr. Manisha Sharma	Referred DR : Dr. Manisha Sharma
Patient Address : Paikin Chhattisgarh,India	Received On : 10/12/2022 11:49 AM
	Reported On : 10/12/2022 01:43 PM
	Report Type : Final

CLINICAL PATHOLOGY

Test	Result	Unit	Biological Reference Interval
PUS CELLS	3-6	hpf	0-2
RBC	NOT SEEN	hpf	0-3
EPITHELIAL CELLS	10-12 H	hpf	2-3
CRYSTALS	NOT SEEN		
CASTS	NOT SEEN		OCC HYALINE CAST / HPF

Note:
Abnormal results are highlighted.
Results relate to the sample only.
Kindly correlate clinically.



Dr. SMRITI RATHORE MBBS MD
PATHOLOGY



DEPARTMENT OF PATHOLOGY LAB

MRN : 17540000317618	Department : Unit of Narayana Health OBSTETRICS & GYNAECOLOGY
Name : Jyoti Shrawan	Specimen : blood, PLASMA, SERUM, Stool, SWA B, URINE, WHOLE BLOOD
Age / Sex : 31 Year(s) / Female	Visit Type : OP
Sample No : 0, 1R2212100268, 1R2212100269, 1R221210 0270, 1R2212100271, 1R2212100272, 22212 100143, 22212100144, 7R2212100066, 92212 100002	Collected On : 10/12/2022 10:58 AM
Consulting DR : Dr. Manisha Sharma	Referred DR : Dr. Manisha Sharma
Patient Address : Paikin Chhattisgarh, India	Received On : 10/12/2022 11:49 AM
	Reported On : 12/12/2022 09:53 AM
	Report Type : Final

HISTOPATHOLOGY

EHP MEDIWHEEL FULL BODY HEALTH CHECK PACKAGE FEMALE BELOW 40 YRS

PAP SMEAR

GENERAL CATEGORIZATION

Smear show superficial and intermediate squamous epithelial cells in background of inflammatory cells and Rbcs.
No malignant cells seen.

MATERIAL RECEIVED

Received one unstained smear.

SPECIMEN TYPE

Pap Smear.

IMPRESSION

Inflammatory Smear
Correlate clinically.

Lab No

2022/C/898

-- End of Report --

Result Entered by



Dr. SMRITI RATHORE MBBS MD
PATHOLOGY

ECHOCARDIOGRAPHY REPORT

Patient ID	: 17540000317618	Report Date	: 10/12/2022
Patient Name:	: Mrs. Jyoti Shrawan		
Age / Gender	: 31Years/ Female		

MEASUREMENT

AO : 28 (20 - 35)mm **LVID(d)** : 47 (36 - 52)mm **IVS**: 09 (06 -11)mm
LA : 31 (19 - 40)mm **LVID s** : 28 (23 - 39)mm **PW**: 09 (06 - 11)mm
EF : 60%

VALVES

Mitral Valve : Normal
Aortic valve : Normal
Tricuspid Valve : Normal
Pulmonary Valve : Normal

CHAMBERS

Left Atrium : Normal
Right Atrium : Normal
Left Ventricle : Normal
Right Ventricle : Normal

SEPTAE

IVS : Intact
IAS : Intact

GREAT ARTERIES

Aorta : Normal
Pulmonary Artery : Normal



Patient ID	: 17540000317618	Report Date	: 10/12/2022
Patient Name	: Mrs. Jyoti Shrawan		
Age / Gender	: 31Years/ Female		

WALL MOTION ABNORMALITIES

No RWMA at rest

FINAL DIAGNOSIS

No RWMA at rest
Normal LV systolic function. LVEF-60%.
Normal cardiac chambers dimension
IVC normal & collapsing >50% with respiratory variation.
No I/C clot, vegetation or pericardial effusion



Dr. S.Gouniyal
MD, DM
Senior interventional Cardiologist

Dr. JINESH JAIN
MD, DM
Consultant, interventional Cardiology



DR. PRASHANT MADHARIA
MD, PGDCC
Consultant Non- Invasive Cardiology

ID: 317618
Name: JYOTI SHRAWAN
Age: 31 Years
Gender: Female

2022-12-10 12:06:35

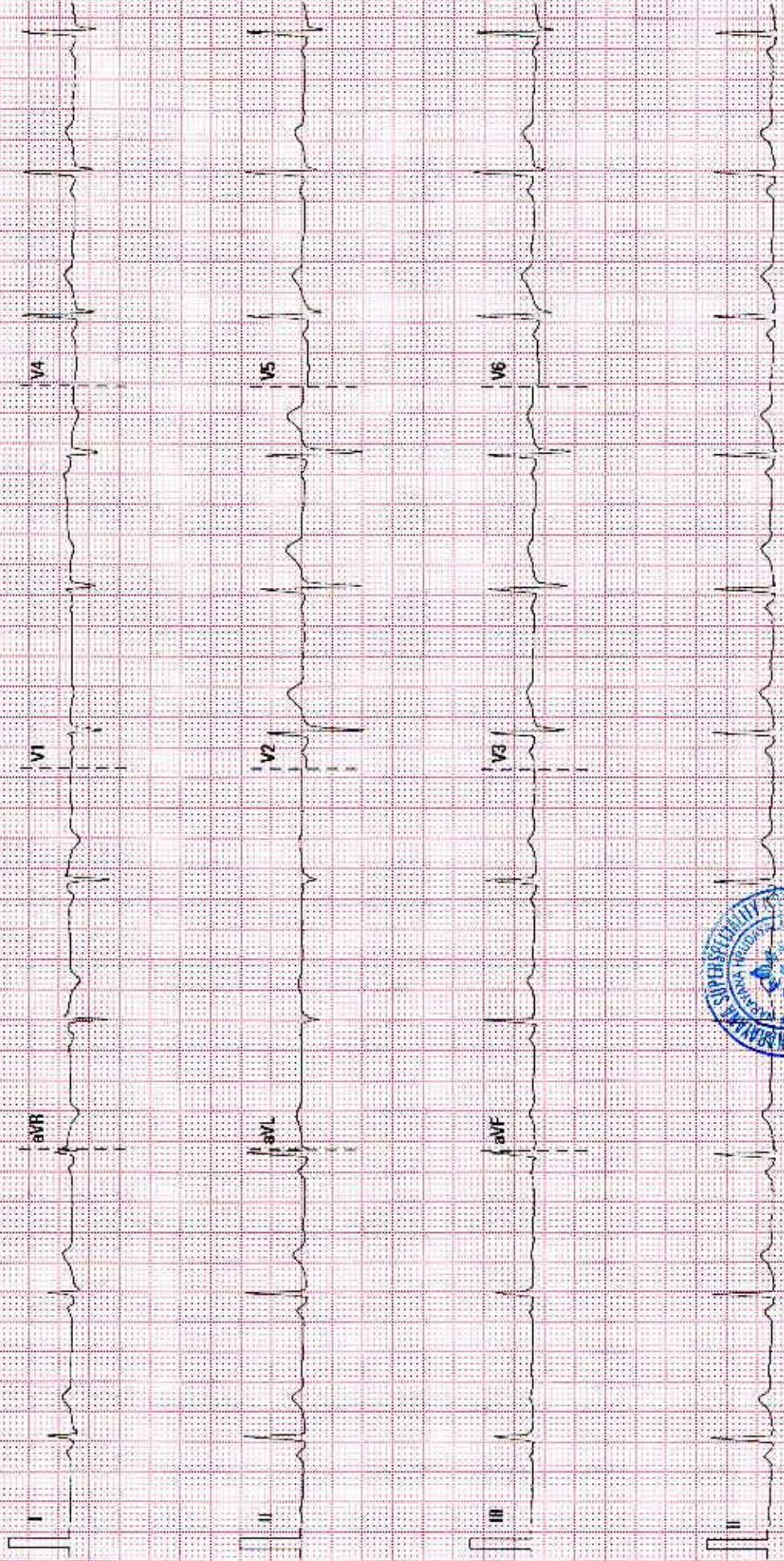
Heart Rate
PR Interval
QRS Duration
QT/QTc Interval
P/QRST Axes
QTc-Hodges

65 bpm
134 ms
82 ms
386/395 ms
51/71/39 deg

Sinus rhythm
Normal ECG

Unconfirmed Diagnosis

“Please Xerox This Copy”



Patient Name	Jyoti Shrawan	Requested By	DR.M.K.SHARMA
MRN	17540000317618	Procedure DateTime	2022-12-10 14:01:21
Age/Sex	31Y 8M / Female	Hospital	NH-RAIPUR

CHEST RADIOGRAPH (PA VIEW)

CLINICAL DETAILS:For health checkup.

FINDINGS:

- The lung fields and bronchovascular markings appear normal.
- The cardiac size is within normal limits.
- Mediastinum and great vessels are within normal limits.
- Trachea is normal and is central. The hilar shadows are unremarkable.
- The costo-phrenic angles are clear. No evidence of pleural effusion or pneumothorax.
- The visualized bones and soft tissue structures appear normal.
- Both the diaphragmatic domes appear normal.

IMPRESSION:

- **Normal chest radiograph.**



DR VIJENDRA RUPRELA
MBBS, DMRD, DNB, MNAMS
CONSULTANT RADIOLOGIST

This is a digitally signed valid document. Reported Date/Time: 2022-12-10 20:32:22

NAME: MS. JYOTI SHRAWAN

REF. BY: DR. MANISHA SHARMA

SONOGRAPHY OF ABDOMEN AND PELVIS

The Real time, B mode, gray scale sonography was performed.

LIVER : The liver is normal in size & reveals normal echotexture with smooth outlines.

PORTAL VEIN : The portal vein is normal in calibre.

GALL BLADDER : The gall bladder is partially distended.

Visualized proximal CBD is normal in calibre.

SPLEEN : The spleen is normal in size . No evidence of focal lesion is noted.

PANCREAS : The visualized pancreas is normal in size, shape, contours and echotexture.

B/L KIDNEYS :

The right kidney measures - 9.6 x 3.2cm and left kidney measures - 10.4 x 3.9cm in size. Both kidneys reveal normal cortical echotexture and have smooth margins. Cortico-medullary differentiation is maintained. No calculus or hydronephrosis is seen.

URINARY BLADDER : The urinary bladder is well distended.

UTERUS: The uterus is anteverted and normal in size 6.5 x 3.7 x 4.7cm. **One iso echoic lesion of size 8 x 8mm with calcification in anterior uterine wall - ? uterine fibroid.** The endometrial thickness is 8mm.

Both ovaries are normal in size and echotexture with few follicles.

Right ovary measures :8cc .Left ovary measures: 7.7cc.

No free fluid is seen in the peritoneal cavity.

Excessive intrabowel gases are noted.

IMPRESSION :

? Uterine fibroid.

ADVISED: Clinical correlation & appropriate further evaluation.



DR. RANJANA KEDIA
MBBS, CBET
CONSULTANT SONOLOGIST

Name.....*Jyoti*.....

Add.....

Age.....*31*..... Sex.....*M*.....

Date.....*10/12/2022*.....

RIGHT

LEFT

	Sph.	Cyl.	Axis	Sph.	Cyl.	Axis
Distance		<i>0.25</i>	<i>180°</i>		<i>0.25</i>	<i>180°</i>

Near

Vision

Without Rt.

Lens Rt.

REMARKS

J. J. With Rt. Use

PLEASE BRING THIS PRESCRIPTION WITH YOUR FUTURE VISIT