

डॉ. बी. एम. शरणागत
एम.डी. (मेडिसिन)

रजि.नं. - 4612
कार्डियो - डायबेटोलॉजिस्ट
एवं परामर्श चिकित्सक



सर्किट हाउस रोड, बालाघाट ☎ 07632-241070 | समय-सुबह 10 बजे से संध्या 8.00 बजे तक

Name **MR. AKASH SONEKAR**

R/O

Date **23/12/2023**

General Physical Examination

Date of Examination **23/12/2023**

Name **MR. AKASH SONEKAR** Age **34y** DOB **04/04/1989** Sex **M**.....

Referred by **MEDIWHEEL**

Photo Id **ADHAAR CARD** ID

Ht **1.75** (CM)

Wt **67** (kg)

Chest (Expiration): **94** (cm)

Abdomen Circumference **101** (cm)

Blood Pressure **130/90** mm Hg

PR **16** /min

RR **22** /min

Temp **98.6°F**


BMI **22.1**

Eye Examination **RE** **LE**


6/6 **6/6**

Other: **Nil**

On examination he/she appears physically and mentally fit: Yes/No Yes

Signature of Examinee:  Name of Examinee: **MR. AKASH SONEKAR**

Signature Medical Examiner: Name Medical Examiner


Dr. B. M. SHARNAGAT
M.D. (Medicine) Reg. No 4612
AYUSHMAN HOSPITAL
& Diagnostic Research Center
BALAGHAT (M.P.) 491100

|| उपलब्ध सुविधाएं ||

- क्रिटिकल केयर यूनिट/आई.सी.सी.यू., सेंट्रल ऑक्सीजन पाइप लाईन युक्त
- फेफड़ों के कार्य क्षमता की कम्प्यूटराईज्ड जाँच (P.F.T.)
- मल्टीपैरा, पल्स ऑक्स, डीफ्रिबीलेटर एवं वेंटीलेटर सुविधाएँ
- फिजियोथेरेपी युनिट एवं डायटिशियन परामर्श।
- कम्प्यूटराईज्ड ई.सी.जी., टी.एम.टी., होल्टर मॉनिटरिंग व अल्ट्रासोनो नेबुलाईजेशन
- डायबीटिज, अस्थमा एवं किडनी क्लिनिक।
- एक्सरे, पैथालॉजी, मेडिकल स्टोर्स व कैंटीन सुविधा
- मनोचिकित्सक, चर्मरोग, कैंसर एवं किडनी विशेषज्ञ द्वारा परामर्श - प्रति रविवार
- सेंट्रली एयर कूल्ड एवं ए.सी.युक्त प्राइवेट एवं जनरल वार्ड
- 24 घंटे इमरजेन्सी सेवा, एम्बुलेन्स एवं विद्युत जनरेटर व्यवस्था।



आयुष्मान हॉस्पिटल
एण्ड डायग्नोस्टिक रिसर्च सेन्टर

Regd.No. : NHA/REG/BGT/2012/21

NAME - MR. AKASH SONEKAR

Age - 34Y/M

R / By - MEDIWHEEL

Date - 23/12/2023

X- RAY CHEST (PA VIEW)

- *Bony cage - Normal.
- *Trachea - Normal.
- * Heart - Position --- Normal.
C-T ratio---Within normal limits.
Cardiac borders--- Normal.
Specific chamber enlargement---None.
- *Aorta- Position---Normal.
- *Mediastinum- Relative Position ---Normal.
Any Lesion---None.
- *Angles- Cardiophrenic angles---Clear.
Costophrenic angles---Clear.
- *Pleura- Normal.
- *Lungs- .Lung apices seen clear.
.Both lungs seen clear.
.No evidence of any focal active lesion in lung fields.
.Broncho-vascular markings appear normal.
- *Hilar shadows- Normal.
- *Diaphragms- Relative position---Normal.
Outline---Normal.

OPINION

"X-RAY CHEST APPEARS NORMAL."
"NO ABNORMALITY DETECTED."

Thanks for referral.

Dr. B. M. SHARMA AGAT
MD (V) (AYU) 461
Stamp
8 Dams Road, Balaghat
BALAGHAT (M.P.) 491001

2D ECHOCARDIOGRAPHY & DOPPLER REPORT

NAME - MR. AKASH SONEKAR

AGE - 34YRS/M

REFD. BY - SELF

DATE - 23.12.2023

M-Mode & Essential Measurements :-

Heart Rate : 82 Bpm	LVID(D) : 36 mm	MV Annulus : 25 mm	RVID(d) : 34 mm
Aortic Root : 28 mm	LVID(S) : 18 mm	TV Annulus : 24 mm	IVC : 16 mm
Left Atrium : 34 mm	IVSd (D) : 11 mm	AO Annulus : 19 mm	Mitral-Epss : 06 mm
LVEF : 60 %	LVPWd(D) : 12 mm	PV Annulus : 20 mm	TAPSE : 16 mm

2D Echo Findings :-

RWM(LV) : NORMAL
 CHAMBERS : NORMAL SIZED
 IAS/IVS : INTACT
 I/C - CLOT/VEGETATION : NIL
 PERICARDIAL EFFUSION : NIL
 PLEURAL EFFUSION : NIL

Doppler Study :-


	Peak Gradient (mm of Hg)	Mean Gradient (mm of Hg)	Valve area (Normal Range)	Grade of Regurgitation
Mitral Valve	--	--	4.0-6.0	NIL
Aortic Valve	--	--	2.5-4.0	NIL
Tricuspid Valve	--	--	7.0-9.0	NIL
Pulmonary Valve	--	--	2.0-3.0	NIL

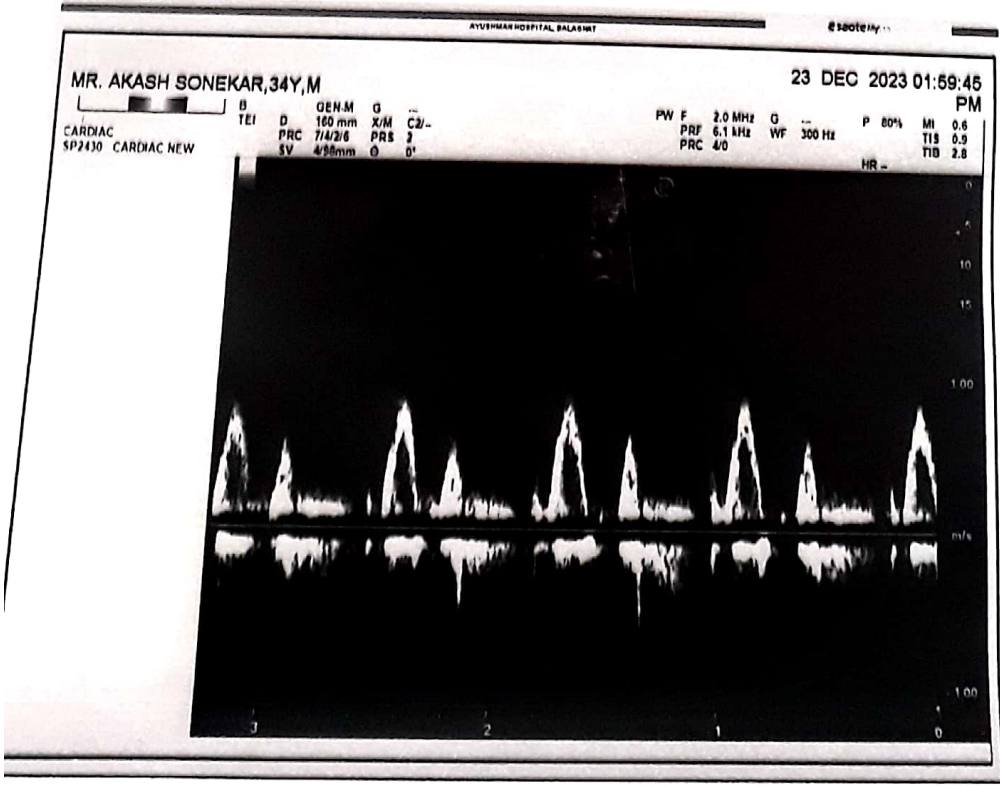
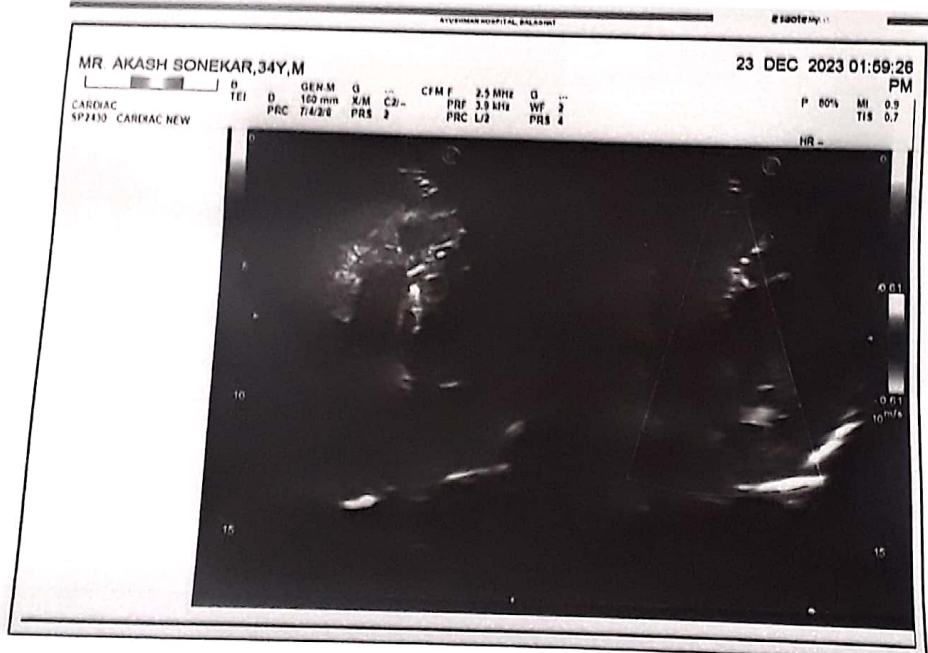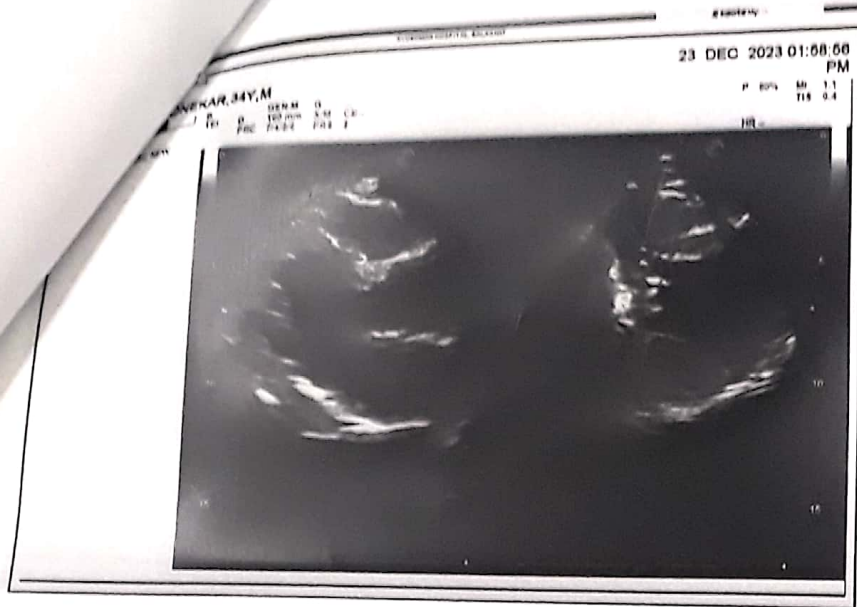Estimated PASP by TR jet = 25 mm of Hg.

FINAL DIAGNOSIS :-

NO RWMA, LVEF = 60%
 NO LVDD
 NORMAL VALVES
 NORMAL LV SYSTOLIC FUNCTION
 NORMAL RV FUNCTION.




 Dr. B.M. SHARNAGAT
 MD (Medical) Reg. No. 4812
 AYUSHMAN HOSPITAL
 Dr. B.M. Sharnagat (MD Medicine)
 BAL-CPA
 28/06/2023



ULTRASOUND REPORT

Name - MR. AKASH SONEKAR

Age - 32Yrs/M

Refd. By - SELF

Date -23.12.2023

LIVER : The liver is normal in size and shape . It shows normal parenchymal echo texture.

The IHBR , IHPR and porta hepatis appear normal.

There is no e/o any lesion.

GALLBLADDER : Normal , There is no e/o evidence of calculi.

PANCREAS : Normal in size and shows normal echotexture.

SPLEEN : Spleen is normal in size and shows homogenous echo texture.

KIDNEYS : Both kidneys are normal in size, shape, contour and in position .

There is no renal calculi and no pelvi calyceal dilatation .


LEFT KIDNEY MEASURES : 8.5 X 6.3 CM


RIGHT KIDNEY MEASURES : 6.2 X 4.7 CM

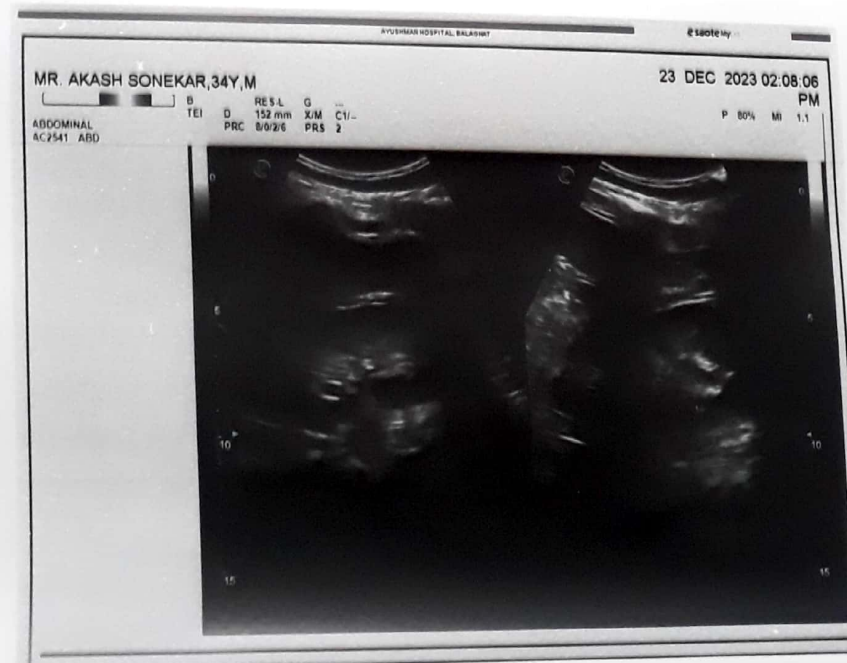
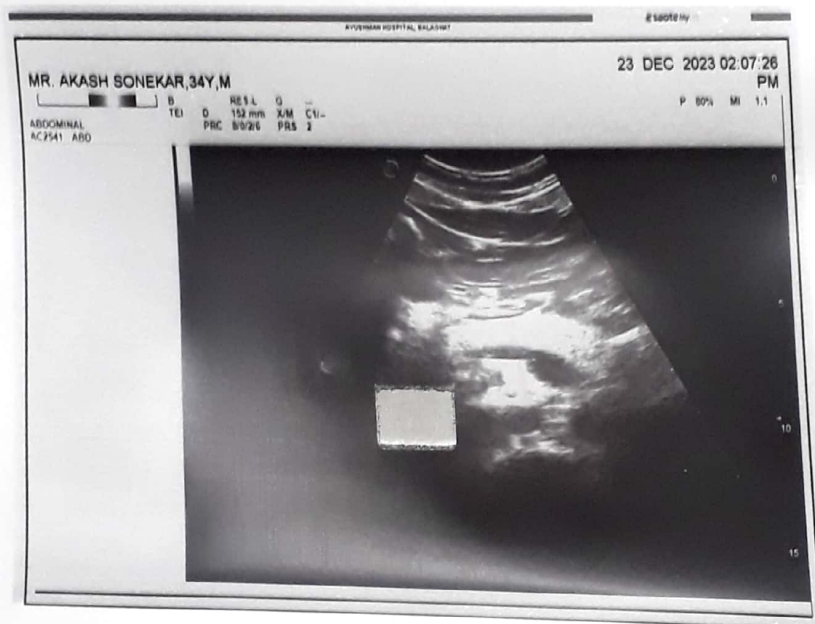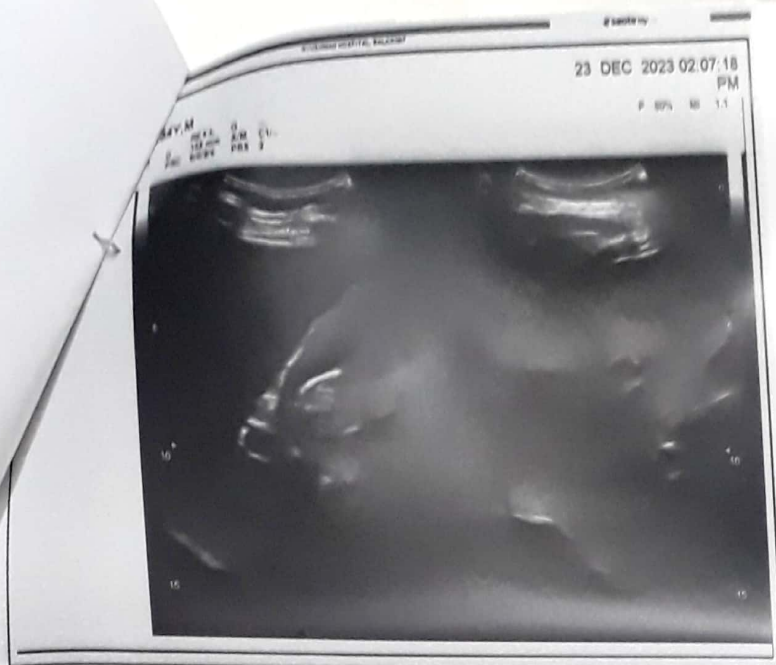PROSTATE : The prostate is normal in size and shows normal echo texture .

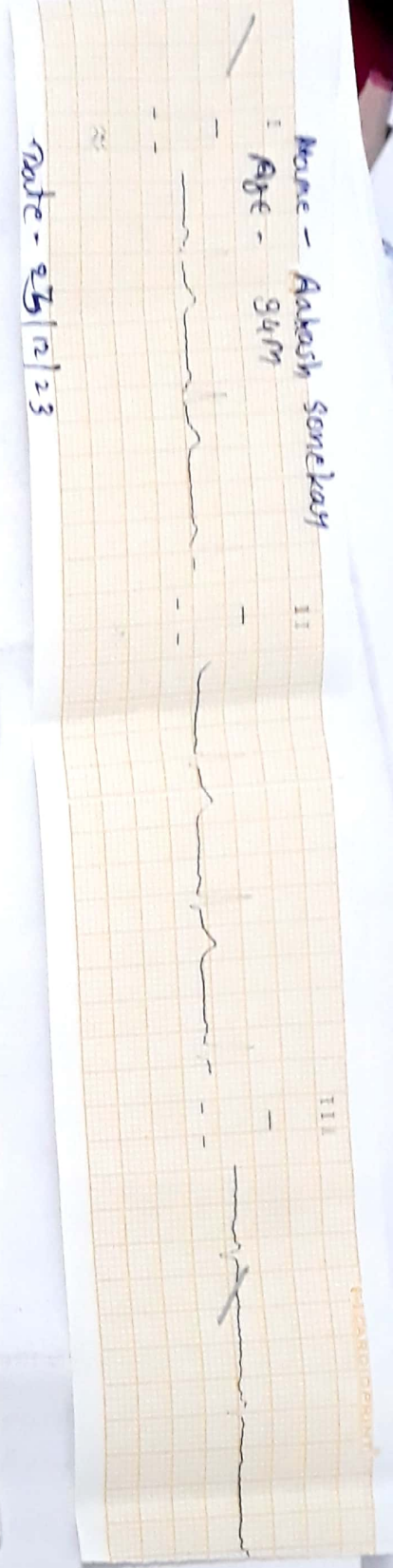
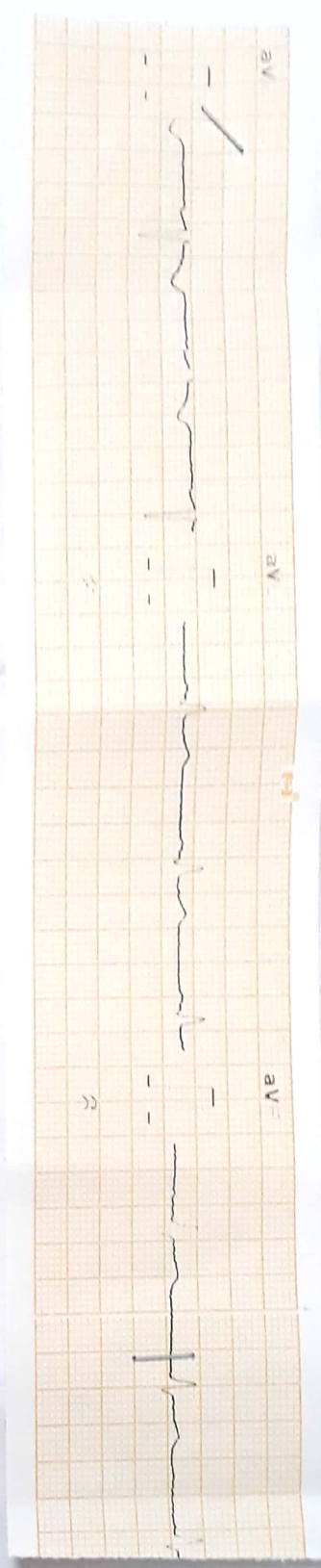
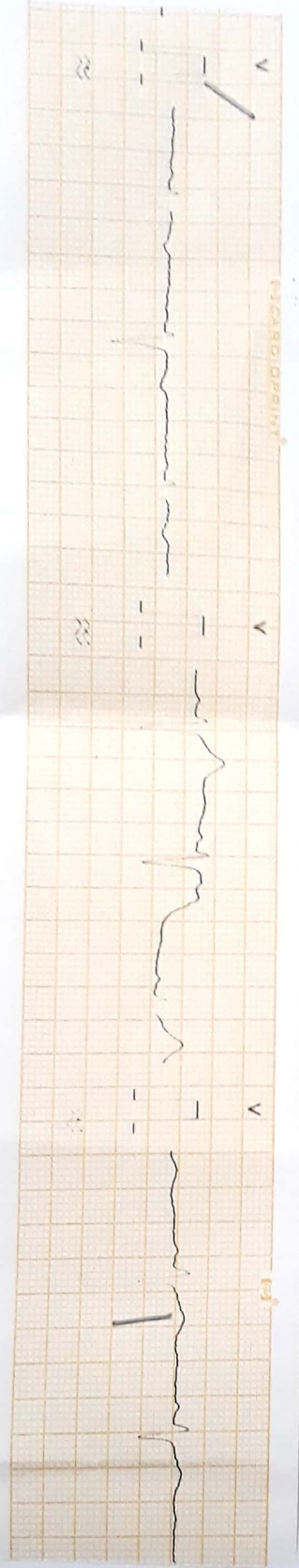

There is no e/o free fluid in pelvis .

IMPRESSION : NORMAL STUDY OF ABDOMEN .




Dr. B.M. SHARNAGAT
M D (Medicine) (P) (F) (C)
AYUSHMAN HOSPITAL
Dr. B.M. Sharnagat (MD Medicine)
BALAGHAT (M.P.) 481001





Date - 25/12/23

Name - Anubh Sonelast
Age - 34M

[Handwritten signature]

REPORT - NORMAL

[Handwritten signature]
Dr. B. M. SHARNAGAT
MD (Medicine) Reg. No. 4012
AYUSHMAN HOSPITAL
& Diagnostic Center
BALAGHAT - 481001

PATHOLOGY REPORT

• Auto Analyzer • Hematology Analyzer • A.B.G. • Computerised Lab

First Name: MR. AKASH
 Sample ID: 3
 Dpt.: PATHOLOGY
 Last Name: SONEKAR
 Patient Type:
 Time of Analysis: 23-12-2023 13:46
 Gender: Male
 Patient ID:
 Mode: WB
 Age: 34 Years

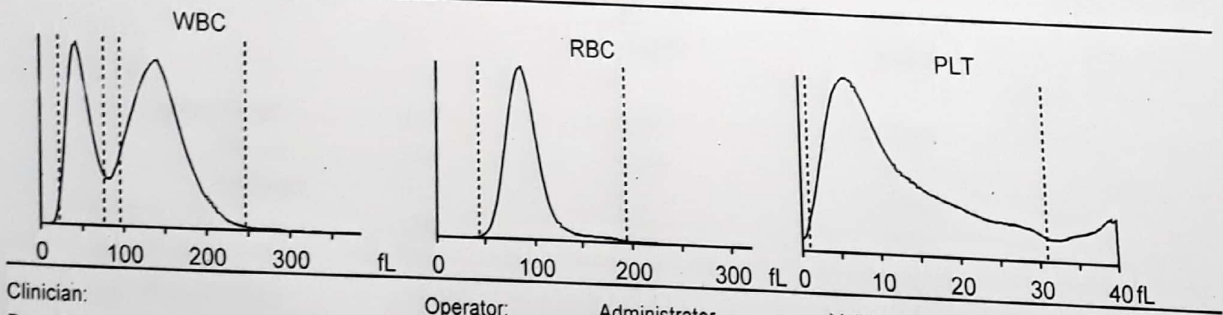
CBC Report done on Hemtology Analyzer Mispa CountX Plus

Modules	Result	Unit	Ref. Ranges
1 WBC	8.3	10 ³ /uL	4.0 - 10.0
2 Lymph#	2.6	10 ³ /uL	0.8 - 4.0
3 Mid#	0.4	10 ³ /uL	0.1 - 1.5
4 Gran#	5.3	10 ³ /uL	2.0 - 7.0
5 Lymph%	31.6	%	20.0 - 40.0
6 Mid%	5.1	%	3.0 - 15.0
7 Gran%	63.3	%	50.0 - 70.0
8 RBC	4.46	10 ⁶ /uL	4.00 - 5.50
9 HGB	13.8	g/dL	12.0 - 16.0
10 HCT	L 39.7	%	40.0 - 54.0
11 MCV	88.9	fL	80.0 - 100.0
12 MCH	30.9	pg	27.0 - 34.0
13 MCHC	34.8	g/dL	32.0 - 36.0
14 RDW-CV	14.2	%	11.0 - 16.0
15 RDW-SD	44.1	fL	35.0 - 56.0
16 PLT	181	10 ³ /uL	100 - 300
17 MPV	H 12.2	fL	6.5 - 12.0
18 PDW	H 18.0		15.0 - 17.0
19 PCT	0.222	%	0.108 - 0.282
20 P-LCC	75	10 ³ /uL	30 - 90
21 P-LCR	41.1	%	11.0 - 45.0

WBC Message

RBC Message

PLT Message



Clinician:
 Draw Time:
 Comments:
 [This report only applies to the corresponding sample analyzed]

Operator: Administrator
 Delivery Time:
 Validated By:
 Time of Printing: 23-12-2023 13:51

1/1
 Dr. B. M. SHARNAGAT
 M.D. Pathologist/Technician
 (Ayushman Hospital Balaghat)
 & Diagnostic Research Centre
 BALAGHAT (M.P.) 481001

• This Report is not valid for MLC purpose.
 • This Report is only for Physician's help to confirm the diagnosis.

PATHOLOGY REPORT

• Auto Analyzer • Hematology Analyzer • A.B.G. • Computerised Lab

NAME : MR. AKASH SONEKAR

REF. BY : Dr. B. M. SHARNAGAT (M.D.)

AGE : 34Yrs.

SEX : M

DATE : 23/12/2023

TEST
Blood group
Rh Type

BIOCHEMISTRY
RESULTS
A
Positive

UNITS
REF. RANGE

STOOL EXAMINATION

Stool for Routine & Microscopic Examination

: Normal

Stool for Occult blood

: Negative

THYROID HORMONE

TSH	3.2	uIU/mL	0.3 - 5.0
T3	0.74	ng/mL	0.6-1.8
T4	8.6	ug/dL	4.5-11.6
CRP(C-reactive Protien)	:4.0	mg/L	up to-06

LIPID PROFILE

S. Cholesterol	:154	mg/dl	UP TO <200
S. Triglycerides	:122	mg/dl	UP TO <150
HDL Cholesterol	:36	mg/dl	32 -60
LDL Cholesterol	:92	mg/dl	UP TO <100
VLDL Cholesterol	:23	mg/dl	7 - 35
LDL / HDL Ratio	:2.9	%	2.5 - 5.0
S. Cholesterol / HDL Ratio	:4.2	%	3.5 - 5.0

KFT

Serum CREATININE	:0.96	mg/dl	0.8-1.2
BUN	:13	mg/dl	8-20

LFT

Bilirubin-Total	:0.7	mg%	0-1.2
Direct	:0.4	mg%	0-0.6
Indirect	:0.3	mg%	0-0.5
SGPT(ALT)	:20	IU/L	7-35
SGOT(AST)	:22	IU/L	8-40
Alk.Phosphatase	:108	U/L	86-306 Adult
TOTAL PROTEINS	7.2	gm/dl	6.2-8.2
Albumin	4.5	g/dl	3.5-5.5
Globulin	2.4	g/dl	2.5-3.2
A/G Ratio	1.7		1.5-2.5
GGT	18	U/L	9-48

Dr. B. M. SHARNAGAT
Pathologist/Technician
(Ayushman Hospital Balaghat)
BALAGHAT (M.P. - 481001)

- This Report is not valid for MLC purpose.
- This Report is only for Physician's help to confirm the diagnosis.

PATHOLOGY REPORT

• Auto Analyzer • Hematology Analyzer • A.B.G. • Computerised Lab

NAME : MR. AKASH SONEKAR
REF. BY : Dr. B. M. SHARNAGAT (M.D.)
AGE : 34Yrs. SEX : M
DATE : 23/12/2023

TEST	RESULTS	UNITS	REF. RANGE
B.SUGAR (f)	:88	mg/ dl	60-100
METHOD : GOD-POD			
S.URIC ACID	4.9	mg/dl	3.4- 7.2
<u>SEROLOGY</u>			
HIV I&II			
HbsAg	:NON-REACTIVE		
COTININE TEST	:NON-REACTIVE		
(Qualitative)	:NEGATIVE		
HbA1C	5.4 %		
			Nondiabetic :4.5 -6.2
			Good Control: 6.0 -7.0%
			Fair Control: 7.0 -8%
			Poor Control: >8%
			(Action Suggested)

ESR :08 1 st Hr
Method westangren 0-20

URINE ANALYSIS REPORT (By urometer120 analyzer)

PHYSICAL EXAMINATION


Colour : pale Yellow
Quantity : 10ml
Apperance : cliar

CHEMICAL EXAMINATION

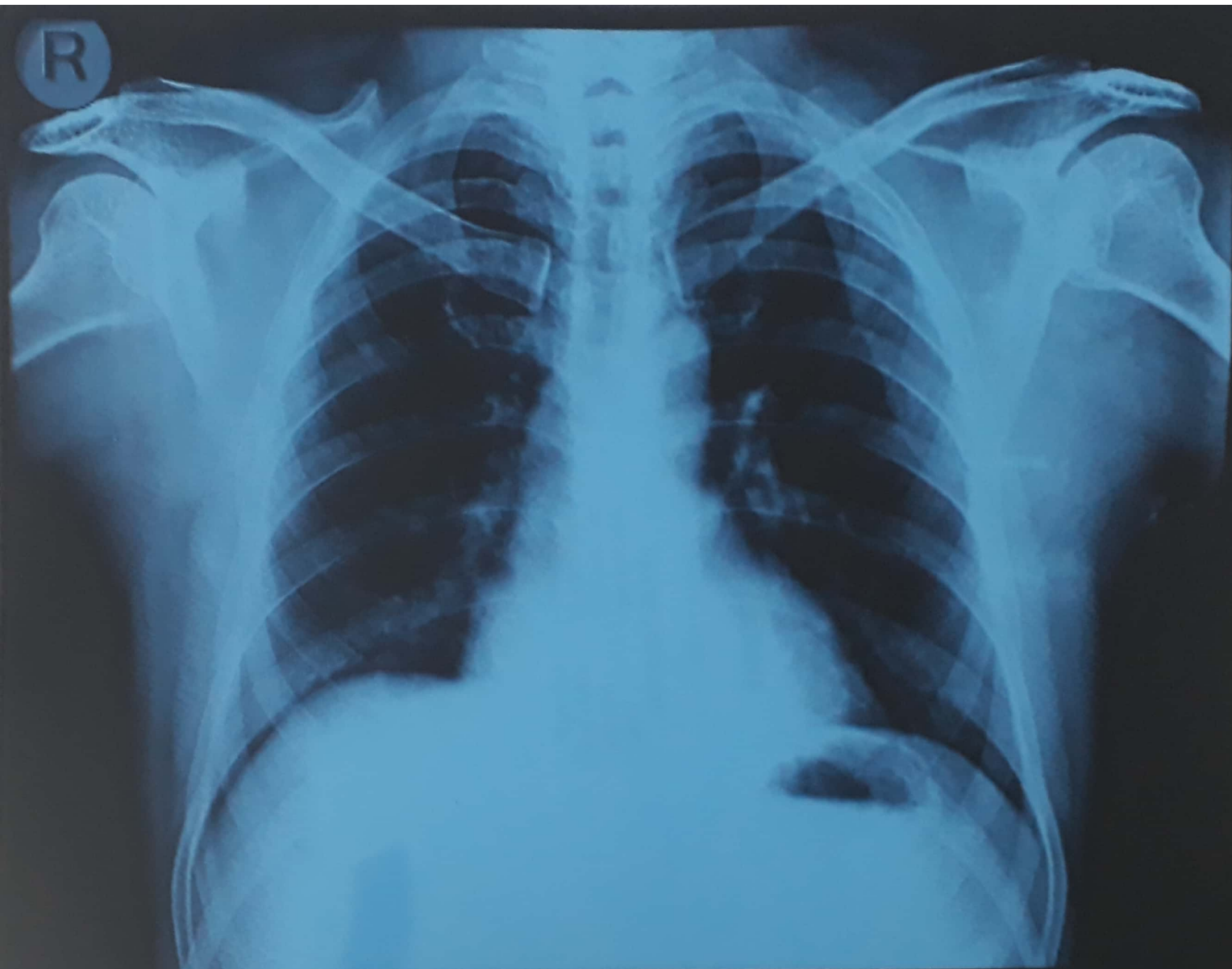Sugar : nil
Bile Pigment : nil
Nitrite : nil
Protein : nil
Bilirubin : nil
Ketone : nil
Albumin : nil
Urobilinogen : Normal 0.01 mg/ml
Specific gravity :1.010 1.010-1.030
Reaction(pH) : 5.5 (Acidic3-6,Alkaline8-10)

MICROSOPIC EXAMINATION

Pus(WBCs) Cells :NIL/ hpf
RBC :nil/hpf
Crystals : Absent
Spermatozoa : Absent
Epithelial Cells : Absent
Bactria :Absent


Dr. B.M. SHARNAGAT
M.D. (Medicine) & Diagnostic Radiology
I/C Pathologist/Technician
(Ayushman Hospital Balaghat)

• This Report is not valid for MLC purpose.
• This Report is only for Physician's help to confirm the diagnosis.



MR AAKASH SONEKAR 34 YRS MALE
Body Part CHEST
AYUSHMAN HOSPITAL BALAGHAT

23/12/2023

Ref DR B. M. SHARMA, SIK, M.D.

MEERA AADHAAR, MERI PEHAACHAN

5648 8797 5316

S/O: वेदश नारायण
 पत्नी: सोनेकर, बॉई नं. 33, कभार
 कनिष्ठ के पास, सोनी नगर,
 बलघात, बालघाट,
 मध्य प्रदेश - 481001

Address:
 S/O: Vedesh Narayan Sonekar,
 ward no.33, near kumar furniture,
 moli nagar, Balaghat, Balaghat,
 Madhya Pradesh - 481001

आकाश सोनेकर
 Akash Sonekar
 जन्म तिथि/DOB: 01/01/1989
 पुरुष / MALE

5648 8797 5316
 मेरा आधार, मेरी पहचान

भारत सरकार
 GOVERNMENT OF INDIA

आकाश सोनेकर
 Akash Sonekar
 जन्म तिथि/DOB: 01/01/1989
 पुरुष / MALE

5648 8797 5316
 मेरा आधार, मेरी पहचान

(Handwritten signature)

(Handwritten signature)
 Dr.B.M.SHARNAGAT
 M.D.(Medicine) Regd No.4612
 AYUSHMAN HOSPITAL
 & Diagnostic Research Ceter
 BALAGHAT (M.P.) 481001