

DAKSH HOSPITAL

396 - 397, Gandhi Nagar, Scheme No. 8, ALWAR -301001

Ref. No.

Date.....

MEDICAL EXAMINATION REPORT
Mediwheel (BOB)


Name: Mrs Neetu Devi

Age: 37 yrs Sex: Female

Date: 26/10/2024

General Physical Examination

| | | | | | |
|--------|---|---------|------------------|---|---------------|
| Height | : | 168 cm. | Weight | : | 56.7 kg |
| Pulse | : | 80 bpm | BP | : | 120/70 mm/hg. |
| Temp. | : | 97.0F | Respiration SpO2 | : | 93 % |
| BMI | : | 20.1 | | | |

Systemic Exam:- NORMAL**Dental Check up :-** NORMAL**Eye check-up :-** NORMAL**Skin Check up:-** NORMAL**ENT Check up:-** NORMAL**Gynae Check up:-** Spod m
LMP - 10-15dyem - Pr Kewary,
LMP 8dy
Bt chie**Impression:-** MICROCYTIC ANEMIA**Recommendation:-** EVALUATION FOR ANEMIA

 Dr. Mukesh Kumar Gupta
 MD Gen. Medicine
 Reg. No 5423/16262

डॉ० मुकेश गुप्ता
M.D.F.C.C.S.
 फिजिशियन एवं मधुमेह रोग विशेषज्ञ
 दक्ष हॉस्पिटल, अलवर
 रजि० नं०-5423/16262

Results

Run Date 26/10/2024 09:55:31 AM

Operator DAKSH

Last Name

Sample ID 7

First Name NEETU DEVI

Department

Gender Female

Age

Physician DR. MUKESH GUPTA M.D

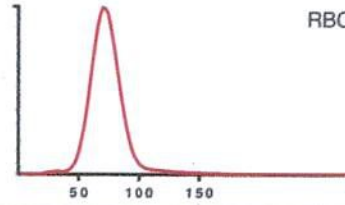
Patient ID AUTO_PID26061

Type Woman

Date of birth

Sample comments

| | | | Range |
|--------|------|---------------------|-------------|
| RBC | 4.03 | 10 ⁶ /μL | 3.80 - 5.50 |
| HGB | 9.9 | g/dL | 11.5 - 15.2 |
| HCT | 29.4 | % | 35.0 - 46.0 |
| MCV | 72.9 | μm ³ | 77.0 - 97.0 |
| MCH | 24.6 | pg | 26.0 - 34.0 |
| MCHC | 33.8 | g/dL | 32.0 - 35.0 |
| RDW-CV | 15.4 | % | 11.0 - 17.0 |
| RDW-SD | 44.8 | μm ³ | 37.0 - 49.0 |



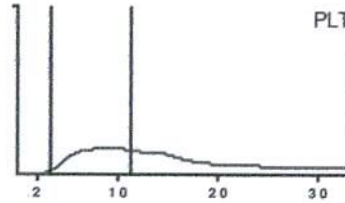
Recommended actions

Slide review

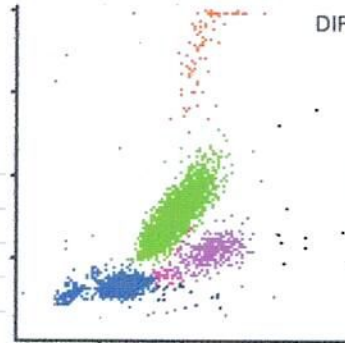
Susp. Pathologies

Macroplatelets

| | | | Range |
|-------|------|---------------------|-------------|
| PLT | 141 | 10 ³ /μL | 150 - 450 |
| PCT | 0.20 | % | 0.15 - 0.40 |
| MPV | 14.3 | μm ³ | 8.0 - 11.0 |
| PDW | 31.0 | μm ³ | 11.0 - 22.0 |
| P-LCC | 83 | 10 ³ /μL | 44 - 140 |
| P-LCR | 58.7 | % | 18.0 - 50.0 |



| | | | Range |
|-----|------|---------------------|--------------|
| WBC | 7.77 | 10 ³ /μL | 3.50 - 10.00 |
| | # | | |
| NEU | 4.80 | 1.60 - 7.00 | 62.0 |
| LYM | 2.55 | 1.00 - 3.00 | 32.9 |
| MON | 0.19 | 0.20 - 0.80 | 2.4 |
| EOS | 0.13 | 0.00 - 0.50 | 1.7 |
| BAS | 0.08 | 0.00 - 0.15 | 1.0 |
| LIC | 0.02 | 0.00 - 0.10 | 0.2 |



Dr. R.S. Gupta
Dr. R.S. GUPTA
 MD (Pathology) (MAHE)
 RMC No. 7924/19778

Date :-26/10/2024 Name :- MRS. NEETU DEVI

Age & Sex :- 37 Yrs/ Female

Refd. :- Dr Mukesh Gupta M.D.

| | TEST NAME | RESULT | REFERENCE RANGE |
|--------------------------------------|------------------------------|--------------------|--------------------------------|
| | ESR | 16 | 00 -20 mm/hrs |
| | Blood Group & Rh Factor | AB" POSITIVE | |
| | HbA1C | 4.5 | 4 - 5.6% |
| | Blood Sugar (F) | 80.3 | < 70 - 100 mg/dl |
| | Blood Sugar (PP) | - | < 140 mg/dl |
| | Urine Sugar (F) | NIL | - |
| | Urine Sugar (PP) | - | - |
| LIVER | S.Bilirubin Total | 0.88 | 0.30 - 1.20 mg/dl |
| | S.Bilirubin Direct | 0.20 | 0.10 - 0.30 mg/dl |
| | S.Bilirubin Indirect | 0.68 | 0.30 - 0.90 mg/dl |
| | S.G.O.T. | 15 | > 37 u/l |
| | S.G.P.T. | 21 | > 40 u/l |
| | S.Alk. Phosp. | 205 | 80 - 306 u/l |
| | G.G.T. | 28 | 5 -40 u/l |
| | Total Protein | 6.8 | 6.5 - 8.5 gm/dl |
| | Albumin | 3.6 | 3.8 - 5.4 gm/dl |
| | Globulin | 3.2 | 2.3 - 3.5 gm/dl |
| | A/G Ratio | 1.2 | - |
| | AST/ALT Ratio | 0.84 | - |
| KIDNEY | Blood Urea | 24.6 | 15 -45 mg/dl |
| | S.Creatinine | 0.74 | 0.60 - 1.30 mg/dl |
| | BUN | 17.0 | 6 -24 mg/dl |
| | S.Uric Acid | 5.1 | M 3.1 - 7.0, F 2.5 - 5.6 mg/dl |
| | BUN/Creatinine Ratio | 0.75 | - |
| LIPID PROFILE | Total Cholesterol | 155.0 | Up to 200 mg/dl |
| | S.HDL | 41.0 | 30 - 70 mg/dl |
| | S.LDL | 89.0 | Up to 170 mg/dl |
| | S.VLDL | 25.0 | 5.0 - 40 mg/dl |
| | S. Triglycerides | 125.0 | Up to 170 mg/dl |
| | LDL/HDL Ratio | 2.1 | - |
| | Total Cholesterol/ HDL Ratio | 3.7 | - |
| THYROID | T3 | 108.3 | 40 - 181 ng/dl |
| | T4 | 8.1 | 4.6 - 10.5 µg/dl |
| | TSH | 1.20 | 0.30 - 5.0 mlu/l |
| | URINE EXAMINATION | | Microscopic Examination: |
| General/Chemical Examination: | | | RBC Absent |
| | Colour | Pale Yellow | WBC 2 -3 |
| | Reaction | Acidic | Epithelial Cells 1 -2 |
| | Specific Gravity | QNS | Cast Absent |
| | Appearance | Clear | Crystal Absent |
| | Albumin | TRACE | Spermatozoa Absent |
| | Sugar | Nil | Amorphous Sediments Absent |
| | | | Other Absent |
| | X-RAY CHEST | NORMAL STUDY | |

Dr. R.S. GUPTA
MD (Pathology) (MAHE)
RMC No. 7924/19778
Doctor

TECHNOLOGIST

All investigation have their own limitations regarding the sensitivity & specificity of individual assay procedures, Isolated laboratory investigations never confirm the final diagnosis of the disease. They only help in arriving at a diagnosis in conjunction with clinical presentation and other related investigations. Report is not valid for medico-legal purpose subject to ALWAR jurisdiction only.

Date :- 26/10/2024

Name :- Mrs. Neetu Devi

Refd. :- Dr Mukesh Gupta MD

Age & Sex :- 37Yrs/ Female

CYTO-PATHOLOGY

PAP SMEAR

| | |
|------------------------|---|
| 1. Specimen type | Received two conventional smears. |
| 2. Specimen adequacy | Smears are satisfactory for evaluation. |
| 3. Microscopic finding | Smears are moderately cellular comprises of predominantly intermediate with mature superficial squamous epithelial cells arranged in clusters & scattered singly. |
| 4. Inflammation | Not seen |
| 5. Bacilli | Not seen |
| 6. Endocervical cells | Not seen |
| 7. Koilocytic changes | Not seen |
| 8. Trichomonas | Not seen |
| 9. Dysplasia | Nil |
| 10. Neoplasia | Nil |
| 11. Endometrial cells | Nil |

Impression:- Negative for intraepithelial lesion or malignancy


Dr. R.S. GUPTA
MD (Pathology) (MAHE)
RMC No. 7924/19778

Doctor


TECHNOLOGIST

All investigation have their own limitations regarding the sensitivity & specificity of individual assay procedures, Isolated laboratory investigations never confirm the final diagnosis of the disease. They only help in arriving at a diagnosis in conjunction with clinical presentation and other related investigations. Report is not valid for medico-legal purpose subject to ALWAR jurisdiction only.



दक्ष हॉस्पिटल

396, गाँधी नगर स्कीम नं.8, अलवर (राज०) ☎ 0144-2703340

Sonography / 2D Echo Cardiography / Doppler Report

2D/ ECHO REPORT

Name: - Mrs NEETU DEVI Age: - 37 Yrs Date: - 26-Oct-24

Reg. No.:- Alw/2009/04
BOB health checkup

PROCEDURES: M-MODE/2D/DOPPLER/COLOR/CONTRASTB.A.S. M²

| MEASUREMENT: | | | DOPPLER: | | | | |
|----------------------|------|-------------------|---------------------|-----|------------|--------|----|
| AOD | 15 | NORMAL (20- 37mm) | MV | 0.6 | (0.8- 1.3) | MR | No |
| LA | 18.8 | (19- 40mm) | AV | 1.4 | (1.2- 1.8) | AR | No |
| AVO | 20 | (12- 25mm) | TV | 0.6 | (0.3- 0.8) | TR | No |
| RVDd. | 9.7 | (03- 09mm) | PV | 0.8 | (0.7- 1.1) | PR | No |
| LVDd | 44.6 | (37- 56mm) | MITRAL VALVE- | | | | |
| LVDs | 26.5 | (22- 40mm) | | | AML | Normal | |
| IVS d | 5 | (06- 12mm) | | | PML | Normal | |
| IVS s | 8 | | AORTIC VALVE | | | | |
| PWd | 3 | (05- 10mm) | | | | Normal | |
| LV FUNCTION | | | TV & PV are normal. | | | | |
| M- E- S Separation | | <0.9cm | | | | | |
| Minor | | 24.42% | | | | | |
| LV Ejection Fraction | 71% | 65 +/- 12% | | | | | |

LV WALL MOTION: NO RWMA
ALL CARDIAC CHAMBERS ARE NORMAL
ALL VALVES ARE NORMAL
NO CLOT, VEGETATION, PERICARDIAL EFFUSION

FINAL DIAGNOSIS: NORMAL STUDY

Adv: - Follow up/ review at higher center for confirmation

Note:- Please Correlate clinically. Due to technical limitations as well as inaccuracies inherent in the laboratory and statistical analysis of biological process. Diagnostic accuracy of ECHO is up to 95% only.
Report is not valid for medico-legal purpose.


Dr. Mukesh Gupta
PHYSICIAN
Physician & Sonologist
RM 5423/16262



"भ्रूण लिंग परीक्षण की शिकायत
104 टोल फ्री सेवा पर भी की
जा सकती है"
भ्रूण लिंग परीक्षण की शिकायत 104 टोल फ्री सेवा पर भी की जा सकती है।



दक्ष हॉस्पिटल

396, गाँधी नगर स्कीम नं.8, अलवर (राज०) ☎ 0144-2703340

Sonography / 2D Echo Cardiography / Doppler Report

NAME :- MRS NEETU DEVI/F/37 YRS

26-Oct-24

BOB HEALTH CHECKUP

U.S.G. OF ABDOMEN & PELVIS

LIVER

Liver is normal in size shape with normal echo-texture. Intra hepatic biliary radicals Are not dilated. No evidence of focal or diffuse lesion.

GALL BLADDER

Gall bladder to be review after fasting to rule out stone.

PANCREAS

Pancreas is normal in size, shape & echo-texture. No evidence of focal or diffuse lesion. MPD not dilated.

SPLEEN

Spleen normal in size with normal shape & echo- texture. Spleen vein is normal. No evidence of focal or diffuse lesion

KIDNEY

Both kidneys are normal size shape and echo- texture.

URINARY BLADDER

UB is normal.

UTERUS:

Uterus is **retroverted** normal in size (9.2x3.4x4.9cm) with homogenous echo-texture. Endometrial 5 mm in thickness & echo genicity

OVARIES:

Both ovaries are normal size, shape & echo-texture.

Advice- follow up/ hormonal study review at higher center for confirmation

Please correlate clinically. USG accuracy is 95 % due to technical limitations as well as inaccuracies inherent in the laboratory and statistical analysis biological process. This report is not valid for medico-legal cases

DR. MUKESH GUPTA
SONOLOGIST
Physician & Sonologist
RM 5423/16262



"भ्रूण लिंग परीक्षण की शिकायत
104 टोल फ्री सेवा पर भी की
जा सकती है"

भ्रूण लिंग परीक्षण की शिकायत 104 टोल फ्री सेवा पर भी की जा सकती है।

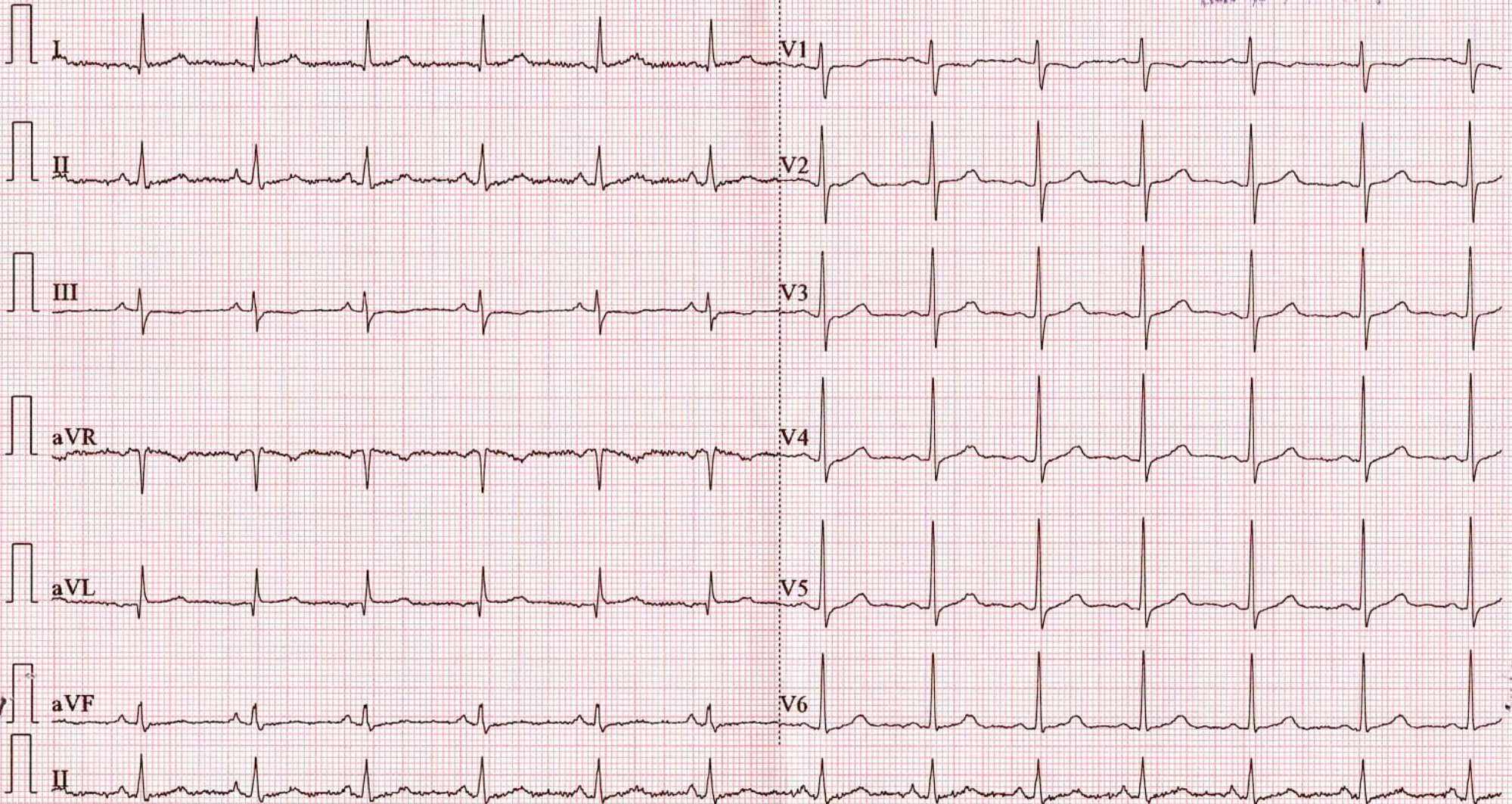
ID: 5
MRS. NEETU DEVZ
Female 37Years

HR : 78 bpm
P : 112 ms
PR : 158 ms
QRS : 90 ms
QT/QTc : 380/434 ms
P/QRS/T : 71/19/18 °
RV5/SV1 : 1.526/0.509 mV

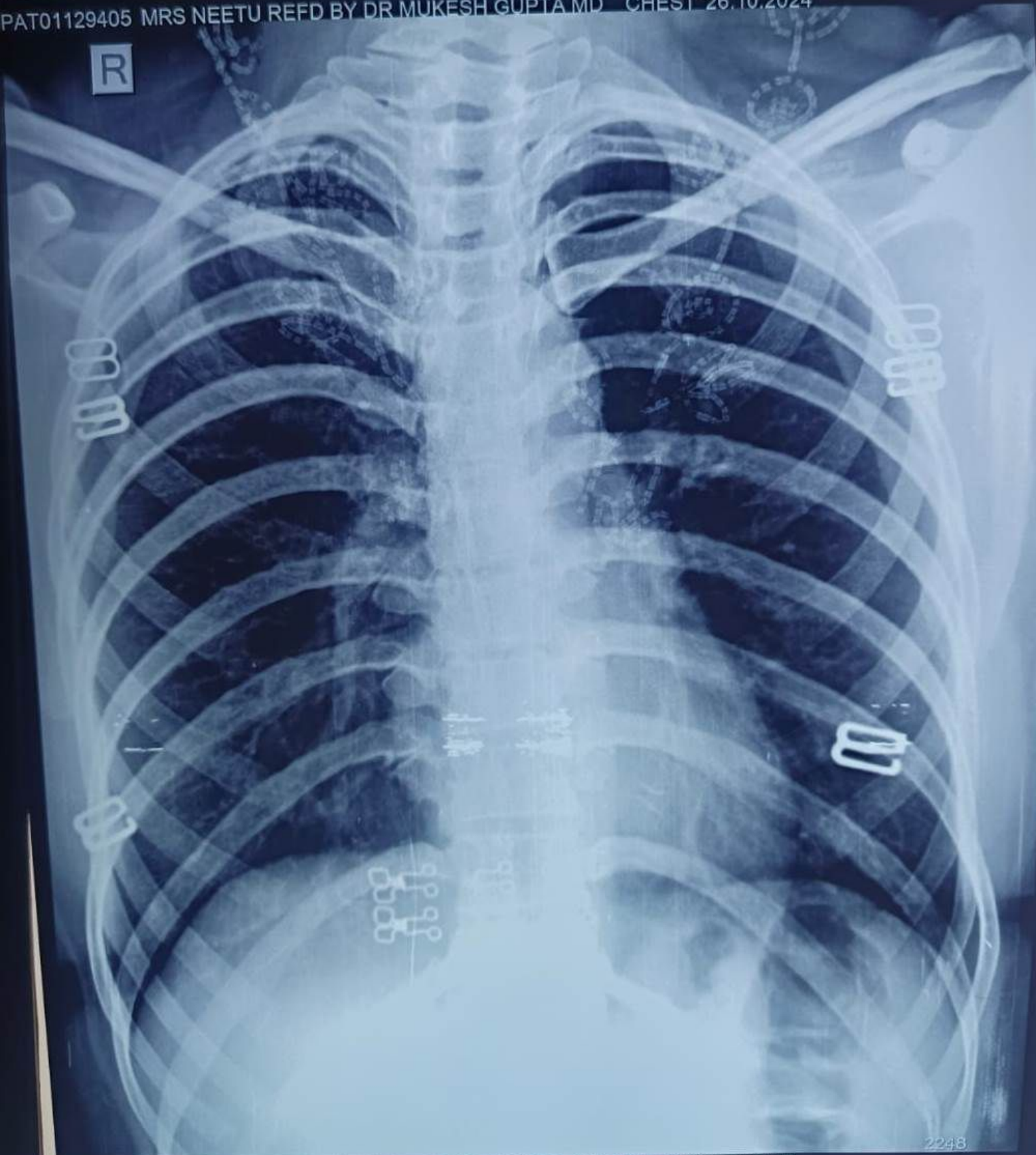
Diagnosis Information:
Sinus Rhythm
Normal ECG


डॉ० मुकेश गुप्ता
M.D.F.C.C.S.
फिजिशियन एवं मधुमेह रोग विशेषज्ञ
दक्ष हॉस्पिटल, अलवर
रजि० नं०-5423/16262

Report Confirmed by:



R



2248