

Delhi Transport Corporation

Vehicle Registration Certificate

REGISTRATION NO. : PD04000000017 **N**

NAME : NISHU YADAV

Holder of : SH R S YADAV

ADDRESS : HSE 205 CHAKUR PUR
RASH BACH
DELHI 110004

DT. OF BIRTH : 11/08/1988

VEHICLE CLASS : MCYL **03/04/2008**
LHM(T) **03/04/2008**

(Holder's Signature)

DT. OF ISSUE : 03/04/2008

VALIDITY : 03/04/2028

INV CARR NO. : NA

(Licencing Authority Signature)
Sig. Of Licencing Authority (MCZ)

(Signature)

Dr. NITIN AGARWAL
MBBS, MD
Regn. No. DMC-R-1436


ONEPLUS ULTRASOUND LAB
47, Harsh Vihar, Pitam Pura,
Delhi-110034
Ph. 011-42480101, 9599913051
E-mail: oneplusul@gmail.com



Dr. NITIN AGARWAL
MBBS, MD
Regn. No. DMC-R-1436



ONEPLUS ULTRASOUND LAB
47, Harsh Vihar, Pitam Pura,
Delhi-110034
Ph. 011-42480101, 9599913051
E-mail: oneplusul@gmail.com



To,

UltraSound Lab.
Pitampura.
Delhi

Sir,

Sub: Mediwheel Annual Health Checkup ID.
21M965041000136345 in the name of.
Meenu Yadav.

In reference to the Captioned Subject, i dont want
to give stools, After fasting Sugar & Urine Sample.

This is for your information please.

Regards,
Meenu

MEENU YADAV.
9953410428.



Dr. NITIN AGARWAL
MBBS, MD
Regn. No. DMC-R-1436

ONEPLUS ULTRASOUND LAB
47, Harsh Vihar, Pitam Pura,
Delhi-110034
Ph. 011-42480101, 9599913051
E-mail: oneplusul@gmail.com

ONEPLUS ULTRASOUND LAB

47, HARSH VIHAR, PITAMPURA, DELHI- 110034

Ms. MEENU YADAV
 Age : 32/F
 Ref. by: MEDIHHEEL
 Indication1 :
 Indication2 :
 Indication3 :
 COMMENTS :

ID : 1906
 HMMT : 164/62
 Recorded : 12-3-2022 11:13
 Medication1 :
 Medication2 :
 Medication3 :

BPM : 91
 BP : 108/74
 P Axis : 82 deg
 QRS Axis : -41 deg
 T Axis : 6 deg

P duration : 86 msec
 PR duration : 130 msec
 QRS duration : 90 msec
 QT interval : 316 msec
 QTc interval : 370 msec

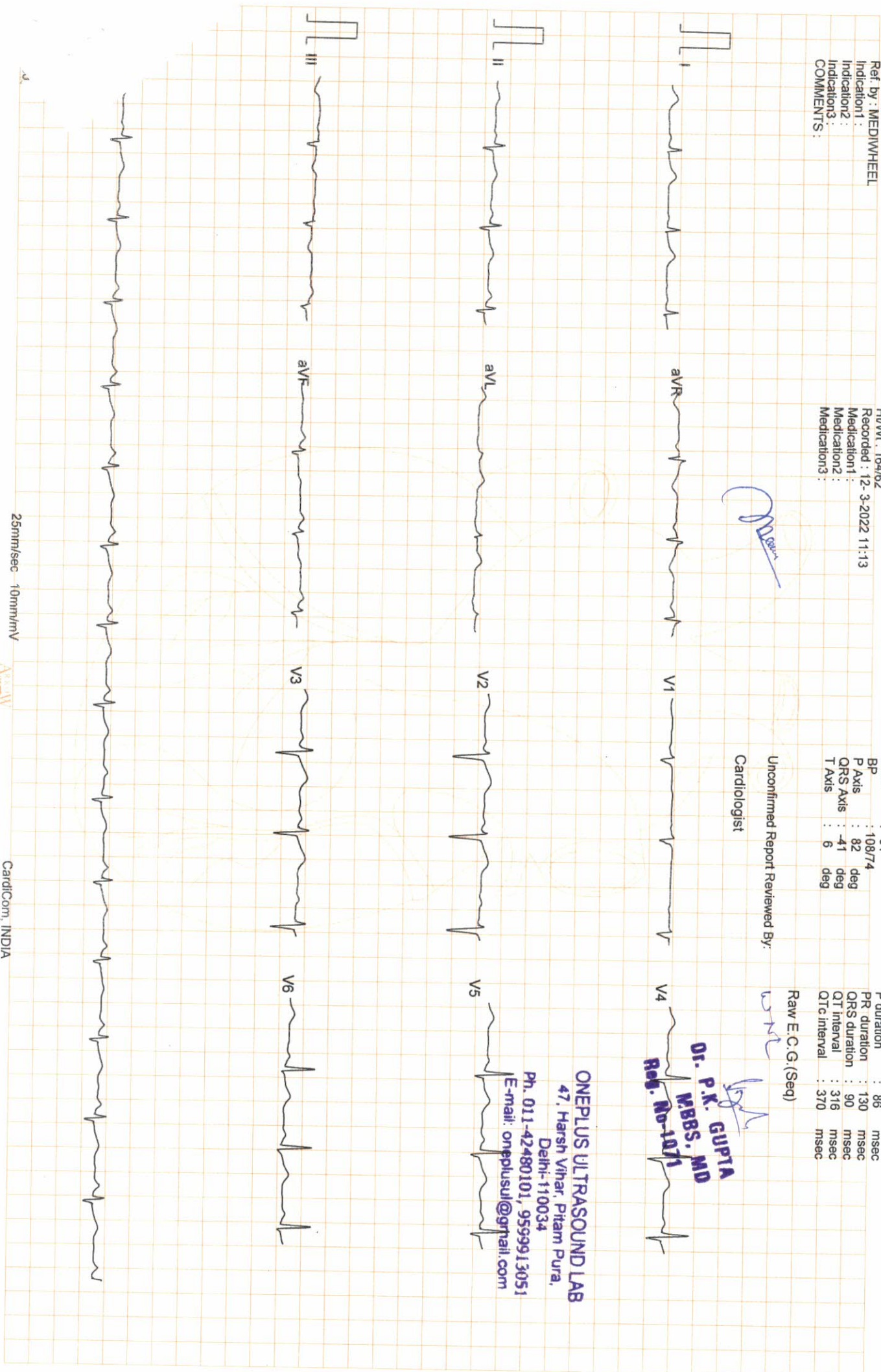
Raw E.C.G. (Seq)

[Signature]

Unconfirmed Report Reviewed By:
 Cardiologist

Dr. P.K. GUPTA
MBBS. MD
Reg. No-1071

ONEPLUS ULTRASOUND LAB
 47, Harsh Vihar, Pitam Pura,
 Delhi-110034
 Ph. 011-42480101, 9599913051
 E-mail: oneplusul@gmail.com



25mm/Sec 10mm/mV

ACQUW

CardiCom, INDIA

1000

1000

1000

1000

1000

1000

1000

1000

1000

1000

1000

1000

1000

1000

1000

1000

1000

1000

1000

1000

1000

1000

1000

ONEPLUS ULTRASOUND LAB

47, HARSH VIHAR PITAMPURA DELHI 110034

Ms. MEENU YADAV

ID : 992
H/Wt : 164/62

Recorded : 12-3-2022 11:15

Age : 32/F
Ref. by : MEDIWHEEL
Indication1 :
Indication2 :
Indication3 :

TREADMILL TEST SUMMARY REPORT
Protocol: BRUCE
History:
Medication1 :
Medication2 :
Medication3 :

PHASE	PHASE TIME	STAGE TIME	SPEED (Km./Hr.)	GRADE (%)	H.R. (BPM)	B.P. (mmHg)	RPP X100	II	ST LEVEL (mm) V2	V5	METS
SUPINE											
STANDING											
STAGE 1	2:59	2:59	2.70	10.00	117	120/78	140	0.1	1.1	0.8	4.80
STAGE 2	5:59	2:59	4.00	12.00	136	130/82	176	0.3	1.6	0.8	7.10
STAGE 3	8:59	2:59	5.40	14.00	148	140/86	207	0.5	2.4	0.8	10.00
STAGE 4	9:59	0:59	6.70	16.00	188	150/90	282	0.7	1.8	0.9	11.32
PEAK EXER	10:01	1:01			189	150/90	283	0.7	1.8	0.9	11.36
RECOVERY	2:59	2:59	0.00	0.00	105	110/74	115	0.7	1.5	0.9	

RESULTS

Exercise Duration : 10:01 Minutes
Max Heart Rate : 189 bpm 100 % of target heart rate 188 bpm
Max Blood Pressure : 150/90 mmHg
Max Work Load : 11.36 METS
Reason of Termination :

Negative for ischaemia

P.K. GUPTA
Cardiologist, M.D.
Reg. No-10711

Meenu

ONEPLUS ULTRASOUND LAB
47, Harsh Vihar, Pitam Pura,
Delhi-110034
Ph. 011-42480101, 9599913051
E-mail: oneplusul@gmail.com

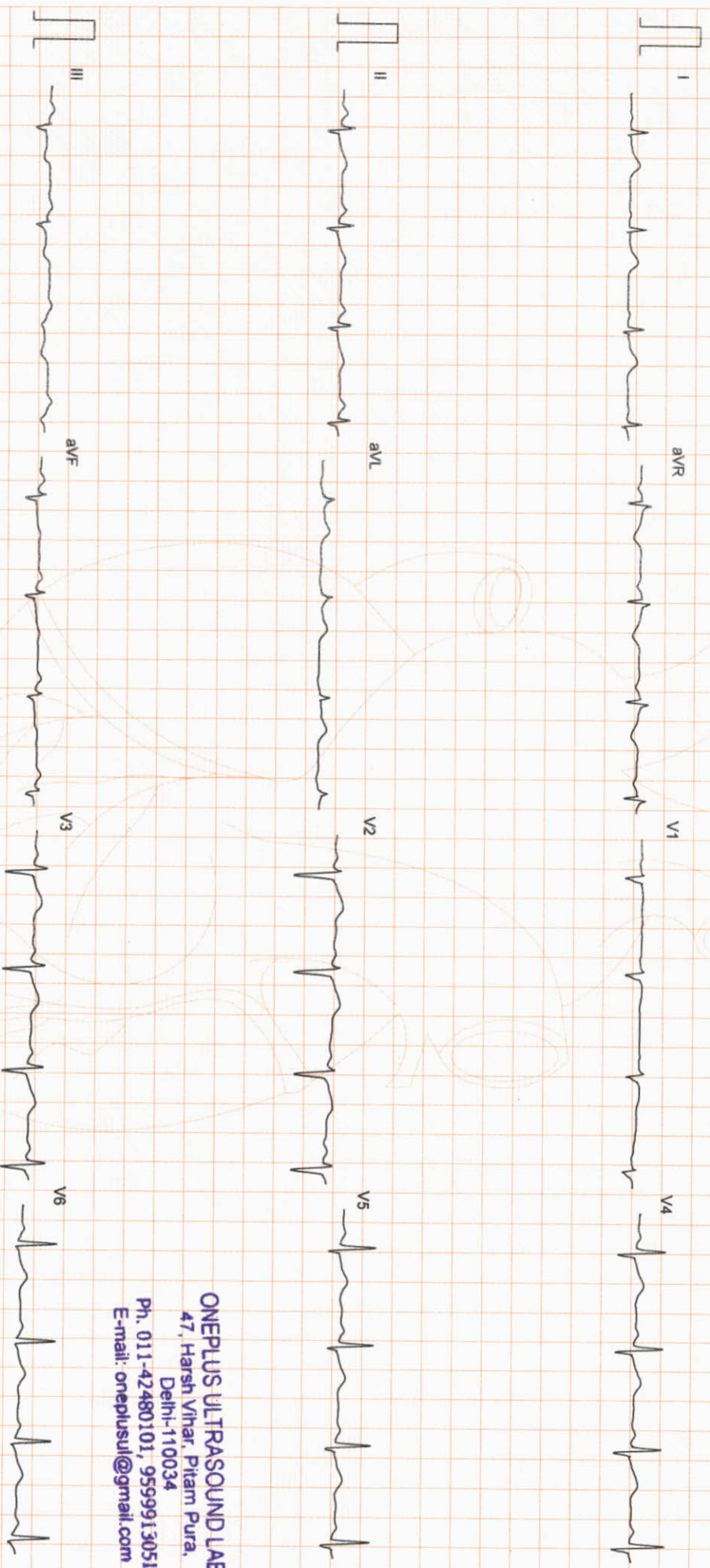
ONEPLUS ULTRASOUND LAB

SUPINE
PRETEST

ST @ 10mm/mV
80ms PostJ

Ms. MEENU YADAV
I.D. : 992
AGE/SEX : 32/F
RECORDED : 12-3-2022 11:15
RATE : 91 BPM
B.P. : 108/74 mmHg

RAW E.C.G.



ONEPLUS ULTRASOUND LAB
47, Harsh Vihar, Pitam Pura,
Delhi-110034
Ph. 011-42480101, 9599913051
E-mail: oneplusul@gmail.com

100

100

100

ONEPLUS ULTRASOUND LAB

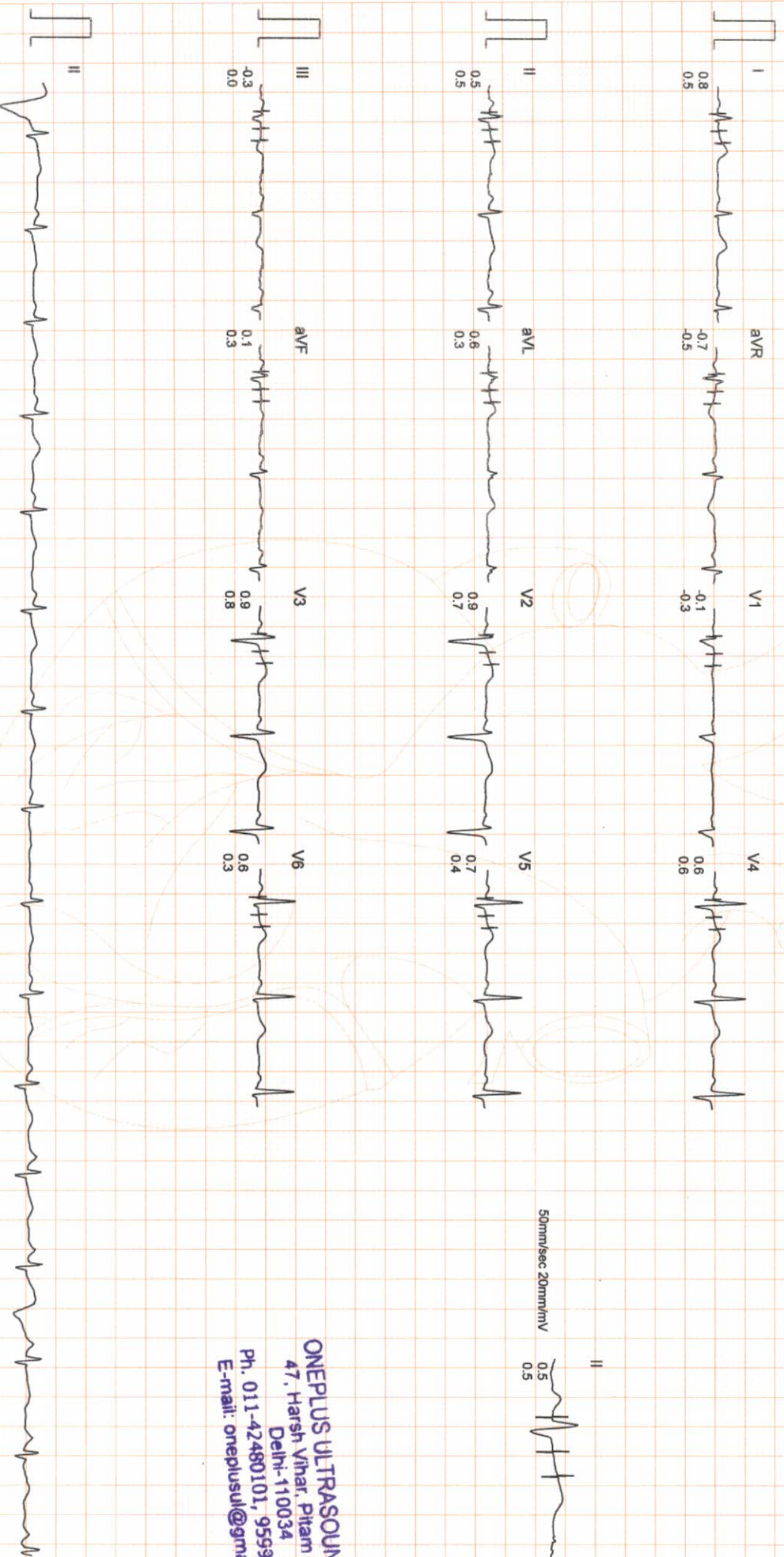
STANDING
PRETEST

ST @ 10mm/mV
80ms PostJ

Ms. MEENU YADAV
I.D. : 992
AGE/SEX : 32/F
RECORDED : 12-3-2022 11:15

RATE : 95 BPM
B.P. : 108/74 mmHg

LINKED MEDIAN



ONEPLUS ULTRASOUND LAB
47, Harsh Vihar, Pitam Pura,
Delhi-110034
Ph. 011-42480101, 9599913051
E-mail: oneplusul@gmail.com

Filtered Computer Corrected Baseline

25mm/sec 10mm/mV

ARCW

CardiCom, INDIA Ph.:091-731-2620740, TeleFax:091-731-2431214

ONEPLUS ULTRASOUND LAB

MS. MEENU YADAV

ID : 992

AGE/SEX : 32/F

RECORDED : 12-3-2022 11:15

RATE : 117 BPM

B.P. : 120/78 mmHg

BRUCE

EXERCISE 1

PHASE TIME : 2:59

STAGE TIME : 2:59

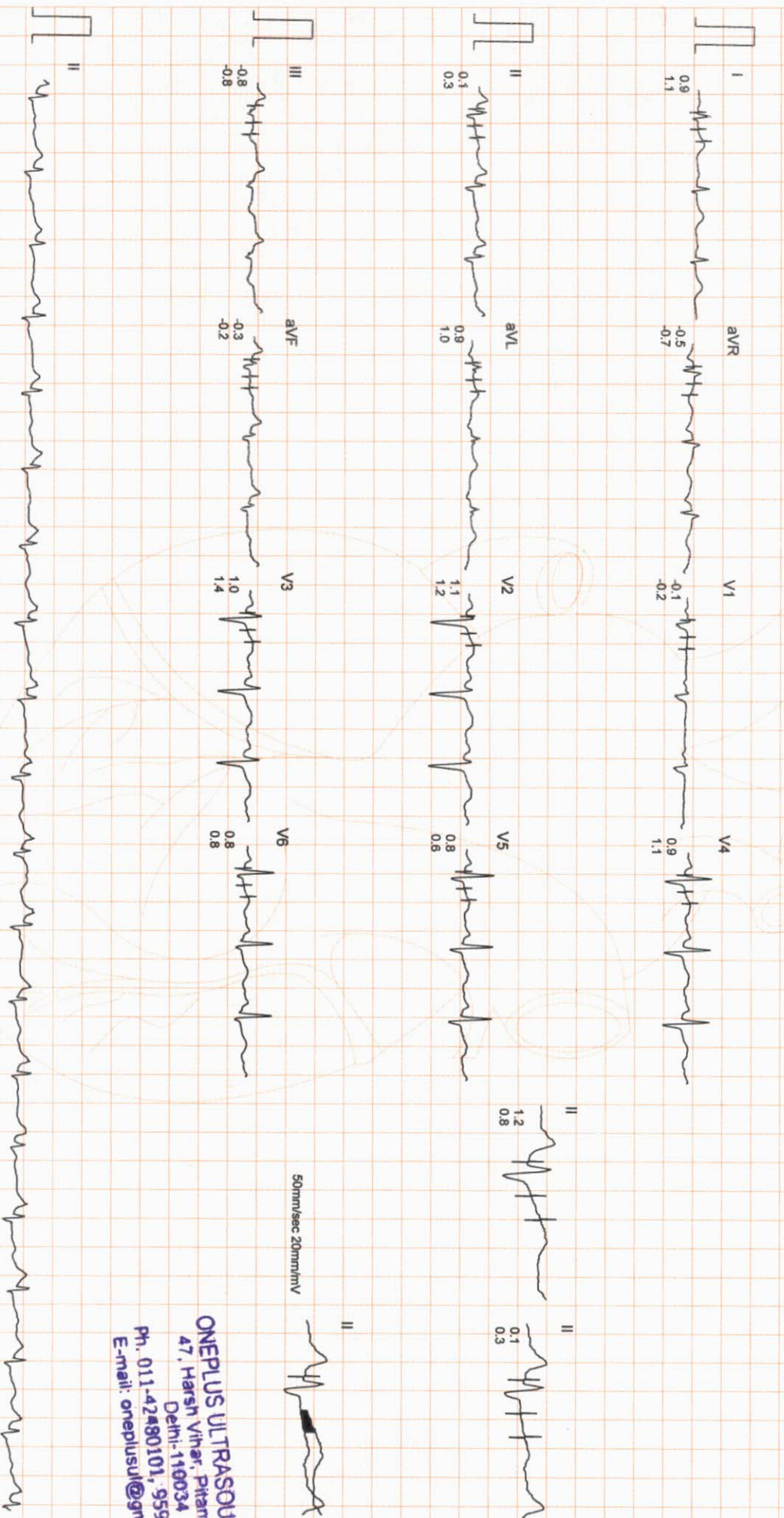
ST @ 10mm/mV

80ms PostJ

SPEED : 2.7 Km./Hr.

GRADE : 10.0 %

LINKED MEDIAN



Filtered Computer-Corrected Baseline

25mm/sec 10mm/mV

ART.M.V.

CardiCom, INDIA Ph.:091-731-2620740, TeleFax:091-731-2431214

ONEPLUS ULTRASOUND LAB
 47, Harsh Vihar, Pitam Pura,
 Delhi-110034
 Ph. 011-42480101, 9599913051
 E-mail: oneplusul@gmail.com



ONEPLUS ULTRASOUND LAB

Ms. MEENU YADAV

ID : 992

AGE/SEX : 32/F

RECORDED : 12-3-2022 11:15

RATE : 136 BPM

B.P. : 130/82 mmHg

BRUCE

EXERCISE 2

PHASE TIME : 5:59

STAGE TIME : 2:59

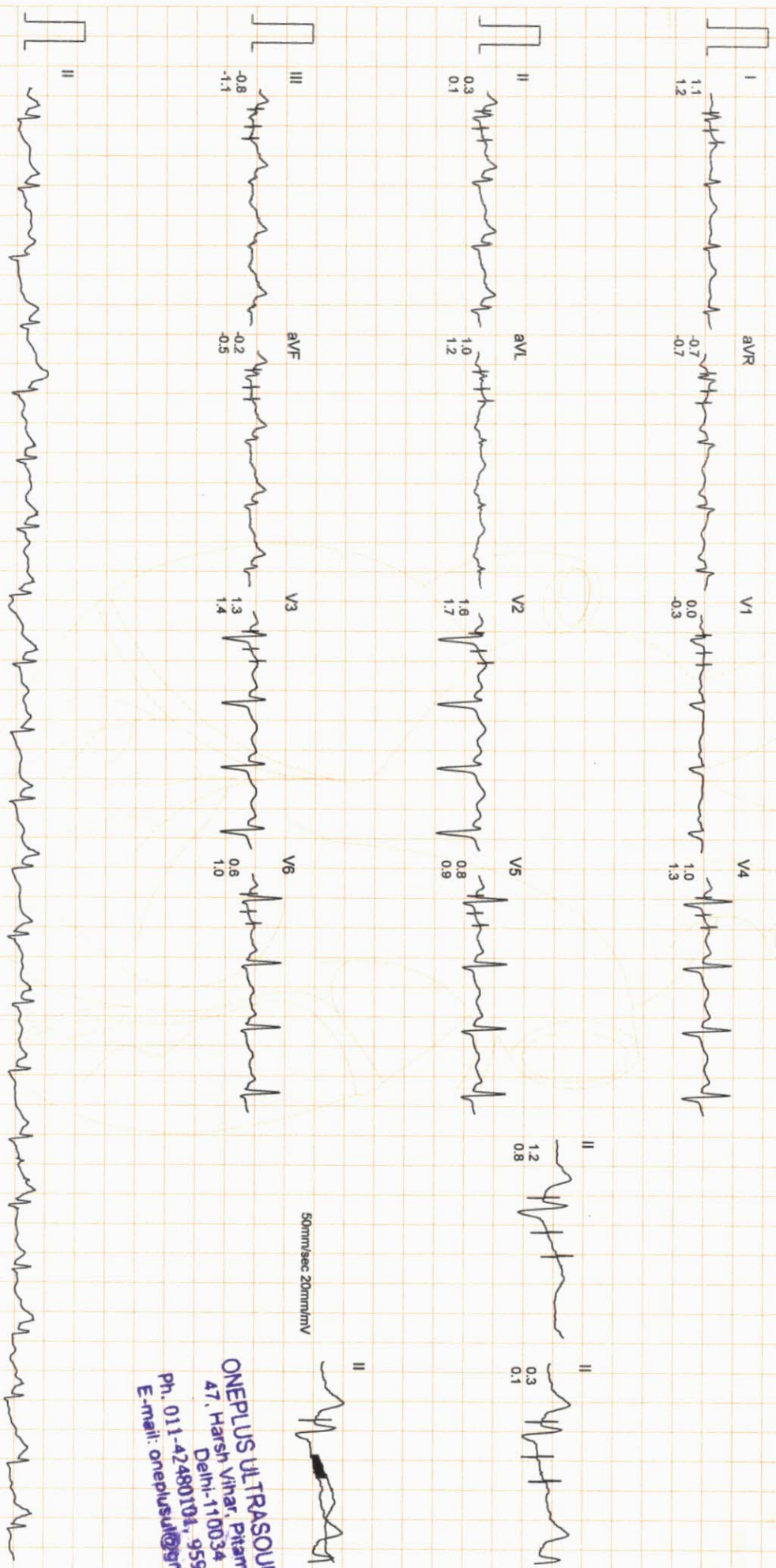
ST @ 10mm/mV

80ms PostI

SPEED : 4.0 Km/Hr.

GRADE : 12.0 %

LINKED MEDIAN



Filtered Computer Corrected Baseline

25mm/sec 10mm/mV

Accu-MV

CardiCom, INDIA Ph.:091-731-2620740, TeleFax:091-731-2431214

ONEPLUS ULTRASOUND LAB
47, Harsh Vihar, Pitam Pura,
Delhi-110034
Ph. 011-42480101, 9559913051
E-mail: onepiusul@gmail.com



ONEPLUS ULTRASOUND LAB

Ms. MEENU YADAV

I.D. : 992

AGE/SEX : 32/F

RECORDED : 12-3-2022 11:15

RATE : 148 BPM

B.P. : 140/86 mmHg

BRUCE

EXERCISE 3

PHASE TIME : 8:59

STAGE TIME : 2:59

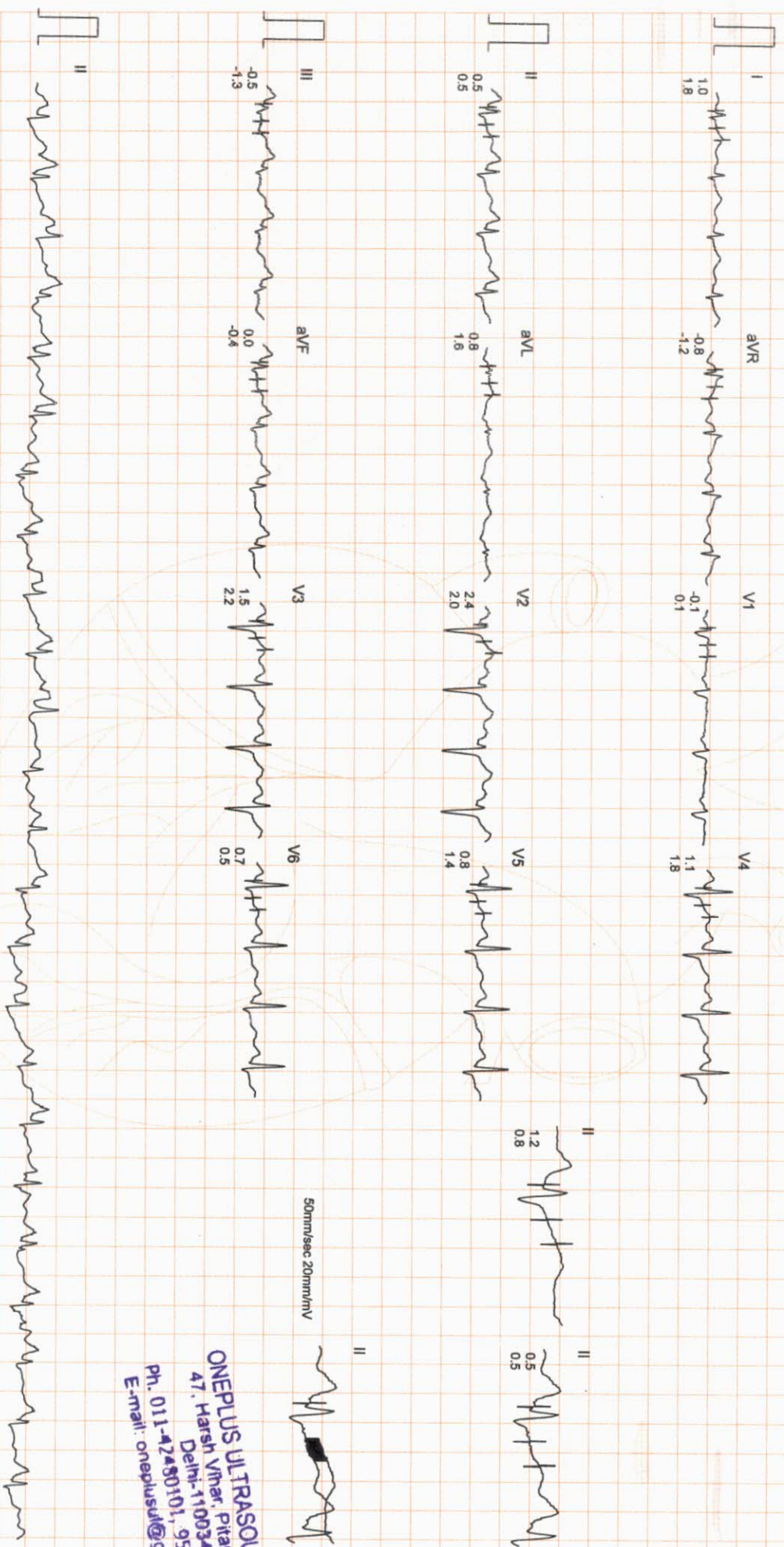
ST @ 10mm/mV

80ms PostI

SPEED : 5.4 Km./Hr.

GRADE : 14.0 %

LINKED MEDIAN



Filtered Computer Corrected Baseline

25mm/sec 10mm/mV

ASAP

CardiCom, INDIA Ph.:091-731-2620740, TeleFax:091-731-2431214

ONEPLUS ULTRASOUND LAB
47, Harsh Vihar, Pitam Pura,
Delhi-110034
Ph. 011-42480101, 9599913051
E-mail: oneplusul@gmail.com



Ms. MEENU YADAV

ID : 992

AGE/SEX : 32/F

RECORDED : 12-3-2022 11:15

RATE : 188 BPM

B.P. : 150/90 mmHg

ONEPLUS ULTRASOUND LAB

BRUCE

EXERCISE 4

PHASE TIME : 9:59

STAGE TIME : 0:59

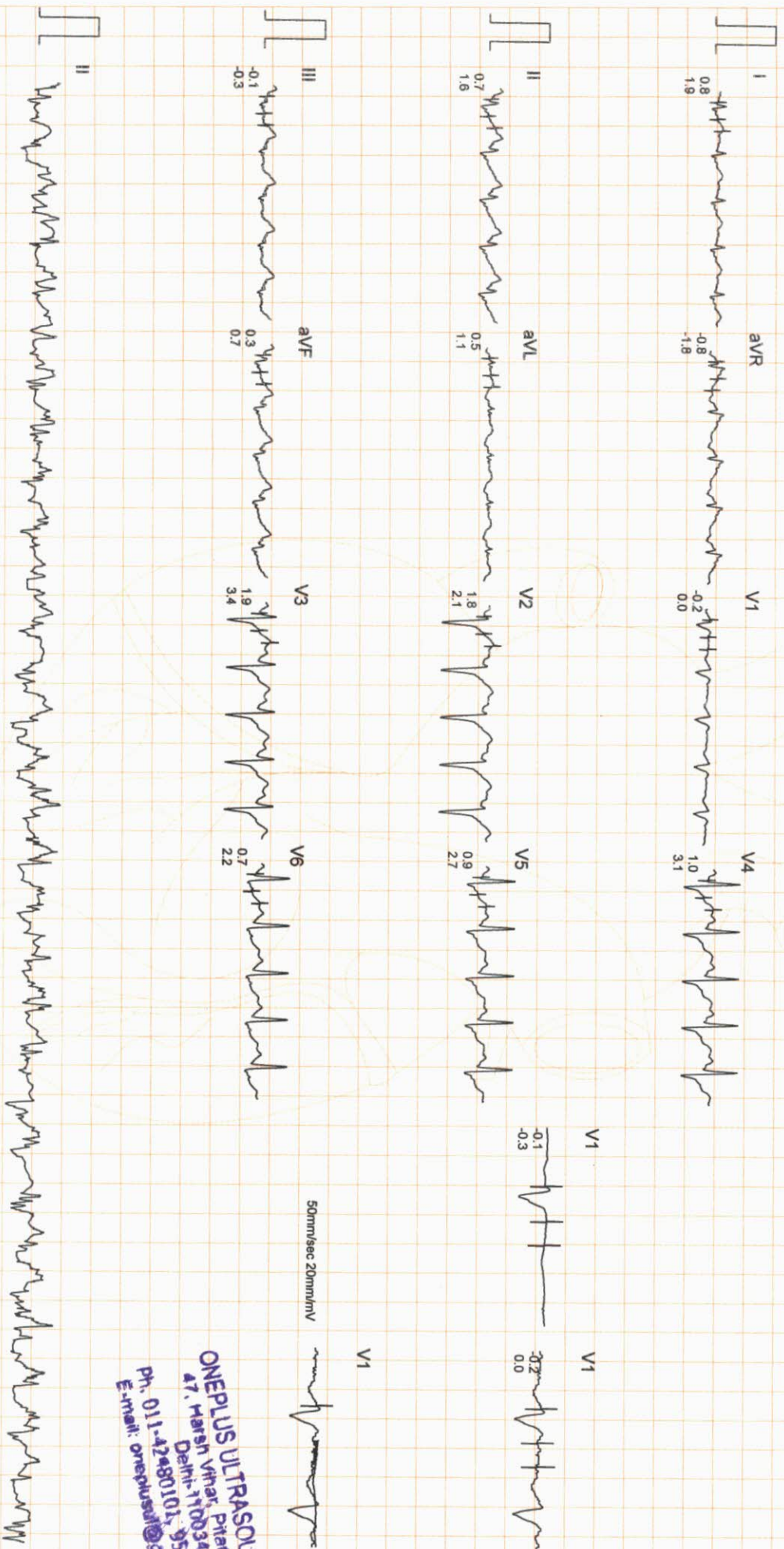
ST @ 10mm/mV

80ms PostJ

SPEED : 6.7 Km./Hr.

GRADE : 16.0 %

LINKED MEDIAN



ONEPLUS ULTRASOUND LAB
 47, Harsh Vihar, Pitam Pura,
 Delhi-110034
 Ph. 011-42480101, 9599913051
 E-mail: onepusul@oneplus.com

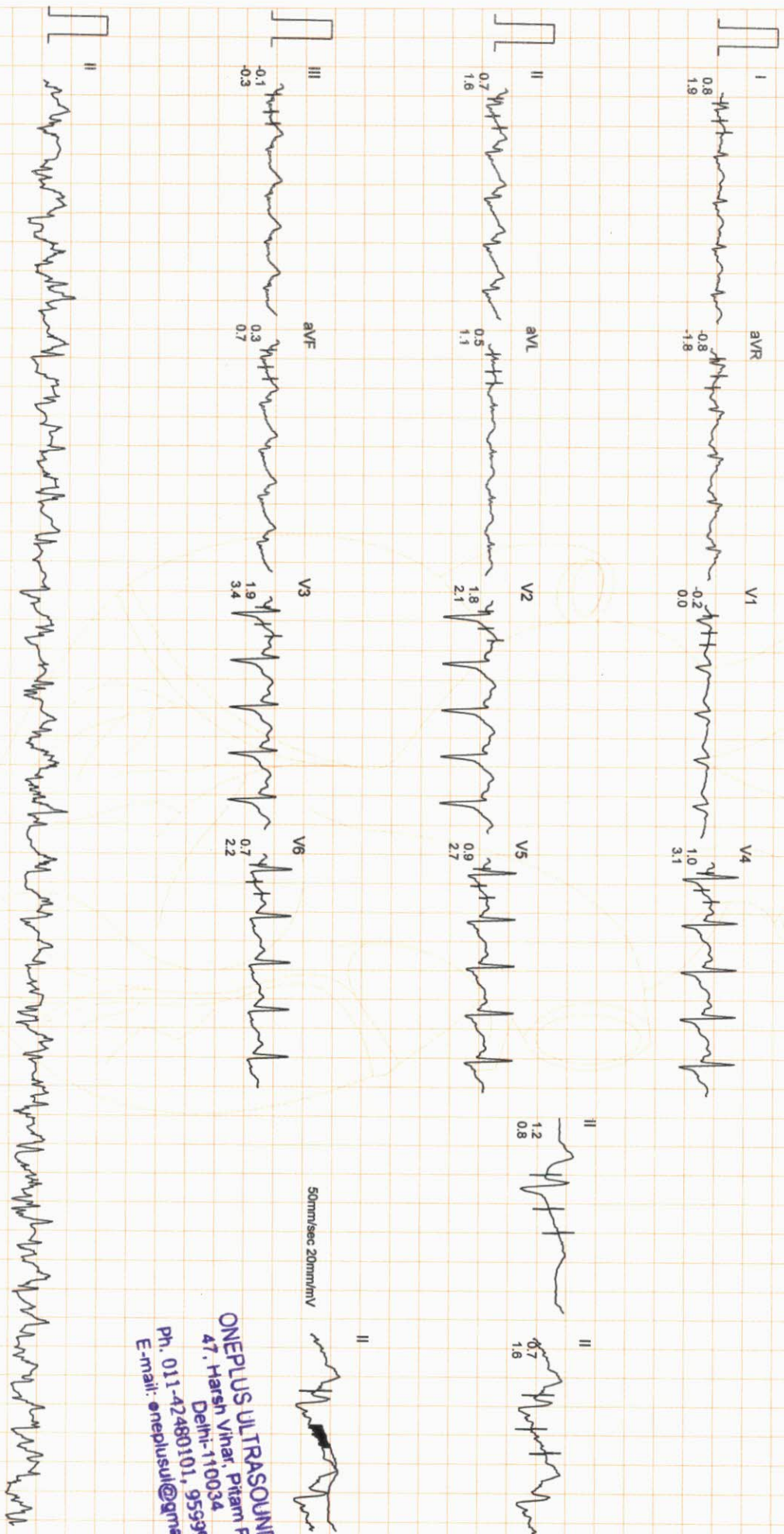
ONEPLUS ULTRASOUND LAB

Ms. MEENU YADAV
 I.D. : 992
 AGE/SEX : 32/F
 RECORDED : 12-3-2022 11:15

RATE : 189 BPM
 B.P. : 150/90 mmHg

BRUCE
 PEAK EXER
 PHASE TIME : 10:01
 STAGE TIME : 1:01

ST @ 10mm/mV
 80ms PostJ
 SPEED : 6.7 Km./Hr.
 GRADE : 16.0 %
 LINKED MEDIAN



ONEPLUS ULTRASOUND LAB
 47, Harsh Vihar, Pitam Pura,
 Delhi-110034
 Ph. 011-42480101, 9599913051
 E-mail: oneplusul@gmail.com

100

100

Ms. MEENU YADAV

ID : 992

AGE/SEX : 32/F

RECORDED : 12-3-2022 11:15

RATE : 105 BPM

B.P. : 110/74 mmHg

ONEPLUS ULTRASOUND LAB

BRUCE

RECOVERY

PHASE TIME : 2:59

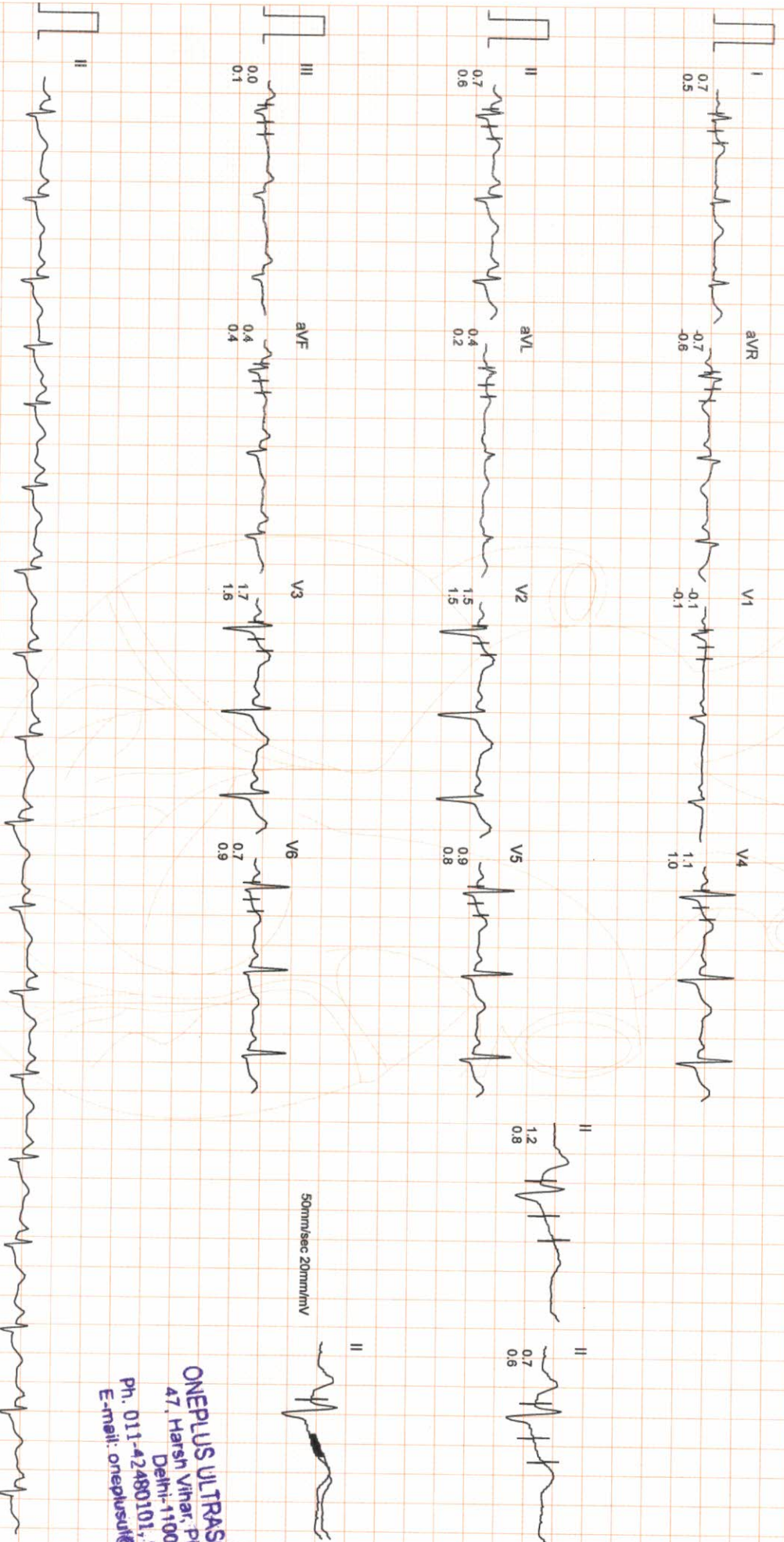
ST @ 10mm/mV

80ms PostJ

SPEED : 0.0 Km./Hr.

GRADE : 0.0 %


LINKED MEDIAN



ONEPLUS ULTRASOUND LAB
 47, Harsh Vihar, Pitam Pura,
 Delhi-110034
 Ph. 011-42480101, 9599913951
 E-mail: oneplusul@oneplusul.com



ONEPLUS ULTRASOUND LAB



ONEPLUS ULTRASOUND LAB
 47, Harsh Vihar, Pitam Pura,
 Delhi-110034
 Ph. 011-42480101, 9559513051
 E-mail: onepusul@gmail.com



OnePLUS Ultrasound Lab

— QUALITY FIRST... ALWAYS! —

Dr. Nitin Agarwal
Pathologist & Director
Ex. Sr. Res. MAMC
& Lok Nayak Hospital
Ex. Chief of Lab Dr. Lal Path Labs.

Dr. Pooja (Garg) Agarwal
Radiologist & Director
MAMC & Lok Nayak Hospital



NAME	:Mrs. MEENU YADAV	Barcode No	:10115132
AGE/GENDER	:32 YRS/Female	SPECIMEN DATE	:12/Mar/2022 08:55AM
PATIENT ID	:92425	SPECIMEN RECEIVED	:12/Mar/2022 09:59AM
REFERRED BY	:Dr. MEDIWHEEL	REPORT DATE	:12/Mar/2022 04:33PM
CENTRE NAME	:ONEPLUS ULTRASOUND LAB	LAB NO.	:012203120005

Test Name	Result	Unit	Ref. Range
-----------	--------	------	------------

HAEMATOLOGY

Health checkup 2 Female

Glycosylated Hemoglobin (HbA1c)	4.5	%	Non Diabetic adults <5.7 Prediabetic (at risk) 5.7-6.4 Diabetes >6.4
--	-----	---	--

Estimated average blood glucose (eag)	82
--	----

Reference range (mg/dl):

90 - 120:Excellent control, 121 - 150:Good Control, 151 - 180:Average Control, 181 - 210:Action Suggested

>211:Panic value

BLOOD GROUP (ABO)	B
Rh typing	POSITIVE

NOTE :

- * Apart from major A,B,H antigens which are used for ABO grouping and Rh typing, many minor blood group antigens exist. Agglutination may also vary according to titre of antigen and antibody.
- * So before transfusion, reconfirmation of blood group as well as cross-matching is needed.
- * Presence of maternal antibodies in newborns, may interfere with blood grouping.
- * Auto agglutination (due to cold antibody, falciparum malaria, sepsis, internal malignancy etc.) may also cause erroneous result.

CBC

Haemoglobin	12.3	g/dl	11.5-15.0
Total Leucocyte Count	4710	/cumm	4000-10000
Differential leucocyte count			
Neutrophils	55.1	%	40-80
Lymphocyte	37.00	%	20-40
Monocytes	4.80	%	2-10
Eosinophils	2.4	%	1-6
Basophils	0.7	%	0-2
RBC Count	4.51	million/cumm	3.8-4.8

Checked By.

DR. NITIN AGARWAL
MBBS MD (PATHOLOGIST)

Dr. NITIN AGARWAL
MBBS, MD (Path)
DMC/R/01436

47, Harsh Vihar, Pitampura, New Delhi-110034 | Ph.: 011-42480101, 9599913051
E-mail: oneplusul@gmail.com | Web.: www.oneplusul.in

Page 1 of 5



OnePLUS Ultrasound Lab

— QUALITY FIRST... ALWAYS! —

Dr. Nitin Agarwal
Pathologist & Director
Ex. Sr. Res. MAMC
& Lok Nayak Hospital
Ex. Chief of Lab Dr. Lal Path Labs.

Dr. Pooja (Garg) Agarwal
Radiologist & Director
MAMC & Lok Nayak Hospital



NAME	:Mrs. MEENU YADAV	Barcode No	:10115132
AGE/GENDER	:32 YRS/Female	SPECIMEN DATE	:12/Mar/2022 08:55AM
PATIENT ID	:92425	SPECIMEN RECEIVED	:12/Mar/2022 09:59AM
REFERRED BY	:Dr. MEDIWHEEL	REPORT DATE	:12/Mar/2022 04:33PM
CENTRE NAME	:ONEPLUS ULTRASOUND LAB	LAB NO.	:012203120005

Test Name	Result	Unit	Ref. Range
PCV(Hematocrit)	38.2	%	36-46
MCV	84.7	fL	83-101
MCH	27.3	Pg	27-32
MCHC	32.3	G/dL	32-35
Platelet count	232000	/cumm	150000-450000
RDW-CV	13.8	%	11.4-14.0
ESR(WESTEGRENs METHOD)	05	mm/1hr	<20

BIOCHEMISTRY

<u>Blood sugar fasting</u>	82	mg/dL	70-110
<u>Bun (blood urea nitrogen)</u>	13.20	mg/dl	7-18.7
<u>Uric acid, serum</u>	4.6	mg/dl	2.4-5.7
<u>Creatinine, serum</u>	0.55	mg/dl	0.50-0.9

LFT(LIVER FUNCTION TEST)

Bilirubin Total	0.74	mg/dl	0.1-1.2
Bilirubin Conjugated	0.36	mg/dl	0-0.4
Bilirubin Unconjugated	0.38	mg/dl	up to 0.7
SGOT (AST)	31	U/L	0-31
SGPT (ALT)	26	U/L	<34
Alkaline phosphatase	92	U/L	35-104
Gamma glutamyl transpeptidase	24	U/L	<39
Total Protein	7.2	gm/dl	6.60 - 8.70
Albumin	4.0	g/dL	3.8-5.1
Globulin	3.20	gm/dl	1.8-3.4
Albumin/Globulin Ratio	1.25		1.10 - 2.50

LIPID PROFILE

Cholesterol	182	mg/dl	50-200
Triglycerides	58	mg/dL	25-150
HDL Cholesterol	38	mg/dL	30 - 70

Checked By.

DR. NITIN AGARWAL
MBBS,MD(PATHOLOGIST)

47, Harsh Vihar, Pitampura, New Delhi-110034 | Ph.: 011-42480101, 059991051
E-mail: oneplusul@gmail.com | Web.: www.oneplusul.com | 011-424801436

Page 2 of 5

Clinical correlation is essential for final diagnosis. • If test results are unsatisfactory please contact personally or on phone. • This report is for perusal of doctors only.
• All disputes Subject to Delhi Jurisdiction only. • Not for medicolegal purposes. • All congenital anomalies in a foetus may not be diagnosed in routine obstetric ultrasound.



OnePLUS Ultrasound Lab

— QUALITY FIRST... ALWAYS! —

Dr. Nitin Agarwal
Pathologist & Director
Ex. Sr. Res. MAMC
& Lok Nayak Hospital
Ex. Chief of Lab Dr. Lal Path Labs.

Dr. Pooja (Garg) Agarwal
Radiologist & Director
MAMC & Lok Nayak Hospital



NAME	:Mrs. MEENU YADAV	Barcode No	:10115132
AGE/GENDER	:32 YRS/Female	SPECIMEN DATE	:12/Mar/2022 08:55AM
PATIENT ID	:92425	SPECIMEN RECEIVED	:12/Mar/2022 09:59AM
REFERRED BY	:Dr. MEDIWHEEL	REPORT DATE	:12/Mar/2022 04:33PM
CENTRE NAME	:ONEPLUS ULTRASOUND LAB	LAB NO.	:012203120005

Test Name	Result	Unit	Ref. Range
LDL cholesterol	132	mg/dL	< 130
VLDL cholesterol	11.6	mg/dL	5-40
Cholesterol/HDL Ratio	4.8		Low Risk 3.3-4.97 Average Risk 4.4-7.1 Moderate Risk 7.1-11.0 High Risk >11.0
LDL/HDL Ratio	3.5		0 - 3.55

According to ATP III and NCEP guidelines

Parameter	Normal	Desirable	Borderline	High
Total cholesterol	<200	200-239		240
Triglycerides	<150	150-199	200-499	500
LDL	Optimal <100 Near Optimal 100-129	130-159	160-180	190
HDL	<40 : LOW 60 : HIGH			

ENDOCRINOLOGY

THYROID PROFILE(T3,T4,TSH)

Triiodothyronine total [t3]	0.72	ng/dl	0.52-1.9
Thyroxine total [t4]	8.20	µg/dl	4.8-11.6
TSH (Thyroid Stimulating Hormone)	2.10	µIU/ml	0.25-5.0

AGE WISE VARIATION IN TSH

AGE	TSH(µIU/ml)	AGE	TSH(µIU/ml)
1-4 weeks	1.00 - 19.0	16-20 yrs	0.25 - 5.0
1-12 mths	1.70 - 9.1	21 - 80 yrs	0.25 - 5.0
1-5 yrs	0.80 - 8.2	I st trimester	0.25 - 5.0
6-10 yrs	0.25 - 5.0	II nd trimester	0.50 - 5.0
11-15 yrs	0.25 - 5.0	II rd trimester	0.4 - 6.0

Checked By.

DR. NITIN AGARWAL
MBBS,MD(PATHOLOGIST)

Dr NITIN AGARWAL

47, Harsh Vihar, Pitampura, New Delhi-110034 | Ph.: 011-42480101, 9599913051

E-mail: oneplusul@gmail.com | Web.: www.oneplusul.in

Page 3 of 5



OnePLUS Ultrasound Lab

— QUALITY FIRST... ALWAYS! —

Dr. Nitin Agarwal

Pathologist & Director
Ex. Sr. Res. MAMC
& Lok Nayak Hospital
Ex. Chief of Lab Dr. Lal Path Labs.

Dr. Pooja (Garg) Agarwal

Radiologist & Director
MAMC & Lok Nayak Hospital



NAME	:Mrs. MEENU YADAV	Barcode No	:10115132
AGE/GENDER	:32 YRS/Female	SPECIMEN DATE	:12/Mar/2022 08:55AM
PATIENT ID	:92425	SPECIMEN RECEIVED	:12/Mar/2022 09:59AM
REFERRED BY	:Dr. MEDIWHEEL	REPORT DATE	:12/Mar/2022 04:33PM
CENTRE NAME	:ONEPLUS ULTRASOUND LAB	LAB NO.	:012203120005

Test Name	Result	Unit	Ref. Range
-----------	--------	------	------------

Reference ranges - Interpretation of Diagnostic tests - (Jacques Wallach)

1. Primary hypothyroidism is accompanied by depressed serum T3 and T4 values and elevated serum TSH level.
2. Primary hyperthyroidism is accompanied by elevated serum T3 and T4 levels along with depressed TSH values.
3. Slightly elevated T3 levels may be found in pregnancy and estrogen therapy, while depressed levels may be encountered in severe illness, renal failure and during therapy with drugs like propranolol and propyl thiouracil.
4. Although elevated TSH levels are nearly always indicative of primary hypothyroidism, and may be seen in secondary thyrotoxicosis

Checked By.

DR. NITIN AGARWAL

MBBS, MD (PATHOLOGIST)

Dr NITIN AGARWAL

MBBS, MD (Path)

DMC/R/01436

47, Harsh Vihar, Pitampura, New Delhi-110034 | Ph.: 011-42480101, 9592963051

E-mail: oneplusul@gmail.com | Web.: www.oneplusul.in

Page 4 of 5

Clinical correlation is essential for final diagnosis. • If test results are unsatisfactory please contact personally or on phone. • This report is for perusal of doctors only.
• All disputes Subject to Delhi Jurisdiction only. • Not for medicolegal purposes. • All congenital anomalies in a foetus may not be diagnosed in routine obstetric ultrasound.



OnePLUS Ultrasound Lab

— QUALITY FIRST... ALWAYS! —

Dr. Nitin Agarwal

Pathologist & Director
Ex. Sr. Res. MAMC
& Lok Nayak Hospital
Ex. Chief of Lab Dr. Lal Path Labs.

Dr. Pooja (Garg) Agarwal

Radiologist & Director
MAMC & Lok Nayak Hospital



NAME	:Mrs. MEENU YADAV	Barcode No	:10115132
AGE/GENDER	:32 YRS/Female	SPECIMEN DATE	:12/Mar/2022 08:55AM
PATIENT ID	:92425	SPECIMEN RECEIVED	:12/Mar/2022 09:59AM
REFERRED BY	:Dr. MEDIWHEEL	REPORT DATE	:12/Mar/2022 02:01PM
CENTRE NAME	:ONEPLUS ULTRASOUND LAB	LAB NO.	:012203120005

Test Name	Result	Unit	Ref. Range
-----------	--------	------	------------

CLINICAL PATHOLOGY

URINE ROUTINE

Physical examination

Quantity	20		ML
Colour	PALE YELLOW		
Transparency	SLIGHTLY TURBID		CLEAR
Sp.gravity	1.020		1.010-1.030
pH	6.00		
Reaction	ACIDIC		ACIDIC

Chemical examination

Urine protein	NIL		NIL
Urine sugar	NIL		NIL
Bilirubin, urine	NEGATIVE		NEGATIVE
Urobilinogen	NORMAL		NORMAL
Ketones	NEGATIVE		NEGATIVE

Microscopic examination

Pus cells.	2-3	/HPF	1-2
Epithelial cells	25-30	/HPF	0-5
R.B.C.	NIL	/HPF	NIL
Casts	NIL	/HPF	NIL
Crystals	NIL	/HPF	NIL
Bacteria	NIL	/HPF	NIL
Others.	NIL		NIL

*** End Of Report ***

Checked By.

Dr. NITIN AGARWAL DR. NITIN AGARWAL
M.B.B.S., MD (Path) MBBS, MD (PATHOLOGIST)

47, Harsh Vihar, Pitampura, New Delhi-110034 | Ph.: 011-42480101, 9599913051

E-mail: oneplusul@gmail.com | Web.: www.oneplusul.in

Page 5 of 5

Clinical correlation is essential for final diagnosis. • If test results are unsatisfactory please contact personally or on phone. • This report is for perusal of doctors only. • All disputes Subject to Delhi Jurisdiction only. • Not for medicolegal purposes. • All congenital anomalies in a foetus may not be diagnosed in routine obstetric ultrasound.



OnePLUS
Ultrasound Lab
— QUALITY FIRST... ALWAYS! —

Dr. Nitin Agarwal
Pathologist & Director
Ex. Sr. Res. MAMC
& Lok Nayak Hospital
Ex. Chief of Lab Dr. Lal Path Labs.

Dr. Pooja (Garg) Agarwal
Radiologist & Director
MAMC & Lok Nayak Hospital

Name	: Mrs. MEENU YADAV	Age/Sex	: 32 YRS/Female
Ref. By	: Dr. MEDIWHEEL	Lab No	: 012203120005
Date	: 12-Mar-2022	Patient ID	: LSHHI92425

ULTRASOUND EXAMINATION----WHOLE ABDOMEN

Liver is normal in size and outline with normal echopattern. Intrahepatic biliary radicles are not dilated. No abscess or mass lesion seen. Hepatic veins, portal vein, IVC and aorta are normal. CBD is normal in caliber.

Gall bladder is well distended with anechoic lumen. Wall thickness is normal.

Both kidneys are normal in size, shape, position, outline and echopattern. Corticomedullary differentiation is maintained. No pelvicalyceal dilation or mass lesion is seen.

Spleen is normal in size and echotexture. No mass lesion seen.

Pancreas is normal in size, outline and echotexture.

Urinary bladder is normal in shape and position. No evidence of intravesical stone or mass seen.


Uterus is normal in size (measures 8.5 x 3.6 x 3.6 cm), shape, position and echopattern. No mass seen. Uterine cavity is empty. Endometrial thickness is 6.7 mm

Both ovaries appear normal in size, shape and echopattern. No tubo-ovarian mass seen.

No abnormal bowel wall thickening seen in right iliac fossa.
No free fluid seen anywhere in abdomen.

IMPRESSION:

- Normal study.

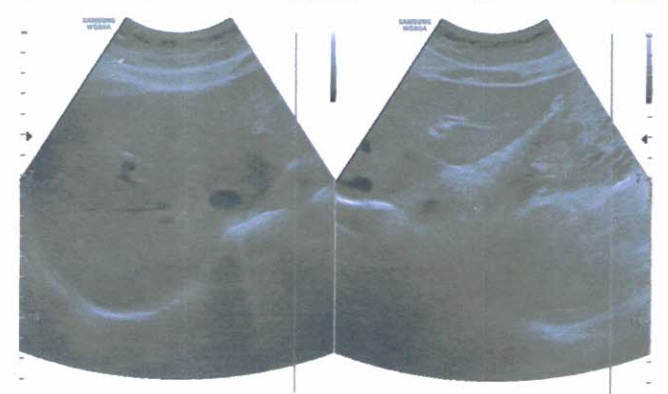

DR. POOJA GARG
RADIOLOGIST
REG NO- DMC/R/03398
Dr. POOJA GARG
M.B.B.S., D.M.R.D
Reg No. DMC/R/03398
Radiologist

Type By : pooja

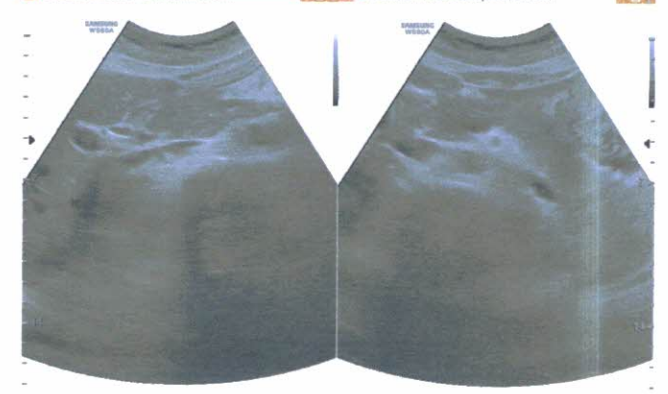47, Harsh Vihar, Pitampura, New Delhi-110034 | Ph.: 011-42480101, 9599913051
E-mail: oneplusul@gmail.com | Web.: www.oneplusul.in

Clinical correlation is essential for final diagnosis. • If test results are unsatisfactory please contact personally or on phone. • This report is for perusal of doctors only.
• All disputes Subject to Delhi Jurisdiction only. • Not for medicolegal purposes. • All congenital anomalies in a foetus may not be diagnosed in routine obstetric ultrasound.

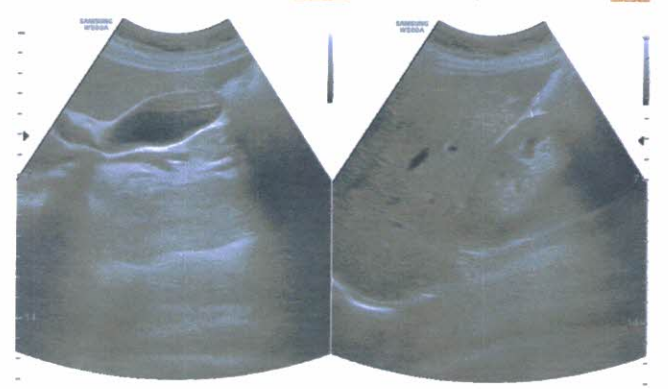
W590A MRS MEENU 32/F OnePlus Ultrasound Lab MI 1.4 12-03-2022
CA1-7A / Abdomen / FR 24Hz Tls 0.1 10:23:42 AM



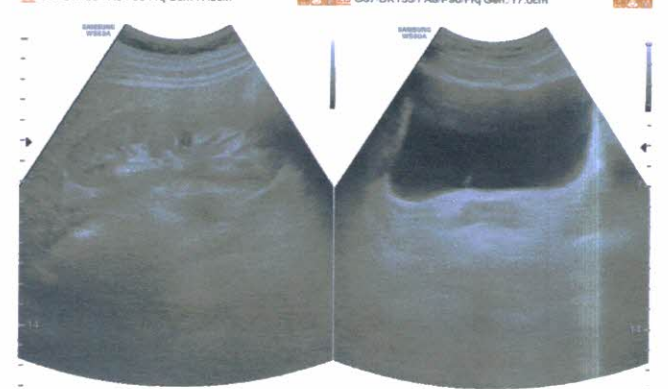
W590A MRS MEENU 32/F OnePlus Ultrasound Lab MI 1.4 12-03-2022
CA1-7A / Abdomen / FR 24Hz Tls 0.1 10:23:47 AM



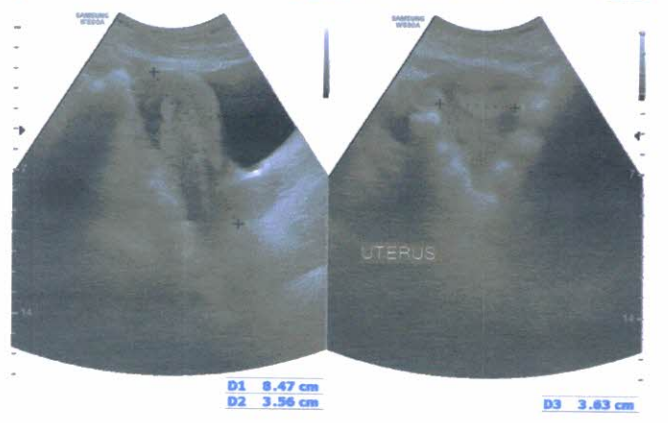
W590A MRS MEENU 32/F OnePlus Ultrasound Lab MI 1.4 12-03-2022
CA1-7A / Abdomen / FR 24Hz Tls 0.1 10:23:58 AM



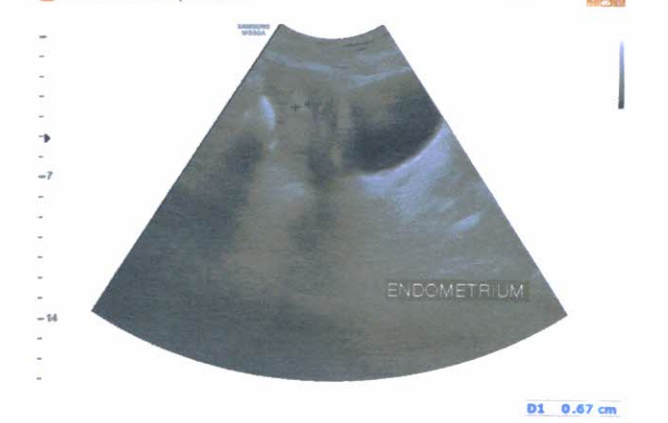W590A MRS MEENU 32/F OnePlus Ultrasound Lab MI 1.4 12-03-2022
CA1-7A / Abdomen / FR 24Hz Tls 0.1 10:24:11 AM



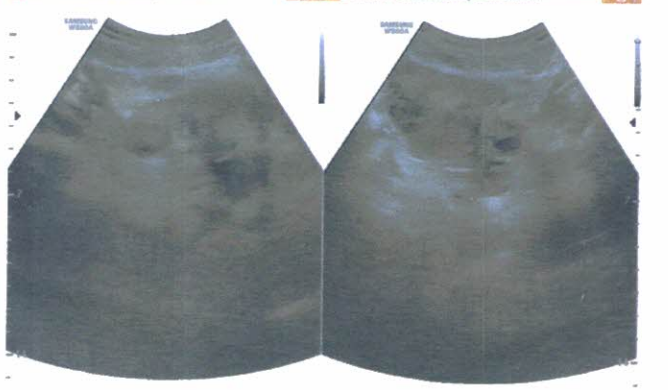W590A MRS MEENU 32/F OnePlus Ultrasound Lab MI 1.4 12-03-2022
CA1-7A / Abdomen / FR 24Hz Tls 0.1 10:24:31 AM



W590A MRS MEENU 32/F OnePlus Ultrasound Lab MI 1.4 12-03-2022
CA1-7A / Abdomen / FR 24Hz Tls 0.1 10:24:40 AM



W590A MRS MEENU 32/F OnePlus Ultrasound Lab MI 1.4 12-03-2022
CA1-7A / Abdomen / FR 24Hz Tls 0.1 10:24:54 AM



W590A MRS MEENU 32/F OnePlus Ultrasound Lab MI 1.4 12-03-2022
CA1-7A / Abdomen / FR 24Hz Tls 0.1 10:25:16 AM

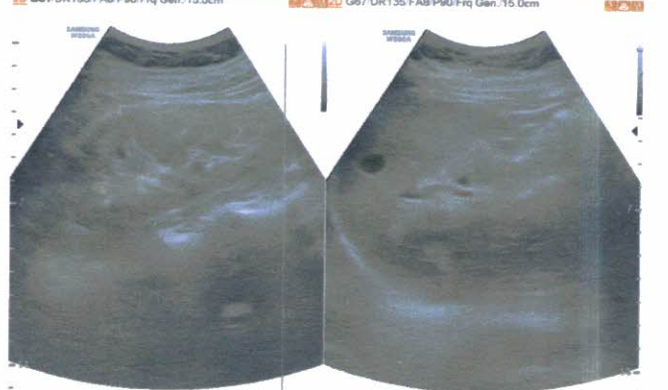




Figure 1: Comparison of two different methods for image enhancement.




Figure 2: Comparison of two different methods for image enhancement, showing a spot.




Figure 3: Comparison of two different methods for image enhancement.



Figure 4: Comparison of two different methods for image enhancement.



Figure 5: Comparison of two different methods for image enhancement.




Figure 6: Comparison of two different methods for image enhancement, showing a spot.



Figure 7: Comparison of two different methods for image enhancement.

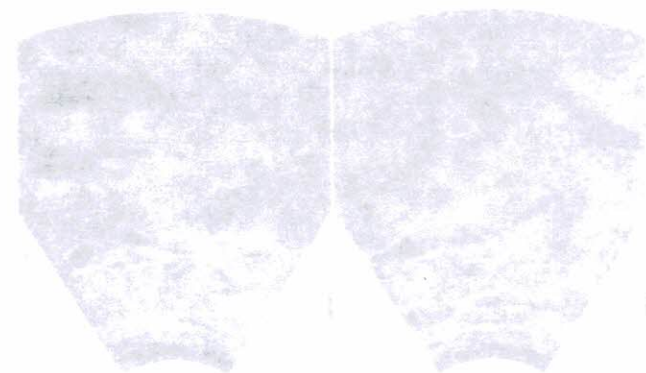

Figure 8: Comparison of two different methods for image enhancement, showing a spot.



OnePLUS
Ultrasound Lab
— QUALITY FIRST... ALWAYS! —

Dr. Nitin Agarwal
Pathologist & Director
Ex. Sr. Res. MAMC
& Lok Nayak Hospital
Ex. Chief of Lab Dr. Lal Path Labs.

Dr. Pooja (Garg) Agarwal
Radiologist & Director
MAMC & Lok Nayak Hospital

Name : Mrs. MEENU YADAV	Age/Sex : 32 YRS/Female
Ref. By : Dr. MEDIWHEEL	Lab No : 012203120005
Date : 12-Mar-2022	Patient ID : LSHHI92425

X-ray-Chest PA view

Bony cage and soft tissues are normal.
Cardiothoracic ratio is normal.
Mediastinum is normal.
Both hila are normal.
Both costophrenic angles are clear.
Both domes of diaphragm are normal.
Lung fields are clear. No parenchymal lesion seen.

IMPRESSION: Normal Study.

DR. POOJA GARG
RADIOLOGIST
REG NO- DMC/R/03398

Dr. POOJA GARG
M.B.B.S., D.M.R.D
Reg No. DMC/R/03398
Radiologist

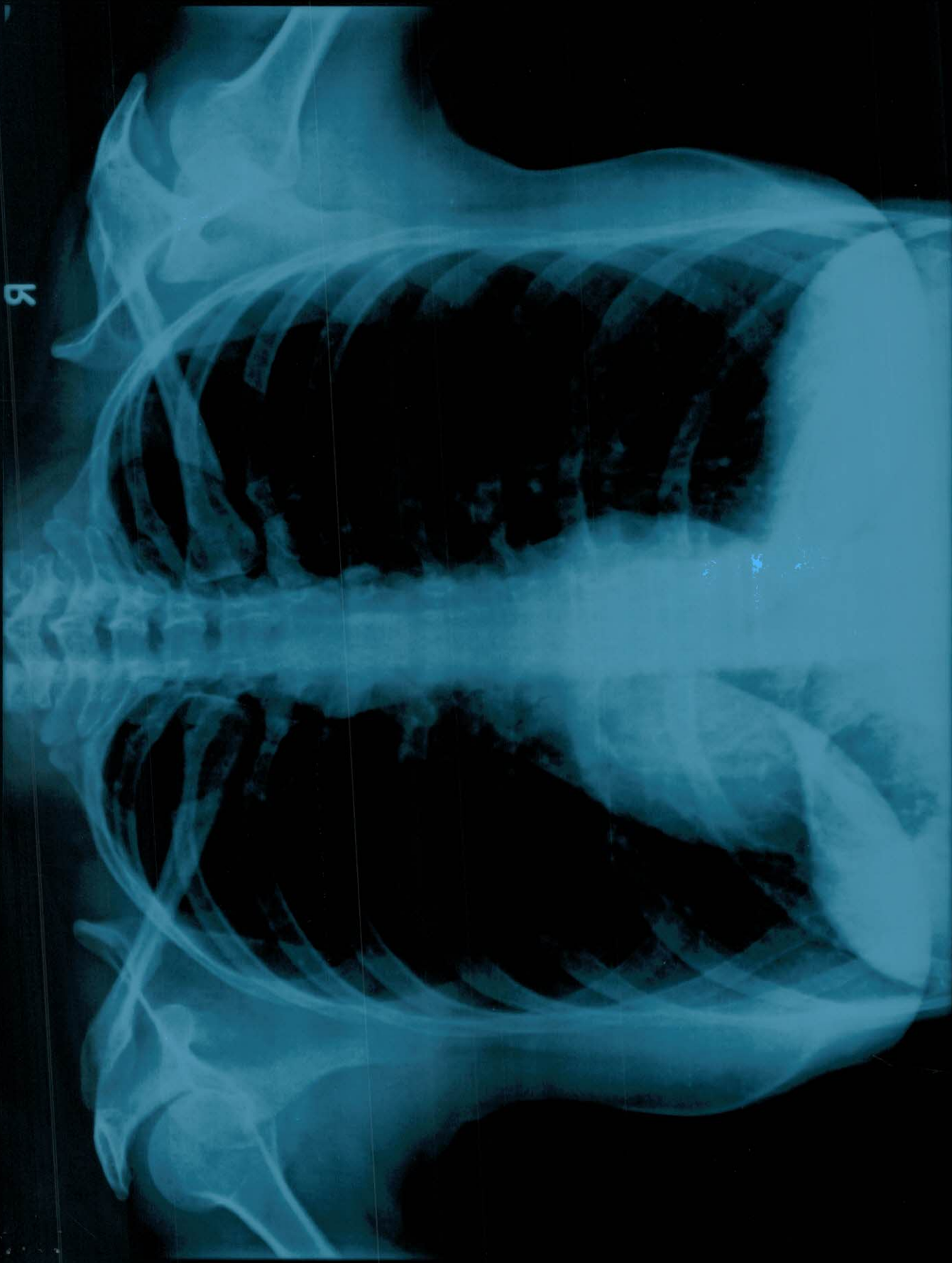
Type By : darshita

47, Harsh Vihar, Pitampura, New Delhi-110034 | Ph.: 011-42480101, 9599913051
E-mail: oneplusul@gmail.com | Web.: www.oneplusul.in

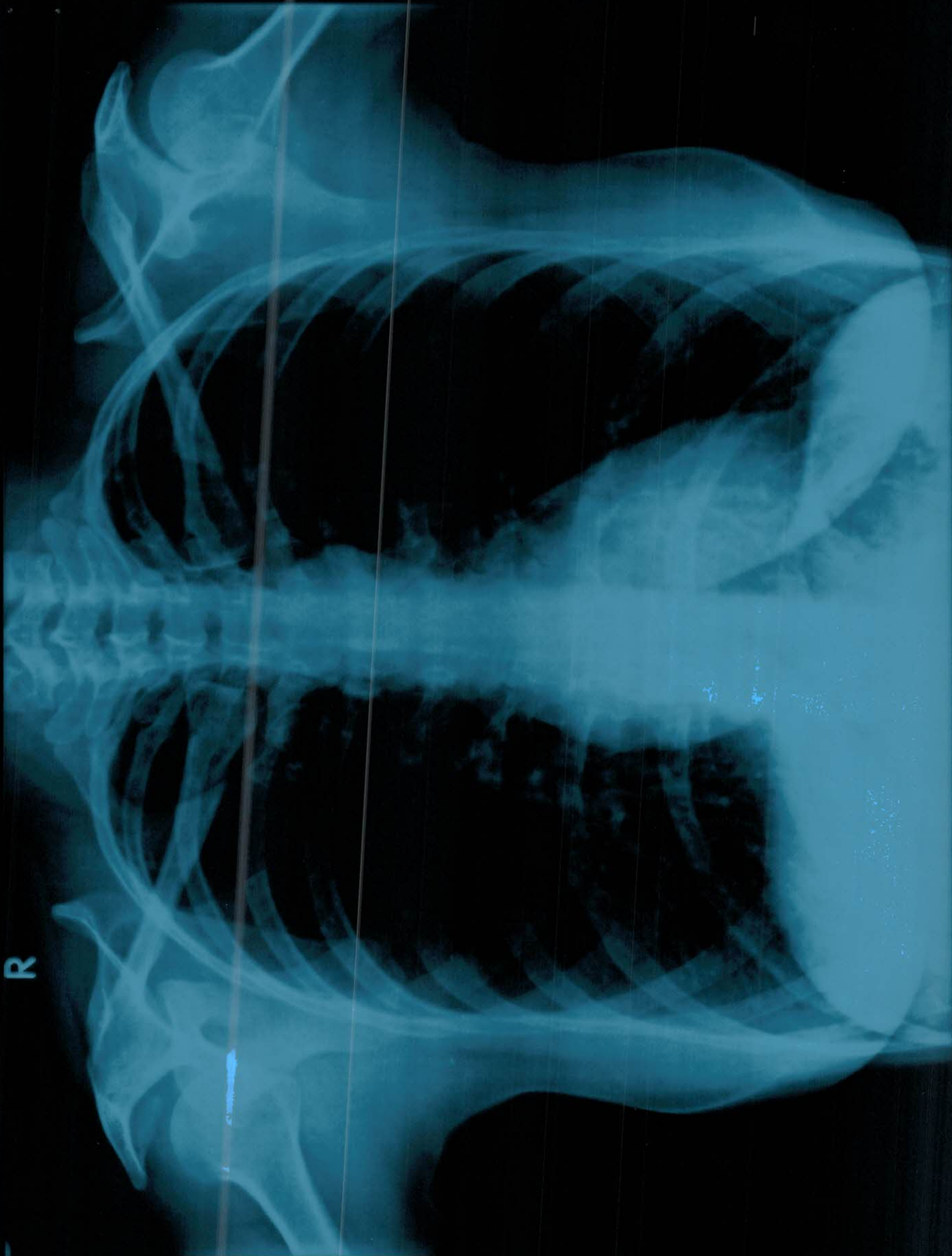
Clinical correlation is essential for final diagnosis. • If test results are unsatisfactory please contact personally or on phone. • This report is for perusal of doctors only.
• All disputes Subject to Delhi Jurisdiction only. • Not for medicolegal purposes. • All congenital anomalies in a foetus may not be diagnosed in routine obstetric ultrasound.

ONEPLUG ULTRASOUND LAB43-HARSH NHAAR,BILAMPUR
MRS. MEENU YADVA 35 YRS 15-03-2022 F CHEST PA VIEW 31/5/2022

R



R



MRS. MEENU YADAV 32 YRS 12-03-2022 F CHEST PA VIEW 3/12/2022

ONEPLUS ULTRASOUND LAB.47-HARSH VIHAR.PITAMPURA