

SARDA

CENTRE FOR DIABETES & SELF CARE

NAME: MR. ABHISHEK PAL

SEX: Male AGE: .

REF. BY : BOB

DATE :11/03/2023

COMPLETE BLOOD COUNT

TEST	RESULT	NORMAL RANGE
WBC COUNT	7400 /cumm	4.0 - 11.0 x 10 ³ /cumm
Haemoglobin:	13.3 g%	13.0 - 18.0 g%
Platelets:	264000 /cumm	1,50,000 - 4,50,000 / cumm
Red Blood Cells:	4.06 /Mill/ul	4.20 - 6.00 Mill/ul
MCV:	97.9 fL	80.0 - 97.0 fL
MCH:	32.7 pg	26.0 - 32.0 pg
MCHC:	33.5 g/dL	31.0 - 36.0 g/dL
HCT:	39.7 %	37.0 - 51.0 %
Differential Count		
Neutrophils:	55 %	40 - 75 %
Lymphocyte:	35 %	20 - 45 %
Monocytes:	04 %	2 - 10 %
Eosinophills:	06 %	1 - 06 %
Basophills:	00 %	0 - 1 %
ESR:	08 mm at 1 Hr.	Male: 0 - 8 mm at 1 Hr. Female: 0 - 20 mm at 1 Hr.

AGE: YRS

BLOOD GROUP

BLOOD GROUP	:	"A"
R.H.FACTOR	:	POSITIVE

Dr.S R. SARDA
M.D Reg. No.56462
SARDA CENTER FOR DIABETES & SELF CARE
Jalna Road, Aurangabad
Dr.Sampat Sarda
M.D.(Pathology)
2333851, 2334858

SARDA

CENTRE FOR DIABETES & SELF CARE

NAME: MR. ABHISHEK PAL

SEX: Male AGE: .

REF. BY : BOB

DATE :11/03/2023

BLOOD SUGAR EXAMINATION

TEST	RESULT
Fasting Blood Sugar:	86 mg/dl
Post Meal Blood Suagr Level:	129 mg/dl

REFERANCE RANGE :	NON DIABETIC	IGT	DIABETIC
FASTING	</=90MG	90-126 mg %	>/=126mg %
POSTMEAL	</=140mg	140-200mg%	>/=200mg

GYCOCYTED HAEMOGLOBIN

TEST	RESULT	NORMAL
HbA1C:	5.4 %	4.7-5.9 %
M.B.G	102.22% mg	70 - 120 mg

INTERPRETATION:

FOR DIABETIC PATIENT

Good Control: 6.0 - 7.0 %

Fair Diabetic Control: 7.0 - 8.0 %

Unsatisfactory control: 8.0 - 10 %

Poor Diabetic Control: Above 10 %

Dr.S R. SARDA
M.D. Reg. No.56462
Dr.Sampat Sarda
M.D.(Pathology)
DIABETES & SELF CARE
Jalna Road, Aurangabad
Phone No.2333851, 2334858

SARDA

CENTRE FOR DIABETES & SELF CARE

NAME: MR. ABHISHEK PÁL

SEX: Male AGE: .

REF. BY : BOB

DATE :11/03/2023

BLOOD PROFILE

TEST	RESULT	NORMAL
BLOOD UREA N2	10 mg%	5-25 mg %
CREATININE	1.0mg%	0.6-1.4 mg %
BILIRUBIN TOTAL	0.79mg%	0.2-1.0 mg
DIRECT	0.24	0.0-0.3
INDIRECT	0.55	0.3-0.7
S.G.O.T	27 IU/L	15-40 IU/L
S.G.P.T	20 IU/L	15-40 IU/L
ALK PHOSPHATASE	104 IU/L	42-128IU/L
S.PROTEIN TOTAL	7.3gm%	6.0-8.0 gm%
ALBUMIN	4.0gm%	3.2-4.4 gm%
GLOBULINS	3.3gm%	2.3-3.5 gm%
ALB/GLO RATIO	1.2	
G.G.T.P	21	upto50IU
SR.URIC ACID	5.3	3.5-7.0 mg % ^{uric-}

Dr. Sampat Sarda
M.D. (Pathology)
Dr. R. SARDA
Reg. No. 56462
DR DIABETES & SELF CARE
Vyankateshnagar, Jalna Road, Aurangabad
Phone No. 2333851, 2334858

SARDA

CENTRE FOR DIABETES & SELF CARE

NAME: MR. ABHISHEK PAL

SEX: Male AGE: .

REF. BY : BOB

DATE :11/03/2023

LIPID PROFILE

Serum Cholesterol :	145 mg/dl	130 - 250 mg/dl
HDL Cholesterol:	43 mg/dl	30 - 95 mg/dl
Serum Triglyceride:	136 mg/dl	up to 165 mg/dl
LDL Cholesterol:	74.8 mg/dl	up to 165 mg/dl
VLDL Cholesterol:	27.2 mg/dl	up to 40 mg/dl
LDL. / HDL Cholesterol Ratio:	1.74	Low risk : 0.5 - 3.0 Moderate risk: 3.0 - 6.0 High risk: > 6.0
CHOL./HDL Cholesterol Ratio:	3.37	Low risk : 3.3 - 4.4 Average risk: 4.4 - 7.1 Moderate risk: 7.0 - 11.0 High risk: > 11

Dr.S R. SARDA

M.D Reg No.66462

Dr.Sampat Sarda
M.D.(Pathology)

SARDA

CENTRE FOR DIABETES & SELF CARE

NAME: MR. ABHISHEK PAL

SEX: Male AGE: .

REF. BY : BOB

DATE :11/03/2023

Urine Routine Examination

Physical Examination

Colour:	Pale Yellow
Appearance:	Clear
Reaction:	Acidic
Deposit	Absent

Chemical Examination:

Specific Gravity	1.005
Albumin	Absent
Sugar:	Absent
Acetone:	----
Bile Salts	----
Bile Pigment:	----

Microscopic Examination

RBC :	Absent
Pus Cells:	OCASSIONAL/HPF
Epihtelial cells:	Absent
Crystals:	Absent
Casts:	Absent

Dr.S R. SARDA
M.D Reg. No.56462
SARDA CENTER FOR DIABETES & SELF CARE
Dr.Sampat Sarda
M.D.(Pathology)
Jalna Road, Aurangabad
333851, 2334858

SARDA

CENTRE FOR DIABETES & SELF CARE

NAME: MR. ABHISHEK PAL

SEX: Male AGE: .

REF. BY : BOB

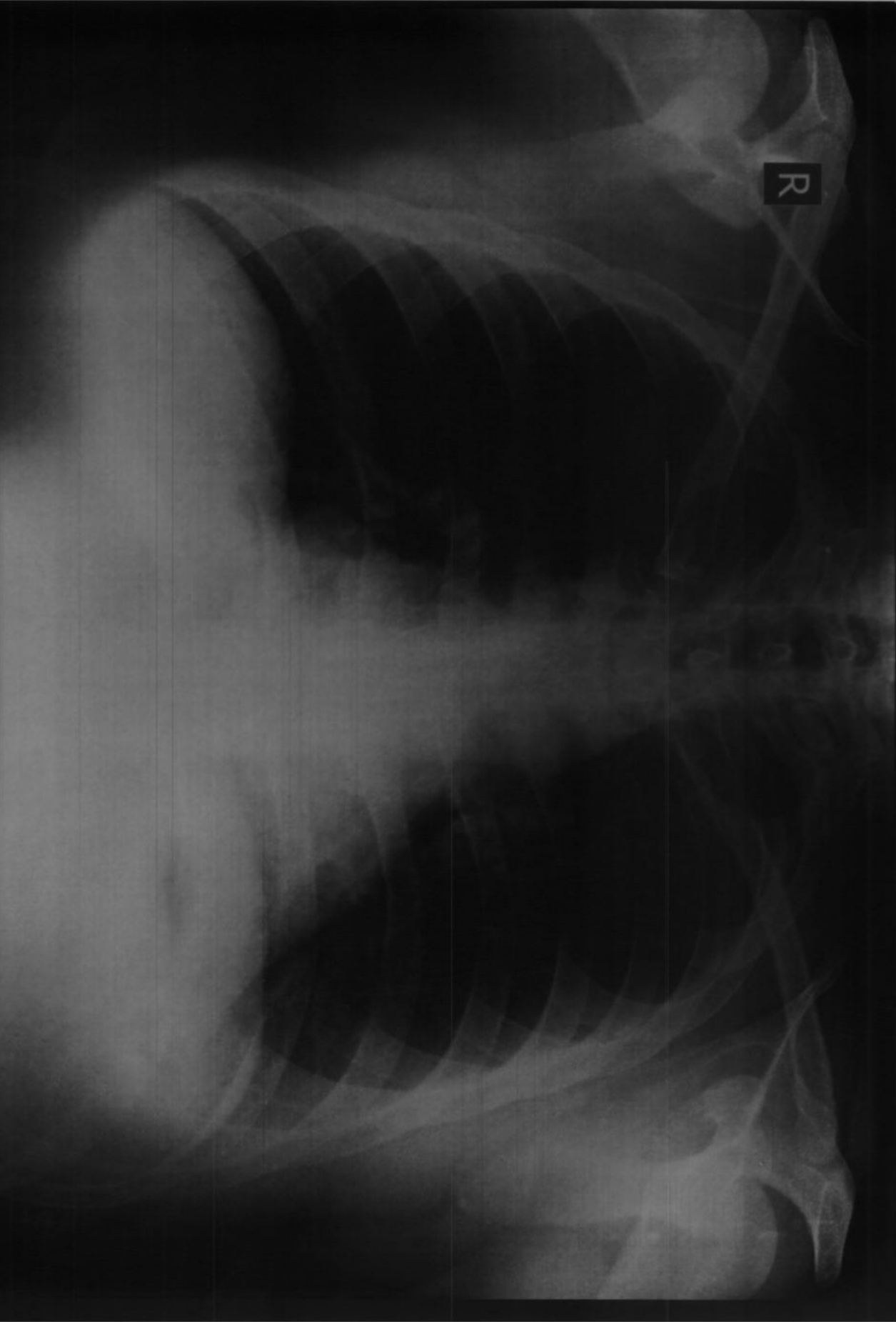
DATE :11/03/2023

AGE: YRS

THYROID FUCTION TEST

TEST	RESULT	NORMAL RANGE
Total T 3 :	103.53 ng/ml	87- 178 ng/ml
Total T 4 :	9.87 ug/dl	4.87 - 11.72 ug/dl
TSH Ultrasensitive :	2.30 uIU/ml	0.38 - 5.33 uIU/ml

Dr. S. R. SARDA
M.D. (Pathology)
Reg. No. 66462
CENTRE FOR DIABETES & SELF CARE
4, Vyankateshnagar, Jalna Road, Aurangabad
Phone No. 2333851, 2334858



R

ABHISHEK PAUL Age 31 YRS Male
Chest PA Patient ID

Ref Dr : DR S SARDA
Date : 11.03.2023 AM 11:33:33

Ellora Diagnostic Centre, Aurangabad (0240) 2353182

DIGITAL X-RAY
INTERVENTIONAL RADIOLOGY
3D/4D SONOGRAPHY & COLOR DOPPLER
2-D ECHOCARDIOGRAPHY
PERIPHERAL COLOR DOPPLER
HI-SPEED HELICAL C.T. SCAN
C.T. ANGIOGRAPHY
PATHOLOGY LAB. SERVICES



DIAGNOSTIC CENTRE
X-RAY, IMAGING & PATHOLOGY

1, VYANKATESH NAGAR, OPP. SFS
HIGH SCHOOL, JALNA ROAD,
AURANGABAD - 431005
☎ : 0240 - 2353182, 2325282, 8446100111

Abhishek Pal

11-03-2023

Ref. by:

CHEST PA VIEW

Trachea central.

Apices are clear.

Both lung fields appeared well pneuamtised and appeared normal.

Both cp angles are clear.

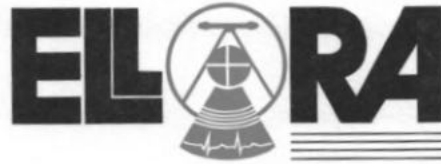Cardiac silhoutte appeared normal.

**IMPRESSION :
NORMAL CHEST**

DR. P. A. BARJATYA
M.B.B.S., M.D.
9823344449

Dr. Gokuldas S. Lahoti
Radiologist
Regd.No.59887
Sarda Center For Diabetes & Selfcare
4, Venkatesh Nagar Rd, Aurangabad.
DR. G. S. LAHOTI
M.B.B.S., D.M.R.D.
9850171587

DIGITAL X-RAY
INTERVENTIONAL RADIOLOGY
3D/4D SONOGRAPHY & COLOR DOPPLER
2-D ECHOCARDIOGRAPHY
PERIPHERAL COLOR DOPPLER
HI-SPEED HELICAL C.T. SCAN
C.T. ANGIOGRAPHY
PATHOLOGY LAB. SERVICES



DIAGNOSTIC CENTRE
X-RAY, IMAGING & PATHOLOGY

1, VYANKATESH NAGAR, OPP. SFS
HIGH SCHOOL, JALNA ROAD,
AURANGABAD - 431005
☎ : 0240 - 2353182, 2325282, 8446100111

Abhishek Pal

11-03-2023

Ref. by:

USG ABDOMEN

Liver is normal in size, and revealed normal echotexture.
Intrahepatic biliary radicles and portovenous echocomplex appeared normal.
No e/o any focal solid, cystic, or diffuse parenchymal pathology seen.
Normal cbd and portal vein.
Gallbladder is physiologically distended and appeared normal, no e/o any gallbladder calculus.
Normal gb wall thickness.
Spleen is normal in size & echogenicity. no e/o focal lesion seen.
Pancreas is normal in size, shape and echotexture. Normal peripancreatic fat planes.
No e/o pancreatic calcification/calculi. normal pancreatic duct.
Both kidneys are normal in size, shape, position and revealed normal cortical & medullary echopattern,
No e/o any calculus seen, No e/o hydronephrosis.
No e/o ascitis. no e/o any paraaortic adenopathy.
Normal bowel loop peristalsis & caliber.
Urinary bladder is well distended and appeared normal, no e/o any vesical calculus or mass lesion.
No changes of cystitis.
Normal prostate.

IMPRESSION :

**NORMAL LIVER, GALL BLADDER, SPLEEN, PANCREAS, BOTH KIDNEYS, .
NORMAL UR BLADDER, PROSTATE.**

DR. P. A. BARJATYA
M.B.B.S., M.D.
9822444449

Dr. Gokuldas S. Lahoti
Radiologist
Regd.No.59887
Sarda Center For Diabetes & Selfcare
4, Venkatesh Nagar, Aurangabad.

DR. G. S. LAHOTI
M.B.B.S., D.M.R.D.
9850171587

SARDA

CENTRE FOR DIABETES & SELF CARE

Date:- 11/03/23

Name Mr Abhishek Pal Age/Sex 31/Male

Address Bank of Baroda

OPHTHALMIC EXAMINATION REPORT

	<u>Right Eye</u>	<u>Left eye</u>
Vision Distant	6/6E-8.0D	6/6E-8.0D
Vision Near	NG	NG
Anterior segment	<u>NAD</u>	<u>NAD</u>
Pupils	NSRTL	<u>NSRTL</u>
Lens	clear	clear
Tension	<u>Normal</u>	<u>Normal</u>
Fundus:-	Disc normal C/D 0.3 R2+	Disc normal C/D 0.3 R2+
Colour Vision	Normal	Normal

Impression:

(BE) myopia ⊕

Rest within Normal limits



Dr. Ajay Louiya

DR. AJAY LOUYIA
M.B.B.S., D.O. (E.O.M.) D.N.C.T. (C.S.)
REG. NO. 65435
TRIPATI NETRALAYA & DENTAL CLINIC
AURANGABAD.



VIGHNAHARTA HEALTH VISIONARIES PRIVATE LIMITED'S

ASIAN SUPERSPECIALITY HOSPITAL

CITICARE

CIN No. : U85100MH2013PTC245579

Reg. Office : CTS No. 15184/3, Asian Hospital, Akashwani Signal, Jalna Road, Aurangabad - 431 001 (MH) India.
E-mail : asianchiticarehospital@gmail.com, Ph. 0240- 6610801 / 6610807

Name of Patient: Mr. Abhishek Pal

Date: 11/03/2023

Age/Sex : 31Yrs/Male

Ref.By: Dr.Sarda Centre

2-D ECHOCARDIOGRAPHY REPORT

Mitral Valve : Normal
Aortic Valve : Normal
Tricuspid Valve : Normal
Pulmonary Valve : Normal
Right Atrium : Normal
Right Ventricle : Normal
Left Atrium : 3.81Cm
Left Ventricle : Normal
IVS(S):1.12Cm LV(S):3.12Cm PW(S):1.24Cm LVEF-59%
IVS(D):0.99Cm LV (D):4.56Cm PW(D):0.74Cm FS- 31%
IVS : 0.90Cm
IAS : Intact
Aorta : 3.13Cm
Pulmonary Artery : Normal
Pericardium : Normal
IVC : Normal

DOPPLER STUDY

Mitral Flow : E- 0.95m/sec A- 0.62m/sec DT- 190m/sec E/A-1.53
Aortic Flow : 1.01m/sec
Pulmonary Flow : 0.74m/sec
Tricuspid Flow : m/sec RVSP- mm Hg

COLOR DOPPLER

MR : No
AR : No
TR : No
PR : No
Shunts : Nil

Dr. Deorao Thenge
M.D., D.N.B., (Cardiology)

Dr. Mukund Bajaj
M.D., D.M., (Cardiology)



VIGHNAHARTA HEALTH VISIONARIES PRIVATE LIMITED'S

ASIAN SUPERSPECIALITY HOSPITAL

CITICARE

CIN No. : U85100MH2013PTC245579

Reg. Office : CTS No. 15184/3, Asian Hospital, Akashwani Signal, Jalna Road, Aurangabad - 431 001 (MH) India.
E-mail : asianchiticarehospital@gmail.com, Ph. 0240- 6610801 / 6610807

CONCLUSION:

Normal Sized Cardiac Chambers.
No LV RWMA.
Good LV Systolic function with LVEF- 59%.
Normal LV Filling Pattern.
No MR/AR/TR.
No PE/LV Clot.

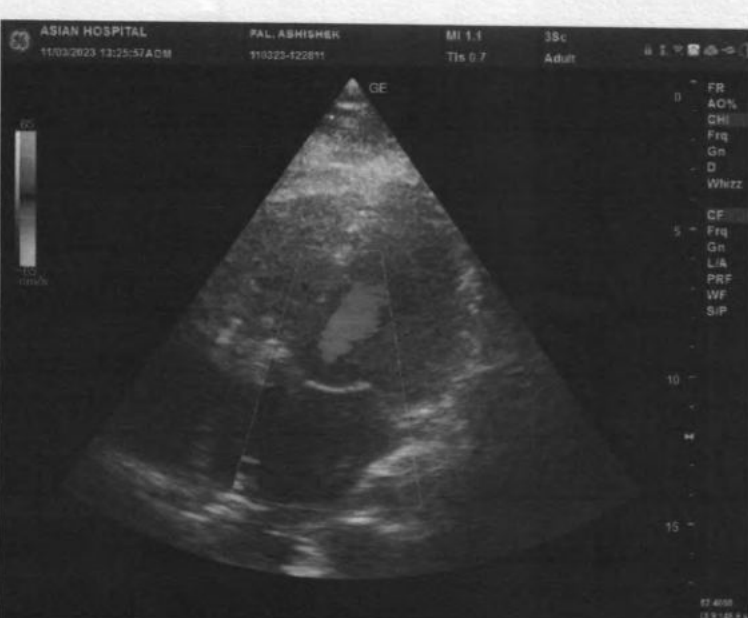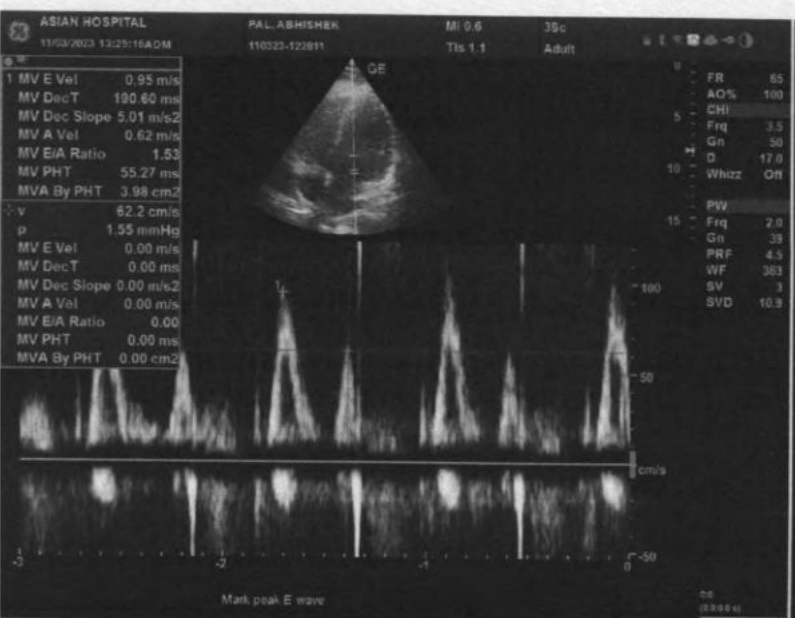
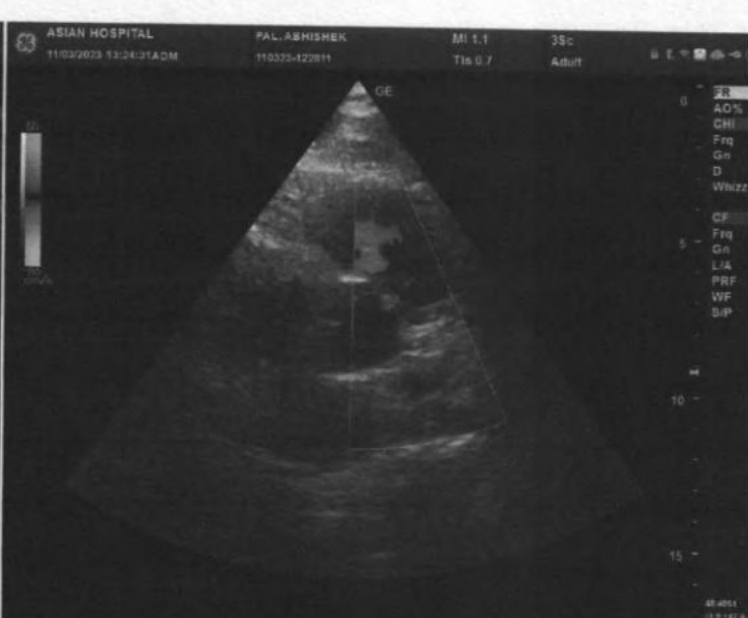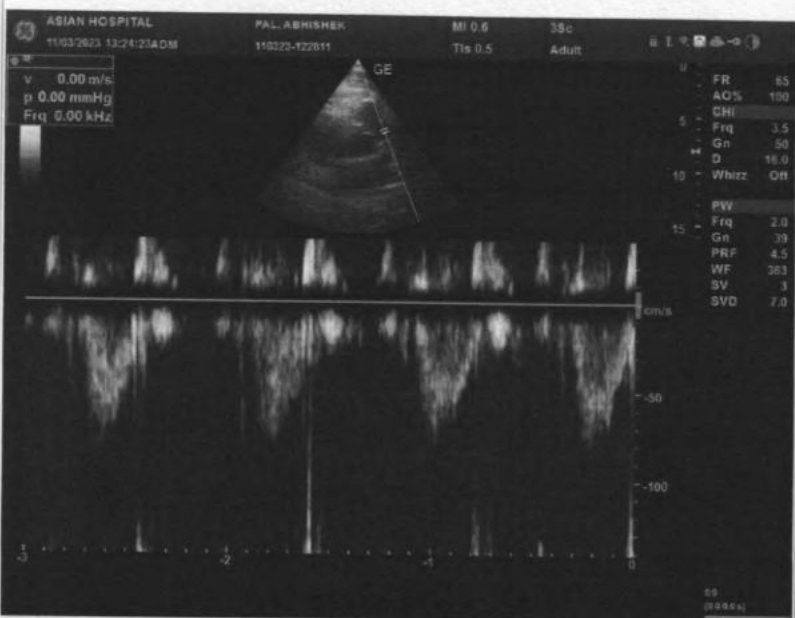
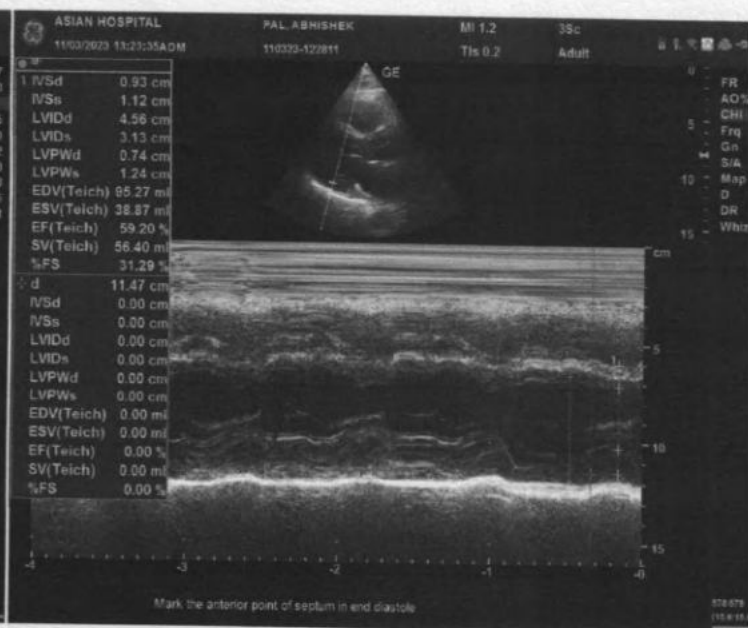
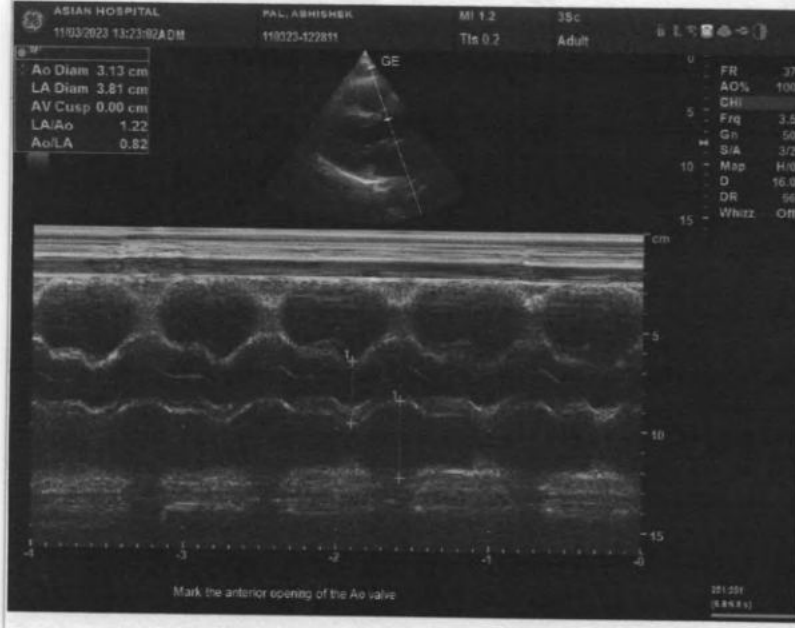
DR. DEORAO THENGE
M.D.D.N.B.(CARDIOLOGY)

Jr. Devrao Thenge
MD, DNB (Cardiology)
Reg. No. 2001/02/491



Dr. Deorao Thenge
M.D., D.N.B., (Cardiology)

Dr. Mukund Bajaj
M.D., D.M., (Cardiology)





बैंक ऑफ़ बड़ोदा
Bank of Baroda




नाम : MR. ABHISHEK INDRAJEET

Name : PAL

संचालक कूट क्र

E.C. No. : 126271


संचालक प्राधिकारी
Issuing Authority
AGM (Regional Head)
Surangaberi Region

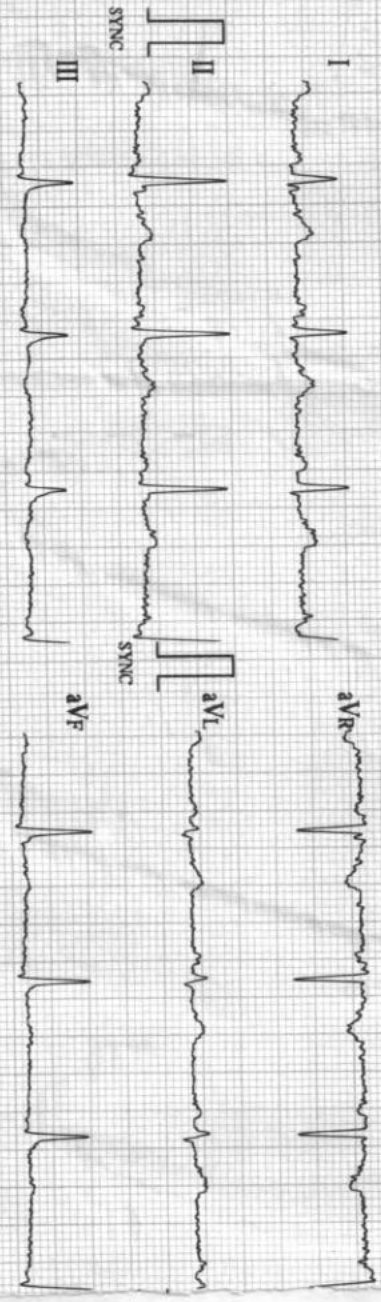

धारक के हस्ताक्षर
Signature of Holder

पिछले पर निम्नलिखित को लौटाएं
निष्पत्तक प्रमाणपत्र (सुरक्षा)
बैंक ऑफ़ बड़ोदा, बंडरा-कुर्ला कॉम्प्लेक्स
सी. 26, सी. 26, सी. 26, बंडरा-कुर्ला कॉम्प्लेक्स, मुंबई - 400 051, भारत
फोन 91 22 2662 5196 फैक्स 91 22 2662 5747

If found, please return to
Asst. General Manager (Security)
Bank of Baroda, Baroda Corporate Center
C-26, C-26, C-26, Bandra-Kurla Complex, Mumbai 400 051, India
Phone 91 22 2662 5196 Fax 91 22 2662 5747

रक्त समूह / Blood Group : AB +ve
संकेतक चिह्न / Identification Marks : Mole on left hand.

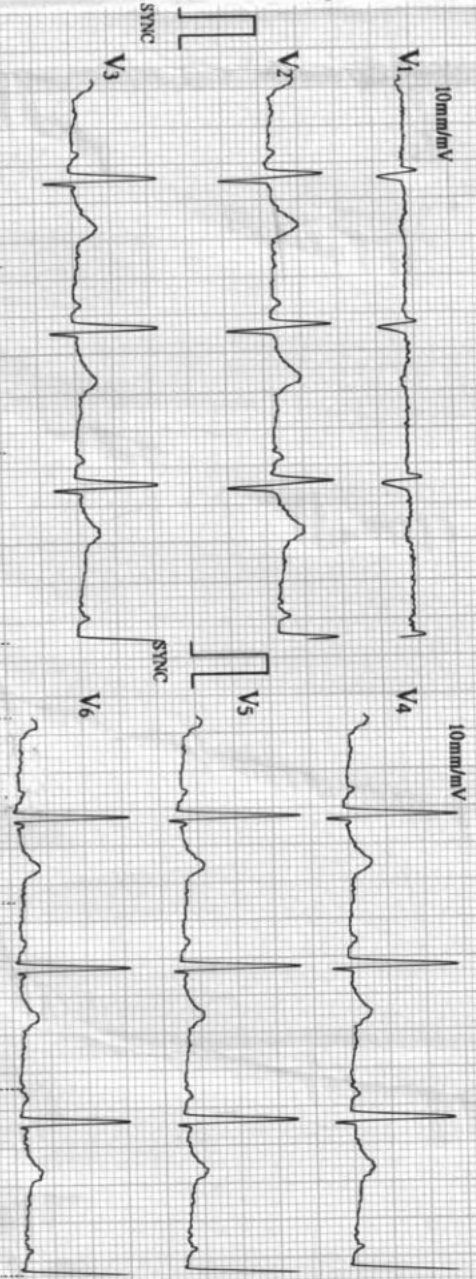
25mm/s 0.5-25Hz
10mm/mV



ECC-1203 V2.004 B105 : V2.004 / AMP : V1.008

BIOMEDICS SADASHIV PETH PUNE-30 CELL-9822

10mm/mV



ID : 2008

03/11/2023 09:21

Name: *Abhishek*

Sex :

Age :

HR : 75 bpm

P-R : 798 ms

P-R : 135 ms

QRS : 93 ms

QT/QTc : 389/435 ms

P/QRS/T : -14/58/17 °

RV5/SVI : 1.570/0.340 mV

RV5-SVI : 1.910 mV

Machine Interpretation Only

Confirm with Physician

Physician

BIOMEDICS SADASHIV PETH P

198798

**SARDA
CENTRE FOR DIABETES & SELF CARE**

4, Vyankatesh Nagar, Jalna Road, Aurangabad. Ph. : (0240) 2333851, 2334858.

Name: Mr. Abhishek Pat Age: 40/5
31x/0

CLINICAL SUMMARY:

Weight : _____ Height (Cms) : _____ Blood Pressure : _____

ECG FINDINGS:

Rate : 75 min _____ ORS. Complex : ~ _____

Rhythm : ~ _____ ST Segment : ~ _____

Mechanism : ~ _____ T. Wave : ~ _____

Axis : ~ _____ QT Interval : ~ _____

P. Wave : ~ _____ PR Interval : ~ _____

Recommendation : Wm

Dr. A. S. S. M.

M.D. REG. NO. 7350
SARDA CENTER FOR DIABETES & SELF CARE
4, Vyankateshnagar, Jalna Road, Aurangabad
Phone No. 2333851, 2334858

Date : 11/3/20 Dr. _____