

Dr. Amit H. Patel

MD (Chest), DTCD

Consultant Pulmonologist

(Specialist in Respiratory Diseases, Fiberoptic Bronchoscopy,
Critical Pulmonary Medicine & Sleep Disorders)

Reg. No. : G-8980

For Emergency: +91-9824310150

Email : amit.patel@cimshospital.org

3/10/22

Ach

Partial exercise
for 45 minutes

Name : Ravi Jain
Age : 32 yrs Weight: 71.04 kg
Past History : NI

History of Addiction : NI

Occupation : Bank of Baroda

Family History : NAD

Dr. Amit Patel

No any complaints

9824310150

Dr - Amit Patel

CONSULTATION ONLY

FOR OPD



4

HEALTH CHECKUP REPORT

Patient Name: MR. RAVI JAIN

Age/Gender: 31/M

Reg. No: 387635

Package: MEDIWHEEL

DATE: 31/10/2022

COMPLAINTS (IF ANY):

- NO COMPALIN

HISTORY OF HEALTH STATUS: No

PRESENT MEDICATIONS: No

HYPERSENSITIVITY TO ANY DRUG: No

PERSONAL HISTORY:

- Bowel : Regular
- Micturition : Normal
- Sleep : Adequate
- Appetite : Adequate

Diet : Veg
Habits : No
Physical Activity/Exercise: Walking

HISTORY OF ILLNESS (WITH PAST MEDICATIONS): NO

FAMILY HISTORY:

- Father – hypertension

TAL SIGNS:

- Height : 165cms
- Weight : 71.4Kgs

Pulse : 80min.
B.P: 94/54mmHg

FOR OFFICE USE ONLY

PHYSICIAN CONSULTATION:

1) Recommendations

- Healthy life style

OPHTHALMO CONSULTATION:

Best corrected visual acuity

RE

6/6

(Dr. amit patel)

LE

6/6

Please take regular medicine as prescribed by the Doctor. (If given)

FOR OFFICE USE ONLY



Reg. No : CIMS/A/2022/387635	Visit No : HC/311022/18 [HCV]
Patient Name : MR. RAVI JAIN	Age(Y-M-D)/Sex : 31 Y 2 M 14 D. / Male
Referring Doctor : Dr. CIMS DOCTOR	Doctor :
Ward/Room :	Bed :

ORDI/311022/408 Lab No : 2022161285 LSN : 930031 (Whole Blood) Sample Quality : Normal
 Collection Time : 31/10/2022 9:50:16 Arrival : 31/10/2022 10:27:16 Validation Time : 31/10/2022 12:11:34PM

FOR PATHOLOGY REPORTS ONLY

	<u>Result</u>	<u>Unit</u>	<u>Reference Range</u>
CBC With ESR			
TOTAL COUNT			
Hemoglobin <i>(SLS Hemoglobin Detection method)</i>	13.9	g/dl	13.5 - 18.0 g/dl
Total RBC Count <i>(Hydro Dynamic Focusing Method)</i>	4.99	mill/Cmm	4.7 - 6.0 mill/Cmm
HCT <i>(Hydro Dynamic Focusing Method)</i>	42	%	42 - 52 %
Total WBC Count <i>(Flow Cytometry)</i>	6730	/Cmm	4000 - 10500 /Cmm
Platelet Count <i>(Hydro Dynamic Focusing Method)</i>	305000	/Cmm	150000 - 450000 /Cmm
DIFFERENTIAL COUNT (by Flow Cytometry)			
Polymorphs	51	%	40 - 70 %
Lymphocytes	43	%	22 - 45 %
Eosinophils	01	%	01 - 04 %
Monocytes	05	%	01 - 06 %
Basophils	00	%	00 - 01 %
Immature Granulocytes	00	%	0 - 2 %
Smear Study			
RBCs are Normochromic & Normocytic. Platelets are adequate in number. Malarial Parasites are not seen. No Premature cells are seen.			
BLOOD INDICES (by Calculated Method)			
M.C.V	84.2	fl	78 - 100 fl
M.C.H	27.9	pg	27 - 31 pg
M.C.H.C.	33.1	gm/dl	32 - 36 gm/dl
RDW-CV	12.7	%	11.5 - 14.0 %
ESR (Red Cell Aggregation)			
After One Hour	27	mm	0 - 10 mm
Blood Group Rh			
ABO	"O"		



Dr. Manisha Shah
MD (Path & Bact)
Consultant Pathologist
Reg. No. : G-15496

Dr. Jitendra Nayak
MD (Path)
Consultant Pathologist
Reg. No. : G-14786





Reg. No : CIMS/A/2022/387635
Patient Name : MR. RAVI JAIN
Referring Doctor : Dr. CIMS DOCTOR
Ward/Room :

VisitNo : HC/311022/18 [HCV]
Age(Y-M-D)/Sex : 31 Y 2 M 14 D. / Male
Doctor :
Bed :

ORD/311022/408 Lab No : 2022161285
Collection Time : 31/10/2022 9:50:16

LSN : 930031 (Whole Blood)
Arrival : 31/10/2022 10:27:16


Sample Quality : Normal
Validation Time : 31/10/2022 12:25:41PM

TEST	Result	Unit	Reference Range
HbA1c (Glycosylated Haemoglobin) TEST HbA1c (Glyoco Hb) (Immuno Turbidimetric)	5.33	%	4.8-5.9% Normal 5.9-7.0% Good diabetic control 7.0-10.0% Fair diabetic control >10.0% Poor diabetic control
Mean Plasma Glucose	112.3	mg/dL	80 - 140 mg/dL

FOR PATHOLOGY REPORTS ONLY

Dr. Manisha Shah
MD (Path & Bact)
Consultant Pathologist
Reg. No. : G-15496

Dr. Jitendra Nayak
MD (Path)
Consultant Pathologist
Reg. No. : G-14786


Dr. Kazumi Gondalia
M.D. (Path)
Consultant Pathologist
Reg. No. : G-21729



Reg. No	: CIMS/A/2022/387635	VisitNo :	HC/311022/18 [HCV]
Patient Name	: MR. RAVI JAIN	Age(Y-M-D)/Sex	: 31 Y 2 M 14 D. / Male
Referring Doctor	: Dr. CIMS DOCTOR	Doctor	:
Ward/Room	:	Bed	:
ORD/311022/408	Lab No : 2022161285	LSN :930031 (Whole Blood)	Sample Quality : Normal
Collection Time :31/10/2022 9:50:16	Arrival : 31/10/2022 10:27:16		Validation Time: 31/10/2022 12:11:35PM

Rh

POSITIVE

*** END OF REPORT ***

FOR PATHOLOGY REPORTS ONLY



Dr. Manisha Shah
MD (Path & Bact)
Consultant Pathologist
Reg. No. : G-15496

Dr. Jitendra Nayak
MD (Path)
Consultant Pathologist
Reg. No. : G-14786




Reg. No : CIMS/A/2022/387635	VisitNo : HC/311022/18 [HCV]
Patient Name : MR. RAVI JAIN	Age(Y-M-D)/Sex : 31 Y 2 M 14 D. / Male
Referring Doctor : Dr. CIMS DOCTOR	Doctor :
Ward/Room :	Bed :
ORD/311022/408 Lab No : 2022161286 LSN : 930031 (SERUM)	Sample Quality : Normal
Collection Time : 31/10/2022 9:50:16	Arrival : 31/10/2022 10:27:16 Validation Time: 31/10/2022 12:22:14PM

FOR PATHOLOGY REPORTS ONLY

	<u>Result</u>	<u>Unit</u>	<u>Reference Range</u>
Creatinine <i>(Buffered Jaffe Reaction Kinetic Compensated)</i>	0.96	mg/dL	0.7 - 1.2 mg/dL
Estimated GFR	111.96	mL/min/1.73m ²	59 - 137 mL/min/1.73m ²
Fasting Glucose <i>(Hexokinase)</i>	85.4	mg/dL	70 - 100 mg/dL
Thyroid Function Test			
TOTAL T3 (T3) * <i>(Electrochemiluminescence Assay)</i>	1.37	ng/ml	0.846 - 2.02 ng/ml
TOTAL T4 (T4) * <i>(Electrochemiluminescence Assay)</i>	9.13	µgm/dl	5.13 - 14.06 µgm/dl
TSH <i>(Electrochemiluminescence Assay)</i>	1.79	µIU/ml	0.27- 4.20 µIU/ml
Uric Acid <i>(Uricase Colorimetric Enzymatic)</i>	6.26	mg/dL	3.4 - 7.0 mg/dL

*** END OF REPORT ***



Dr. Manisha Shah
MD (Path & Bact)
Consultant Pathologist
Reg. No. : G-15496

Dr. Jitendra Nayak
MD (Path)
Consultant Pathologist
Reg. No. : G-14786





Reg. No : CIMS/A/2022/387635
 Patient Name : MR. RAVI JAIN
 Referring Doctor : Dr. CIMS DOCTOR
 Ward/Room :

VisitNo : HC/311022/18 [HCV]
 Age(Y-M-D)/Sex : 31 Y 2 M 14 D. / Male
 Doctor :
 Bed :

ORD/311022/408 Lab No : 2022161287 LSN : 930031 (SERUM) Sample Quality : Normal
 Collection Time : 31/10/2022 9:50:16 Arrival : 31/10/2022 10:27:16 Validation Time : 31/10/2022 12:29:53PM

	<u>Result</u>	<u>Unit</u>	<u>Reference Range</u>
BUN * (Ureas with UV)	9.1	mg/dL	6 - 20 mg/dL

*** END OF REPORT ***

FOR PATHOLOGY REPORTS ONLY

Jain

Dr. Manisha Shah
 MD (Path & Bact)
 Consultant Pathologist
 Reg. No. : G-15496

Dr. Jitendra Nayak
 MD (Path)
 Consultant Pathologist
 Reg. No. : G-14786



Reg. No : CIMS/A/2022/387635
 Patient Name : MR. RAVI JAIN
 Referring Doctor : Dr. CIMS DOCTOR
 Ward/Room :

VisitNo : HC/311022/18 [HCV]
 Age(Y-M-D)/Sex : 31 Y 2 M 14 D. / Male
 Doctor :
 Bed :


ORD/311022/408 Lab No : 2022161467 LSN : 930031 (Urine) Sample Quality : Normal
 Collection Time : 31/10/2022 12:22:39 Arrival : 31/10/2022 12:22:39 Validation Time : 31/10/2022 1:05:25PM

	<u>Result</u>	<u>Unit</u>	<u>Reference Range</u>
Urine R & M			
PHYSICAL EXAMINATION			
Quantity	20 cc		
Colour	Pale Yellow		
Transperancy	Clear		
Reaction (QDS-10 Strip)	7.0		
Sp. Gravity (QDS-10 Strip)	1.010		1.005 - 1.035 .
CHEMICAL EXAMINATION			
U. Albumin (QDS-10 Strip/Manual)	Nil		
U. Glucose (QDS-10 Strip/Manual)	Nil		
U. Acetone (QDS-10 Strip/Manual)	Absent		
BS/BP (QDS-10 Strip/Manual)	Absent		
MICROSCOPIC EXAMINATION			
Pus Cell	Occasional	/H.P.F.	/H.P.F.
Red Blood Cell	Nil	/H.P.F.	/H.P.F.
Epithelial Cell	1-2	/H.P.F.	/H.P.F.
Cast	Not Seen		
Crystals	Not Seen		
Amorphous	Absent		
Monilia	Absent		

*** END OF REPORT ***

Dr. Manisha Shah
 MD (Path & Bact)
 Consultant Pathologist
 Reg. No. : G-15496

Dr. Jitendra Nayak
 MD (Path)
 Consultant Pathologist
 Reg. No. : G-14786


Dr. Kazumi Gondalia
 M.D. (Path)
 Consultant Pathologist
 Reg. No. : G-21729



FOR PATHOLOGY REPORTS ONLY

I-10-2022 13:52:53

D: 695

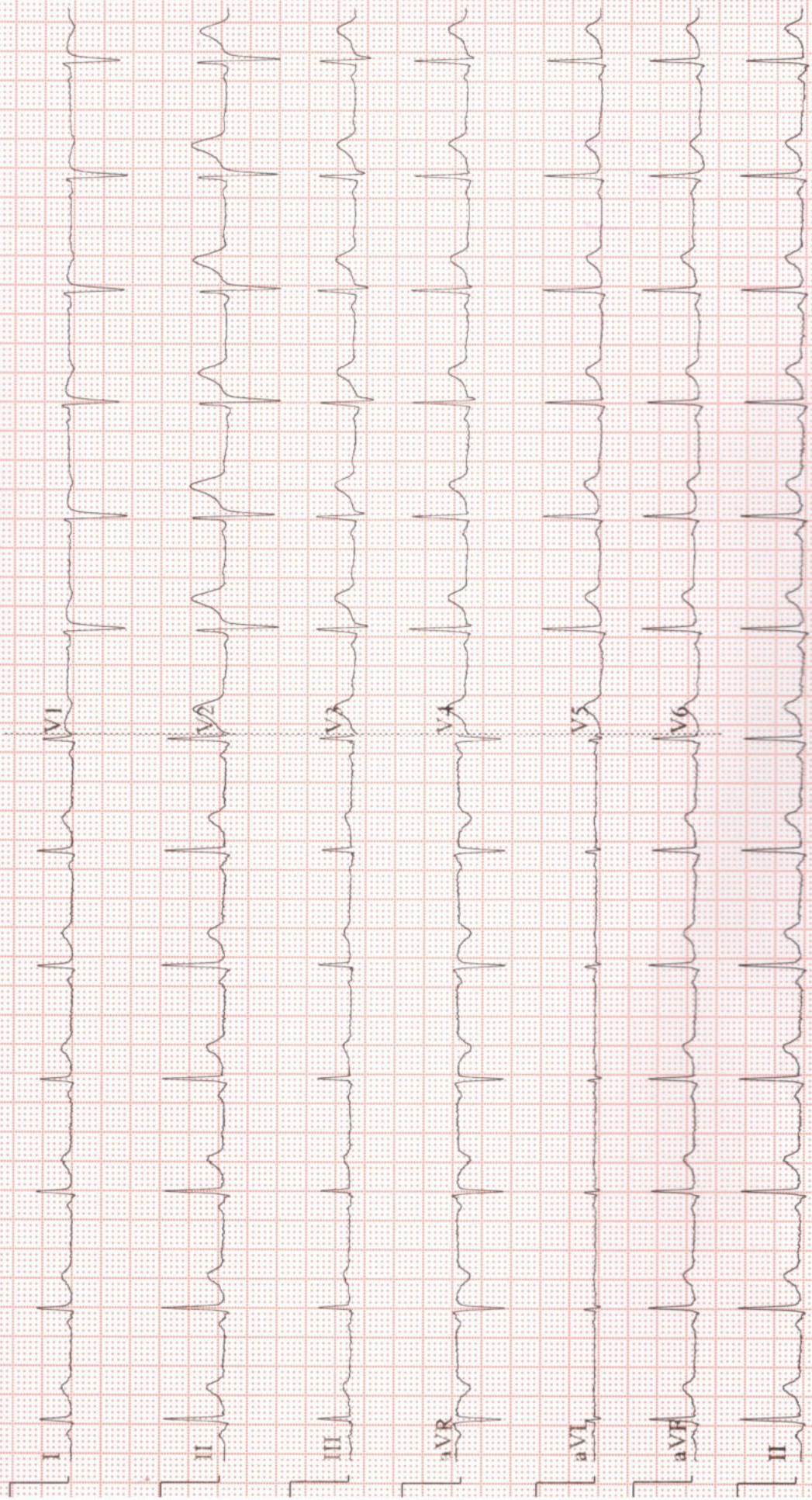
Years

HR : 77 bpm
 P : ms
 PR : 119 ms
 QRS : 86 ms
 QT/QTc : 348/394 ms
 P/QRS/T : 56/59/57 °
 RV5/SV1 : 0.974/0.909 mV

Diagnosis Information

Name : MR. RAVI JAIN
 Reg No : CIMS/A/2022/387635
 DoB/Sex : 17/08/1991 / Male

Report Confirmed by:



Name : MR. RAVI JAIN

Reg No : CIMS/A/2022/387635

DoB /Sex: 17/08/1991 / Male

ECHO Report

Dt : 31/10/2022

Patient Details

Patient ID 320277
Name Mr. RAVI JAIN
Age 31 Years
Gender Male
Blood Group
Referral Doctor

ECHO Identification Detail

Doctor Incharge Dr. ANISH CHANDARANA
Clinical Status Of Patient
ECHO Code JP
Finding Description

1. Normal sized LA, LV, RA, RV.
2. Normal LV systolic function, LVEF: 60%.
3. No RWMA.
4. Normal LV diastolic function.
5. All cardiac valves are structurally normal.
6. Trivial MR, Trivial TR, Trivial PR, No AR.
7. No PAH.
8. No clot/vegetation/pericardial effusion.

Dr. ANISH CHANDARANA

Patient's Name :RAVI JAIN
Reg. No. (IP/OP):HC-387635
Referred By Dr. :CIMS

Age, Sex :31Y/M
Date :31/10/2022

Plain Skiagram of Chest PA standing view:
(Serial No-6422)

Both lung fields appear normal.

No evidence of pleural effusion or pneumothorax is seen on either side.


Mediastinal shadow appears normal.

Heart and aorta appear normal.

Domes of diaphragm appear normal.

Bones under view appears normal.

Kindly correlate clinically



DR KIRTAN SHAH M.D. RADIOLOGIST
DR DEEPA SHAH M.D., D.M.R.E
DR UMA MEHTA D.M.R.D. F.R.C.R
DR NIMISH SHARMA D.M.R.D. (D.N.B.)
DR RAVINA CHAUHAN M.D. RADIOLOGIST
DR YASH PATEL M.D., D.N.B.
DR SUNALI DESAI MD, DNB, DM, FRCR
CONS. RADIOLOGIST
CONS. RADIOLOGIST
CONS. RADIOLOGIST
CONS. RADIOLOGIST
CONS. RADIOLOGIST
CONS. RADIOLOGIST
CONS. RADIOLOGIST NEURORADIOLOGIST

Note: This is only a radiological impression and not the final diagnosis. All diagnostic modalities have their own limitations. Therefore radiological modality report should be interpreted in correlation with clinical and pathological findings.

FOR RADIOLOGY REPORTS ONLY

Patient's Name :RAVI JAIN	Age, Sex :31Y/M
Reg. No. (IP/OP):HC-387635	Date :31/10/2022
Referred By Dr. :CIMS	

USG OF ABDOMEN & PELVIS

LIVER: Liver is normal in size and echotexture. No evidence of focal SOL or dilatation of IHBR seen. Porta hepatis appear normal.

GALLBLADDER: Gallbladder appeared normal. No calculus or mass lesion seen.

PANCREAS: Pancreas appeared normal in size and echotexture. No focal lesion, mass or pancreatitis.

SPLEEN: Spleen appears normal in size and echotexture.

PARAAORTIC REGION: Aorta grossly appeared normal. No paraaortic lymphnodes seen.

KIDNEYS: Both kidneys appear normal in size, shape and in position. Cortex and collecting system of both kidneys appeared normal. No evidence of calculus or obstructive uropathy on either side. Right kidney: 92x43mm. Left kidney: 93x46mm.

URINARY BLADDER: Bladder appeared normal. No calculus or mass lesion is seen.

PROSTATE: Prostate appears normal in size and echotexture. Size of prostate: 29x25x34mm. Volume: 13cc.

No evidence of free fluid or collection is seen in peritoneal spaces. Normal small bowel peristalsis noted.

COMMENTS: Appearance suggests,

- No significant abnormality detected.

Kindly correlate clinically.

DR KIRTAN SHAH M.D. RADIODIAG. CONS. RADIOLOGIST
 DR DEEPA SHAH M.D., D.M.R.E. CONS. RADIOLOGIST
 DR UMA MEHTA D.M.R.D. F.R.C.R. CONS. RADIOLOGIST
 DR NIMISH SHARMA D.M.R.D. (D.N.B.) CONS. RADIOLOGIST
 DR RAVINA CHAUHAN M.D. RADIODIAG. CONS. RADIOLOGIST
 DR YASH PATEL M.D., D.N.B. CONS. RADIOLOGIST
 DR SUNALI DESAI MD, DNB, DM, FRCR NEURORADIOLOGIST

Note: This is only a radiological impression and not the final diagnosis. All diagnostic modalities have their own limitations. Therefore radiological modality report should be interpreted in correlation with clinical and pathological findings.

FOR RADIOLOGY REPORTS ONLY

