


MER- MEDICAL EXAMINATION REPORT

Date of Examination	01-08-2023		
NAME	MA. DAUDAYAL PATEDAR.		
AGE	34y / m	Gender	male
HEIGHT(cm)	175 cms	WEIGHT (kg)	62kg
B.P.	122 / 77	P- 79min / Regular	
ECG	Normal		
X Ray	Normal		
Vision Checkup	Color Vision : Clear Far Vision Ratio : 6/6 Near Vision Ratio : 6/6		
Present Ailments	nil		
Details of Past ailments (If Any)	nil		
Comments / Advice : She /He is Physically Fit	Fit & Fine		



Dr. Vivek Agnihotri  
 MBBS  
 Reg. No. MP-5034  
 Signature with Stamp of Medical Examiner

# CERTIFICATE OF MEDICAL FITNESS

This is to certify that I have conducted the clinical examination

of Mr. Dandayal Patidar on 01-08-2023


After reviewing the medical history and on clinical examination it has been found that he/she is

	Tick
<ul style="list-style-type: none"> <li>• Medically Fit</li> </ul>	<input type="checkbox"/>
<ul style="list-style-type: none"> <li>• Fit with restrictions/recommendations</li> </ul> <p>Though following restrictions have been revealed, in my opinion, these are not impediments to the job.</p> <p>1.....</p> <p>2.....</p> <p>3.....</p> <p>However the employee should follow the advice/medication that has been communicated to him/her.</p> <p>Review after _____</p>	<input checked="" type="checkbox"/>
<ul style="list-style-type: none"> <li>• Currently Unfit. Review after _____ recommended</li> </ul>	<input type="checkbox"/>
<ul style="list-style-type: none"> <li>• Unfit</li> </ul>	<input type="checkbox"/>

*Dr. Vivek Agnihotri*

**Dr. Vivek Agnihotri**  
**Medical Officer**  
**The Apollo Clinic, (Location)**

*This certificate is not meant for medico-legal purposes*







# Dr. Agnihotri's Path Lab & Diagnostic Center

(A unit of Virom Healthcare Pvt. Ltd.)

Patient Name	DAUDAYAL PATIDAR	Patient ID	010823050
Age   Gender	34Y MALE	Scan Date	01 AUG 2023
Referring Doctor	SELF		

## CHEST X-RAY PA VIEW

- Soft tissue opacity and thoracic bony cage appears to be normal.
- Bronchovascular markings are prominent.
- Cardiac shadow is normal .
- Both lungs fields are clear .
- Both domes of diaphragm appear normal.
- Both cardio-phrenic angles appear to be clear.

## IMPRESSION:

**No obvious abnormality noted.**

## Suggested clinical correlation.


  
**DR. PRAMITA KHETI**  
MBBS, M.D., (MP No. 28319)  
Dr. Pramita kheti

MBBS, MD REG MP NO - 28319

Consultant Radiologist

### Disclaimer

It is an online interpretation of medical imaging based on the available clinical data. Patient's identification in online reporting not established, so this report cannot be utilized for any medico legal purpose/ certifications. All modern machines/procedures have their own limitations. If there is any clinical discrepancy, this investigation may be repeated or reassessed by other tests.



**Head Office :** UG-4,5,6, The Magnet Tower, 6/1, Race Course Road,  
Janjirwala Square, New Palasia, INDORE (M.P.)

Phone : 0731- 4061771, 4061772, Mobile : 91099 99009, 91099 99004, 99939 42466

✉ drvivekagnihotri@gmail.com 🌐 www.dragnihotripathlab.com | www.dragnihotripathlab.in



# Dr. Agnihotri's Path Lab & Diagnostic Center

(A unit of Virom Healthcare Pvt. Ltd.)

Patient ID : 00000110  
Patient Name : MR DAUDAYAL PATIDAR  
Age/ Gender : 34Y /MALE  
Ref. By : DR. SELF  
Center Name : Dr. Agnihotri's Path Lab & Diagnostic Center  
DATE : 01/ 08 /2023

## ECHO COLOR DOPPLER REPORT

### 1. INTERPRETATION:

Normal 2D Echo Doppler

- Normal sized cardiac chambers.
- LVEF:65%.
- Normal cardiac valves.

Normal PAH.

### 2. IMAGING

M Mode examination revealed normal movement of both mitral leaflets during diastole. No SAM or mitral valve prolapse is seen. Aortic cusps are not thickened and enclosure line is central. Tricuspid valve is normal, pulmonary valve is normal, aortic root is normal in size, dimensions of left atrium and left ventricle are normal.

2 - D imaging in PLAX, SAX and apical views revealed a normal sized left ventricle. Movement of septum, anterior, posterior, inferior and lateral walls is normal.

Global LVEF is 65%. Mitral valve opening is normal. No evidence of mitral valve prolapse is seen. Aortic valve has three cusps and its opening is not restricted. Right atrium & right ventricle are normal sized. Tricuspid valve leaflets move normally. Pulmonary valve is normal. Interatrial and interventricular septa are intact. No intracardiac mass of thrombus is seen. No pericardial pathology is observed.

📍 **Head Office** : UG-4,5,6, The Magnet Tower, 6/1, Race Course Road,  
Janjirwala Square, New Palasia, INDORE (M.P.)







# Dr. Agnihotri's Path Lab & Diagnostic Center

(A unit of Virom Healthcare Pvt. Ltd.)

### 3. MEASUREMENTS: Normal


Aortic root diameter	3.0cms	2.0 - 3.7 cm <2.2cm/M2
Aortic valve opening	1.8cms	1.5-2.6cm
Right ventricular dimension	1.9cms	0.7-2.5cm <1.4cm/M2
Left atrial dimension	3.5cms	1.9-4.0cm <2.2cm/M2
Left ventricular ED dimension	4.5cms	3.7-5.6cm <3.2cm/M2
Left ventricular ES dimension	3.0cms	2.2-4.0cm
Interventricular ED septal thickness	0.8cms	0.6-1.2cm
Left ventricular EDPW thickness	0.8cm	0.5-1.0cm
IVS/LVPW	1	<1.3

### Indices of left Ventricle function:

LVEjection Fraction	65%	60 - 80 %
---------------------	-----	-----------

### 3. COLOUR DOPPLER STUDY


Peak Velocity	Max. Gradient Regurgitation (m/sec) (mm/Hg)		
M.V	0.9	3.8	0/0
A.V	1.4	8.2	0/0
P.V	1	4	
T.V	0.56	1.25	

  
**Dr. Yatendra Kumar Porwal**  
 D.M. Cardiologist  
 MP-13449  
**Dr. YATENDRA KUMAR**  
**PORWAL**  
 MD, Cardiologist

 **Head Office :** UG-4,5,6, The Magnet Tower, 6/1, Race Course Road,  
 Janjirwala Square, New Palasia, INDORE (M.P.)

Phone : 0731- 4061771, 4061772, Mobile :  91099 99009, 91099 99004, 99939 42466

 drvivekagnihotri@gmail.com  www.dragnihotripathlab.com | www.dragnihotripathlab.in





# Dr. Agnihotri's Path Lab & Diagnostic Center

(A unit of Virom Healthcare Pvt. Ltd.)

Patient Name	MR.DAUDAYAL PATIDAR	Age / Sex	34Y/MALE
Referred by	SELF	Date	01/08/2023
OPD / IPD	OPD		

## USG WHOLE ABDOMEN

**Technique:** - Real time ultrasound examination of abdomen and pelvis was performed with abdominal probe on ultrasound machine (Philips Clearvue 650)).

### Observations:-

Liver is normal in size. No focal lesion is seen. No evidence of any IHBR dilatation.

Gall bladder wall is normal. No sludge or calculi. Walls are thin.

The main portal vein is normal. CBD is normal in size.

Pancreas and spleen are normal in size, shape and echotexture.

Right kidney measures 10.5 cms Left kidney measures 10.2 cms  
Both kidneys show normal size and echotexture. Cortico-medullary differentiation and cortical thickness are maintained. No calculi / hydronephrosis in either side.

Urinary bladder is well distended and is normal in contour and capacity. No calculus or mass is seen.

Prostate is normal in size, shape and echotexture .

No ascites or pleural effusion noted. No significant lymphadenopathy.

### IMPRESSION:-

- *No significant abnormality detected.*

*For clinico-pathological correlation .*

*Dr. A. MANGAL*  
Dr. A. Mangal, DNB  
Consultant Radiologist  
REG. NO. 142870

*Important: Due to technical and biological limitations in case of any error in any study, the doctor can not be held responsible for claim of damages of any nature and this report is not valid for any medicolegal aspect.*

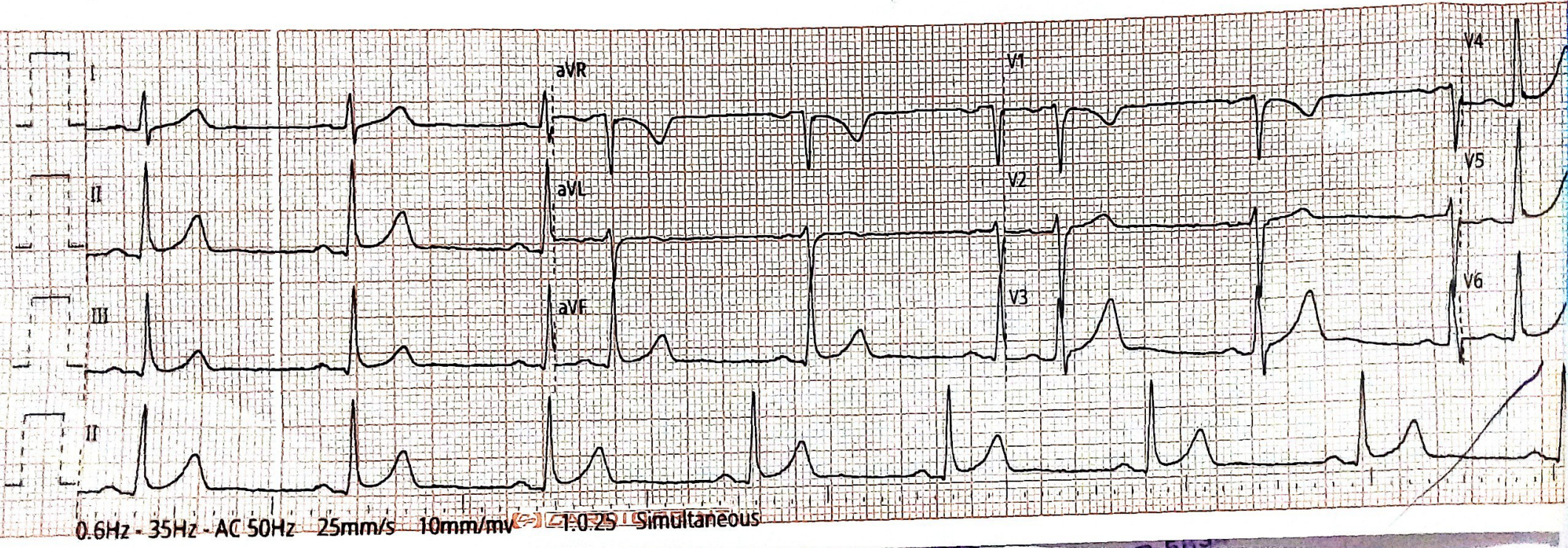


**Head Office :** UG-4,5,6, The Magnet Tower, 6/1, Race Course Road,  
Janjirwala Square, New Palasia, INDORE (M.P.)

Phone : 0731- 4061771, 4061772, Mobile : 91099 99009, 91099 99004, 99939 42466

✉ drvivekagnihotri@gmail.com | www.dragnihotripathlab.com | www.dragnihotripathlab.in

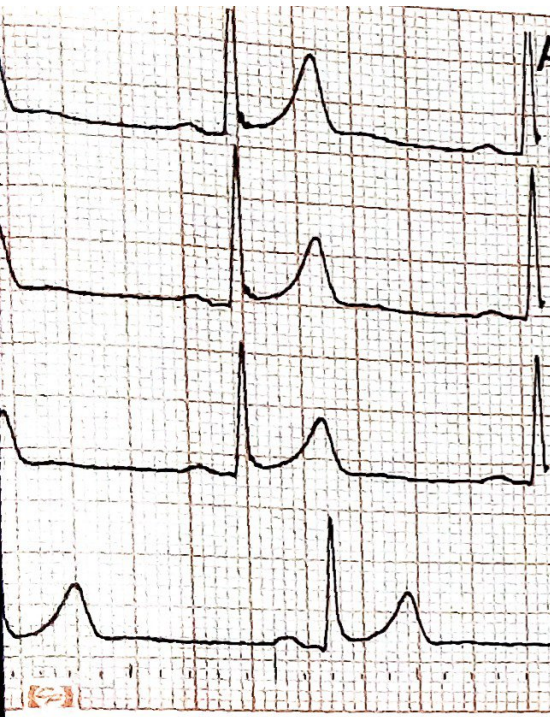



0.6Hz - 35Hz - AC 50Hz 25mm/s 10mm/mv 1:0.25 Simultaneous

AD-500






# Agnihotri Pathology lab Indore ECG report

ID : 20210122172039  
Name :  
Gender :  
Age :  
Dept :  
Bed No :  
HR : 54 bpm  
PR : 166 ms  
QRS : 88 ms  
QT/QTc : 412/402 ms  
P/QRS/T : 66/80/61 °  
RV5/SV1 : 1.479/0.850 mv  
RV5+SV1 : 2.329 mv

<<Interpretations >>  
Sinus bradycardia  
Normal ECG except for rate



Confirm and sign:  
Examination time: 2021-01-22 10:30

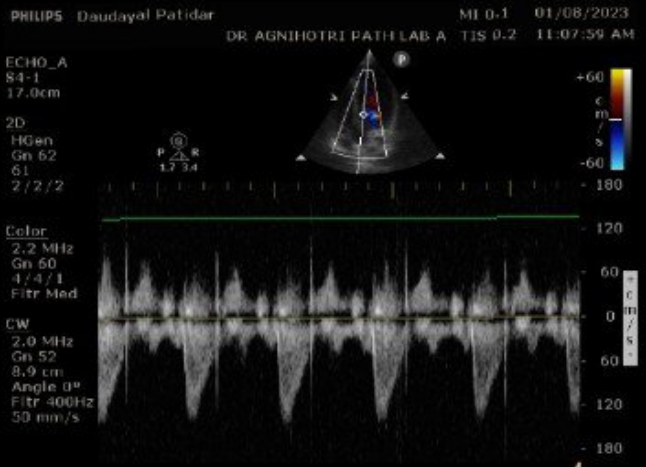
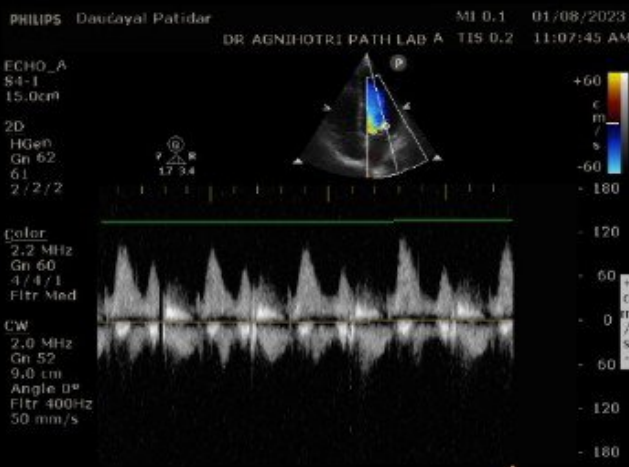
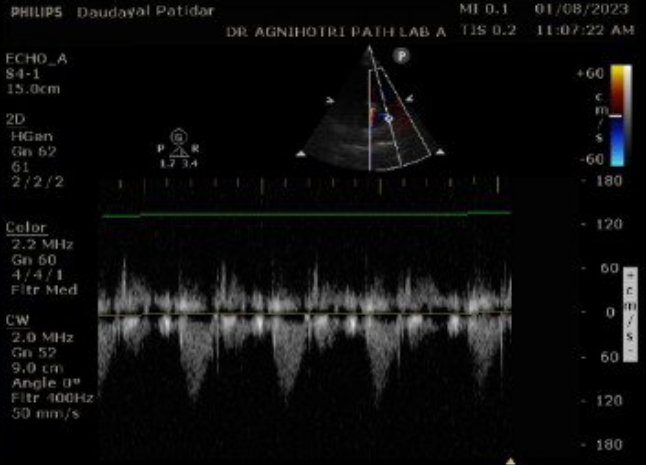
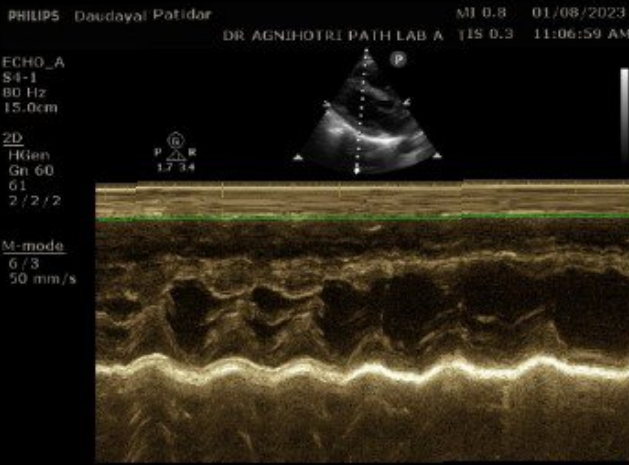
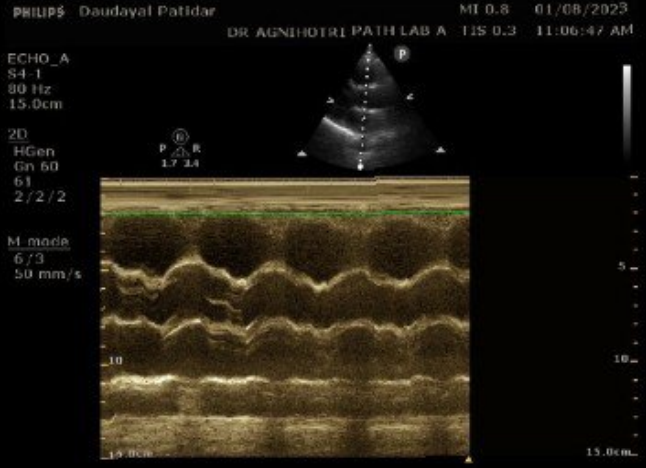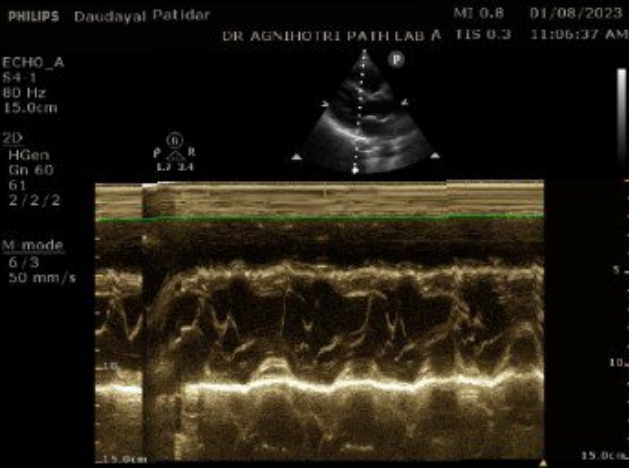
*Yash*  
**Dr. Agnihotri**  
**Cardiologist**

(C) CARDIOPRINT



# Dr. AGNIHOTRI'S PATH LAB & DIAGNOSTIC CENTER, INDORE

01 Aug 2023  
Name : Daudayal Patidar



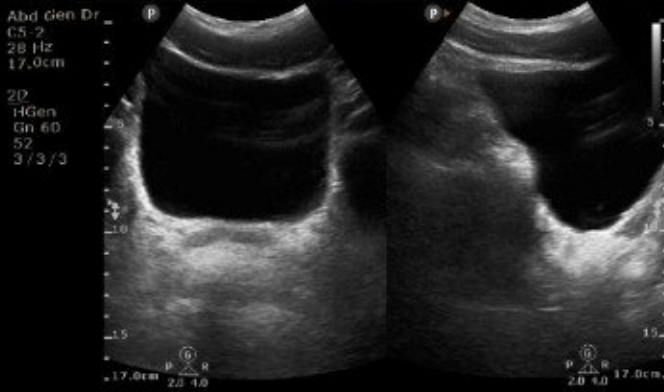


# Dr. AGNIHOTRI'S PATH LAB & DIAGNOSTIC CENTER, INDORE

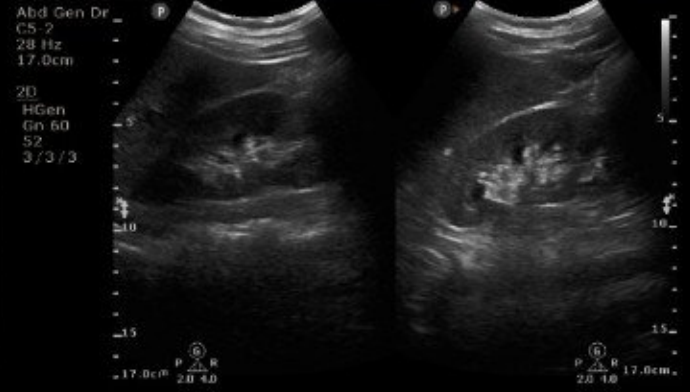
01 Aug 2023

Name : DAUDAYAL PATIDAR 34 Y M

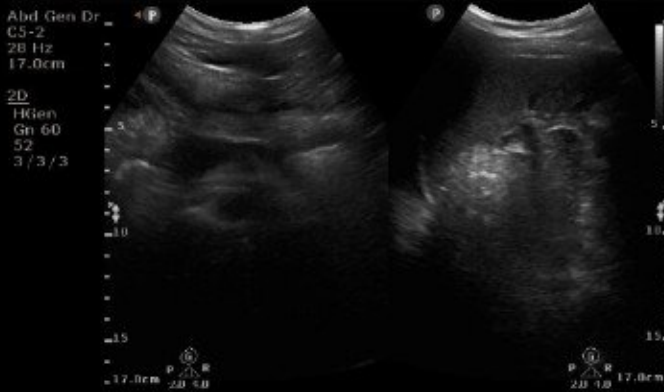
PHILIPS DAUDAYAL PATIDAR 34 Y M MI 0.9 01/08/2023  
DR. AGNIHOTRI PATH LAB A TIS 0.3 12:41:25 PM



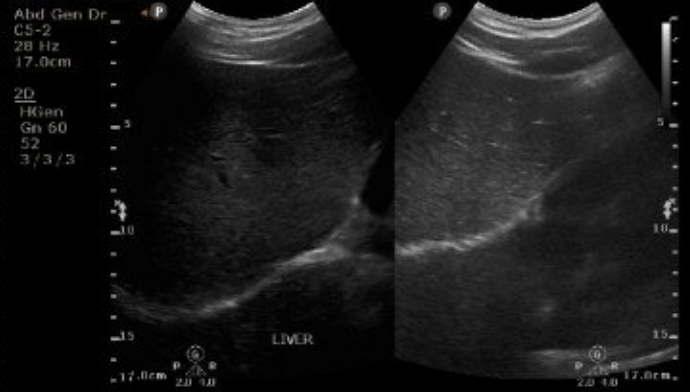
PHILIPS DAUDAYAL PATIDAR 34 Y M MI 0.9 01/08/2023  
DR. AGNIHOTRI PATH LAB A TIS 0.3 12:41:43 PM



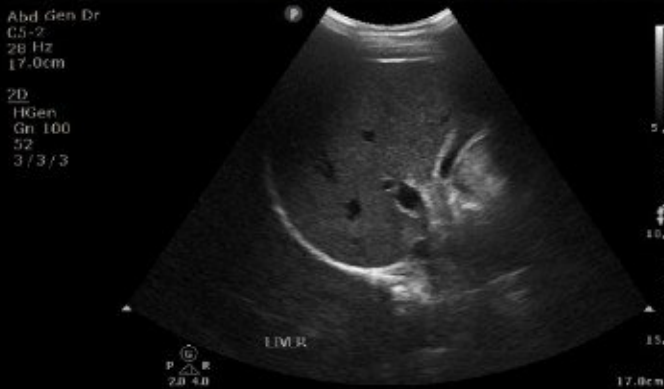PHILIPS DAUDAYAL PATIDAR 34 Y M MI 0.9 01/08/2023  
DR. AGNIHOTRI PATH LAB A TIS 0.3 12:41:54 PM



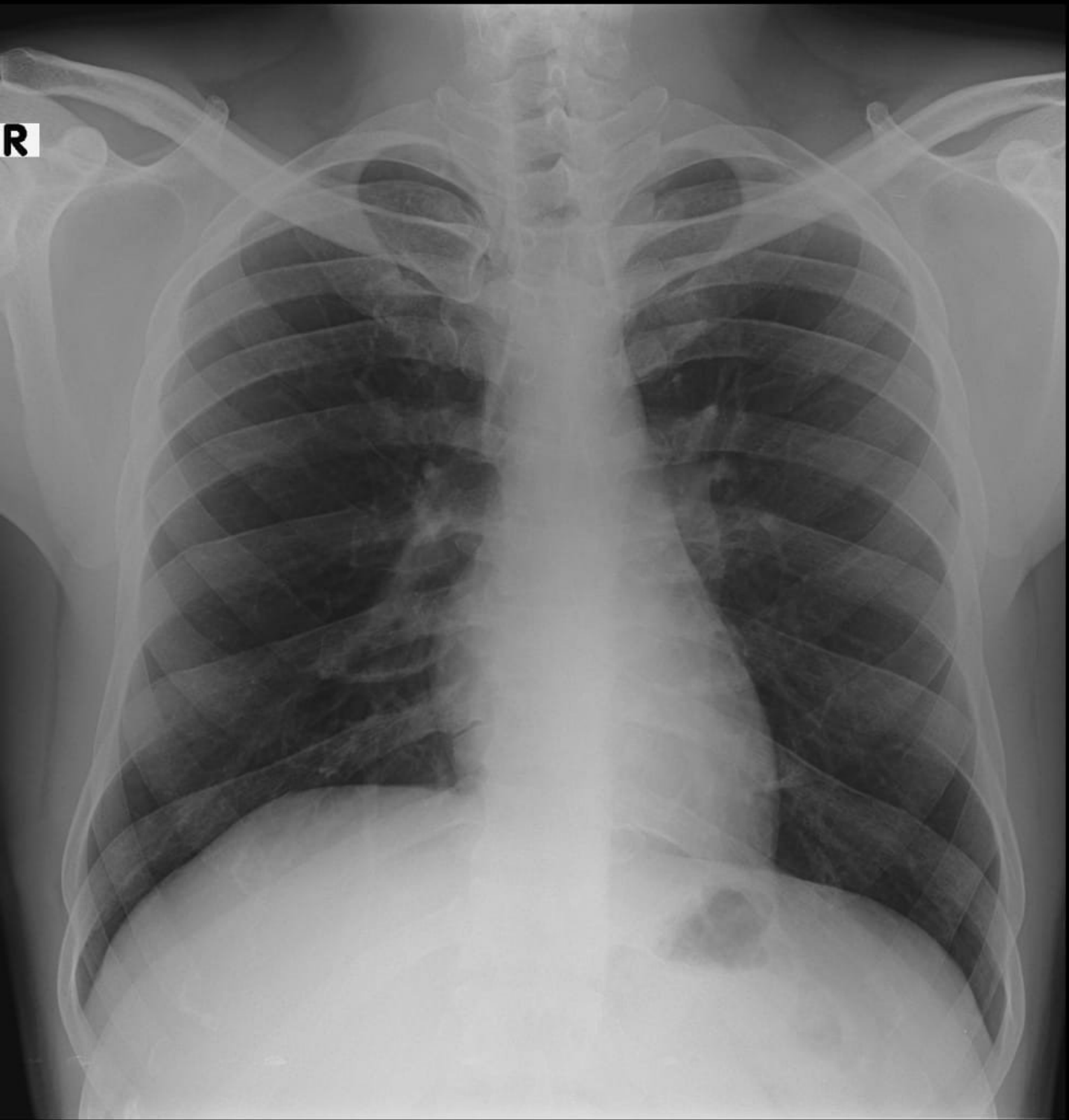
PHILIPS DAUDAYAL PATIDAR 34 Y M MI 0.9 01/08/2023  
DR. AGNIHOTRI PATH LAB A TIS 0.3 12:42:04 PM



PHILIPS DAUDAYAL PATIDAR 34 Y M MI 0.9 01/08/2023  
DR. AGNIHOTRI PATH LAB A TIS 0.3 12:42:16 PM









**MR. DAUDAYAL PATIDAR 34Y 010823050 CHEST,FRN P->A 01/08/2023**  
**Dr. Agnihotri's Path Lab & Diagnostic Centre Indore**





 **GPS Map Camera**

**Indore, Madhya Pradesh, India**

LG-5, Magnet Tower, 6/1, Curewell Hospital Rd, opp. Zari & Kurti  
Junktion, New Palasia, Indore, Madhya Pradesh 452001, India

Lat 22.727213°

Long 75.883473°

01/08/23 09:57 AM GMT +05:30



Google





भारत सरकार

Government of India



दाउदयाल पाटीदार  
Daudayal Patidar

जन्म तिथि / DOB : 25/06/1989  
पुरुष / Male



8006 0234 8062

मेरा आधार, मेरी पहचान





भारतीय विशिष्ट पहचान प्राधिकरण

Unique Identification Authority of India

पता: आत्मज: जगन्नाथ पाटीदार,  
101 हनुमान पाति, भेन्सोदा, भैसोदा,  
शाजापुर, भैसोदा, मध्य प्रदेश,  
465445

Address: S/O: Jagannath Patidar, 101  
hanuman pati, bhensoda, Bhaisoda,  
Shajapur, Bhesoda, Madhya Pradesh,  
465445

8006 0234 8062



1947



help@uidai.gov.in

WWW

www.uidai.gov.in